

# Pyoderma gangrenosum controlled with rituximab



Matthew DaCunha, MD, Spyros Siscos, MD, Malia Downing, MD, Isadore Tarantino, MD, and John Hall, MD  
Kansas City, Kansas

**Key words:** biologic therapy; pyoderma gangrenosum; rituximab; treatment.

## INTRODUCTION

Pyoderma gangrenosum (PG) is a rare inflammatory cutaneous disease. Much of the underlying pathophysiology and etiology remain poorly understood, but PG is often associated with autoimmunity and chronic inflammatory and/or neoplastic diseases.<sup>1,2</sup> The disease can be extremely variable in presentation with either single or multiple lesions presenting on various parts of the body.

PG is often difficult to diagnose because of variability of presentation, nonspecific laboratory findings, and indeterminate histology.<sup>3</sup> Other conditions associated with cutaneous ulcerations must be considered in the differential diagnosis, such as infections, vasculitis, and malignancies. No official protocol exists for treatment of PG, but therapy usually involves immunosuppression in conjunction with wound care.<sup>1,2,4</sup> We present a case of recalcitrant PG with widespread involvement that resolved with rituximab.

## CASE SYNOPSIS

A 24-year-old man presented with a 6-year history of widespread cutaneous ulcerations, including involvement of two-thirds of his face. The patient had been evaluated at multiple institutions with a working diagnosis of recalcitrant ulcerative and vegetative PG. At presentation to our facility, physical examination found vegetative plaques and ulcerations encompassing most of his face (Fig 1) and bilateral inguinal folds. The patient's attempts at pain control led to narcotic addiction, depression, and social anxiety.

Search for underlying disease processes was negative. The patient denied any history of arthritis or joint disease, and no history of such conditions were found in his medical records. Chest

### Abbreviation used:

PG: pyoderma gangrenosum

radiographs and colonoscopies were unremarkable, and multiple laboratory tests were negative with nothing to suggest any underlying malignancy. We did not conduct genetic testing for possible genodermatoses, but he did have a negative family history of autoinflammatory conditions. Excisional biopsy found sheets of dermal neutrophils with areas of granulation tissue and reactive squamous proliferation (Fig 2). Cultures and direct immunofluorescence were negative. Given the findings on pathology, clinical presentation, and exclusion of other underlying disease processes, poorly controlled, severe PG was diagnosed.

The patient had exhausted numerous treatment options over the prior 6 years, including oral and intravenous corticosteroids, ciprofloxacin, minocycline, intralesional triamcinolone, mycophenolic acid, infliximab, adalimumab, acitretin, azathioprine, apremilast, radiation, and intravenous immunoglobulin. At time of presentation, the patient had been on prednisone, for 6 years without benefit. The patient had no significant side effects from his history of prednisone use. Dual-energy x-ray absorptiometry scan was within normal limits, and he did not appear Cushingoid. We were surprised by the lack of Cushingoid appearance and other systemic corticosteroid side effects and questioned patient reliability, but we have seen other such unexplainable lack of overt side effects from long-term systemic corticosteroids, and his steroid therapy claims were validated by medical records. The patient's regimen was changed to 15 drops SSKI (saturated solution of

From the Division of Dermatology, University of Kansas Medical Center.

Funding sources: None.

Conflicts of interest: None disclosed.

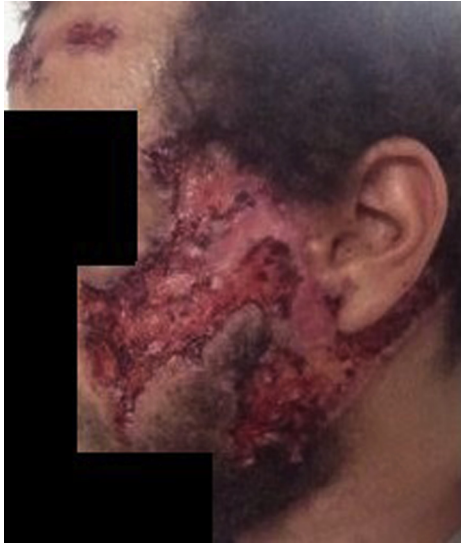Correspondence to: Matthew DaCunha, BS, 3901 Rainbow Blvd, Kansas City, KS 66160. E-mail: [mdacunha@kumc.edu](mailto:mdacunha@kumc.edu).

JAAD Case Reports 2019;5:593-5.

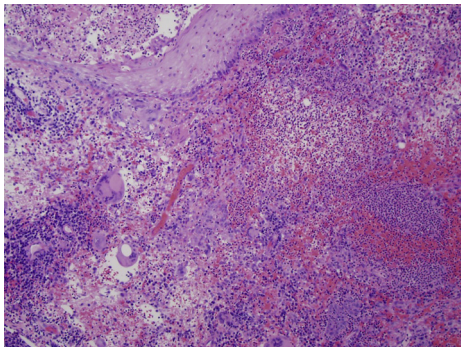
2352-5126

© 2019 by the American Academy of Dermatology, Inc. Published by Elsevier, Inc. This is an open access article under the CC BY-NC-ND license (<http://creativecommons.org/licenses/by-nc-nd/4.0/>).

<https://doi.org/10.1016/j.jidcr.2019.04.019>



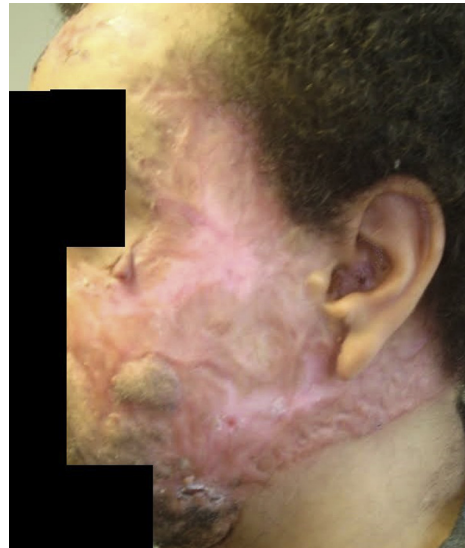**Fig 1.** Pyoderma gangrenosum. Extensive ulceration of the face with some involvement of the earlobe upon presentation to our clinic, despite being on 100 mg of prednisone daily for the past 6 years.



**Fig 2.** Sheets of dermal neutrophils with areas of granulation tissue and reactive squamous proliferation.

potassium iodide) 3 times a day, 0.5 mL per injection of 6 mg/mL intralesional triamcinolone every 3 to 4 weeks, 30 mg apremilast twice a day, 3 mg/kg intravenous immunoglobulin weekly, and 60 mg prednisone daily. At 3 and 6 months, this treatment also proved nonbeneficial, as the patient's lesions continued to spread, extending to his hairline, earlobe, and forehead.

With this failed combination therapy adding to the list of exhausted treatment options, the decision was made to attempt a trial of rituximab. Therapy was initiated at a time when all other medications had been stopped. The patient was tapered off systemic steroids successfully over 1 year. The patient noted significant improvement within 3 months of rituximab initiation and complete clearing of the disease at 6 months using monotherapy of 600 mg



**Fig 3.** Pyoderma gangrenosum. Resolution of lesions after 6 months of monotherapy with 600 mg intravenous rituximab per week.

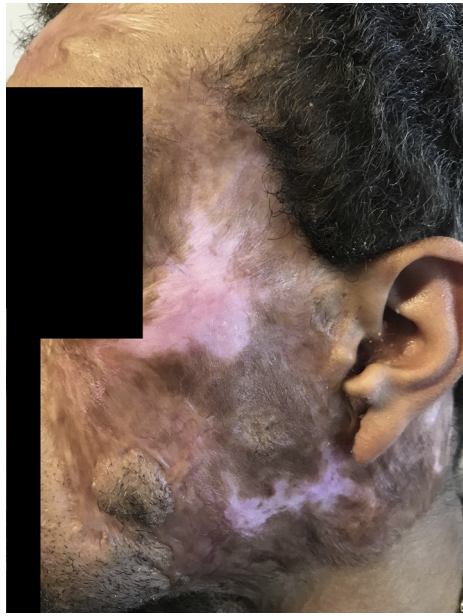intravenous rituximab per week (Fig 3). He has since been advised to taper off rituximab but has not because of fear of relapse. He has now been in remission for 10 months (Figs 3 and 4).

## DISCUSSION

PG is characterized by a rapidly progressive, painful ulceration with irregular, violaceous borders. Diagnosis is one of exclusion, as both clinical presentation and diagnostic studies can be variable or nonspecific.<sup>2-5</sup> Presentation varies in location and number of lesions. In a retrospective review by Binus et al,<sup>4</sup> it was found that PG most often occurs on the lower extremities (78%), whereas PG of the head/neck region is much more rare (7.8%).

Although the pathogenesis is not completely understood, PG is considered an inflammatory neutrophilic dermatosis.<sup>1-4</sup> It is known that PG is often associated with various autoimmune and inflammatory processes. In a retrospective review, a few of the most common conditions associated with PG included inflammatory bowel disease (34%), arthritis (29%), and hematologic disorders (20%) such as hematologic malignancies.<sup>4</sup> Therefore, it is important to screen for such conditions when PG is suspected.

PG can be classified clinically into ulcerative, pustular, bullous, and vegetative subtypes and commonly has a chronic relapsing course leaving mutilating scars upon resolution. Treatment can be challenging, and there is currently no gold standard, although therapy usually involves immunosuppression.<sup>1,2</sup>



**Fig 4.** Pyoderma gangrenosum (left profile). Complete resolution of lesions after 10 months of monotherapy with 600 mg intravenous rituximab per week.

Treatment typically targets a variety of immunologic mediators through immunosuppressants and various biologic agents. More commonly used biologics are anti-tumor necrosis factor drugs such as etanercept, adalimumab, certolizumab, and infliximab.<sup>1,2</sup> In cases of recalcitrant PG, treatment can be especially challenging. Patients with recalcitrant PG often resort to experimental or invasive therapies such as unconventional biologics, radiation, and hyperbaric oxygen,<sup>1,6,7</sup> as their condition may not be responsive to systemic steroids,<sup>8</sup> as in our case. The use of apremilast for adjunctive treatment of recalcitrant PG has also been reported.<sup>9</sup>

Case reports on the efficacy of rituximab for PG are limited. Additionally, there are anecdotal reports of rituximab causing PG.<sup>10-12</sup> Rituximab is a chimeric monoclonal antibody targeting the B-cell CD20 receptor.<sup>13</sup> Rituximab's activity leads to rapid B-cell depletion via antibody-dependent cell-mediated toxicity and apoptotic mechanisms. Rituximab is found to have significant efficacy in the management of autoimmune diseases, such as systemic lupus erythematosus, but is mostly known for its role in the management of B-cell lymphomas. Rituximab has an excellent safety profile with minimal adverse events. These effects include potential for infusion-related reactions and increased risk of infection.<sup>13,14</sup> The dosage was based on those used to treat autoimmune diseases.

Our case illustrates an atypical presentation of severe, refractory PG and provides evidence to support the use of rituximab as an option for treatment. Our case is atypical in that (1) it appears clinically to be the less common vegetative subtype, (2) 100 mg/d of prednisone for 6 years failed to prevent progression of the disease, and (3) the patient responded well to rituximab despite negative workup for underlying disease, including heme malignancy.

PG is considered a neutrophilic disease,<sup>1-4</sup> but the use of rituximab to successfully treat refractory PG shows that much remains unknown regarding its pathogenesis and treatment. Our case suggests that rituximab could be a viable treatment option for those suffering from severe, recalcitrant PG.

#### REFERENCES

1. Bhat RM. Pyoderma gangrenosum: an update. *Indian Dermatol Online J.* 2012;3(1):7-13.
2. Gameiro A, Pereira N, Cardoso JC, Gonçalo M. Pyoderma gangrenosum: challenges and solutions. *Clin Cosmet Investig Dermatol.* 2015;8:285-293.
3. Maverakis E, Ma C, Shinkai K, et al. Diagnostic criteria of ulcerative pyoderma gangrenosum. a delphi consensus of international experts. *JAMA Dermatol.* 2018;154(4):461-466.
4. Binus AM, Qureshi AA, Li VW, Winterfield LS. Pyoderma gangrenosum: a retrospective review of patient characteristics, comorbidities and therapy in 103 patients. *Br J Dermatol.* 2011;165:1244-1250.
5. Kratzsch D, Ziemer M, Milkova L, et al. Facial pyoderma gangrenosum in senescence. *Case Rep Dermatol.* 2013;5(3):295-300.
6. Cabalag MS, Wasiak J, Lim SW, Raiola FB. Inpatient management of pyoderma gangrenosum: treatments, outcomes, and clinical implications. *Ann Plast Surg.* 2015;74(3):354-360.
7. Rumeileh IA, Furlan C, Minatel E, Mascarin M. Radiation therapy for recalcitrant pyoderma gangrenosum. *G Ital Dermatol Venereol.* 2014;149(1):145-148.
8. Hinterberger L, Müller C, Vogt T, Pföhler C. Adalimumab: a treatment option for pyoderma gangrenosum after failure of systemic standard therapies. *Dermatol Ther (Heidelb).* 2012;2(1):6.
9. Laird ME, Tong LX, Lo Sicco K, et al. Novel use of apremilast for adjunctive treatment of recalcitrant pyoderma gangrenosum. *JAAD Case Rep.* 2017;3(3):228-229.
10. Dixit S, Selva-Nayagam P, Hamann I, Fischer G. Vulvovaginal pyoderma gangrenosum secondary to rituximab therapy. *J Low Genit Tract Dis.* 2015;19(1):e6-e9.
11. Maloney C, Blickenstaff N, Kugasia A, et al. Vulvovaginal pyoderma gangrenosum in association with rituximab. *JAAD Case Rep.* 2018;4(9):907-909.
12. Georgakopoulos J, Rohekar G, Lovegrove F. A case of rituximab-induced pyoderma gangrenosum. *JAAD Case Rep.* 2018;4(10):979-981.
13. Beckwith H, Lightstone L. Rituximab in systemic lupus erythematosus and lupus nephritis. *Nephron Clin Pract.* 2014;128(3-4):250-254.
14. Jones RB. Rituximab in the treatment of anti-neutrophil cytoplasm antibody-associated vasculitis. *Nephron Clin Pract.* 2014;128(3-4):243-249.