

Pulmonary edema following transcatheter closure of atrial septal defect

Keerthi Chigurupati^{1,2}, Liza Jose Reshmi², Shrinivas Gadhinglajkar², S. Venkateshwaran³, Rupa Sreedhar²

¹Departments of Cardiothoracic and Vascular Anaesthesia, ²Cardiovascular and Thoracic Anaesthesia and ³Cardiology, Sree Chitra Tirunal Institute for Medical Sciences and Technology, Trivandrum, Kerala, India

ABSTRACT

We describe an incident of development of acute pulmonary edema after the device closure of a secundum atrial septal defect in a 52-year-old lady, which was treated with inotropes, diuretics and artificial ventilation. Possibility of acute left ventricular dysfunction should be considered after the defect closure in the middle-aged patients as the left ventricular compliance may be reduced due to increased elastic stiffness and diastolic dysfunction. Baseline left atrial pressure may be > 10 mmHg in these patients. Associated risk factors for the left ventricular dysfunction are a large Qp:Qs ratio, systemic hypertension, severe pulmonary hypertension and paroxysmal atrial fibrillation.

Received: 08-12-14
Accepted: 03-04-15

Key words: Atrial septal defect; Occluder; Pulmonary edema

INTRODUCTION

Atrial septal defect (ASD) is routinely closed using occluder device in a cardiac catheterization laboratory. The device closure of ASD may be complicated with perforation of cardiac chambers and embolization of the device.^[1] We describe an incident of the development of acute pulmonary edema after the device closure of a secundum ASD.

CASE REPORT

A 52-year-old lady presented with a history of dyspnea on exertion (grade 2) and self-limiting paroxysmal atrial fibrillation (AF) since 1-year and hypertension since 3 years on T.Amlodipine 5 mg OD. Features on preoperative transthoracic echocardiography (TTE) were a 26 mm × 16 mm ostium secundum ASD shunting left-to-right, normal systolic function of the ventricles and right ventricular systolic pressure (RVSP) of 42 mmHg. The left ventricular (LV) internal diastolic diameter and systolic diameter were 42 mm/27 mm, and right ventricular (RV) diameter was 36 mm.

Chest X-ray findings were the cardiothoracic ratio of 55% and bilateral pulmonary plethora [Figure 1a]. She was scheduled for transcatheter closure of the ASD in the cardiac catheterization laboratory. On the day of the procedure in the cardiac catheterization laboratory, standard monitors were connected. After anesthesia induction with Inj.Midazolam 1 mg, Inj.Fentanyl 100 mcg, and Inj.Propofol 100 mg, Inj.Vecuronium 8 mg was used as a relaxant and patient was intubated with 7.5 mm cuffed endotracheal tube. Transesophageal echocardiography (TEE) probe was inserted (I/E 33, Philips Medical Systems, Bothell, WA, USA). Cardiac examination confirmed the findings on TTE. Cardiac catheterization studies revealed a normal coronary angiogram, a Qp: Qs shunt >2:1 and the LV end-diastolic pressure and left atrial pressure (LAP) of 10 mmHg. Pulmonary venous Doppler profile showed continuous antegrade wave during systole and diastole. The ASD was closed with the deployment of a size 28 Cocoon device. The patient was in sinus rhythm with stable hemodynamics. After confirming ASD device in place and stable, TEE probe was removed. At

Access this article online
Website: www.annals.in
DOI: 10.4103/0971-9784.159827
Quick Response Code:


Address for correspondence: Dr. Keerthi Chigurupati, Department of Cardiothoracic and Vascular Anaesthesia, Sree Chitra Tirunal Institute for Medical Sciences and Technology, Trivandrum - 695 011, Kerala, India. E-mail: keerthi@scimst.ac.in

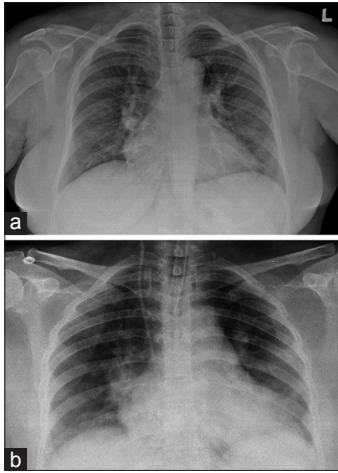


Figure 1: (a) Preoperative chest X-ray shows cardiomegaly and bilateral pulmonary plethora (b) chest X-ray after atrial septal defect device closure shows bilateral lung congestion in basal and hilar region

the end of the procedure, the neuromuscular blockade was reversed, and trachea extubated after the recovery of adequate respiratory efforts and muscle power. There was no evidence of stridor, secretions or laryngospasm immediately after tracheal extubation.

About 10 min after extubation, patient had tachycardia, hypotension, and fall in the saturation to 85%. The TTE revealed moderate LV global hypokinesia, severe tricuspid regurgitation (TR), and RVSP of 40 mmHg. The trachea was reintubated and infusion of epinephrine $0.1 \text{ mcg}^{-1} \times \text{kg}^{-1} \times \text{min}^{-1}$ and Dobutamine $10 \text{ mcg}^{-1} \times \text{kg}^{-1} \times \text{min}^{-1}$ were commenced. In addition, 40 mg furosemide and morphine 10 mg were injected. The patient was transferred to ICU and ventilated artificially. As the rhythm changed to paroxysmal AF (rate >140), infusion of Amiodarone was started. The LV contractility improved within 10 min, although the TR persisted. The troponin-T levels done 3 h after the procedure showed normal values. The chest X-ray showed features of pulmonary edema [Figure 1b], which were resolved after 14 h of ventilation. The LV systolic function as evidenced by the ejection fraction had improved as seen on repeat TTE after tracheal extubation. The patient had an uneventful recovery afterwards and was discharged on 3rd day after the procedure.

DISCUSSION

Left ventricular failure is a rare complication following device closure of ASD especially in elderly patients. Fundamental pathophysiology of ASD in young adults can be described as RV volume overload, paradoxical

movement of the interventricular septum (IVS), severe restriction in diastolic filling and chronic LV underloading.^[2-4] Prolonged RV contraction results in dyssynchronization of relaxation between the ventricular septum and the LV free wall. ASD closure ceases the RV volume overload and removes the LV diastolic restraint by restoring the IVS movements. The baseline left ventricular end-diastolic pressure (LVEDP) remains comparable with normal subjects and increases marginally after the ASD closure. The LV volume increases along with an increase in the LAP and LVEDP after the ASD closure. The transmitral Doppler E/A ratio remain normal unless the LAP remains grossly elevated due to reduced LV compliance. The E/E' increases in all patients after ASD closure.^[5] The LV pressure-volume relationship in young adults with ASD is governed by ventricular interdependence rather than a high LV passive stiffness that explains the absence of pulmonary edema after the ASD closure.

Increasing elastic stiffness and impaired intrinsic diastolic compliance of LV influence the LV pressure-volume relationship in elderly patients with ASD.^[2,5] Studies focused on LV compliance and stiffness in ASD patients reveals that the slope *k* of the elastic stiffness-stress relation is significantly greater in patients with ASD than in the normal patients, suggestive of increased chamber stiffness.^[4,6] It predicts higher LV filling pressures with respect to volume after ASD closure. In middle-aged patients, the LV compliance may also be reduced due to LV diastolic dysfunction in as many as 19% of patients,^[3] which gets unmasked after ASD occlusion causing acute increase in LAP and transmitral E/A ratio.

Apart from stiffness and diastolic dysfunction, some other factors may contribute toward LV dysfunction after the ASD closure. LV diastolic dysfunction may be associated with advanced age, severe pulmonary hypertension, systemic hypertension, hypertrophic cardiomyopathy, and aggravated by paroxysmal AF. Transcatheter closure of ASD should always be deferred in ischemic heart disease patients who need percutaneous myocardial revascularization.^[7] Coronary air embolism during the deployment of ASD device has been reported to cause cardiac dysfunction,^[8] although delayed hemodynamic deterioration and absence of increase in troponin-T levels indicate that it was not the cause of LV failure in our patient. Although, the LV dimensions in our patient were within normal limits, the baseline LAP was raised to 10 mmHg, suggesting reduced LV compliance [Table 1]. The reduced LV

Table 1: Comparing presentation between patients with and without LV dysfunction immediately after ASD closure

	Patients with LV dysfunction after ASD closure	Patients without LV dysfunction after ASD closure
Clinical parameters		
Hemodynamic deterioration	Present	Absent
Pulmonary edema	Present	Absent
Paroxysmal atrial fibrillation	May be present	Usually absent
Antifailure measures (inotropes, diuretics, afterload reducing agents)	Required	Not required
Biochemical parameters		
Troponin I	Elevated if associated acute coronary event	Normal
Echocardiographic parameters		
Isovolumic relaxation time	Prolonged	Normal or prolonged
Transmitral E/A ratio	Significantly increased	Usually normal for the age or mildly increased
Tissue Doppler E'	Reduced	Usually normal
E/E'	High	Marginally increased
LV systolic function	May be deranged	Usually normal
Catheterization parameters		
Baseline LVEDP	Elevated, may be >10 mmHg	Usually <10 mmHg
Increase in LAP compared to baseline	Significant increase	Mild increase
Peak pressure of V-wave on LAP monitoring	Significantly increased	Mildly increased

LV: Left ventricular, ASD: Atrial septal defect, LVEDP: Left ventricular end-diastolic pressure, LAP: Left atrial pressure

compliance could have precipitated pulmonary edema due to increased LAP that was compounded by the coexistence of other conditions like middle-age, large Qp: Qs ratio, systemic hypertension, pulmonary hypertension, and paroxysmal AF.

The temporary balloon occlusion of the ASD along with LAP monitoring is considered the best method to predict the risk of postclosure heart failure. If the LV compliance is reduced due to high elastic stiffness or diastolic dysfunction, the baseline mean LAP is usually >10–12 mmHg.^[2,7] Balloon occlusion in such patients markedly increases the transmitral E/A ratio and LAP, particularly in the peak pressure of V-wave.^[5,9] Current management options in potential high-risk patients for heart failure after ASD closure include pharmacological preconditioning before ASD closure and the use of the fenestrated device, which markedly reduce the mean LAP and help preventing postclosure heart failure.^[2,9,10] The pharmacological preconditioning may be performed before ASD closure for 48 h using intravenous inotropes and furosemide or for 2 months with diuretics and afterload reducing agents like enalapril. In addition, a small ASD may be left unclosed as a decompression route for both the ventricles.

In summary, the possibility of acute LV dysfunction should be considered after ASD closure in a middle-aged

patient, whose baseline LAP is elevated to 10 mmHg and above. The risk of pulmonary edema is compounded in the presence of other risk factors such as a large Qp: Qs ratio, systemic hypertension, pulmonary hypertension, and paroxysmal AF. Treatment with inotropes and diuretics, maintaining sinus rhythm, and instituting artificial ventilation may be needed to stabilize the vital parameters.

REFERENCES

1. Knirsch W, Dodge-Khatami A, Valsangiacomo-Buechel E, Weiss M, Berger F. Challenges encountered during closure of atrial septal defects. *Pediatr Cardiol* 2005;26:147-53.
2. Masutani S, Senzaki H. Left ventricular function in adult patients with atrial septal defect: Implication for development of heart failure after transcatheter closure. *J Card Fail* 2011;17:957-63.
3. Stojnic B, Krajcer Z, Pavlovic P, Nozic M, Aleksandrov R, Prcovic M. Pulsed Doppler assessment of left ventricular diastolic function in atrial septal defect. *Tex Heart Inst J* 1992;19:258-64.
4. Satoh A, Katayama K, Hiro T, Yano M, Miura T, Kohno M, et al. Effect of right ventricular volume overload on left ventricular diastolic function in patients with atrial septal defect. *Jpn Circ J* 1996;60:758-66.
5. Gruner C, Akkaya E, Kretschmar O, Roffi M, Corti R, Jenni R, et al. Pharmacologic preconditioning therapy prior to atrial septal defect closure in patients at high risk for acute pulmonary edema. *J Interv Cardiol* 2012;25:505-12.

6. Booth DC, Wisenbaugh T, Smith M, DeMaria AN. Left ventricular distensibility and passive elastic stiffness in atrial septal defect. *J Am Coll Cardiol* 1988;12:1231-6.
7. Tomai F, Gaspardone A, Papa M, Polisca P. Acute left ventricular failure after transcatheter closure of a secundum atrial septal defect in a patient with coronary artery disease: A critical reappraisal. *Catheter Cardiovasc Interv* 2002;55:97-9.
8. Huang YY, Chen MR. Coronary air embolism during transcatheter closure of atrial septal defects. *J Pediatr* 2014;164:669.
9. Ewert P, Berger F, Nagdyman N, Kretschmar O, Dittrich S, Abdul-Khaliq H, *et al.* Masked left ventricular restriction in elderly patients with atrial septal defects: A contraindication for closure? *Catheter Cardiovasc Interv* 2001;52:177-80.
10. Schubert S, Peters B, Abdul-Khaliq H, Nagdyman N, Lange PE, Ewert P. Left ventricular conditioning in the elderly patient to prevent congestive heart failure after transcatheter closure of atrial septal defect. *Catheter Cardiovasc Interv* 2005;64:333-7.

Cite this article as: Chigurupati K, Reshmi LJ, Gadhinglajkar S, Venkateshwaran S, Sreedhar R. Pulmonary edema following transcatheter closure of atrial septal defect. *Ann Card Anaesth* 2015;18:441-4.

Source of Support: Nil, **Conflict of Interest:** None declared.