

Combination Therapy Using Prothrombin Complex Concentrate and Vitamin K in Anticoagulated Patients with Traumatic Intracranial Hemorrhage Prevents Progressive Hemorrhagic Injury: A Historically Controlled Study

Hiroshi KOYAMA,^{1,2} Kenji YAGI,¹ Keijiro HARA,¹ Shunji MATSUBARA,¹
Yoshifumi TAO,¹ and Masaaki UNO¹

¹*Department of Neurosurgery, Kawasaki Medical School, Kurashiki, Okayama, Japan*

²*Department of Neurosurgery, Tokushima University Hospital, Tokushima, Tokushima, Japan*

Abstract

Warfarin remains crucially involved in the treatment of patients at thrombotic or thromboembolic risk. However, warfarin increases the mortality rate among patients with traumatic intracranial hemorrhage (TICH) through progressive hemorrhagic injury (PHI). Therefore, a rapid anticoagulation reversal could be required in patients with TICH to prevent PHI. Differences in the warfarin reversal effect between combination therapy of prothrombin complex concentrate (PCC) with vitamin K (VK) and VK monotherapy remain unclear. However, studies have reported that PCC has greater effectiveness and safety for warfarin reversal compared with fresh frozen plasma (FFP). This retrospective study aimed to evaluate the warfarin reversal effects of combination therapy of PCC with VK and VK monotherapy on TICH. We compared the clinical outcomes between the periods before and after the PCC introduction in our hospital. There were 13 and 7 patients who received VK monotherapy and PCC with VK, respectively. PHI predictors were evaluated using univariate regression analyses. Warfarin reversal using PCC had a significant negative association with PHI (odds ratio: 0.03, 95% confidence interval: 0.00–0.41, $P = 0.004$). None of the patients presented with thrombotic complications. Warfarin reversal through a combination of PCC with VK could be more effective for inhibiting post-trauma PHI compared with VK monotherapy. This could be attributed to a rapid and stable warfarin reversal. PCC should be administered to patients with TICH taking warfarin for PHI prevention.

Keywords: prothrombin complex concentrate, Vitamin K, warfarin reversal, progressive hemorrhagic injury, traumatic intracranial hemorrhage

Introduction

With increasing life expectancy, there has been a concomitant increase in the number of patients requiring long-term anticoagulation to prevent arterial fibrillation-associated cerebral or systemic embolism and deep venous thrombosis.¹⁾ These patients receive oral anticoagulants, including warfarin as a vitamin K (VK) antagonist or direct oral anticoagulants

(DOAC). A previous large-scale randomized clinical trial reported that DOAC and warfarin had similar efficacy and safety.^{2–5)} Furthermore, DOAC has predictable pharmacokinetics and does not require routine monitoring since their anticoagulating effect does not interact with VK and interacts less frequently with other drugs. Therefore, DOAC has been preferably used for thromboembolic disease prevention recently. However, warfarin remains crucially involved in the treatment of patients at thrombotic or thromboembolic risk, including those with an artificial valve, mitral stenosis, etc.²⁾ Furthermore, warfarin is administered to patients with severe renal impairment who cannot be treated with DOAC.

Received July 21, 2020; Accepted September 23, 2020

Copyright© 2021 by The Japan Neurosurgical Society This work is licensed under a Creative Commons Attribution-NonCommercial-NoDerivatives International License.

Head trauma could cause an acute subdural hematoma, acute epidural hematoma, cerebral contusion, and traumatic subarachnoid hematoma. Progressive hemorrhagic injury (PHI) could cause a worsening of neurological conditions.³⁾ Warfarin increases the mortality rate among patients with traumatic intracranial hemorrhage (TICH) since it inhibits hemostasis.⁶⁻⁸⁾ Therefore, a rapid anticoagulation reversal in patients with TICH might be required for PHI prevention.

VK, fresh frozen plasma (FFP), and prothrombin complex concentrate (PCC) are available for warfarin reversal in emergencies.²⁾ PCC, which is the most recent to become clinically available, could have greater advantages compared with FFP. This is because it does not require blood typing and cross-matching; moreover, it eliminates the risk of FFP-related volume overload. Furthermore, compared with VK, PCC normalizes prothrombin time/international normalized ratio (PT-INR) more rapidly.^{9,10)} Studies have reported that PCC for warfarin reversal could have greater effectiveness and safety than FFP.¹¹⁾ However, prior to PCC becoming clinically available, warfarin reversal was commonly achieved using VK alone rather than FFP infusion followed by VK. This could be because patients on warfarin treatment often present poor cardiac function and FFP could cause volume-overload associated with congestive heart failure.^{2,12)} There is a need to study differences in the warfarin reversal effect in patients with head trauma between combination therapy of PCC with VK and VK monotherapy.

This retrospective study aimed to evaluate the warfarin reversal effects of a combination of PCC with VK and VK monotherapy in patients with TICH. Furthermore, we aimed to compare the clinical outcomes between the periods before and after the PCC introduction in our hospital.

Methods

The protocol for this retrospective study was approved by the ethics committee at our institution, which waived the requirement for patient consent (No. 3758). We retrospectively reviewed the medical records of 498 adult patients (≥ 18 years old) admitted at our hospital between February 2016 and November 2019 due to TICH within 12 post-injury hours (Fig. 1). Among them, 35 patients underwent warfarin treatment with a PT-INR of ≥ 1.4 . Seven patients were infused with FFP to treat coincidental systemic massive hemorrhage due to aortic, hepatic, or pulmonary injuries. They were excluded from the study population because the clinical status is different from the others. In our hospital, four-factor

PCC (4F-PCC) (Kcentra), which is among the clinically available PCC, was introduced for warfarin reversal from December 2017. We considered the periods before and after November 2017 as the VK era and PCC era, respectively. There 18 and 10 patients in the VK and PCC eras, respectively.

We excluded patients with mild head injury or excessively severe trauma on admission who did not receive treatment for warfarin reversal effect. The treatment outcome was evaluated in the remaining 20 patients (13 and 7 patients in the VK and PCC era, respectively). Immediately after TICH identification, all patients in the VK and PCC era were treated using intravenous administration of VK and PCC in combination with VK, respectively. Regarding the patients' demographic and clinical characteristics, only time from injury to admission showed a significant between-group difference where it was longer in the VK era than in the PCC era (Table 1).

All the patients underwent a computer tomography (CT) scan on admission and repeat scans at least twice within 3 and 4-24 hours after admission. PHI was evaluated on the repeat CT scans and defined as follows: the appearance of a new intracranial hematoma, including intracerebral, intraventricular, subdural, epidural, or subarachnoid hemorrhage not caused by redistributed hemorrhage or expansion of pre-existing hematoma indicated by a qualitative increase in the volume by 1.4 times greater than the volume on the admission CT.¹³⁾

For warfarin reversal with and without PCC, the target PT-INR level was < 1.40 . Regarding reversal using PCC, PCC was intravenously administered immediately followed by intravenous VK administration (10–20 mg). The administered PCC dose was determined according to our institutional protocol, which was approved by the medical safety commission of our hospital, as follows: 25 IU/kg, 35 IU/kg, and 50 IU/kg were given to patients with INR 1.4–4, 4.0–6.0, and > 6 , respectively. PCC was only administered once. Contrastingly, 10 mg VK was repeatedly administered in case the PT-INR was ≥ 1.4 in the follow-up test at 8–12 post-admission hours. We performed between-reversal comparisons of the rates of reaching the target PT-INR at half a day after hospitalization.

The PHI incidence was evaluated in all the patients who underwent reversal treatment. Furthermore, we performed between-reversal comparisons of the in-hospital death; modified Rankin Scale (mRS) at discharge; and adverse events, including myocardial infarction, ischemic stroke, pulmonary embolism, and deep vein thrombosis.

Table 1 presents the patients' baseline and clinical characteristics. Hypertension was defined as a

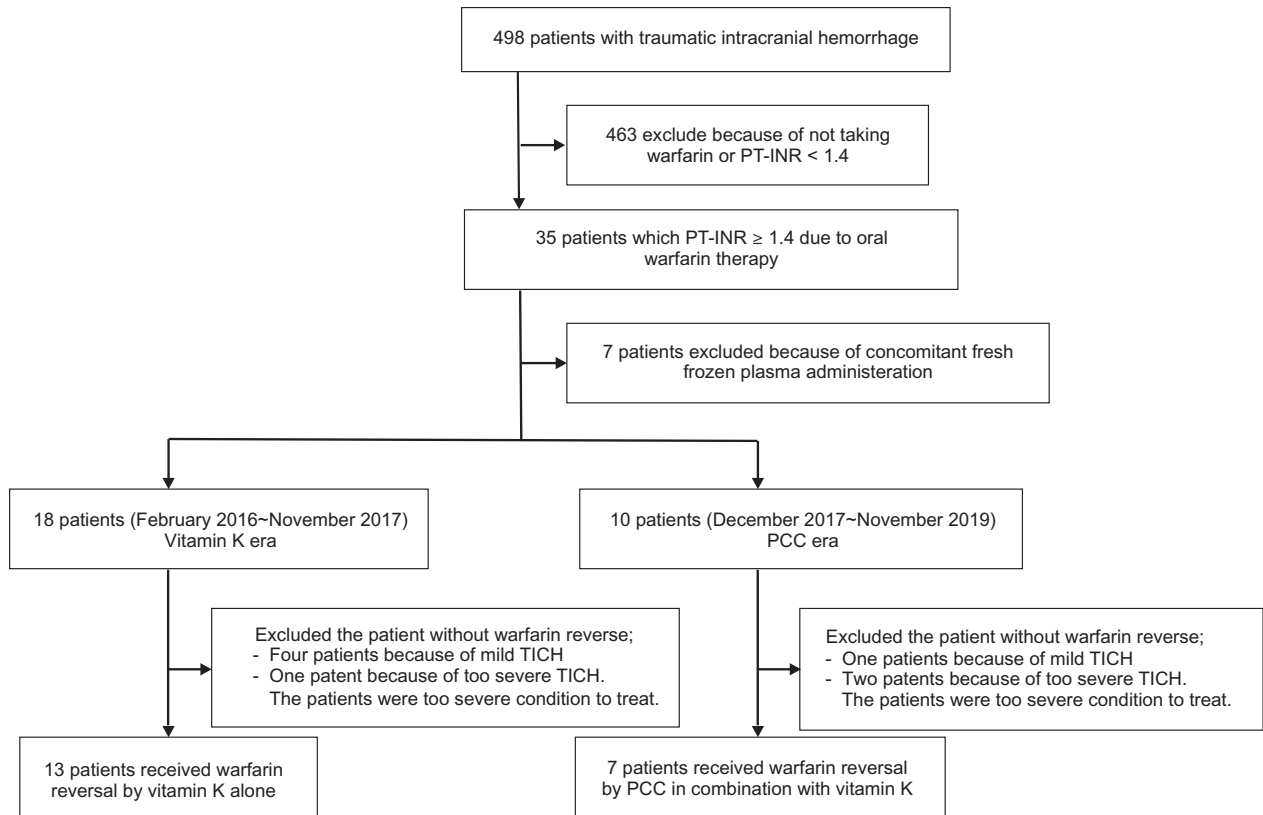


Fig. 1 Study profile. PCC: prothrombin complex concentrate, PT-INR: prothrombin time-international normalized ratio, TICH: traumatic intracranial hemorrhage.

pre-injury or pre-treatment systolic and/or diastolic blood pressure of ≥ 140 mmHg and ≥ 90 mmHg, respectively. Patients were considered to have diabetes if their glycosylated hemoglobin A1C level exceeded 6.5% or if they were being treated with insulin and/or oral hypoglycemic medications. The used antiplatelet drugs included aspirin, cilostazol, and clopidogrel with none of the patients taking prasugrel and ticlopidine hydrochloride.

Continuous variables were expressed as mean \pm SD or median (interquartile range [IQR]). Categorical variables were expressed as number (%). All statistical analyses were performed using JMP version 15 software (SAS Institute, Tokyo, Japan). Statistical significance was set at $P < 0.05$. Between-group comparisons were performed using Fisher's exact test or Mann–Whitney U test. Univariable logistic regression analyses were performed to determine PHI predictors.

Results

Figure 2 shows the time course of PT-INR in the seven patients who underwent combination therapy of PCC with VK. There was a rapid decrease in PT-INR, which

reached its target (< 1.40) at 1 hour after the start of warfarin reversal in all patients. PT-INR at half a day after reversal remained < 1.40 in most patients except one who presented a PT-INR of 1.41.

There were no patients who had new bleeding at other sites and all of the PHI was identified as an expansion of pre-existing hematomas. Patients who underwent warfarin therapy had a high PHI incidence. Among the 20 patients, 12 (60%) patients presented with PHI. The PHI incidence was significantly lower in patients who underwent PCC therapy than VK monotherapy (84.6% vs. 14.3%, $P = 0.004$; Table 2). There were numerically, but not significantly, more patients who underwent PCC therapy with a PT-INR < 1.40 at half a day after warfarin reversal induction compared with those who underwent VK monotherapy (85.7% vs 30.8%). There were no significant between-reversal differences in the hospitalization period, mRS at discharge, mortality, and rate of surgical treatment by craniotomy.

As shown in Table 3, PHI predictors were evaluated by univariate regression analyses. Warfarin reversal using PCC had a significant negative association with PHI (odds ratio: 0.03, 95% confidence interval: 0.00–0.41, $P = 0.004$). Contrastingly, other demographic

Table 1 Patient baseline and clinical characteristics

	Total	VK monotherapy (n = 13)	Combination with PCC (n = 7)	P value
Age	79.1 ± 7.08	78.6 ± 7.2	80 ± 6.6	0.72
Female gender	7 (35%)	5 (38.5%)	2 (28.6%)	>0.99
Hypertension	14 (70%)	13 (69.2%)	5 (71.4%)	>0.99
Diabetes mellitus	9 (45%)	6 (46.2%)	3 (42.9%)	>0.99
Antiplatelet therapy	6 (30%)	5 (38.5%)	1 (14.3%)	0.35
mRS before injury	3 (1–3)	5 (4–6)	4 (3.5–5.5)	0.93
GCS on admission	12 (11–14.3)	12 (8.5–14)	12 (11–15)	0.54
PT-INR at admission	2.33 (1.70–3.18)	2.52 (1.78–3.17)	1.83 (1.67–3.39)	>0.99
Time from injury to admission (hour)	3.7 ± 2.6	4.5 ± 2.8	2.1 ± 1.3	0.02*
Use of tranexamic acid	60 (%)	7 (53.9%)	5 (71.4%)	0.64

Data are presented as mean (SD), number (%), or median (IQR). *Indicates statistical significance. GCS: Glasgow Coma Scale, IQR: interquartile range, mRS: modified Rankin Scale, PCC: prothrombin complex concentrate, PT-INR: prothrombin time-international normalized ratio, VK: vitamin K.

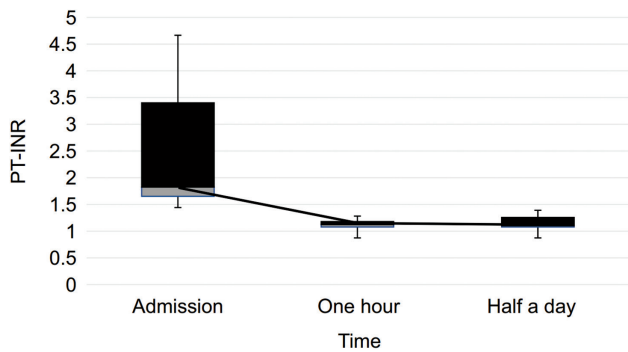


Fig. 2 Time course of PT-INR in patients with combination therapy of PCC with VK. PCC: prothrombin complex concentrate, PT-INR: prothrombin time-international normalized ratio, VK: vitamin K.

and patient characteristics were not associated with PHI. Hemostasis-related factors, including antiplatelet therapy and tranexamic acid administration, did not affect PHI. Severely impaired consciousness (Glasgow Coma Scale [GCS] <12) and delayed admission (time from injury to admission >4 hours) did not affect PHI. Higher PT-INR (>2.0) at admission was not associated with PHI. Patients who reached the target-PT-INR (<1.4) at half a day tended to have less PHI but it was not statistically significant.

Discussion

There have been numerous reports that warfarin reversal using PCC is effective in patients with non-TICH or TICH.^{11,14–28)} However, these studies compared warfarin reversal using PCC and FFP^{11,14–28)}

with none of the studies comparing the treatment outcome of warfarin reversal using combination therapy of PCC with VK and VK monotherapy. The use of FFP is associated with a greater risk of volume overload and heart failure.⁹⁾ In some clinical settings, FFP administration for warfarin reversal is difficult since patients on anticoagulant therapy present with a high risk of heart failure, and the complication rate of atrial fibrillation increases in proportion to the severity of heart failure.²⁹⁾ Moreover, heart failure has been reported in 37% of newly developed atrial fibrillation.³⁰⁾ Therefore, there is a need to directly compare the recent warfarin reversal using a combination therapy of PCC and conventional reversal using VK monotherapy. In this novel study, we found that warfarin reversal by PCC significantly suppressed PHI compared with VK monotherapy.

Warfarin treatment is associated with poor prognosis of patients with TICH. Ivascu et al. reported that oral warfarin increased the mortality rate in patients with TICH (48%), which is approximately five times higher than that in patients without anticoagulant therapy.³¹⁾ The observed poor outcome under warfarin treatment could be attributed to the anticoagulation causing PHI.^{7,32–34)} Oral anticoagulation is associated with PHI even in patients with minor head trauma.³¹⁾ Therefore, there is a need to improve the prognosis of patients with head trauma under anticoagulant therapy by rapidly neutralizing the anticoagulant effect. Furthermore, risk factors for PHI have been shown to include older age, male gender, and larger initial lesions.^{35–40)} However, these findings were not observed in our study given its small sample size.

Table 2 Patient characteristics of the hematoma expansion positive and negative groups

	Total (n = 20)	VK monotherapy (n = 13)	Combination with PCC (n = 7)	P value
PHI	12 (60)	11 (84.6)	1 (14.3)	0.004*
Reached target-PT-INR after a half day	10 (50)	4 (30.8)	6 (85.7)	0.057
Hospitalization (day)	22.6 ± 30.2	15.1 ± 15.0	36.4 ± 45.7	0.27
mRS at discharge	4.5 (3–6)	5 (4–6)	4 (3.5–5.5)	0.46
Death	8 (40)	6 (46.2)	2 (28.6)	0.48
Craniotomy	3 (15)	2 (15.3)	1 (14.3)	>0.99

Data are shown as mean (SD), number (%), or median (IQR). *Shows statistical significance. mRS: modified Rankin Scale, PCC: prothrombin complex concentrate, PHI: progressive hemorrhagic injury, PT-INR: prothrombin time-international normalized ratio, VK: vitamin K.

Table 3 Univariable analysis of predictors of hematoma expansion

Predictor	Odds ratio	95% Confidence interval	P value
Age >80	0.43	0.07–2.68	0.65
Female sex	0.84	0.092–8.32	>0.99
Hypertension	1.8	0.26–12.5	0.62
Diabetes mellitus	0.3	0.05–1.94	0.36
Antiplatelet therapy	4.9	0.46–54.5	0.32
Tranexamic acid	2.1	0.32–12.5	0.65
GCS score at admission <12	3.1	0.422–21.3	0.37
Delayed admission†	1.19	0.19–7.46	>0.99
Higher PT-INR (>2.0) at admission	0.84	0.134–5.26	>0.99
Reaching target-PT-INR after a half day	0.17	0.0225–1.23	0.17
Reversal using PCC	0.03	0.00–0.41	0.004*

†Time from injury to admission was >4 hours. *Shows a statistical significance. GCS: Glasgow Coma Scale, PCC: prothrombin complex concentrate, PT-INR: prothrombin time-international normalized ratio.

For warfarin reversal, the use of PCC, rather than FFP, was associated with a more rapid decrease in the PT-INR^{17,18,22)} and a higher rate of achieving the target PT-INR value without a cardiovascular volume load.⁹⁾ VK, which induces production of warfarin-inhibiting coagulant factors in the liver, takes about 24 hours to fully exert its effect to modulate prolonged PT-INR by warfarin.⁴¹⁾ PCC intravenous administration is to compensate for the shortage of coagulant factor and shows a more rapid decrease in PT-INR levels than VK intravenous administration alone.⁴²⁾ Rapid PT-INR correction by PCC is considered to suppress PHI more effectively than VK alone in patients taking warfarin. To neutralize a warfarin effect by PCC, the short-lasting effect of PCC should be paid attention to. PCC without VK may result in a re-increase in PT-INR and clinical deterioration.⁴³⁾ Therefore, to maintain the rapidly corrected PT-INR by PCC, VK plays an important role. These

were consistent with our findings that, in the present study, most of the patients who underwent the combination therapy using PCC and VK had normalized values of PT-INR rapidly (at 1 hour after PCC administration) and remained within or close to the reference values after 12 hours. Immediate and stable effect of the combination of PCC and VK is considered to prevent PHI.

Anticoagulant therapy neutralization is associated with thrombosis risk.^{44,45)} There have been reports on adverse events of PCC, including ischemic stroke, anaphylactic shock, disseminated intravascular coagulation, and deep vein thrombosis.^{43,46–50)} However, none of our patients presented with complications in the present study. Given the association of warfarin with PHI, which could increase the mortality rate,⁵¹⁾ we suggest that anticoagulation neutralization should be performed as early as possible in patients with traumatic head injury under anticoagulant therapy.

PCC contains concentrated VK-dependent coagulation factors (factors II, VII, IX, and X) extracted from large donor-pooled plasma and stored as a lyophilized powder. Currently, PCC is available in two forms: 4F-PCC^{11,14–16,24)} and three-factor PCC (3F-PCC),^{18–21,23)} which have both been used in previous studies. Compared with 3F-PCC, 4F-PCC contains higher levels of factor VII, as well as some anticoagulant proteins (Protein C, Protein S, Anti-thrombin, and heparin),⁵²⁾ and is associated with rapid INR reversal and a reduction in transfusion requirement without the risk of thromboembolic events.⁵³⁾ However, it remains unclear whether 4F-PCC is better than 3F-PCC.

This study has several limitations. First, this was a retrospective study with a small number of patients. Furthermore, there could have been patient selection bias. However, this was minimized by comparing warfarin-reversal using PCC with historical control. Second, although PCC may improve the prognosis of patients with TICH, this was not assessed. There is a need for further studies to confirm our findings and the PCC effect on the prognosis.

Conclusion

Warfarin reversal using combination therapy of PCC with VK after head trauma might be more effective for PIH inhibition than using VK monotherapy. This could be attributed to the rapid and stable neutralization of the warfarin anticoagulant effect. Furthermore, treatment with PCC was not associated with major thrombotic complications. PCC should be administered to patients with TICH taking warfarin to prevent PHI.

Conflicts of Interest Disclosure

All authors declare that they have no conflicts of interest.

References

- 1) Bechtel BF, Nunez TC, Lyon JA, Cotton BA, Barrett TW: Treatments for reversing warfarin anticoagulation in patients with acute intracranial hemorrhage: a structured literature review. *Int J Emerg Med* 4: 40, 2011
- 2) Yamashita Y, Uozumi R, Hamatani Y, et al.: Current status and outcomes of direct oral anticoagulant use in real-world atrial fibrillation patients-Fushimi AF registry. *Circ J* 81: 1278–1285, 2017
- 3) Compagnone C, d'Avella D, Servadei F, et al.: Patients with moderate head injury: a prospective multicenter study of 315 patients. *Neurosurgery* 64: 690–696; discussion 696–697, 2009
- 4) Iaccarino C, Schiavi P, Picetti E, et al.: Patients with brain contusions: predictors of outcome and relationship between radiological and clinical evolution. *J Neurosurg* 120: 908–918, 2014
- 5) Tierney KJ, Nayak NV, Prestigiacomo CJ, Sifri ZC: Neurosurgical intervention in patients with mild traumatic brain injury and its effect on neurological outcomes. *J Neurosurg* 124: 538–545, 2016
- 6) Mina AA, Bair HA, Howells GA, Bendick PJ: Complications of preinjury warfarin use in the trauma patient. *J Trauma* 54: 842–847, 2003
- 7) Karni A, Holtzman R, Bass T, et al.: Traumatic head injury in the anticoagulated elderly patient: a lethal combination. *Am Surg* 67: 1098–1100, 2001
- 8) Mina AA, Knipfer JF, Park DY, Bair HA, Howells GA, Bendick PJ: Intracranial complications of preinjury anticoagulation in trauma patients with head injury. *J Trauma* 53: 668–672, 2002
- 9) Refaai MA, Goldstein JN, Lee ML, Durn BL, Milling TJ, Sarode R: Increased risk of volume overload with plasma compared with four-factor prothrombin complex concentrate for urgent vitamin K antagonist reversal. *Transfusion* 55: 2722–2729, 2015
- 10) Huttner HB, Schellinger PD, Hartmann M, et al.: Hematoma growth and outcome in treated neurocritical care patients with intracerebral hemorrhage related to oral anticoagulant therapy: comparison of acute treatment strategies using vitamin K, fresh frozen plasma, and prothrombin complex concentrates. *Stroke* 37: 1465–1470, 2006
- 11) Steiner T, Poli S, Griebel M, et al.: Fresh frozen plasma versus prothrombin complex concentrate in patients with intracranial haemorrhage related to vitamin K antagonists (INCH): a randomised trial. *Lancet Neurol* 15: 566–573, 2016
- 12) Chai-Adisaksotha C, Hillis C, Siegal DM, et al.: Prothrombin complex concentrates versus fresh frozen plasma for warfarin reversal. A systematic review and meta-analysis. *Thromb Haemost* 116: 879–890, 2016
- 13) Kazui S, Naritomi H, Yamamoto H, Sawada T, Yamaguchi T: Enlargement of spontaneous intracerebral hemorrhage. Incidence and time course. *Stroke* 27: 1783–1787, 1996
- 14) Huhtakangas J, Tetri S, Juvela S, et al.: Improved survival of patients with warfarin-associated intracerebral haemorrhage: a retrospective longitudinal population-based study. *Int J Stroke* 10: 876–881, 2015
- 15) Kuwashiro T, Yasaka M, Itabashi R, et al.: Effect of prothrombin complex concentrate on hematoma enlargement and clinical outcome in patients with anticoagulant-associated intracerebral hemorrhage. *Cerebrovasc Dis* 31: 170–176, 2011
- 16) Majeed A, Meijer K, Larrazabal R, et al.: Mortality in vitamin K antagonist-related intracerebral bleeding treated with plasma or 4-factor prothrombin complex concentrate. *Thromb Haemost* 111: 233–239, 2014
- 17) Yanamadala V, Walcott BP, Fecci PE, et al.: Reversal of warfarin associated coagulopathy with 4-factor prothrombin complex concentrate in traumatic brain

- injury and intracranial hemorrhage. *J Clin Neurosci* 21: 1881–1884, 2014
- 18) Edavettal M, Rogers A, Rogers F, Horst M, Leng W: Prothrombin complex concentrate accelerates international normalized ratio reversal and diminishes the extension of intracranial hemorrhage in geriatric trauma patients. *Am Surg* 80: 372–376, 2014
 - 19) Fong WC, Lo WT, Ng YW, et al.: The benefit of prothrombin complex concentrate in decreasing neurological deterioration in patients with warfarin-associated intracerebral haemorrhage. *Hong Kong Med J* 20: 486–494, 2014
 - 20) Frontera JA, Gordon E, Zach V, et al.: Reversal of coagulopathy using prothrombin complex concentrates is associated with improved outcome compared to fresh frozen plasma in warfarin-associated intracranial hemorrhage. *Neurocrit Care* 21: 397–406, 2014
 - 21) Hanger HC, Geddes JA, Wilkinson TJ, Lee M, Baker AE: Warfarin-related intracerebral haemorrhage: better outcomes when reversal includes prothrombin complex concentrates. *Intern Med J* 43: 308–316, 2013
 - 22) Siddiq F, Jalil A, McDaniel C, et al.: Effectiveness of factor IX complex concentrate in reversing warfarin associated coagulopathy for intracerebral hemorrhage. *Neurocrit Care* 8: 36–41, 2008
 - 23) Woo CH, Patel N, Conell C, et al.: Rapid Warfarin reversal in the setting of intracranial hemorrhage: a comparison of plasma, recombinant activated factor VII, and prothrombin complex concentrate. *World Neurosurg* 81: 110–115, 2014
 - 24) Jehan F, Aziz H, O’Keeffe T, et al.: The role of four-factor prothrombin complex concentrate in coagulopathy of trauma: a propensity matched analysis. *J Trauma Acute Care Surg* 85: 18–24, 2018
 - 25) Baldi G, Altomonte F, Altomonte M, et al.: Intracranial haemorrhage in patients on antithrombotics: clinical presentation and determinants of outcome in a prospective multicentric study in Italian emergency departments. *Cerebrovasc Dis* 22: 286–293, 2006
 - 26) Kalina M, Tinkoff G, Gbadebo A, Veneri P, Fulda G: A protocol for the rapid normalization of INR in trauma patients with intracranial hemorrhage on prescribed warfarin therapy. *Am Surg* 74: 858–861, 2008
 - 27) Zubkov AY, Mandrekar JN, Claassen DO, Manno EM, Wijdicks EF, Rabinstein AA: Predictors of outcome in warfarin-related intracerebral hemorrhage. *Arch Neurol* 65: 1320–1325, 2008
 - 28) Paisley MJ, Johnson A, Price S, et al.: Reversal of warfarin anticoagulation in geriatric traumatic brain injury due to ground-level falls. *Trauma Surg Acute Care Open* 4: e000352, 2019
 - 29) Maisel WH, Stevenson LW: Atrial fibrillation in heart failure: epidemiology, pathophysiology, and rationale for therapy. *Am J Cardiol* 91: 2D–8D, 2003
 - 30) Santhanakrishnan R, Wang N, Larson MG, et al.: Atrial fibrillation begets heart failure and vice versa: temporal associations and differences in preserved versus reduced ejection fraction. *Circulation* 133: 484–492, 2016
 - 31) Ivascu FA, Howells GA, Junn FS, Bair HA, Bendick PJ, Janczyk RJ: Rapid warfarin reversal in anticoagulated patients with traumatic intracranial hemorrhage reduces hemorrhage progression and mortality. *J Trauma* 59: 1131–1137; discussion 1137–1139, 2005
 - 32) Ansell J, Hirsh J, Poller L, Bussey H, Jacobson A, Hylek E: The pharmacology and management of the vitamin K antagonists: the Seventh ACCP Conference on Antithrombotic and Thrombolytic Therapy. *Chest* 126: 204S–233S, 2004
 - 33) Stein SC, Young GS, Talucci RC, Greenbaum BH, Ross SE: Delayed brain injury after head trauma: significance of coagulopathy. *Neurosurgery* 30: 160–165, 1992
 - 34) Fabbri A, Vandelli A, Servadei F, Marchesini G: Coagulopathy and NICE recommendations for patients with mild head injury. *J Neurol Neurosurg Psychiatry* 75: 1787–1788, 2004
 - 35) Alahmadi H, Vachhrajani S, Cusimano MD: The natural history of brain contusion: an analysis of radiological and clinical progression. *J Neurosurg* 112: 1139–1145, 2010
 - 36) Chang EF, Meeker M, Holland MC: Acute traumatic intraparenchymal hemorrhage: risk factors for progression in the early post-injury period. *Neurosurgery* 58: 647–656; discussion 647–656, 2006
 - 37) Gopinath SP, Robertson CS, Contant CF, Narayan RK, Grossman RG, Chance B: Early detection of delayed traumatic intracranial hematomas using near-infrared spectroscopy. *J Neurosurg* 83: 438–444, 1995
 - 38) Oertel M, Kelly DF, McArthur D, et al.: Progressive hemorrhage after head trauma: predictors and consequences of the evolving injury. *J Neurosurg* 96: 109–116, 2002
 - 39) Narayan RK, Maas AI, Servadei F, Skolnick BE, Tillinger MN, Marshall LF: Traumatic Intracerebral Hemorrhage Study Group: Progression of traumatic intracerebral hemorrhage: a prospective observational study. *J Neurotrauma* 25: 629–639, 2008
 - 40) Wang MC, Linnau KF, Tirschwell DL, Hollingworth W: Utility of repeat head computed tomography after blunt head trauma: a systematic review. *J Trauma* 61: 226–233, 2006
 - 41) Watson HG, Baglin T, Laidlaw SL, Makris M, Preston FE: A comparison of the efficacy and rate of response to oral and intravenous Vitamin K in reversal of over-anticoagulation with warfarin. *Br J Haematol* 115: 145–149, 2001
 - 42) Preston FE, Laidlaw ST, Sampson B, Kitchen S: Rapid reversal of oral anticoagulation with warfarin by a prothrombin complex concentrate (Beriplex): efficacy and safety in 42 patients. *Br J Haematol* 116: 619–624, 2002
 - 43) Yasaka M, Sakata T, Minematsu K, Naritomi H: Correction of INR by prothrombin complex concentrate and vitamin K in patients with warfarin related hemorrhagic complication. *Thromb Res* 108: 25–30, 2002
 - 44) Beynon C, Hertle DN, Unterberg AW, Sakowitz OW: Clinical review: traumatic brain injury in patients receiving antiplatelet medication. *Crit Care* 16: 228, 2012

- 45) McMillian WD, Rogers FB: Management of prehospital antiplatelet and anticoagulant therapy in traumatic head injury: a review. *J Trauma* 66: 942–950, 2009
- 46) Milling TJ, Jr., Refaai MA, Goldstein JN, et al.: Thromboembolic events after vitamin K antagonist reversal with 4-factor prothrombin complex concentrate: exploratory analyses of two randomized, plasma-controlled studies. *Ann Emerg Med* 67: 96–105.e5, 2016
- 47) Milling TJ, Refaai MA, Sarode R, et al.: Safety of a four-factor prothrombin complex concentrate versus plasma for vitamin k antagonist reversal: an integrated analysis of two phase IIIb clinical trials. *Acad Emerg Med* 23: 466–475, 2016
- 48) Lorenz R, Kienast J, Otto U, et al.: Successful emergency reversal of phenprocoumon anticoagulation with prothrombin complex concentrate: a prospective clinical study. *Blood Coagul Fibrinolysis* 18: 565–570, 2007
- 49) Lankiewicz MW, Hays J, Friedman KD, Tinkoff G, Blatt PM: Urgent reversal of warfarin with prothrombin complex concentrate. *J Thromb Haemost* 4: 967–970, 2006
- 50) Pabinger I, Brenner B, Kalina U, Knaub S, Nagy A, Ostermann H: Beriplex P/N Anticoagulation Reversal Study Group: Prothrombin complex concentrate (Beriplex P/N) for emergency anticoagulation reversal: a prospective multinational clinical trial. *J Thromb Haemost* 6: 622–631, 2008
- 51) Stein SC, Spettell C, Young G, Ross SE: Delayed and progressive brain injury in closed-head trauma: radiological demonstration. *Neurosurgery* 32: 25–30; discussion 30–31, 1993
- 52) Grottke O, Levy JH: Prothrombin complex concentrates in trauma and perioperative bleeding. *Anesthesiology* 122: 923–931, 2015
- 53) Zeeshan M, Hamidi M, Kulvatunyou N, et al.: 3-Factor versus 4-Factor PCC in coagulopathy of trauma: four is better than three. *Shock* 52: 23–28, 2019

Corresponding author: Kenji Yagi, MD, PhD

Department of Neurosurgery, Kawasaki Medical School, 577 Matsushima, Kurashiki, Okayama, 701-0192, Japan.

e-mail: kenji-yagi@mail.goo.ne.jp