

Case Report

If AFP is elevated, where is cancer? The case report on hereditary persistence of Alpha-fetoprotein

Hatice SARACOGLU^{1*}, Mevlut BASKOL², Hakan SARACOGLU³, Gulden BASKOL¹

1. Department of Medical Biochemistry, Faculty of Medicine, Erciyes University, Kayseri/Turkey

2. Department of Gastroenterology, Faculty of Medicine, Erciyes University, Kayseri/Turkey

3. Department of Internal Medicine, Faculty of Medicine, Erciyes University, Kayseri/Turkey

*Corresponding author; Hatice SARACOGLU; Email address: hsaracoglu@erciyes.edu.tr

Abstract

Alpha-fetoprotein (AFP) is expressed by tumors with a high mitotic index such as hepatocellular carcinoma and germ cell tumors, therefore it is used as a tumor biomarker. Interestingly, although there is no underlying cause, elevated AFP has been reported in some genetically predisposed individuals. This is a very rare and benign condition called “hereditary persistence of AFP (HPAFP)” and an inherited in an autosomal dominant manner. To our knowledge, only 28 families have been reported to date. Some of the reported cases received inappropriate treatments such as chemotherapy and surgery. The possibility of HPAFP should be kept in mind in patients with high AFP in the absence of radiological evidence of hepatocellular carcinoma or germ cell tumor to avoid harmful procedures. It can be easily confirmed by analyzing AFP levels in other family members. We report a case of HPAFP with surprisingly higher AFP levels than previously reported cases and this is the first case reported from Turkey.

Keywords: Hereditary persistence of alpha-fetoprotein, HPAFP, AFP, Hepatocellular carcinoma

Introduction

Alpha-fetoprotein (AFP) is the main plasma protein produced in the liver and the yolk sac (after 4. weeks) during intrauterine life. It decreases after postpartum 12-16. weeks and remains staying low levels throughout life¹. AFP is thought to be the fetal counterpart of plasma albumin. In the fetus, it has estrogen-binding and immune-protective functions, while in healthy adults it has no known function².

AFP is expressed by tumors with a high mitotic index such as hepatocellular carcinoma and germ cell tumors, therefore it is used as a tumor biomarker. In addition, chronic viral hepatitis with active replication may cause moderate AFP elevation³. Physiologically, AFP is increased in pregnant women and it is used in fetal anomaly screening, especially for neural tube defects⁴.

Interestingly, although there is no underlying cause, elevated AFP has been reported in some genetically predisposed individuals. This is a very rare and benign condition called “hereditary persistence of AFP (HPAFP)” and an inherited in an autosomal dominant manner⁵. To our knowledge, only 28 families have been reported to date, the first in 1983. However, the true incidence of HPAFP is unknown because it is only noticed when there is a reason to evaluate AFP. The diagnosis of HPAFP is supported by the detection of individuals with high AFP levels in other family members and definitively confirmed by molecular analysis of the AFP gene and revealing the mutations⁶. The AFP gene is located in chromosome 4 and is regulated by enhancer, promoter, and silencer factors. Hepatocyte nuclear factor-1 (HNF-1) activates the AFP gene, while non-tissue-specific factor-1 (NF-1) suppresses it. Over-binding of HNF-1 and under binding of NF-1 to the AFP gene as a result of point mutations (the most common single nucleotide

polymorphism, -119G>A, -55C>A, and -65C>T) lead to overexpression of AFP^{2,7}.

We report a case of HPAFP with surprisingly higher AFP levels than previously reported cases and this is the first case reported from Turkey.

Case

A 55-year-old male patient was admitted to the gastroenterology clinic to investigate the etiology due to extremely high AFP levels. In the patient’s medical history, he was diagnosed with renal oncocytoma five years ago, and left partial nephrectomy was performed. He had no known disease other than chronic hepatitis B infection and coronary artery disease. He was on lamivudine, metoprolol, and acetylsalicylic acid treatment. Physical examination findings were normal.

Laboratory results are presented in Table 1. AFP level was 60921 ng/mL, while other laboratory tests were within the reference range. In addition, all other tumor markers were within the reference range. Abdominal ultrasonography (USG), computer tomography (CT), and dynamic magnetic resonance (MR) screenings revealed no malignant lesions except a few hemangiomas in the liver and a few cortical cysts (angiomyolipoma) in both kidneys. Hepatic biopsy showed mild chronic hepatitis without fibrosis. The Ishak fibrosis score was 0/6. Scrotal USG was completely normal and the urology department stated that there was no urological pathology to explain the high AFP. No malignant lesion was found in thorax CT scans. Upper and lower gastrointestinal system evaluations were normal, except for chronic gastritis, and no evidence of malignancy was found in any of the randomized multiple biopsies.

Table 1: Laboratory results of the patient at admission.

Parameters	Results	Units	Reference Range
BUN	28	mg/dL	6-20
Creatinine	0.95	mg/dL	0.5-1.2
Total bilirubin	0.21	mg/dL	0-1.4
Direct bilirubin	0.1	mg/dL	0-0.3
AST	14	U/L	0-40
ALT	9	U/L	0-41
GGT	12	U/L	10-71
LDH	178	U/L	135-250
ALP	45	U/L	40-130
AFP	60921	ng/mL	0-7
CEA	2.59	ng/mL	0-6.5
CA-19-9	7.35	U/mL	0-27
CA-125	7.12	U/mL	0-20
Free beta-HCG	<0.003	U/L	0-2
Total PSA	0.96	ng/mL	0-3.1

BUN: blood urea nitrogen, AST: aspartate transaminase, ALT: alanine aminotransferase, GGT: gamma-glutamyl transferase, LDH: lactate dehydrogenase, ALP: alkaline phosphatase, AFP: alpha-fetoprotein, CEA: carcino-embryonic antigen, CA: carbohydrate antigen, HCG: human chorionic gonadotropin, PSA: prostate specific antigen. Measurements were performed on Cobas c701 and e801 autoanalyzer (Roche Diagnostic).

PET-CT scan did not show any focus of malignancy and/or metastasis. Since no clinical pathology could be detected to explain AFP elevation, the presence of interferences that could cause false high AFP measurement was investigated. No interference was considered in repeated analyzes with serial dilution, polyethylene glycol precipitation, heterophile antibody, and nonspecific antibody blocking tubes. Finally, it was thought that this patient can have HPAFP, and with official consent, other family members were screened for elevated AFP.

AFP levels were 52757 ng/mL in his son (30y), 65902 ng/mL (28y) and 40809 ng/mL (26y) in his daughters. Due to the presence of consanguineous marriage (uncle's daughter), his wife (58y) was also evaluated and her AFP level was 4.09 ng/mL, within the reference range (Figure 1). Family members with elevated AFP levels were evaluated with free beta HCG (human chorionic gonadotropin), AST (aspartate transaminase), ALT (alanine aminotransferase), GGT (gamma-glutamyl transferase), ALP (alkaline phosphatase), total and direct bilirubin levels, and liver USG to rule out an actual AFP elevation, and all were normal. We confirmed that there is "HPAFP" in this family since there is no pathology to explain the high AFP and it conforms to the autosomal dominant inheritance pattern.

Discussion

In a patient with AFP levels above 500 ng/mL, generally three conditions are usually suspected: Hepatocellular carcinoma,

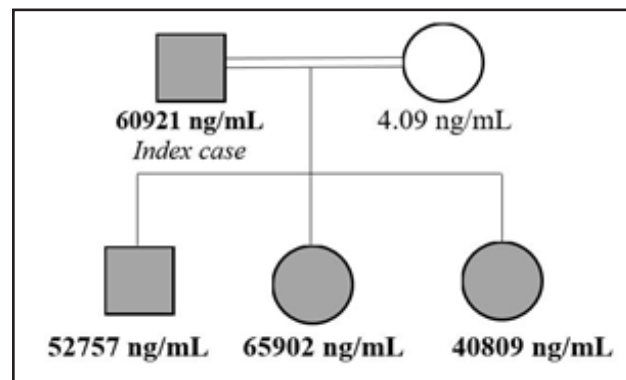


Figure 1: Pedigree chart of HPAFP in family members (Dark color indicates family members with HPAFP and double line indicates the consanguineous marriage).

Table 2: Primary conditions and AFP levels of the HPAFP cases reported to date.

Year / Author	Primary condition	AFP levels (ng/mL)*
1983 Smith	Pregnancy	-
1986 Staples	Hereditary spherocytosis and seminoma	15-25
1990 Greenberg	Testicular cyst	30-46
1993 Tokoro	Idiopathic familial basal ganglia calcification	290
1994 Feng	Check up	21-129
1997 Mal	Tuberculosis	200-800
1998 Schefer	Testicular nodule	20-24
1999 Cochran	Testicular germ cell tumour	61.3-152.9
2001 Flechon	Seminoma testis	31.9-42.5
2001 Flechon	Testicular pain	15
2002 Platini	Seminoma testis	35-43
2003 Blesa	Asthenia	1500-3564
2004 Alj	Pleurisy	1089
2004 Alj	Dorsal pain	218
2004 Yeh	Check up	143
2004 Klümpen	Seminoma testis	20-51
2005 Nagata	Check up	516
2005 Nagata	Check up	1200
2009 Li	Endocrine evaluation	55-88
2010 Chierigo	Check up	20-30
2011 Abt	Acute epididymitis	546-590
2012 Waseda	Testicular germ cell tumour	19-27
2012 Bonfig	Ovarian cyst	13.5-44.9
2013 Rood	Pregnancy	-
2017 Deshpande	Fatty liver and hepatomegaly	1830
2020 Patil	Chronic liver disease (three cases)	854-1475
Current case	Renal oncocyoma and chronic hepatitis B	60921

*In index patient. All values were presented in ng/mL for comparability.

germ cell tumors, and liver metastasis from tumors with a primary origin elsewhere⁸. In our case, AFP levels were always above 50000 ng/mL in repeated measurements, so these three reasons were investigated in detail. We initially suspected hepatocellular carcinoma, since he has a chronic hepatitis B infection. No investigation, including PET CT, has demonstrated the presence of malignancy including hepatocellular carcinoma. Chronic hepatitis B infection alone did not explain the extremely high AFP levels. When clinical reasons and false elevation due to the measurement method were excluded, we suspected a hereditary elevation in our case. Detection of similarly high levels of AFP in family members confirmed this diagnosis. The limitation of our case report is the lack of genetic testing.

HPAFP was first described in 1983 during a prenatal screening program for spina bifida in pregnant women and the inheritance was autosomal dominant⁹. Molecular analyzes revealed that most affected members had mutations in the promoter region of the AFP gene².

Although the AFP levels of HPAFP cases reported to date have been highly variable, the median (25th-75th percentiles) was 85 (31.25-541.5) ng/mL in reported cases (Table 2). This variability was thought to be due to the etiological heterogeneity of HPAFP, except for point mutations in the AFP promoter region². Compared to other cases in the literature, our family has extremely high AFP levels [56839 (43796-64656) ng/mL vs. 85 (31.25-541.5) ng/mL].

Ten of the HPAFP (36%) cases presented with a urological pathology (Table 2). Our case had chronic hepatitis B infection and a history of renal oncocytoma.

It should also be kept in mind that some of the reported cases received inappropriate treatments such as chemotherapy and surgery¹⁰⁻¹⁴. Our case underwent highly detailed investigations in terms of unexplained very high AFP levels, because of the index case in the family and increased risk of hepatocellular carcinoma development due to chronic hepatitis B infection. Fortunately, HPAFP was correctly diagnosed before receiving additional inappropriate surgical/medical treatments.

In addition, two HPAFP cases were detected in pregnant women during prenatal screening (Table 2). AFP levels are evaluated in pregnancy to screen for neural tube defects or Down syndrome⁴. If HPAFP is not recognized in a pregnant woman, it may even result in unnecessary pregnancy terminations.

In conclusion, the possibility of HPAFP should be kept in mind in patients with high AFP in the absence of radiological evidence of hepatocellular carcinoma or germ cell tumor to avoid harmful procedures. Hereditary persistence of AFP can be easily confirmed by analyzing AFP levels in other family members.

Conflict of interest

None declared

Informed consent

Informed consent forms were obtained from all family members for the anonymous publication of medical data.

References

- Adigun OO, Yarrarapu SNS, Khetarpal S. Alpha Fetoprotein. 2022 Aug 8. In: StatPearls [Internet]. Treasure Island (FL): StatPearls Publishing; 2022 Jan-. PMID: 28613501.
- Jeon Y, Choi YS, Jang ES, et al. Persistent α -Fetoprotein Elevation in Healthy Adults and Mutational Analysis of α -Fetoprotein Promoter, Enhancer, and Silencer Regions. *Gut Liver*. 2017;11(1):136-141. doi: 10.5009/gnl16069.
- Patil V, Jothimani D, Narasimhan G, et al. Hereditary Persistence of Alpha-Fetoprotein in Chronic Liver Disease-Confusing Genes! *J Clin Exp Hepatol*. 2021;11(5):616-618. doi: 10.1016/j.jceh.2020.12.008.
- Srinivasan B, Finkelstein JL, Erickson D, et al. Point-of-Care Quantification of Serum Alpha-Fetoprotein for Screening Birth Defects in Resource-Limited Settings: Proof-of-Concept Study. *JMIR Biomed Eng*. 2021;6(1):e23527. doi: 10.2196/23527.
- Lazarevich NL. Molecular mechanisms of alpha-fetoprotein gene expression. *Biochemistry (Mosc)*. 2000 Jan;65(1):117-33. PMID: 10702646.
- Bhatt P, Gupta DK, Agrawal D, et al. Hereditary Persistence of Alpha Fetoprotein in an Indian Family. *Trop Gastroenterol*. 2019; 40(1): 32-5. doi: <http://dx.doi.org/10.7869/tg.522>
- Deshpande N, Chavan R, Bale G, et al. Hereditary Persistence of Alpha-Fetoprotein Is Associated with the -119G>A Polymorphism in AFP Gene. *ACG Case Rep J*. 2017;4:e33. doi: 10.14309/crj.2017.33.
- Bonfig W, Hempel M, Teichert-von Lüttichau I, et al. Avoiding harmful procedures in patients with elevated α -fetoprotein concentrations: hereditary persistence of α -fetoprotein is an important and benign differential diagnosis! *J Pediatr Hematol Oncol*. 2012;34(7):e301-3. doi: 10.1097/MPH.0b013e3182441256.
- Ferguson-Smith MA, May HM, O'Hare E, et al. Hereditary persistence of alphafetoprotein: A new autosomal dominant trait identified in an antenatal screening programme for spina bifida. *J Med Genet*. 1983; 20(6):454-8.
- Schefer H, Mattmann S, Joss RA. Hereditary persistence of alpha-fetoprotein. Case report and review of the literature. *Ann Oncol*. 1998;9(6):667-72. doi: 10.1023/a:1008243311122.
- Cochran PK, Chauvenet AR, Hart PS, et al. Hereditary persistence of alpha-fetoprotein in a child with testicular germ cell tumor. *Med Pediatr Oncol*. 1999;32(6):436-7. doi: 10.1002/(sici)1096-911x(199906)32:6<436::aid-mpo9>3.0.co;2-m. PMID: 10358703.
- Platini C. Hereditary persistence of alpha-fetoprotein: report of a case. *Rev Med Interne*. 2002;23(2):182-8. doi: 10.1016/s0248-8663(01)00534-3.
- Klumpen HJ, Westermann AM. Diagnostic dilemma in a man with seminoma. *Lancet*. 2004;364(9452):2230. doi: [https://doi.org/10.1016/S0140-6736\(04\)17600-9](https://doi.org/10.1016/S0140-6736(04)17600-9).
- Tokoro K, Chiba Y, Ohtani T, et al. Pineal ganglioglioma in a patient with familial basal ganglia calcification and elevated serum alpha-fetoprotein: case report. *Neurosurgery*. 1993;33(3):506-11; discussion 511. doi: 10.1227/00006123-199309000-00023.