



Since January 2020 Elsevier has created a COVID-19 resource centre with free information in English and Mandarin on the novel coronavirus COVID-19. The COVID-19 resource centre is hosted on Elsevier Connect, the company's public news and information website.

Elsevier hereby grants permission to make all its COVID-19-related research that is available on the COVID-19 resource centre - including this research content - immediately available in PubMed Central and other publicly funded repositories, such as the WHO COVID database with rights for unrestricted research re-use and analyses in any form or by any means with acknowledgement of the original source. These permissions are granted for free by Elsevier for as long as the COVID-19 resource centre remains active.

The Senior Ferret (*Mustela Putorius Furo*)

Sharman M. Hoppes, DVM, DABVP-Avian

KEYWORDS

- Ferret • Geriatric • Neoplasia • Adrenal disease
- Lymphoma • Cardiomyopathy

Ferrets are an increasingly popular pet in the United States. They are active, gregarious pets that delight their owners with their playful antics. One of the issues that ferret owners and veterinarians have had to deal with is their shortened life span brought on by multiple disease processes. Although literature cites the life span of the ferret as 8 to 10 years of age, most exotic veterinarians routinely see ferrets as “old” at as early as 3 years of age. The majority of the information on senior ferrets has focused on neoplastic diseases, primarily adrenal tumors and insulinomas. This article discusses husbandry and nutritional issues of the aging ferret along with some of the more commonly seen geriatric diseases, including neoplasia, and the available diagnostics and treatment options.

Ferrets (*Mustela putorius furo*) have become a popular pet in the past decade. They belong to the family, Mustelidae, and are related to mink, martens, badgers, otters, and skunks. In the United Kingdom, ferrets were used for rodent control and hunting rabbits. These practices still occur in Europe but to a lesser degree. In the United States, ferrets have been used in research and as pets. Hunting with ferrets is illegal in the United States and ferrets are considered a companion animal. Most ferret owners are as committed to their ferrets as dog and cat owners are to their pets, and they seek the same veterinary care that others expect for their dogs and cats.

HUSBANDRY

Ferrets of all ages are curious active creatures and should be confined to a large cage or enclosure when not under close supervision, but they should not be caged 24 hours a day. They need time out of the cage for exercise and mental stimulation. Ferrets should be allowed to play in a ferret-proof area for several hours daily, and this time can be divided throughout the day. In their cage, ferrets should have a retreat for sleeping, in the form of a cloth tube, hammock, or tent. Ferrets can be trained to use a litter box—a corner box works well because they like to back up into corners to defecate. Litter boxes should be close and easily accessed, as ferrets have a short

Department of Veterinary Small Animal Sciences, Texas A&M University, College of Veterinary Medicine, 4474 TAMU, College Station, TX 77843-4474, USA
E-mail address: shoppes@cvm.tamu.edu

Vet Clin Exot Anim 13 (2010) 107–122

doi:10.1016/j.cvex.2009.12.002

vetexotic.theclinics.com

1094-9194/10/\$ – see front matter © 2010 Elsevier Inc. All rights reserved.

gastrointestinal transit time and may not make it to a litter box in another room or area of the house.

As ferrets age, some changes in their housing may be required. They may develop vision difficulties or they may not be as agile as they once were. Providing fewer levels for climbing, adjusting ramps so they are easier to climb, placing shelves closer together, and making sure food and water bowls are accessible may be necessary. For some elderly ferrets affected by multiple diseases, a smaller one-story cage may be safer.

Ferrets are predatory hunters and should be monitored closely when housed with other pets, especially other pocket pets, birds, or reptiles. This is true even with older ferrets. They are extremely playful and play hard for hours followed by a long nap. Senior ferrets often play less and sleep more, and with advancing age many ferrets sleep the majority of the day and night.

DIET

Ferrets are strict carnivores. They have a short gastrointestinal tract that empties in 3 to 4 hours. Due to diminished gastrointestinal flora and few brush border enzymes, they do not metabolize carbohydrates well.¹ They also have difficulty digesting fiber. They require diets high in good-quality animal protein and fat with minimal carbohydrates and fiber. Excess carbohydrates may lead to pancreatic disease, such as insulinoma. Treats that are acceptable include pieces of chicken, eggs, and other high-protein snacks. Ferrets develop their dietary preferences in the first few months of age, so it is important that they be started on an appropriate diet early.¹ Changing an adult or older ferret's diet can be challenging. A whole prey diet has been advocated by many authorities and is fed in some areas of the world. In the United States, a good-quality dry ferret or kitten diet is recommended to aid in prevention of dental disease. As ferrets age, a switch to a senior ferret diet should be considered. Several geriatric diets are available. Weight loss, emaciation, and muscle wasting can occur in older ferrets. Long-term anorexia can lead to hepatic lipidosis. More frequent feedings and assisted feedings may be necessary in sick or senior ferrets (**Fig. 1**).

VETERINARY CARE

The literature reports that the life span of ferrets can be up to 10 years of age, but most ferrets in North America live 5 to 7 years, with the onset of many geriatric and

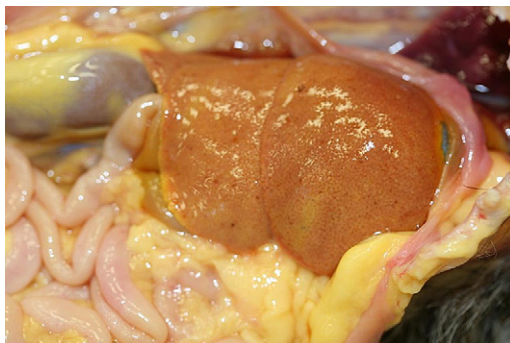

Fig. 1. Ferret with marked, diffuse hepatic lipidosis and icterus of the abdominal adipose. (Courtesy of C.M. Pfent.)

neoplastic diseases seen as early as 3 years of age.² Most exotic veterinarians consider ferrets “senior” at 3 to 4 years of age. At this age it is recommended that ferrets have physical examinations performed twice a year and yearly blood work. Blood work may include complete blood count (CBC), chemistry profile, and possibly an adrenal panel, depending on the age and health of a ferret. With many disease processes, CBC and chemistry profiles may need to be performed more frequently.

FERRET RESTRAINT AND PHYSICAL EXAMINATION

Ferrets of any age are typically easily restrained for physical examination. Most ferrets tolerate gentle restraint on a table. If a ferret is difficult to restrain or fractious, scruffing a ferret at the back of its neck and suspending it off the table results in relaxation and allows for physical examination.³

VENIPUNCTURE

Venipuncture sites for ferrets include the jugular vein, cranial vena cava, and cephalic and lateral saphenous. Many ferrets can be restrained for venipuncture without sedation or anesthesia. For jugular venipuncture, the technique used in cats, with head tilted back and forelegs pulled forward over the edge of a table, works well. The jugular vein in ferrets is slightly more lateral than in cats or dogs. For the cranial vena cava approach, a ferret is held on its back with its front legs pulled caudally and the head and neck extended. A 25-gauge needle is inserted into the thoracic cavity between the manubrium and first rib at a 45° angle, pointing the needle toward the opposite rear leg. The needle is inserted to its hub, then slowly withdrawn while gently applying suction until blood begins to fill the syringe. For difficult or fractious ferrets, the author routinely masks them down with isoflurane or sevoflurane briefly to obtain the sample. Isoflurane anesthesia can reduce the hematocrit level, red blood cell count, and hemoglobin concentrations so be sure to note that the sample is taken with the ferret under anesthesia in the evaluation of the blood sample.⁴

PREVENTIVE CARE

Preventive medicine for older ferrets includes yearly to twice-a-year physical examinations, distemper and rabies vaccination, monthly heartworm preventative, and dental prophylaxis. Ferrets of all ages are susceptible to canine distemper, which is a fatal disease in ferrets. PureVax (Merial, Athens, Georgia) is the distemper vaccine recommended for ferrets.⁵ Vaccination for rabies is also recommended and required in some states. The Imrab 3 (Merial, Athens, GA, USA) killed vaccine is approved for use in ferrets.⁶

Ferrets are susceptible to vaccine reactions.⁷ Mild reactions may include pruritis or weakness. More severe reactions include vomiting, diarrhea, hyperthermia, or, rarely, death. The author routinely premedicates ferrets with diphenhydramine (2 mg/kg subcutaneously 20 minutes before vaccination) and then monitors ferrets for a minimum of 30 minutes post vaccination. In older ferrets with multiple diseases present and any history of vaccine reaction, it is important to weigh the benefits and risks of vaccination.

Vaccine injection-site sarcomas have also been documented in ferrets, although no particular vaccine was identified as the culprit.⁸ Implementing the vaccine protocols used in cats may be prudent.

Ferrets are susceptible to heartworm disease and should be on a monthly preventative in endemic areas. Recommended monthly preventatives include selamectin,

applied topically (6 mg/kg); ivermectin (0.05 mg/kg by mouth or subcutaneously); or milbemycin oxime (1.15 to 2.33 mg/kg by mouth).⁹

COMMON GERIATRIC DISEASES

Ferrets are well known for the development of several geriatric disorders. They have a high incidence of tumors, with neoplasia often the cause of or a contributing factor to death in geriatric ferrets. Gastrointestinal disease, dental disease, cardiomyopathy, renal disease, and cataracts are other common diseases in senior ferrets.

GASTROINTESTINAL DISEASE

Gastrointestinal disease occurs commonly in older ferrets, with trichobezoars, gastric ulcers, epizootic catarrhal enteritis, and inflammatory bowel disease the most commonly reported causes.^{10,11}

Although foreign bodies are the most common cause of gastrointestinal obstruction in young ferrets, in older ferrets trichobezoars are a more common cause.¹² Clinical signs of obstruction include anorexia, lethargy, hypersalivation, and pain on abdominal palpation. Vomiting occurs infrequently in ferrets but if present is supportive of obstructive disease. Weight loss can be significant if the obstruction is chronic. Abdominal radiographs may reveal a fluid- or gas-filled stomach and a gas pattern in the intestinal tract. The trichobezoar may or may not be radiographically evident. Medical therapy includes fluid therapy and laxation, but in many cases surgery is necessary.

Gastric ulcers can occur in young and old ferrets. Gastrointestinal ulcers are often secondary to other disease processes, such as gastrointestinal neoplasia, foreign body, drug therapy, renal disease, or *Helicobacter mustelae* infection.^{10,11} Clinical signs of gastric ulcers include lethargy, ptyalism, diarrhea, teeth grinding, melena, and pain on abdominal palpation. A presumptive diagnosis can be reached through the use of diagnostics, including radiographs, CBC and biochemical profile, biopsy, or response to treatment. CBC may reveal a mild to moderate regenerative anemia. A definitive diagnosis can be reached with endoscopy. *H. mustelae* infections can be difficult to diagnose as it is believed that most ferrets are infected, so presence of the organism is not definitive for disease. Treatment options include treating any underlying disease in conjunction with treatment of the gastric ulcers. For treatment of gastric ulcers, a combination of amoxicillin (20 mg/kg by mouth every 12 h) and metronidazole (20 mg/kg by mouth every 12 h) is recommended along with systemic H₂-receptor antagonists: ranitidine (24 mg/kg every 8 h), famotidine (0.5 mg/kg by mouth every 24 h), or cimetidine (10 mg/kg every 8 h).^{9,10} Depending on the severity of the disease, supportive care may be necessary.

Epizootic catarrhal enteritis is a highly contagious disease caused by a coronavirus that can spread rapidly through a collection of ferrets.^{10,11} The history often includes the addition of a young ferret to a home with older ferrets. The young ferret is often clinically normal, but the older ferrets in the home develop symptoms within a few days. Clinical signs include depression, lethargy, watery green diarrhea, melena, dehydration, and weight loss. Diagnostics include CBC, biochemical profile, and radiographs. CBC may reveal a leukocytosis, a monocytosis, and a mild to severe anemia. Serum urea nitrogen, alanine aminotransferase (ALT), and alkaline phosphatase may be elevated. Radiographs may reveal ileus. Supportive care includes aggressive fluid therapy, antibiotics, and nutritional support. All affected ferrets should be isolated.

Inflammatory bowel disease is common in older ferrets.¹³ This disease is typically multifactorial in ferrets. A chronic form of coronavirus (epizootic catarrhal enteritis) has been reported as a causative agent, as has *H mustelae* infection. Other suspected causes include dietary intolerance or hypersensitivity. A history of previous illness with epizootic catarrhal enteritis, along with chronic loose birdseed-like stools, may aid in the diagnosis of inflammatory bowel disease, but full-thickness gastric and intestinal biopsies are necessary for a definitive diagnosis.¹⁰ Histopathology may reveal a lymphoplasmacytic or eosinophilic inflammation. Treatments include dietary management often with a hypoallergenic diet, prednisone (1 mg/kg by mouth every 12 h), or azathioprine (0.9 mg/kg by mouth every 24 to 72 h).⁹

A recent study performed at Texas A&M University revealed that ferrets, similarly to cats, have diminished cobalamin levels when afflicted with chronic diarrhea.¹⁴ This study revealed that ferrets with chronic diarrhea have significantly decreased serum concentrations of cobalamin, and significantly increased serum concentrations of methylmalonic acid. These findings suggest that cobalamin malabsorption is common in ferrets with chronic diarrhea and that it can be severe enough to cause increases in serum methylmalonic acid concentrations indicating tissue depletion of cobalamin. Although only a few ferrets have been followed after cobalamin therapy, the preliminary results suggest that cobalamin therapy is helpful in treatment of chronic diarrhea in ferrets.¹⁴ The author's current recommendations are extrapolated from cobalamin therapy in cats: cobalamin (250 µg subcutaneously per ferret weekly for 6 weeks, then 250 µg every 2 weeks for 6 weeks, then monthly). Cobalamin levels should be re-evaluated 1 month after the last administration. Monthly injections may be necessary in chronic intestinal disease.¹⁴

NEOPLASIA

Adrenal tumors are one of the most common endocrine tumors in domestic ferrets.¹⁵ Middle-aged to older ferrets are affected most often. The cause of adrenal tumors in ferrets is unknown; many theories have been considered. Early neutering has been implicated as have husbandry and nutrition issues. In the United States, ferrets are neutered at a few weeks of age, are housed indoors, and are on formulated diets. European ferrets are neutered later, often housed outdoors, and are fed a whole prey diet. A recent article revealed that when ferrets are neutered at a later age in Europe they too develop adrenal disease, indicating that it does not appear to be the age of neutering but the act of neutering that results in disease.¹⁶

In contrast to canine and human adrenal disease (Cushing disease), serum cortisol levels are not elevated.¹⁷ In ferrets, one or more of the plasma hormones are elevated: estradiol, 17-hydroxyprogesterone, or androstenedione. These elevations can occur with adrenal cortical hyperplasia, adenoma, or adenocarcinoma.¹⁷

Bilateral progressive alopecia, often accompanied by pruritus, is the most commonly reported clinical sign. Hair loss occurs in both genders and typically progresses from the tail forward to the shoulders and neck. Female ferrets may have an enlarged vulva and male ferrets an enlarged prostate.¹⁵ Male ferrets may present with stranguria secondary to prostatic hyperplasia or prostatic cysts. Severe prostaticomegaly can lead to urinary obstruction and result in acute renal failure.¹⁸ Affected male ferrets may also exhibit aggression.

If significantly enlarged, the adrenal gland may be palpable. The left adrenal is located in a large fat pad cranial to the left kidney. The right adrenal is cranial to the right kidney and beneath a lobe of the liver, making it more difficult to palpate even if enlarged (**Fig. 2**).

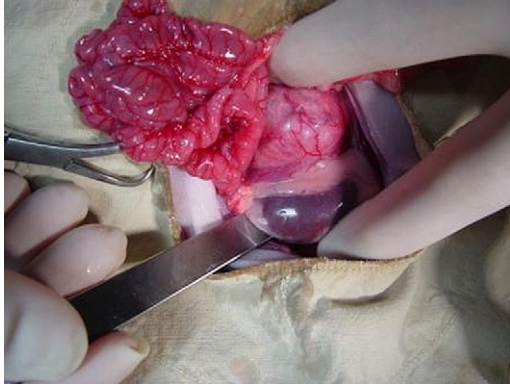


Fig. 2. Grossly enlarged left adrenal gland in a ferret.

A presumptive diagnosis of adrenal cortical tumors in domestic ferrets can be reached based on history and clinical signs. CBC values are usually within normal limits. Occasionally, an anemia may be present, and in severe cases a pancytopenia similar to that seen as a result of estrogen toxicity may be seen. A packed cell volume of less than 15% is associated with a grave prognosis. The serum chemistry profile is usually within normal limits, although ALT may be elevated. Radiographs can be helpful in reaching a presumptive diagnosis if an adrenal tumor is large enough to be visible or if there is displacement of other organs. Ultrasound can be used to determine the size and extent of tumors in association with other structures, such as the liver or caudal vena cava.¹⁷

The dexamethasone suppression test and adrenocorticotropic hormone stimulation test are not useful as cortisol levels are not elevated.¹⁷ A definitive diagnosis of adrenal cortical tumors can be reached by measuring plasma hormone levels or histopathology. A hormone plasma steroid panel measuring estradiol, 17-hydroxyprogesterone, or androstenedione is offered by the University of Tennessee.¹⁹

Treatment includes medical and surgical options. Surgery consists of adrenalectomy and may be preferred if a ferret is in otherwise good health.¹⁵ CBC, chemistry profile, radiographs, and ultrasound should be performed before surgery. A thorough abdominal exploratory should be performed with evaluation of both adrenal glands and excision of the affected gland. If both adrenal glands are affected, bilateral adrenalectomy is recommended. The right adrenal gland is adjacent to the caudal vena cava and when enlarged may invade the vena cava. Because of this close proximity or invasion into the caudal vena cava, complete excision of the right adrenal gland is often not possible. Reoccurrence may take place in the remaining adrenal gland or in any residual tissue left after a right adrenalectomy.¹⁸ Male ferrets with prostatomegaly or prostatic cysts should have the prostatic cysts drained and marsupialized.¹⁷ Whenever surgery is performed on a ferret, evaluation of the gastrointestinal tract, spleen, lymph nodes, kidney, and pancreas should be included.

The medical approach is often chosen in older ferrets with concurrent diseases or ferrets that are poor anesthetic and surgical candidates. Drugs commonly used in the treatment of adrenal tumors of ferrets include leuprolide, anastrozole, and melatonin. Less commonly used drugs include flutamide and bicalutamide.

Leuprolide acetate (Lupron) is a gonadotropin-releasing hormone analog (GnRH) and is one of the most widely used drugs for adrenal tumors in ferrets.²⁰ Although Lupron aids in the reduction of clinical signs, there is usually not a reduction in the size of

the affected adrenal gland. In studies on Lupron and its effects on ferrets with adrenal tumors, Lupron eliminated the clinical signs and reduced the concentrations of the affected sex hormones.²⁰ The recommended dosage is 100 to 500 $\mu\text{g}/\text{kg}$ intramuscularly or subcutaneously every 3 to 8 weeks. Dosage and interval vary depending on individuals. Most ferrets need to be treated for the rest of their lives.

Melatonin implants have been successful in stimulating hair growth. Melatonin has been used for years to stimulate molt and winter coat growth in farmed minks. The exact mechanism of action is unknown. It is thought to aid in regulation of GnRH secretion through specific receptors in the pituitary and hypothalamus, negatively affecting GnRH secretion, decreasing LH and FSH, and ultimately reducing sex hormones. Studies have revealed reduction of plasma steroids, dramatic regrowth of hair, and reduction of vulvar swelling or prostatic size.²¹

Other drugs that have been used to treat adrenal disease in ferrets include anastrozole (Arimidex), an aromatase inhibitor that lowers estrogen by converting adrenal-generated androstenedione to estrone by aromatase in peripheral tissues²²; flutamide (Eulexin), which inhibits androgen uptake and binding in target tissues¹⁵; and bicalutamide (Casodex), which competitively inhibits the action of androgens at the receptor site.²² Flutamide and bicalutamide have been used in ferrets to reduce the size of prostatic tissue and diminish clinical signs of adrenal disease.^{15,22}

INSULINOMA

Pancreatic islet cell tumors are one of the most common tumors in middle-aged and older ferrets. Beta cell tumors or insulinomas are the most frequently diagnosed islet cell tumor in ferrets.^{23,24} Reported age for ferrets with insulinoma ranges from 2 to 7 years with an average of 5 years.²⁵ Pancreatic islet cell tumors produce insulin, resulting in increased insulin secretion and subsequent hypoglycemia. Male and female ferrets are affected.

The history may include a ferret that is “sleeping more.” Clinical signs may vary immensely, from asymptomatic ferrets with hypoglycemia detected on routine hematology to ferrets presenting with weakness, ataxia, posterior paresis, hypersalivation, and seizing (**Fig. 3**).

Diagnosis is based on a documented hypoglycemia. A blood glucose level of less than 60 mg/dL is diagnostic. History and clinical signs are usually supportive of the diagnosis.¹⁵ Hematology and chemistry profiles are often unremarkable as are radiographs. Ultrasound may pick up large pancreatic nodules but often small discrete insulinomas are undetectable (**Fig. 4**).

Treatment options include surgical excision and medical management.¹⁵ Medical management may reduce clinical signs of disease but does not stop progression of the tumor. Dietary recommendations include a meat-based, high-protein ferret or



Fig. 3. Hindlimb paresis in a geriatric ferret with insulinoma. (Courtesy of C.M. Pfent.)

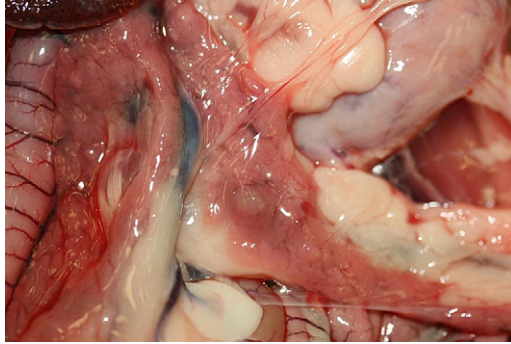


Fig. 4. Pancreatic islet cell adenomas (insulinomas) are often multiple and less than 2 mm in size. This 6-mm insulinoma is easier to identify at surgery or necropsy. (Courtesy of C.M. Pfent.)

cat food with high-protein treats, such as chicken, egg, or chicken- or liver-flavored feline treats. High-sugar or high-carbohydrate treats should be avoided. Food should be available at all times. Severely affected ferrets may require additional feedings at night to avoid a hypoglycemic crisis. Owners should be instructed on identifying early signs of hypoglycemia and to have honey or corn syrup available for an acute crisis.

Drug therapy includes prednisone or prednisolone and diazoxide used singly or in combination. Prednisone or prednisolone increases peripheral blood glucose concentrations by inhibiting glucose uptake by peripheral tissues and increasing hepatic gluconeogenesis. Dosage may range from 0.25 mg/kg to 2 mg/kg every 12 hours.⁹ Many ferrets can be managed medically with prednisone alone at least initially. With progression of the disease, increasing doses of prednisone are needed. Diazoxide is a benzothiadiazide diuretic that inhibits release of insulin from the beta cells, promotes gluconeogenesis, and decreases cellular uptake of glucose. Diazoxide should be added to the medical protocol when prednisone alone is no longer effective. The dosage for diazoxide is 10 to 30 mg/kg every 12 hours, beginning at the low end of the range and increasing the dose as needed.⁹ Often the dose of prednisone can be reduced with the addition of diazoxide. Diazoxide is expensive and cost prohibitive for some owners.

Surgical therapy is the treatment of choice but is often not curative. One study reported 53% of ferrets still required medical management for hypoglycemia after surgery.²⁶ Surgery involves excision of all pancreatic nodules, if possible, or partial pancreatectomy, if indicated. Although most ferrets need medical therapy if not immediately then within months of surgery, it has been shown that ferrets with surgery have a longer survival time than those on medical therapy alone.²⁵ Another benefit to surgery is that even if medical therapy is required postoperatively, it is usually at a much reduced dosage. Blood glucose should be monitored 7 to 14 days postoperatively and then every 2 to 3 months. Prognosis for insulinoma is dependent on severity of disease, with reports of mean survival times of 668 days after surgery.²⁶ The age of a ferret and concurrent diseases can affect prognosis.

LYMPHOMA

The term, *lymphoma* or *lymphosarcoma*, refers to the invasion of any organ or lymph node with atypical lymphocytes. Lymphoma and lymphosarcoma are both used to describe malignant disease. Lymphoma is one of the most common neoplastic

diseases in ferrets. It has been described in all ages and can affect most organs. It primarily affects the lymph nodes, mediastinal lymphatic tissue, and intestines. A viral etiology has been proposed but has not been validated.^{27,28}

Lymphoma in ferrets is often broken down into two distinct syndromes: a juvenile form and an adult-onset form.²⁹ The juvenile form occurs in ferrets less than 2 years of age. The most common presentation is acute respiratory distress due to the presence of a cranial mediastinal mass. This is known as lymphoblastic lymphoma.

The adult form is seen in ferrets more than 3 years of age. Lymphadenopathy is often present. This is often termed *lymphocytic lymphoma*. This disease has a slower progression and more chronic pattern than the juvenile form.^{18,29} Clinical signs vary according to organ system affected and include weakness, dyspnea, depression, anorexia, weight loss, diarrhea, and maldigestion.

Physical examination may reveal a weakened, thin, or emaciated ferret. There may be a peripheral lymphadenopathy. Hepatomegaly, splenomegaly, and thickened intestines may be palpable.

Diagnostics include a CBC, chemistry profile, radiographs, and ultrasound. Hematology may reveal a leukocytosis or leukopenia with or without a lymphocytosis. There may be elevations in liver or kidney enzymes reflecting organ involvement. Radiographs may reveal hepatomegaly, splenomegaly, mediastinal masses, or other masses in the thorax or abdomen. Ultrasound and ultrasound-guided fine-needle aspirates or biopsies with cytology or histopathology may be necessary for a definitive diagnosis.³⁰ Biopsy of a popliteal lymph node is recommended if there is a generalized peripheral lymphadenopathy. CT can aid in determining the presence of tumors. CT can provide excellent contrast between tissue types. The density of the mass can be compared with normal tissue to aid in determining size and invasiveness.¹⁸ MRI is recommended if there is a suspicion of a tumor of the brain or spinal chord.¹⁸

In other species, a staging scheme has been developed to aid in determining proper treatment and prognosis. A classification scheme used in dogs has been accepted for ferrets.¹⁸

Stage 1: single site involvement (lymph node or other single site)

Stage 2: two or more noncontiguous sites on same side of diaphragm

Stage 3: multiple lymphatic sites on both sides of diaphragm (spleen, lymph node)

Stage 4: multiple sites on both sides of diaphragm, including nonlymphatic tissue or bone marrow involvement.

There are many treatment options for lymphoma available for several species. Several have been described in ferrets.¹⁸ These chemotherapeutic protocols have been modified from canine and feline medicine.¹⁸ Available treatment options often do not cure but only result in temporary remission. Surgery may be indicated for excision of tumors or affected organs. Chemotherapy includes treatment with prednisolone alone, which may result in rapid although temporary remission, to more aggressive chemotherapeutic protocols.

Many of the multimodal chemotherapeutic therapies involve frequent hospital visits, potentially caustic intravenous drugs and significant cost. The use of venous access ports is recommended to aid in the administration of frequent intravenous therapies.¹⁸ Radiation treatment is also an available option for drug-resistant lymphomas or owners who do not feel comfortable with chemotherapy. Treatment goals should be discussed with the owner. Slowing down tumor growth, thereby extending or improving the quality of a ferret's life versus providing an actual cure, may be a realistic goal in most cases.

OTHER TUMORS

Other tumors that have been documented in ferrets include pancreatic adenocarcinoma, chordoma, chondrosarcoma, osteoma, thymoma, and hemangiosarcoma, which occurs most commonly in the liver and spleen. Hepatocellular and biliary adenocarcinomas and adenomas have also been reported.^{23,24,29}

Ferrets have several types of cutaneous neoplasms, including basal cell tumors and mast cell tumors; both are usually benign and surgical excision is curative.²⁹

CARDIOMYOPATHY

Cardiac disease is common in older ferrets.^{31,32} Dilated and hypertrophic cardiomyopathy, valvular disease, and heartworm disease have all been documented. Dilated cardiomyopathy is the most common form of heart disease in domestic ferrets.³¹ The cause of dilated cardiomyopathy in ferrets is unknown. The cause in cats has been linked to a deficiency in taurine, and in dogs there is a genetic component, but the effect of diet or genetics in ferrets is undetermined. Hypertrophic cardiomyopathy also occurs but not as commonly. It is important to distinguish between the two disease processes for proper treatment.

Dilated cardiomyopathy usually occurs in ferrets over 3 years of age.³¹ There is no sex predilection. The clinical signs include lethargy, weight loss, anorexia, coughing, distended abdomen, and exercise intolerance.³¹ Cardiac disease is often not diagnosed early in older ferrets because owners often attribute the lethargy or “sleeping a lot” to age.

Left-sided heart murmurs may be auscultated, and often a tachycardia (350 to 400 bpm) is present.^{31,32} Biochemical and hematologic parameters are often normal. Electrocardiographically, there may not be changes. Sinus tachycardia and ventricular and atrial premature complexes may be detected. Radiographically, an enlarged globoid heart may be noted, and this could be indicative of actual cardiac enlargement or pericardial effusion.³³ An elevated trachea or increased sternal contact of the heart may be seen. Other radiographic signs include ascites, hepatomegaly, splenomegaly, or pulmonary edema.³³

Ultrasound is necessary for definitive diagnosis. Ultrasound distinguishes between hypertrophic and dilated cardiomyopathy, pleural and pericardial effusion, and heartworm disease and thoracic masses.³³ Definitive diagnosis is critical for therapy.

Treatment for heart disease in ferrets is similar to treatment in dogs and cats. Oxygen therapy should be initiated in dyspneic ferrets. Furosemide is given initially at 2.2 mg/kg every 8 to 12 hours. With dilated cardiomyopathy, digoxin (0.01 mg/kg every 24 h) may be initiated. Enalapril (0.25 to 0.5 mg/kg every 48 h) or captopril (one-eighth of a 12.5-mg tablet by mouth every 48 h) may be added if no renal disease is present. Nitroglycerin ointment may be used on initial presentation as a vasodilator by applying one-eighth of an inch strip to the inner pinna every 12 to 24 hours.^{31,33} Pimobendan may be used (0.5 mg/kg by mouth every 12 h) for dilated cardiomyopathy or valvular disease.³³

Hypertrophic cardiomyopathy is rarer but does occur.³³ Oxygen therapy may be warranted along with diuretics, such as furosemide; β -blockers, such as atenolol (3 to 6 mg by mouth every 24 h); or a calcium channel blocker, such as diltiazem (1.75 to 7.5 mg by mouth every 12 h).³³

Ferrets are susceptible to heartworm disease and this should be considered when clinical signs of heart disease are present in endemic areas. Heartworm disease in ferrets produces low numbers of microfilaria and, therefore, microfilarial testing can be unrewarding. ELISA-based antigen tests may be effective but with low worm

burdens false-negative results may occur.³¹ Ultrasound is often the best diagnostic tool allowing visualization of the worms.³⁴ There are few treatment options available for heartworm disease in ferrets. Ultrasound-guided retrieval of heartworms has been performed successfully at Texas A&M University. Treatments include steroids to reduce inflammation, ivermectin therapy, and cage rest. Ferrets in endemic areas should be on heartworm preventative.

RENAL DISEASE

Clinical illness due to renal disease is somewhat rare in ferrets, yet renal pathology is often seen on necropsy of older ferrets.^{35,36} Many ferrets over the age of 4 years have varying degrees of chronic interstitial nephritis on necropsy. Early lesions may be seen in ferrets as young as 2 years of age. The disease is often progressive with pathologic changes that may or may not lead to renal failure, and the cause of death is infrequently related to kidney disease.^{37,38} The most commonly reported pathologic changes in the kidneys of ferrets include interstitial nephritis and renal cysts.^{35,36} Other causes of renal pathology include Aleutian mink disease, toxins, urolithiasis, and neoplasia (**Fig. 5**).^{18,36}

Renal cysts are common in ferrets, although their etiology is unknown. Most renal cysts are not a cause of renal disease and are an incidental finding during ultrasound examination, at surgery, or on necropsy (**Fig. 6**).^{38,39}

Aleutian mink disease is a parvovirus that often presents as a chronic wasting disease in ferrets. It can occur in ferrets of any age. Clinical signs include weight loss, depression, posterior paresis, and anemia. The disease results in a marked inflammatory response that can eventually lead to glomerulonephritis and marked interstitial nephritis, which results in renal failure and death.^{39,40}

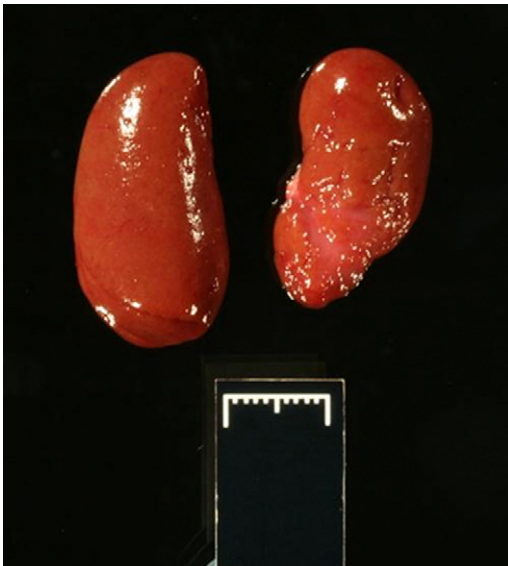

Fig. 5. Chronic interstitial nephritis is a common finding in older ferrets but is rarely problematic clinically. (Courtesy of C.M. Pfent.)

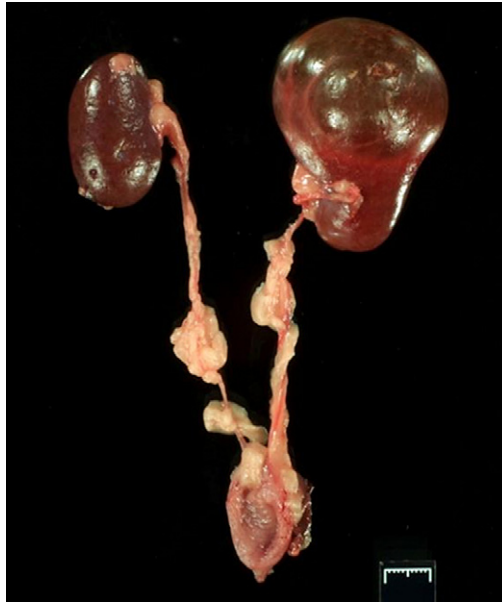


Fig. 6. Renal cysts in ferrets can range from 1 mm to several centimeters in size. Veterinarians should use caution not to mistake large benign renal cysts for hydronephrosis on ultrasound or by other imaging tools. (Courtesy of C.M. Pfent.)

Several toxicoses have been reported in ferrets, including zinc, copper, and ibuprofen. Ferrets of all ages should be monitored closely when not confined to their cages to avoid potential ingestion of toxins.^{41–45}

Urolithiasis has been reported, but the incidence is reduced with the development of improved diets in ferrets.³⁷

Clinical signs of renal disease in ferrets are similar to other companion animals and include depression, lethargy, weakness, posterior paresis, anorexia, weight loss, muscle wasting, and polyuria/polydipsia. Physical examination may reveal emaciation, dehydration, pale mucous membranes, and irregularly shaped kidneys.³⁸

Initial diagnostics include a CBC, biochemical profile, and urinalysis. The biochemical profile may reveal hyperphosphatemia and elevated serum urea nitrogen. The creatinine in ferrets does not elevate markedly in renal disease.³⁵ In ferrets a creatinine of 2 mg/dL is significant. Other blood parameters that may be affected include an elevation in plasma proteins and a nonregenerative anemia. With plasma protein elevations, a protein electrophoresis or Aleutian disease testing should be submitted. Isosthenuria may be present on the urinalysis.³⁸

Additional diagnostics include radiographs and ultrasound. Radiographs may reveal changes in kidney size or shape. Ultrasound can confirm changes and determine if renal architecture is normal. Ultrasound-guided biopsies or fine-needle aspirates may aid in reaching a definitive diagnosis.

Treatment in ferrets is similar to that of other mammals with renal disease. Fluid therapy can be administered intravenously in acute disease or subcutaneously by the owners at home in chronic cases. Antibiotics are included if infection is present, and phosphorus binders can be administered if indicated. Erythropoietin may aid in resolving nonregenerative anemia. The dosage for erythropoietin is 50 to 150 International Units subcutaneously 3 times a week until a desired packed cell volume is

reached, then weekly.⁹ Dietary changes can be challenging because ferrets are strict carnivores and require a high-protein diet.

DENTAL DISEASE

Dental calculi and fractured canines are the most common dental diseases in older ferrets.¹¹ A dry diet may decrease the incidence of calculi formation, which can lead to the development of gingivitis.^{11,12} Yearly dental prophylaxis should be performed in older ferrets. Owners should be encouraged to provide dental care at home, including brushing teeth (**Fig. 7**).¹²

CATARACTS

Cataracts are the most common ophthalmic condition in ferrets. The cause is unknown, although genetics and dietary factors have been discussed as potential etiologies.³² They can occasionally occur in young ferrets but more commonly occur in older ferrets. Because they progress slowly, ferrets adapt to diminished vision and owners may not readily notice anything and may even believe that acute blindness has occurred after a sudden change in a ferret's environment. Ferrets adapt well to cataract-induced blindness and manage well in home environments. Cataract surgery is an option, and phacoemulsification and extracapsular extraction have been performed successfully.⁴⁶

SPLENOMEGALY

Splenomegaly is a common finding in older ferrets. There are several potential causes of splenomegaly, including neoplasia, hypersplenism, heart disease, and extramedullary hematopoiesis, the latter being the most common cause of splenomegaly in ferrets.³¹ With extramedullary hematopoiesis, the spleen appears large but smooth in texture. Splenomegaly associated with lymphoma or other neoplastic processes is often nodular and white or tan nodules may be present.⁴⁷ Splenomegaly is often an incidental finding on physical examination, during ultrasound, or at surgery or necropsy. Often the spleen is large and easily palpated. If pathology is suspected, ultrasound-guided aspiration or aspiration through the abdominal wall can be performed relatively safely. Splenectomy should not be performed unless there is

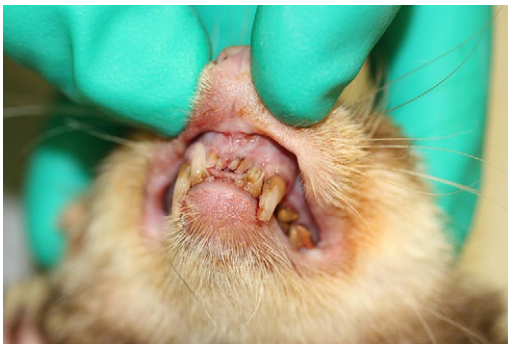


Fig. 7. Dental disease is common in geriatric ferrets. In this ferret, incisors 101, 201, 301, 302, 401, and 402 are missing and the canines 204 and 304 are fractured. The remaining teeth are covered with dental calculi. (Courtesy of C.M. Pfent.)



Fig. 8. The cross-section of a normal spleen is compared with markedly enlarged spleen diagnosed with extramedullary hematopoiesis. (Courtesy of J.F. Edwards and C.M. Pfent.)

documented pathology or the spleen has become so large it is impairing mobility of a ferret (**Fig. 8**).⁴⁷

DEALING WITH LOSS

The emotional bond of owners to their ferrets is strong, similar to the bond owners develop with their dogs and cats. Clients have often spent many hours caring for their elderly pet, strengthening this bond even further. This can make euthanasia a difficult decision for owners. Determining when the time is right to euthanize can be challenging. Discussing the quality of life of ferrets is important in helping owners determine if that time has come. Is the pet able to get around on its own? Is it eating? Is the pet playful or able to enjoy interactions with the client? Are there more good days than bad? Often owners ask if it is better to allow a pet to die at home or be humanely euthanized. If the animal is not in pain or suffering and has an adequate quality of life, keeping the pet home and allowing it to die of “old age” may be an option. But often these animals have debilitating disease and may have multiple diseases present that are uncomfortable if not painful to the animal. It is veterinarians’ responsibility to discuss with clients the option of euthanasia as an alternative to days or weeks of suffering. Euthanasia can be a painless, gentle end to a long, happy life for many pets. Owners can be allowed to be present with their pet. Pre-sedation may be necessary in some pets, and placement of an intravenous catheter reduces stress for the client and the pet. If euthanasia is chosen, offering burial or cremation services is often appreciated by grieving owners, as are remembrance items, such as clay paws and locks of hair.

REFERENCES

1. Bell JA. Ferret nutrition. *Vet Clin North Am Exotic Anim Pract* 1999;2:169–92.
2. Brown S. Basic anatomy, physiology, and husbandry. In: Quesenberry KE, Carpenter JW, editors. *Ferrets, rabbits and rodents: clinical medicine and surgery*. 2nd edition. Philadelphia: WD Saunders; 2003. p. 2–12.
3. Quesenberry KE, Orcutt C. Basic approach to veterinary care. In: Quesenberry KE, Carpenter JW, editors. *Ferrets, rabbits and rodents: clinical medicine and surgery*. 2nd edition. Philadelphia: WD Saunders; 2003. p. 13–23.
4. Marini RP, Jackson LR, Esteves MI, et al. Effect of isoflurane on hematologic variables in ferrets. *Am J Vet Res* 1994;55:1479–83.

5. Tanner PA, Tseggai T, Rice Conlon JA, et al. Minimum protective dose (MPD) and efficacy determination of a recombinant canine distemper virus vaccine in ferrets. In: Proceedings of 81st Annual Meeting of the Conference of Research Workers in Animal Diseases. Chicago, November 12–14, 2000. Abstract 156.
6. Rupprecht CE, Gilbert J, Pitts R, et al. Evaluation of an inactivated rabies vaccine in domestic ferrets. *J Am Vet Med Assoc* 1990;196:1614–6.
7. Meyer EK. Vaccine associated adverse events. *Vet Clin North Am Small Anim Pract* 2001;31:494–514.
8. Munday JS, Stedman N, Richey LJ. Histology and immunochemistry of seven ferret vaccination-site fibrosarcomas. *Vet Pathol* 2003;40:288–93.
9. Carpenter JW, Mashima TY, Rupiper DJ. Exotic animal formulary. 2nd edition. Philadelphia: WB Saunders; 2001.
10. Jenkins J. Gastrointestinal diseases. In: Quesenberry KE, Carpenter JW, editors. Ferrets, rabbits and rodents: clinical medicine and surgery. 2nd edition. Philadelphia: WD Saunders; 2003. p. 161–71.
11. Fox JG. Diseases of the gastrointestinal system. In: Fox JG, editor. Biology and diseases of the ferret. Baltimore (MD): Williams & Wilkins; 1998. p. 273–90.
12. Mullen HS, Scavelli TD, Quesenberry KE, et al. Gastrointestinal foreign body in ferrets: 25 cases (1986–1990). *J Am Anim Hosp Assoc* 1989;28:13–9.
13. Burgess M, Garner M. Clinical aspects of inflammatory bowel disease in ferrets. *Exotic DVM* 2002;4(2):29–34.
14. Hoppes S, Xenoulis PG, Berghoff N, et al. Serum cobalamin, folate, and methylmalonic acid concentrations in ferrets (*Mustela putorius*). In: Proceedings of Assoc of Exotic Mammal Veterinarians 2008.
15. Quesenberry KE, Rosenthal KL. Ferrets: endocrine diseases. In: Quesenberry KE, Carpenter JW, editors. Ferrets, rabbits and rodents: clinical medicine and surgery. 2nd edition. Philadelphia: WD Saunders; 2003. p. 79–90.
16. Shoemaker NJ, Schuurmans M, Moorman H. Correlation between age at neutering and at onset of hyperadrenocorticism in ferrets. *J Am Vet Med Assoc* 2000; 216(2):195–7.
17. Rosenthal KL, Peterson ME, Quesenberry KE, et al. Hyperadrenocorticism associated with adrenocortical tumor or nodular hyperplasia of the adrenal gland in ferrets: 50 cases (1987–1991). *J Am Vet Med Assoc* 1993;203(2):271–5.
18. Antinoff N, Hahn K. Ferret oncology: diseases, diagnostics and therapeutics. *Vet Clin North Am Exotic Anim Pract* 2004;7:579–625.
19. Rosenthal KL, Peterson ME. Plasma androgen concentrations in ferrets with adrenal gland disease. *J Am Vet Med Assoc* 1996;209:1097–102.
20. Wagner RA, Bailey EM, Schneider JF, et al. Leuprolide acetate treatment of adrenocortical disease in ferrets. *J Am Vet Med Assoc* 2001;218:1272–4.
21. Ramer JC, Benson KG, Morrissey JK, et al. Effects of melatonin administration on the clinical course of adrenocortical disease in domestic ferrets. *J Am Vet Med Assoc* 2006;229(11):1743–8.
22. Weiss C. Medical management of ferret adrenal tumors and hyperplasia. *Exotic DVM* 1999;1(5):38–9.
23. Li X, Fox JG, Padrid PA. Neoplastic disease in ferrets: 574 cases (1968–1997). *J Am Vet Med Assoc* 1998;212(1):1402–6.
24. Li X, Fox JG. Neoplastic diseases. In: Fox JG, editor. Biology and diseases of the ferret. Baltimore (MD): Williams & Wilkins; 1998. p. 405–47.
25. Weiss CA, Williams BH, Scott MV. Insulinoma in the ferret: clinical findings and treatment comparison of 66 cases. *J Am Anim Hosp Assoc* 1998;34(6):471–5.

26. Caplan ER, Peterson ME, Mullen HS, et al. Diagnosis and treatment of insulin-secreting pancreatic islet cell tumors in ferrets: 57 cases (1986–1994). *J Am Vet Med Assoc* 1996;209(10):1741–5.
27. Erdman SE, Kanki PJ, Moore FM, et al. Clusters of lymphoma in ferrets. *Cancer Invest* 1996;14(3):225–30.
28. Erdman SE, Reimann KA, Moore FM, et al. Transmission of a chronic lymphoproliferative syndrome in ferrets. *Lab Invest* 1995;72(5):539–46.
29. Williams BH, Weiss CA. Ferrets: neoplasia. In: Quesenberry KE, Carpenter JW, editors. *Ferrets, rabbits and rodents: clinical medicine and surgery*. 2nd edition. Philadelphia: WD Saunders; 2003. p. 91–106.
30. Erdman SE, Brown SA, Kawasaki TA, et al. Clinical and pathologic findings in ferrets with lymphoma: 60 cases (1982–1994). *J Am Vet Med Assoc* 1996; 108(8):1285–9.
31. Petrie JP, Morrisey JK. Ferrets: cardiovascular and other diseases. In: Quesenberry KE, Carpenter JW, editors. *Ferrets, rabbits and rodents: clinical medicine and surgery*. 2nd edition. Philadelphia: WD Saunders; 2003. p. 58–71.
32. Fox JG. Other systemic diseases. In: Fox JG, editor. *Biology and diseases of the ferret*. Baltimore (MD): Williams & Wilkins; 1998. p. 313–20.
33. Wagner R. Ferret cardiology. *Vet Clin North Am Exot Anim Pract* 2009;12:115–34.
34. Antinoff N. Clinical observations in ferrets with naturally occurring heartworm disease and preliminary evaluation of treatment with ivermectin with and without Melarsomine. *Recent Adv Heartworm Dis*; 2002. p. 45–7.
35. Kawasaki TA. Normal parameters and laboratory interpretation of disease states in the domestic ferret. *Semin Avian Exotic Pet Med* 1994;3(1):40–7.
36. Fisher PG. Exotic mammal renal disease: causes and clinical presentation. *Vet Clin North Am Exotic Anim Pract* 2006;9:33–43.
37. Orcutt CJ. Ferret urogenital diseases. *Vet Clin North Am Exot Anim Pract* 2003; 6(1):113–38.
38. Polluck CG. Ferrets: urogenital diseases. In: Quesenberry KE, Carpenter JW, editors. *Ferrets, rabbits and rodents: clinical medicine and surgery*. 2nd edition. Philadelphia: WD Saunders; 2003. p. 41–9.
39. Williams BH. Pathology of the domestic ferret (*Mustela putorius furo*). In: 2004 C.L. Davis ACVP Symposium Pathology of Non-traditional Pets; 2004. p. 103–32.
40. Fox JA, Parson RC, Bell JA. Diseases of the genitourinary system. In: Fox JG, editor. *Biology and diseases of the ferret*. Baltimore (MD): Williams & Wilkins; 1998. p. 247–72.
41. Cathers TE, Isaza R, Oehme F. Acute ibuprofen toxicosis in a ferret. *J Am Vet Med Assoc* 2000;216(9):1426–8.
42. Richardson JA, Balabuszko RA. Ibuprofen ingestion in a ferret. *Exotic DVM* 2001; 3(2):3.
43. Richardson JA, Balabuszko RA. Managing ferret toxicosis. *Exotic DVM* 2000;2(4): 23–6.
44. Straube EF, Schuster NH, Sinclair AJ. Zinc toxicity in the ferret. *J Comp Pathol* 1980;90(3):355–61.
45. Fox JG, Zeman DH, Mortimer JD, et al. Copper toxicosis in sibling ferrets. *J Am Vet Med Assoc* 1994;205(8):1154–6.
46. Van der Woerd A. Ophthalmologic diseases in small pet mammals. In: Quesenberry KE, Carpenter JW, editors. *Ferrets, rabbits and rodents: clinical medicine and surgery*. 2nd edition. Philadelphia: WD Saunders; 2003. p. 421–7.
47. Erdman SE, Xiantang L, Fox JG. Hematopoietic diseases. In: Fox JG, editor. *Biology and diseases of the ferret*. Baltimore (MD): Williams & Wilkins; 1998. p. 231–46.