

# Electrical isolation of the right pulmonary veins requiring ablation from the right atrial septum



Rahul Bhardwaj, MD,\* Vivek Y. Reddy, MD†

From the \*Loma Linda University, Loma Linda, California, and †Icahn School of Medicine at Mount Sinai, New York, New York.

## Introduction

Pulmonary vein (PV) isolation has become the mainstay of atrial fibrillation (AF) ablation. Isolation of the right PV pair using an extraostial antral ablation approach is sometimes limited by the thickness of the atrial tissue along the anterior aspect of the vein pair. We describe a case of AF ablation where acute isolation of the right PV pair was not achieved with endocardial left atrial ablation alone, but required additional ablation from the adjacent right atrial septum.

## Case report

A 70-year-old woman with a history of symptomatic paroxysmal AF refractory to medical therapy with flecainide and dronedarone was referred for catheter ablation. Her medical history was only notable for hypothyroidism, breast cancer with prior radiation therapy, and prior spinal surgeries. The left ventricular systolic function was normal. The procedure was performed with uninterrupted anticoagulation with Xarelto.

An octapolar catheter was placed in the coronary sinus, and dual transseptal access was achieved with intracardiac echocardiographic (ICE) and fluoroscopic guidance. After esophageal deviation with a dedicated esophageal retracting balloon (DV8 Balloon, Manual Surgical Sciences Inc, Minneapolis, MN), the left atrial anatomy was rendered using a multispline catheter and an electroanatomic mapping system (PentaRay, CARTO3; Biosense Webster Inc, Diamond Bar, CA). Using a deflectable sheath (Agilis, St. Jude, St. Paul, MN), ablation lesions were placed with a force-sensing irrigated ablation catheter (ThermoCool SmartTouch SurroundFlow, Biosense Webster Inc). The Visitag software module was used with ablation tags of 2 mm and a minimum force-time integral of 550 gs.

**KEYWORDS** Atrial fibrillation ablation; Pulmonary vein isolation (Heart Rhythm Case Reports 2018;4:144–145)

**Address reprint requests and correspondence:** Dr Vivek Y. Reddy, Helmsley Electrophysiology Center, Icahn School of Medicine at Mount Sinai, One Gustave L. Levy Place, Box 1030, New York, NY 10029. E-mail address: [vivek.reddy@mountsinai.org](mailto:vivek.reddy@mountsinai.org).

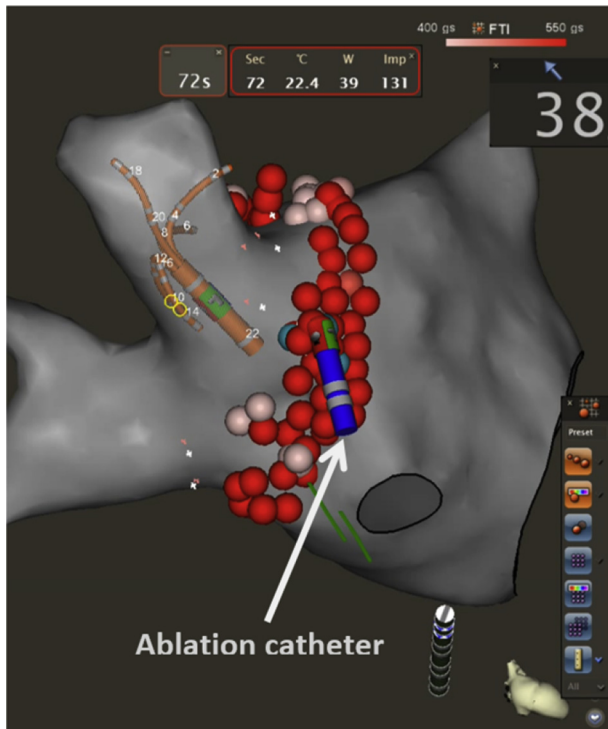
## KEY TEACHING POINTS

- The interatrial septum may be thick in some patients.
- A thick septum may cause difficulty for creation of transmural lesions with ablation from the left atrial endocardial surface.
- Ablation from both the anterior aspect of the right pulmonary veins in the left atrium and the corresponding right atrial aspect of the septum may be necessary to achieve transmural lesions and pulmonary vein isolation.

Despite completion of a circumferential lesion set, electrical PV isolation was not achieved. Activation mapping localized the earliest electrogram to the anterior aspect of the lesion set. Additional application of radiofrequency (RF) energy in the left atrium caused only transient electrical isolation, with immediate reconnection upon cessation of energy delivery. The ablation catheter was then withdrawn to the right atrium, and RF energy was delivered to the right atrial septum adjacent to the left atrial lesions that had transiently isolated the PV; this achieved electrical isolation of the right PVs (Figure 1). ICE imaging demonstrated that the ablation catheter was in contact with a thick portion of the intra-atrial septum (Figure 2). The right PVs remained electrically isolated despite the administration of adenosine (18 mg).

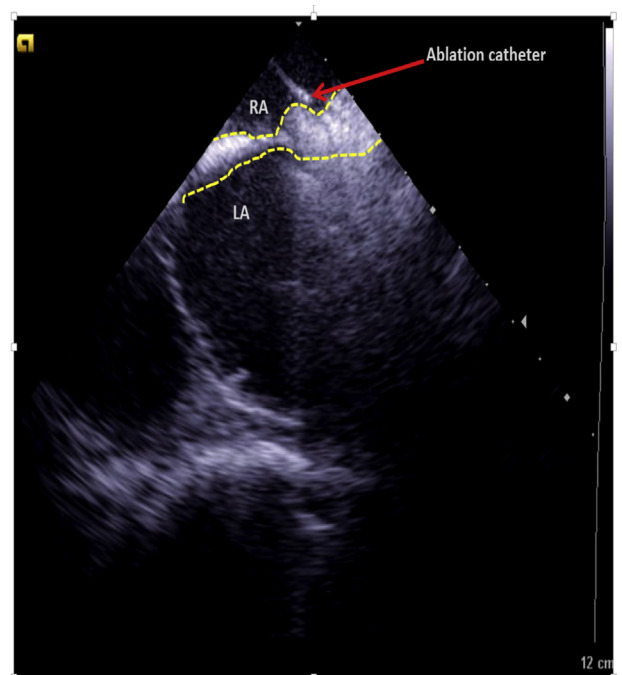
## Discussion

This case demonstrates the necessity of adjuvant right atrial ablation in the setting of a thickened intra-atrial septum where left atrial ablation alone was insufficient to achieve electrical isolation. The thickened aspect of the septum anterior to the right PVs likely represents the limbus of the fossa ovalis. It is not uncommon for this tissue to be thickened, and in some instances there can be extensive lipomatous hypertrophy. In these situations, particularly when the anterior aspect of the



**Figure 1** Electroanatomic map of left atrium with the ablation catheter delivering radiofrequency energy in the right atrium. A multielectrode mapping catheter is placed in the right superior pulmonary vein. Red dots represent left atrial ablation lesions; light blue dots represent right atrial lesions. Ablation on the right atrial aspect of the intra-atrial septum resulted in isolation of right pulmonary vein pair.

right PV lesion set is situated quite antrally, transmuralty of the isolating line may only be achieved with ablation of the right atrial septum. The posterior right atrial septum is a



**Figure 2** Intracardiac echocardiographic imaging shows the ablation catheter in the right atrium on a thick portion of the intra-atrial septum (inscribed in yellow dashed lines) adjacent to the left atrial lesions that caused transient isolation of right pulmonary veins. Ablation from this location resulted in right pulmonary vein isolation. LA = left atrium; RA = right atrium.

safe place to ablate. Practitioners should consider right atrial ablation if there is failure to isolate the right pulmonary veins after left atrial ablation, particularly if there is anterior breakthrough and ICE imaging demonstrates a thickened septum.