

Posterior tibial artery aneurysm in a child with *SMAD3* mutation

Elias Kfoury, MD,^a Aaron Y. Chen, BS,^a and Peter H. Lin, MD,^{a,b} *Houston, Tex; and Los Angeles, Calif*

ABSTRACT

Peripheral arterial aneurysms in children are uncommon. We report a 6-year-old boy who developed a right posterior tibial artery aneurysm with symptoms including pain and pulsatile tenderness. His genetic testing revealed a *SMAD3* mutation, a condition associated with familial aortic aneurysm, early-onset of osteoarthritis, and peripheral aneurysms. The posterior tibial artery aneurysm was treated with surgical resection and primary anastomosis. The patient remained free of symptoms or aneurysm recurrence in his tibial artery 2 years later. This represents the first reported case of pediatric tibial artery aneurysm linked to a *SMAD3* mutation. (*J Vasc Surg Cases and Innovative Techniques* 2017;3:109-11.)

Arterial aneurysms in children are rare, which can be attributed to congenital cardiovascular disease, connective tissue disorders, or arteritis. A genetic abnormality, such as a *SMAD3* mutation, has been linked to thoracic aortic pathologies, including aneurysm and dissection.¹ In this report, we describe a child with a *SMAD3* mutation who developed a posterior tibial artery aneurysm. Informed consent was obtained for the publication of this report.

CASE REPORT

A 6-year-old boy presented with a 2-year history of right ankle pain. He noted a progressive painful pulsatile mass located posterior to the medial malleolar region. Physical examination revealed a 2-cm × 2-cm tender posterior tibial artery aneurysm (Fig 1). There were no other physical findings, such as arthritis or joint pain, and no history of trauma to his lower extremities. His family history revealed an uncle with a thoracic aortic aneurysm who died suddenly, presumably of aneurysm rupture, at age 58 years. His paternal grandfather died suddenly in his late 50s after an acute onset of chest pain, although no definitive cause of death was known.

Comprehensive genetic testing was performed for transforming growth factor- β (TGF- β) receptor 1 (*TGFBR1*) and receptor 2 (*TGFBR2*) mutations (mutation causing Loey-Dietz syndrome), collagen type III alpha 1 (*COL3A1*) mutation (mutation causing Ehlers-Danlos syndrome type IV), and *SMAD3* mutations. These genetic evaluations revealed a disease-causing mutation in *SMAD3*.

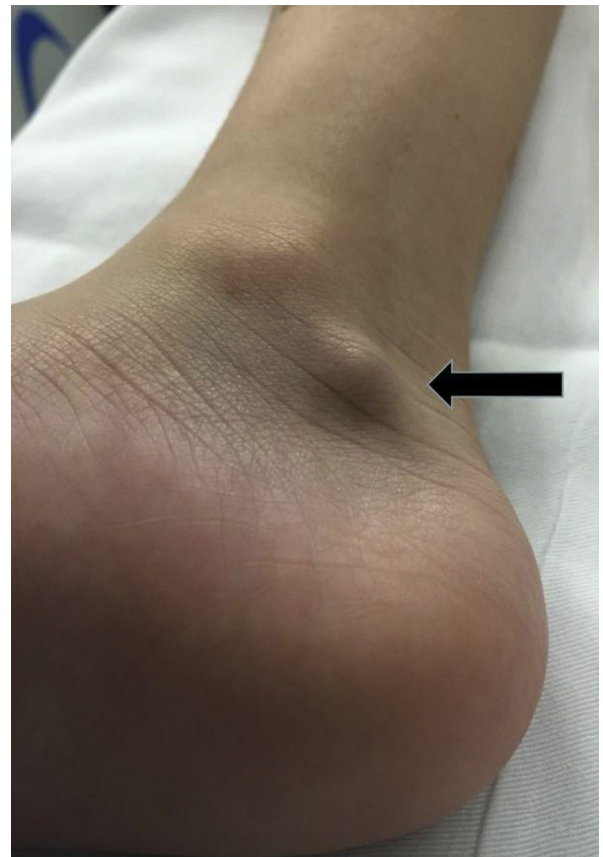

Fig 1. A pulsatile mass (arrow) caused by a posterior tibial artery aneurysm is seen adjacent to the medial malleolus in this child.

A diagnostic angiogram showed a saccular aneurysm involving the posterior tibial artery with distal embolic occlusion of the posterior plantar artery (Fig 2). Surgical repair was performed, which entailed proximal and distal arterial control, followed by aneurysm resection and primary anastomosis of the posterior tibial artery using interrupted 7-0 polypropylene sutures (Fig 3).

The patient was discharged to home 4 days later. In subsequent follow-up visits at 2 years, the patient remained pain free without aneurysm recurrence. He continues to undergo annual surveillance duplex ultrasound imaging of bilateral extremities.

From the Division of Vascular Surgery and Endovascular Therapy, Michael E. DeBakey Department of Surgery, Baylor College of Medicine, Houston^a; and the University Vascular Associates, Los Angeles.^b

Author conflict of interest: none.

Correspondence: Peter H. Lin, MD, Michael E. DeBakey Department of Surgery, Baylor College of Medicine, One Baylor Plaza, Houston, TX 77030 (e-mail: plin@bcm.edu).

The editors and reviewers of this article have no relevant financial relationships to disclose per the Journal policy that requires reviewers to decline review of any manuscript for which they may have a conflict of interest.

2468-4287

© 2016 The Author(s). Published by Elsevier Inc. on behalf of Society for Vascular Surgery. This is an open access article under the CC BY-NC-ND license (<http://creativecommons.org/licenses/by-nc-nd/4.0/>).

<http://dx.doi.org/10.1016/j.jvscit.2016.07.003>

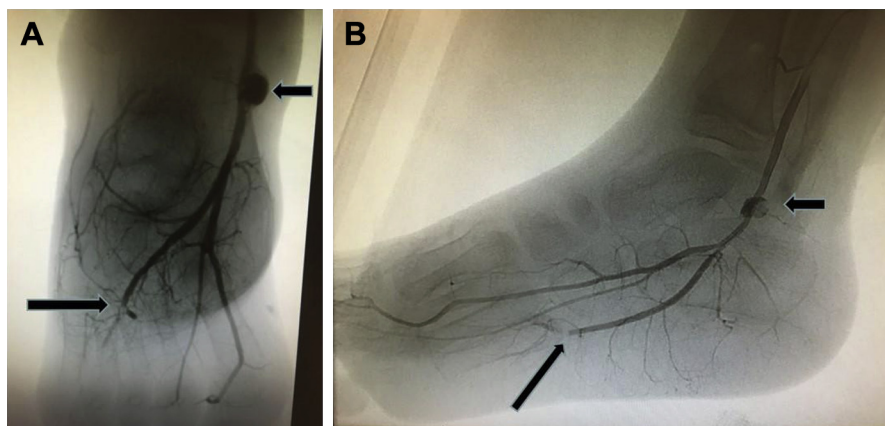


Fig 2. Angiogram of the posterior tibial artery in **(A)** anteroposterior and **(B)** lateral views demonstrated a posterior tibial artery aneurysm (*short arrow*). Distal embolic occlusion in the posterior plantar artery (*long arrow*) is noted.

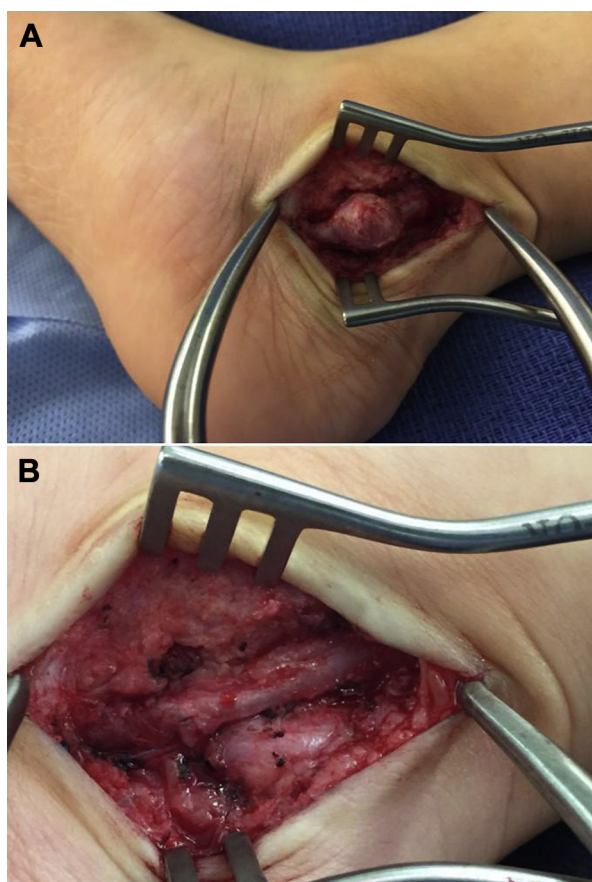


Fig 3. A, Intraoperative view of the posterior tibial artery aneurysm. **B,** The posterior tibial artery aneurysm was resected and repaired primarily using interrupted polypropylene sutures.

DISCUSSION

Arterial aneurysm in children is uncommon, and only <200 cases have been reported in the literature. Among them, pediatric arterial aneurysm involving the lower extremity is even rarer, with <20 patients in

published reports.²⁻⁵ In a clinical review of pediatric arterial aneurysm from the University of Michigan, these researchers characterized nine pathologic factors contributing to pediatric arterial aneurysms.³ These etiologic factors include arterial infection, giant-cell arteritis, autoimmune connective tissue disorder, Kawasaki disease, medial degeneration disease, noninflammatory medial degeneration disease, vascular dysplasia, congenital-idiopathic condition, and extravascular process. In our patient, the etiologic factor contributing to his tibial artery aneurysm is *SMAD3* mutation, which represents the first reported case linking such a genetic mutation to a lower extremity arterial aneurysm in children. Our case also underscores the important role of genetic testing when treating a child who presents with an arterial aneurysm.

Previous reports have linked *SMAD3* mutation to arterial aneurysm formation.⁶⁻⁸ A recent study reports treatment strategies of *SMAD3* mutation-associated visceral and iliac artery aneurysms by means of endovascular interventions.⁶ Burke et al⁷ reported a patient with *SMAD3* mutation who developed an internal mammary artery aneurysm and underwent successful endovascular coil exclusion.

Most of the current understanding of *SMAD3* mutation principally implicates an etiologic role in inherited thoracic aortic disease on chromosome 15.^{1,9} As a recently discovered genetic variable, *SMAD3* mutation joins other identified genetic etiologic factors, including fibrillin-1 (*FBN1*), *TGFBR1*, and *TGFBR2*, which can result in inherited thoracic aortic abnormalities such as Loeys-Dietz syndrome and Marfan syndrome. The *SMAD3* gene encodes SMAD3 protein, which plays a role in cellular signaling pathway following the binding TGF- β to the TGF- β receptors. Genetic mutations of *SMAD3*, which can be inherited in an autosomal-dominant fashion, can result in a syndrome characterized by aortic aneurysms and early-onset degenerative osteoarthritis.

This condition, also known as the aneurysms-osteoarthritis syndrome, can result in aneurysms and dissections in the arterial circulation, craniofacial abnormalities, osteoarthritis, and cutaneous and skeletal anomalies.⁸

In an analysis of 34 patients with *SMAD3* mutation, van de Laar et al⁹ found that cardiovascular abnormalities were present in 80%. Although aortic aneurysm and aortic dissection were the two most common vascular pathologies, approximately one-third of these patients exhibited some form of arterial aneurysms, including vertebral, pulmonary, splenic, iliac, and mesenteric artery aneurysms. Significant arterial tortuosity was detected in nearly half of these patients, which involved vertebral, internal carotid, and cerebral arterial circulation.⁹ Another genetic study analyzed 42 patients with *SMAD3* mutation from five families with familial thoracic aortic pathologies.¹⁰ The authors reported common vascular abnormalities, including thoracic aortic aneurysm or dissection, abdominal aortic aneurysm, and iliac artery aneurysms. The patient described in this report is notable because no previous published studies have linked *SMA3* mutation to a posterior tibial artery aneurysm.

CONCLUSIONS

Although other researchers have described the feasibility of endovascular treatment using coil embolization in excluding arterial aneurysm in patients with *SMD3* mutation,^{6,7} we believe such a treatment would not result in a long-term durable success in our patient. Owing to the small vessel caliber of the posterior tibial artery in our young patient, we elected surgical repair with aneurysm resection and primary repair using interrupted polypropylene sutures. The principle of interrupted anastomosis in pediatric vascular reconstruction has been highlighted by our previous reports because this technique allows circumferential vessel growth without suture line stricture when the child continues to grow.^{4,11} The treatment outcome of our patient was remarkable after the surgical repair as he continued to

undergo yearly ultrasound surveillance, without evidence of aneurysm recurrence.

REFERENCES

1. van der Linde D, van de Laar IM, Bertoli-Avella AM, Oldenburg RA, Bekkers JA, Mattace-Raso FU, et al. Aggressive cardiovascular phenotype of aneurysms-osteoarthritis syndrome caused by pathogenic *SMAD3* variants. *J Am Coll Cardiol* 2012;60:397-403.
2. Yetman RJ, Black CT. Traumatic false aneurysms of peripheral arteries in children. *South Med J* 1992;85:665-6.
3. Sarkar R, Coran AG, Cilley RE, Lindenauer SM, Stanley JC. Arterial aneurysms in children: clinicopathologic classification. *J Vasc Surg* 1991;13:47-56; discussion: 57.
4. Lin PH, Dodson TF, Bush RL, Weiss VJ, Conklin BS, Chen C, et al. Surgical intervention for complications caused by femoral artery catheterization in pediatric patients. *J Vasc Surg* 2001;34:1071-8.
5. Bagwell CE, Caffee HH, Talbert JL. Peripheral aneurysms in children—a link to trauma. *Pediatrics* 1988;82:786-8.
6. van der Linde D, Verhagen HJ, Moelker A, van de Laar IM, Van Herzele I, De Backer J, et al. Aneurysm-osteoarthritis syndrome with visceral and iliac artery aneurysms. *J Vasc Surg* 2013;57:96-102.
7. Burke C, Shalhub S, Starnes BW. Endovascular repair of an internal mammary artery aneurysm in a patient with *SMAD3* mutation. *J Vasc Surg* 2015;62:486-8.
8. van de Laar IM, van der Linde D, Oei EH, Bos PK, Bessems JH, Bierma-Zeinstra SM, et al. Phenotypic spectrum of the *SMAD3*-related aneurysms-osteoarthritis syndrome. *J Med Genet* 2012;49:47-57.
9. van de Laar IM, Oldenburg RA, Pals G, Roos-Hesselink JW, de Graaf BM, Verhagen JM, et al. Mutations in *SMAD3* cause a syndromic form of aortic aneurysms and dissections with early-onset osteoarthritis. *Nat Genet* 2011;43:121-6.
10. Regalado ES, Guo DC, Villamizar C, Avidan N, Gilchrist D, McGillivray B, et al. Exome sequencing identifies *SMAD3* mutations as a cause of familial thoracic aortic aneurysm and dissection with intracranial and other arterial aneurysms. *Circ Res* 2011;109:680-6.
11. Lin PH, Barr V, Bush RL, Velez DA, Lumsden AB, Ricketts J. Isolated abdominal aortic rupture in a child due to all-terrain vehicle accident—a case report. *Vasc Endovasc Surg* 2003;37:289-92.

Submitted May 24, 2016; accepted Jul 8, 2016.