

Dual arterial blood supply D-pouch in a patient with ulcerative colitis undergoing proctocolectomy and ileal pouch-anal anastomosis

A case report

Hang Hu, MD^{a,b}, Yichao Zhang, BSMed^{a,b}, Qun Qian, MD^{a,b}, Ming Xu, MD^c, Min Chen, MD^d, Congqing Jiang, MD^{a,b}, Zhao Ding, MD^{a,b,*}

Abstract

Introduction: Pouchitis is the most common complication in Ulcerative colitis (UC) patients after restorative proctocolectomy with ileal pouch-anal anastomosis (RP-IPAA) and ischemia may be a significant contributing factor. Tension and blood supply are the primary concerns while performing the procedure. A dual arterial blood supply technique is designed to decrease tension while ensuring sufficient blood perfusion.

Patient concerns: A 61-year-old female patient with 14 years history of UC wanted to seek surgical treatment.

Diagnoses: Ulcerative colitis.

Interventions: After physical examination and treatment of parenteral nutrition, the patient underwent a D-pouch with dual arterial blood supply after total proctocolectomy.

Outcomes: The patient recovered well and was discharged 10 days after her procedure. Postoperatively dual arterial blood supply to the D-pouch was demonstrated by computed tomography angiography (CTA).

Conclusion: D-pouch with dual arterial blood supply is feasible and safe in patients with UC undergoing RP-IPAA.

Abbreviations: CD = Crohn's disease, CT = computed tomography, CTA = computed tomography angiography, NSAIDs = nonsteroidal anti-inflammatory drugs, RP-IPAA = restorative proctocolectomy with ileal pouch-anal anastomosis, UC = ulcerative colitis.

Keywords: D-pouch, ileal pouch-anal anastomosis, pouchitis, ulcerative colitis

1. Introduction

Restorative proctocolectomy with ileal pouch-anal anastomosis (RP-IPAA) has been the procedure of choice for patients with

ulcerative colitis (UC) who require surgery.^[1] Quality of life after RP-IPAA is satisfactory in most cases.^[2] However, pouchitis can occur in 14% to 59% of the patients after surgery.^[3–6]

The etiology of pouchitis is unknown. In addition to gut microbiota and mucosal immunity, genetic, vascular, and luminal factors (such as nonsteroidal anti-inflammatory drugs [NSAIDs]) are likely to contribute to the initiation, exacerbation, and progression of pouchitis. Ischemic pouchitis is generally a poorly understood phenomenon presenting as secondary pouchitis, whose symptoms are similar to primary pouchitis but are often treated unsuccessfully with standard medical therapy.^[4,7] Although the etiology is still being investigated, it is thought to be the result of undue tension on the small bowel mesentery in a chronic manner causing asymmetrical ischemic inflammation.^[8] As the etiology is proposed to be tension-induced ischemia, tension correction has been shown to be an effective treatment, including weight loss^[9] and fecal diversion combined with hyperbaric oxygen therapy.^[10] A dual arterial supply is designed to ensure sufficient blood supply to the pouch while ensuring a tension-free anastomosis. In addition to offering superior mesenteric artery blood supply, the ileocolic artery, and its ileum branches parts are reserved, which are then anastomosed with the distal stump of the inferior mesenteric artery during the IPAA procedure.

We describe a 61-year-old female patient with UC undergoing a D-pouch with dual arterial blood supply after total proctocolectomy.

Editor: N/A.

HH and YZ contributed equally to this work.

The authors declared no financial conflict of interest.

Ethical approval: Ethical approval was given by Zhongnan Hospital's IRB committee.

Consent: Patient has provided informed consent for publication of the case.

^aColorectal Surgery Department, Zhongnan Hospital of Wuhan University, ^bHubei Key Laboratory of Intestinal & Colorectal Diseases, Quality Control Center of Colorectal Surgery, Health Commission of Hubei Province, ^cCardiovascular Surgery Department, Zhongnan Hospital of Wuhan University, ^dGastroenterology Department, Zhongnan Hospital of Wuhan University, Hubei, China.

* Correspondence: Zhao Ding, Colorectal Surgery Department, Zhongnan Hospital of Wuhan University, Wuhan 430071, China (e-mail: wb002550@whu.edu.cn).

Copyright © 2019 the Author(s). Published by Wolters Kluwer Health, Inc. This is an open access article distributed under the terms of the Creative Commons Attribution-Non Commercial-No Derivatives License 4.0 (CCBY-NC-ND), where it is permissible to download and share the work provided it is properly cited. The work cannot be changed in any way or used commercially without permission from the journal.

Medicine (2019) 98:18(e15394)

Received: 6 December 2018 / Received in final form: 25 March 2019 / Accepted: 2 April 2019

<http://dx.doi.org/10.1097/MD.00000000000015394>

2. Case presentation

A 61-year-old female was diagnosed with UC pancolitis 14 years ago. The patient underwent steroid therapy for approximately 2 years, which was stopped 3 years before operation. Only 5-ASA was administered as maintenance therapy. She was hospitalized at the department of colorectal surgery. CT showed partial wall thickening of the sigmoid colon with no lymphadenopathy or distant metastases. The body mass index was 15.8 (weight/height²).

D-pouch IPAA in the double-stapled technique was performed as previously described and was modified appropriately.^[11] The patient was brought to the operating room and placed in a modified lithotomy position to prepare laparoscopic. The abdomen was explored to rule out evidence of CD. The colon was mobilized and meticulous care was taken to preserve the ileocolic artery and its ileal branches. The distal ileum was transected using linear stapler close to the cecum. The inferior mesenteric artery was mobilized to the level of the sacral promontory. Mobilization of the rectum was carried out as close to the bowel as possible to minimize damage to the pelvic autonomic nerves. The rectum was divided approximately 2 cm above the dentate line using a linear stapler.

Attention was diverted to the creation of the D-shape ileal reservoir, a modified J-pouch. The terminal ileum was aligned in a J configuration. Both limbs of the J were approximately 15 cm in length and the exact length was guided by where the lowest aspect of the pouch reached the rectal stump in order to accomplish a tension-free ileoanal anastomosis. The anvil of a 21 mm circular stapler was placed into the terminal ileum. An incision was made at the apex of the J and a 21 mm circular stapler advanced through the afferent limb in 15 cm long. Then the trocar was passed through the anti-mesenteric intestine wall. The end to side anastomosis was completed. The configuration of the terminal ileum was modified from J to D. The 80 or 100 mm linear stapler was applied through the apical enterotomy. Two to three loads were usually needed, which ensured that the liner stapler would surpass the bowel end-to-side anastomosis over the stapler and form the entire D-pouch (Fig. 1).

After the D-pouch was created, the ileocolic artery root was ligated and anastomosed with the distal stump of the inferior mesenteric artery by an experienced cardiovascular surgeon. These vessels formed dual arterial perfusion for the pouch after ileocolic-inferior mesenteric artery anastomosis (Fig. 2). A 29 mm circular stapler was used to affect the pouch-anal anastomosis. The total operative time was 270 min, build time of ileal D-pouch was 35 min, volume of pouch was 165 mL and blood loss was 100 mL.

The remainder of the postoperative course was unremarkable. She was discharged 10 days after her procedure. And 14 days after the operation, the CTA showed that the artery blood of the pouch originated from both the superior mesenteric artery and inferior mesenteric artery. Defecography using iopamidol after D-pouch IPAA showed no pouch stump and there was good pouch capacity at rest. No recent complications such as intestinal obstruction, anastomotic fistula, and ischemic pouchitis occurred during the follow-up period of 1 to 6 months. CGQL, Postoperative Wexner incontinence score, frequency of defecation at 24h and at the night were 0.6, 4, 6, 3 at 1 month postoperatively, and 0.4, 2, 3, 1 at 6 months postoperatively.

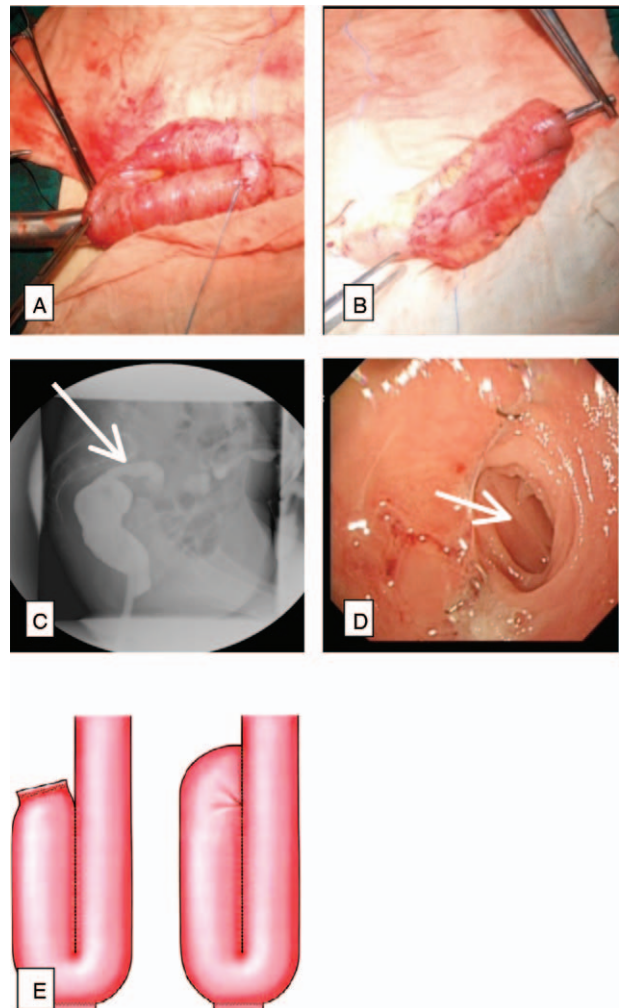


Figure 1. Ileal D-pouch creation. A: The 21 mm circle staple advanced 15 cm through proximal limbs of ileum, then the trocar advanced through antimesenteric ileum wall. The 21 mm anvil mechanism was positioned onto the rod of the circular stapler. The end to side anastomosis was completed. B: The end to side anastomosis was completed. The configuration of terminal ileum turned J to D. C: Patient with D-pouch showed though iopamidol defecography. The pouchogram shows no pouch stump and there is good pouch capacity at rest. The white arrow indicated afferent ileal limbs. D: Ileal D-reservoir with only afferent ileal limbs, and the apical enterotomy anastomosis was well. The white arrow indicated afferent ileal limbs. E: The left is traditional J-pouch, the right is D-pouch, a modified J-pouch.

3. Discussion

RP-IPAA is the cornerstone of treatment for UC. For the majority of cases, surgery is successful, pouch function is ideal, and patients enjoy excellent bowel function and a high quality of life.^[12] However, a minority of patients suffer from poor pouch function as a result of a number of complications that often challenge the clinician with identification and management.^[4–7,13] Pouchitis is the most common complication in UC patients with IPAA. And at least 50% of patients with IPAA suffer pouchitis at least once, 70% of whom have this complication after 1 year of ileostomy.^[5,6] Symptoms of pouchitis include abdominal pain, increased stool frequency, incontinence, tenesmus, fecal urgency, and diarrhea.^[3] Pouchitis occurs at a rate of

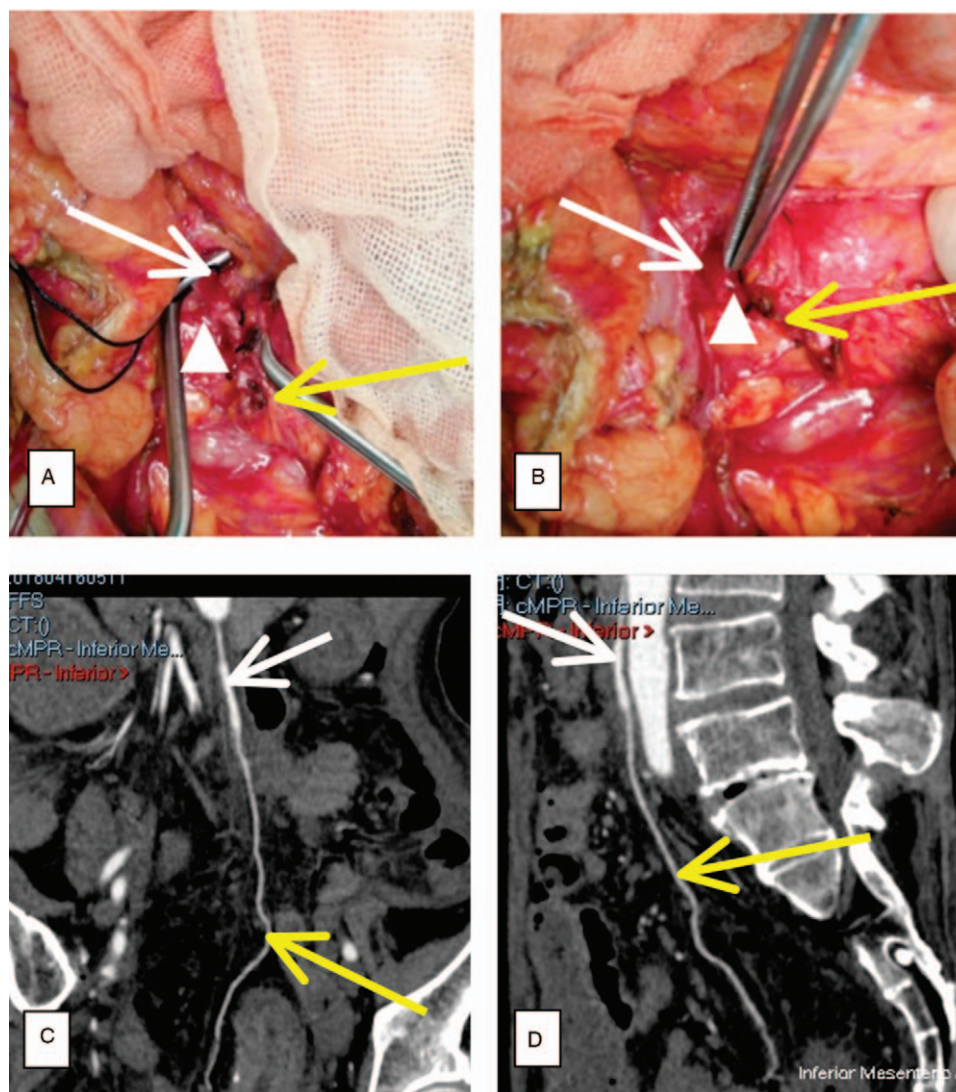


Figure 2. Blood vessels anastomosis. A and B: During the procedure, the ileal branches of the ileocolic artery and vein were preserved. Ileocolic artery root was liberated (yellow arrow) and its ileum branches parts were reserved. Inferior mesenteric artery (white arrow) was liberated to sacral promontory level. The ileocolic artery was anastomosed with the distal stump of inferior mesenteric artery (the anastomosed site showed with triangle). C and D: On 14 days after the operation, the CTA showed complete patency of inferior mesenteric-ileocolic artery. Blood of pouch originated from both superior mesenteric artery and inferior mesenteric artery.

31% in patients who undergo total proctocolectomy with IPAA for UC. Further, 34% will develop an episode of pouchitis that is easily treated and does not recur, while 61% will suffer at least a second episode, of which 16% will go on to develop chronic or refractory pouchitis.^[14,15]

Ischemic pouchitis is a disease with few reports in the literature and standard treatment is still under discussion.^[16] Patients with pouchitis suffer from severe symptoms and are limited in their social activities. Studies have suggested that weight loss may help with symptoms.^[8] In these cases, a diverting ileostomy may be offered with a pouch in situ to allow patients to regain health and lose weight. Common scenarios where chronic tension may develop are those patients who present as obese when they have IPAA or increased weight after receipt of an IPAA. In these obese patients, the small bowel mesentery was not long enough. To accomplish a tension-free ileoanal anastomosis, lengthening maneuvers, including selective division of mesenteric vessels,

superficial incision on the anterior and posterior aspects of the small bowel mesentery, and mobilization of the small bowel mesentery up to and anterior to the duodenum were provided.^[17,18] However, over time, pouchitis might cause chronic ischemia. Other patients suffered from UC for years and are malnourished. When they regained health, their increased visceral adiposity created tension on the small bowel mesentery. As the etiology is proposed to be tension-induced ischemia, tension correction has been shown to be an effective method and antibiotic therapy is the primary treatment of choice for this kind of pouchitis.^[16] A double artery supply was designed to ameliorate the pouch blood supply and correct tension. The technique we propose is to provide double artery supply and correct the tension. A few technical points should be stressed. Omentectomy should be performed to lower the incidence of postoperative sepsis. Stapling of the distal ileum flush with the cecum is very important and the ileal branches of the ileocolic

artery and vein should be preserved by stapling of the distal ileum flush with the cecum. Furthermore, this ileocolic artery was anastomosed with the inferior mesenteric artery instead of being abandoned. Mobilization of the rectum should be flush with the fascia propria to minimize damage to nearby autonomic nerves traveling to the urinary bladder and sexual organs.

In this case, 14 days after the operation, the CTA showed that the artery blood of the pouch originated from both the superior mesenteric artery and inferior mesenteric artery. Defecography using iopamidol after D-pouch IPAA showed no pouch stump and there was good pouch capacity at rest. D-pouch, a modified J-pouch, was typical without a pouch stump, which was functionally comparable to a J-pouch.^[11] On the other hand, it was better than a J-pouch in preventing leakage/fistula complications. Although this procedure needs an extra anastomosis, it took no more than 30 min for a practiced vascular surgeon. Low-molecular-weight heparin was used as an anticoagulant routinely.

Despite the absence of an effective surgical “cure” for refractory or chronic ischemic pouchitis, the surgeon’s role in the multidisciplinary management of pouchitis is crucial with regard to confirming the correct diagnosis and offering options for symptom management. The above discussion might highlight a concept that forms a surgical technique for the management of patients with this complication, and as yet poorly understood, an IPAA complication was paid particular attention to. From this case, an IPAA with a D-pouch double artery blood supply is feasible and secure for patients with UC. Further studies with a large sample size and standardized diagnostic criteria for pouchitis need to be carried out to further evaluate the efficiency of alleviating ischemic pouchitis by the double artery blood supply D-pouch.

Author contributions

Conceptualization: Hang Hu, Yichao Zhang, Zhao Ding.

Data curation: Hang Hu, Yichao Zhang.

Formal analysis: Hang Hu, Yichao Zhang.

Investigation: Hang Hu, Yichao Zhang, Congqing Jiang.

Resources: Ming Xu, Min Chen.

Writing – original draft: Hang Hu, Yichao Zhang.

Writing – review & editing: Hang Hu, Yichao Zhang, Qun Qian, Zhao Ding.

References

- [1] Kent A, Keshav S. Managing intractable proctitis and the problematic pouch. *Dig Dis* 2014;32:427–37.
- [2] Wu H, Shen B. Pouchitis and pouch dysfunction. *Gastroenterol Clin North Am* 2009;38:651–68.
- [3] Hata K, Ishihara S, Nozawa H, et al. Pouchitis after ileal pouch-anal anastomosis in ulcerative colitis: diagnosis, management, risk factors, and incidence. *Dig Endosc* 2017;29:26–34.
- [4] Shen B. Problems after restorative proctocolectomy: assessment and therapy. *Curr Opin Gastroenterol* 2016;32:49–54.
- [5] Pardi DS, D’Haens G, Shen B, et al. Clinical guidelines for the management of pouchitis. *Inflamm Bowel Dis* 2009;15:1424–31.
- [6] Shen B. Pouchitis: what every gastroenterologist needs to know. *Clin Gastroenterol Hepatol* 2013;11:1538–49.
- [7] Shen B, Plesec TP, Remer E, et al. Asymmetric endoscopic inflammation of the ileal pouch: a sign of ischemic pouchitis? *Inflamm Bowel Dis* 2010;16:836–46.
- [8] Liu G, Wu X, Li Y, et al. Postoperative excessive gain in visceral adipose tissue as well as body mass index are associated with adverse outcomes of an ileal pouch. *Gastroenterol Rep (Oxf)* 2016.
- [9] Wu XR, Zhu H, Kiran RP, et al. Excessive weight gain is associated with an increased risk for pouch failure in patients with restorative proctocolectomy. *Inflamm Bowel Dis* 2013;19:2173–81.
- [10] Nyabanga CT, Kulkarni G, Shen B. Hyperbaric oxygen therapy for chronic antibiotic-refractory ischemic pouchitis. *Gastroenterol Rep (Oxf)* 2015;28.
- [11] Ding Z, Wu Y, Qin Q, et al. Application of ileal D-pouch anal anastomosis in the treatment of ulcerative colitis and familial adenomatous polyposis. *Zhonghua Wei Chang Wai Ke Za Zhi* 2015;18:1231–4.
- [12] Sofo L, Caprino P, Sacchetti F, et al. Restorative proctocolectomy with ileal pouch-anal anastomosis for ulcerative colitis: a narrative review. *World J Gastrointest Surg* 2016;8:556–63.
- [13] Zezos P, Saibil F. Inflammatory pouch disease: the spectrum of pouchitis. *World J Gastroenterol* 2015;21:8739–52.
- [14] Fazio VW, Kiran RP, Remzi FH, et al. Ileal pouch anal anastomosis: analysis of outcome and quality of life in 3707 patients. *Ann Surg* 2013;257:679–85.
- [15] Sullivan JF, Katz##JA. Treatment of acute pouchitis. *Semin Colon Rectal Surg* 2017;28:132–7.
- [16] Schaus BJ, Fazio VW, Remzi FH, et al. Large polyps in the ileal pouch in patients with underlying ulcerative colitis. *Dis Colon Rectum* 2006;50:832–8.
- [17] None . Technical aspects of ileoanal pouch surgery[J]. *Clin Colon Rectal Surg* 2004;17:35–41.
- [18] Uraiqat AA, Byrne CMD, Phillips RKS. Gaining length in ileal-anal pouch reconstruction: a review[J]. *Colorectal Dis* 2010;9:657–61.