



## Original article

## Chitosan treatment for skin ulcers associated with diabetes



Ana Aglahe Escárcega-Galaz<sup>a</sup>, José Luis De La Cruz-Mercado<sup>b</sup>, Jaime López-Cervantes<sup>a</sup>,  
Dalia Isabel Sánchez-Machado<sup>a,\*</sup>, Olga Rosa Brito-Zurita<sup>b</sup>, José Manuel Ornelas-Aguirre<sup>c</sup>

<sup>a</sup> Departamento de Biotecnología y Ciencias Alimentarias, Instituto Tecnológico de Sonora, Ciudad Obregón, Sonora, Mexico

<sup>b</sup> Unidad de Investigación en Epidemiología Clínica, Hospital de Especialidades No. 2, Unidad Médica de Alta Especialidad, Instituto Mexicano del Seguro Social, Ciudad Obregón, Sonora, Mexico

<sup>c</sup> Departamento de Ciencias de la Salud, Universidad de Sonora, Campus Cajeme, Ciudad Obregón, Sonora, Mexico

## ARTICLE INFO

## Article history:

Received 2 March 2016

Revised 10 March 2017

Accepted 29 March 2017

Available online 30 March 2017

## Keywords:

Chitosan

Ulcer

Diabetes mellitus

Gel

Film

Biomaterials

## ABSTRACT

Infections, ulcerations, gangrene and, in severe cases, extremity amputation, are common complications among diabetic subjects. Various biomaterials have been utilized for the treatment of these lesions. Chitosan is an amino sugar with a low risk of toxicity and immune response. In this study, we evaluated chitosan topical gel and film treatments for subjects with diabetic ulcerations and wounds associated with diabetes mellitus. In a pre-experimental design, we described the result of chitosan gel and film treatment for wounds and skin ulcers among patients with long-standing diabetes mellitus. We studied 8 diabetic patients with wounds and skin ulcers (long duration and Wagner degree 1–2). Initially, most lesions had some degree of infection, tissue damage and ulceration. At the end of the treatment (topical chitosan) period, the infections were cured. All patients experienced a significant improvement in the initial injury and developed granulation tissue and a healthy skin cover. This report represents one of the few published clinical experience regarding the chitosan for the treatment of skin lesions among diabetic subjects. These results are relevant and promising for the treatment of this disease.

© 2017 The Authors. Production and hosting by Elsevier B.V. on behalf of King Saud University. This is an open access article under the CC BY-NC-ND license (<http://creativecommons.org/licenses/by-nc-nd/4.0/>).

## 1. Introduction

Diabetic foot is a common complication among patients with diabetes mellitus (DM) (Boada, 2012). Diabetic foot is one of the heaviest and most debilitating financial burdens, not only for the sufferer, but for the family and health system (Brito-Zurita et al., 2013; Odhayani et al., 2017). Some of the complications associated with diabetic foot include infections, ulcers, gangrene and extremity amputation (in severe cases) (Rubio et al., 2012). For mild infections, *Staphylococcus aureus* is present in 80–90% of lesions, whereas *Enterococcus spp.* and *Pseudomonas spp.* are responsible for moderate-to-severe infections (Dai et al., 2010). The treatment options for diabetic foot include substances with local effects, such as hyper-oxygenated fatty acids, silicone, alginates, different antiseptics, carbon dressings, silver, and collagen.

Peer review under responsibility of King Saud University.



Production and hosting by Elsevier

\* Corresponding author at: 5 de Febrero 818 Sur, 85000 Ciudad Obregón, Sonora, Mexico.

E-mail address: [dalia.sanchez@itson.edu.mx](mailto:dalia.sanchez@itson.edu.mx) (D.I. Sánchez-Machado).

The use of synthetic acellular biomaterials for replacing skin has recently been introduced (Dieckmann et al., 2010). Among these biomaterials, chitosan, which is a polysaccharide composed of amino sugars, has a low risk of toxicity and immune response (Dieckmann et al., 2010). Chitosan is a biodegradable linear polymer that is non-toxic to mammals and is obtained by partial deacetylation of chitin (Sánchez-Duarte et al., 2012). Chitosan is a naturally occurring compound and is present in the coating of some mollusks and insects. Chitosan is comprised of glucosamine and N-acetyl-D-glucosamine linked by  $\beta$ -(1 → 4) glycosidic bonds (Aytekin et al., 2011) and is insoluble in water and soluble in acidic solutions (pH < 6.5). The properties of chitosan depend on molecular weight, deacetylation degree and ionic strength of the molecules (Dutta et al., 2009). Due to its cationic nature, chitosan has antimicrobial activity against a wide range of microorganisms, such as *Escherichia coli*, *Salmonella typhimurium*, *Staphylococcus aureus* and *Listeria monocytogenes* (Rodríguez-Núñez et al., 2014). Among the properties observed in the tissues where it has been used, chitosan allows blood to clot quickly and has recently gained approval in the United States for use in bandages and other hemostatic agents (Rabea et al., 2003).

Several animal studies have been performed using chitosan, and this product has proven superior to others in eliminating infection

<http://dx.doi.org/10.1016/j.sjbs.2017.03.017>

1319-562X/© 2017 The Authors. Production and hosting by Elsevier B.V. on behalf of King Saud University.

This is an open access article under the CC BY-NC-ND license (<http://creativecommons.org/licenses/by-nc-nd/4.0/>).

and promoting tissue healing compared to frequently used compounds by physicians (Dai et al., 2010). However, few clinical studies have been performed using chitosan for the treatment of skin ulcers. Valentine et al. (2010) tested 40 subjects who underwent chitosan treatment for hemostasis and wound repair subsequent to endoscopic surgery. The authors observed decreased bleeding times from the wounds. Later, Velazco et al. (2012) reported the application of dressings made with chitosan on patients with diabetic foot complications. The granulation process begins at eight days after dressing placement and at 22 days there was decrease in the size of the lesion. At 45 days, the total closure of the ulcer was observed. Furthermore, the dressings were completely biodegradable. Due to the current evidence, we evaluated chitosan topical gel and film treatments for diabetic patients with wounds and ulcers associated with diabetes mellitus.

## 2. Materials and methods

Utilizing a pre-experimental study design, we describe the results of administering chitosan gel and film to wounds and ulcers to patients with long-standing diabetes mellitus.

### 2.1. Obtaining chitosan

Chitosan was obtained from the deacetylation of chitin using the methodology proposed by Correa-Murrieta et al. (2012) according to the following procedure. First, the raw chitin was isolated by lactic acid fermentation of the shrimp head. For its purification, the chitin was desmineralized with chlorhydric acid 1 M (1:15 w/v) at 27 °C for 4 h. Then, the solid was desproteinized with NaOH 4.5% at 65 °C for 4 h. Finally, the chitin was deacetylated with NaOH 45% at 110 °C for 1:30 h. All steps were with constant agitation. The moisture content was adjusted by drying the sample in an oven (Felisa, Zapopan, Jalisco, Mexico) at 60 °C for 5 h until achieving a constant weight. The ash content was determined on a Barnstead Thermolyne muffle (Madison, Iowa, USA) at 550 °C for 5 h until obtaining a gray powder. The protein content was determined by a spectrophotometric method based on adding the colorant Comassie Blue G-250 to the proteins. The deacetylation degree (DD) was determined by UV spectrophotometry according to the method proposed by Liu et al. (2006) using glucosamine and N-acetyl glucosamine standards. The viscosity was determined with an Ostwald viscometer (Vineland, Nueva Jersey, EE. UU.) in a water bath at  $21 \pm 1.0$  °C. The molecular weight determination was performed according to the method proposed by Solis et al. (2007). For this determination, chitosan solution with a 0.0014 g/mL concentration was calculated by the method of Mark-Houwink (Wagner, 1985).

### 2.2. Chitosan gel and film preparation

Chitosan gel was prepared at 2%. For this, two grams of chitosan were added to 100 mL of acetic acid 1% and were stirred for 12 h.

Chitosan films were prepared by casting method according to the methodology proposed by Rodríguez-Núñez et al. (2014) with minor modifications. Those were made to base from chitosan gel 2%, specifically, 4 ml this solution were poured onto polypropylene plates and dried at 60 °C for 12 h. Finally, the films was removed from the mold and stored in sterile plastic bags (Whirl-Pak®).

### 2.3. Samples and subjects

A group of subjects with wounds and ulcerations associated with diabetes mellitus attended the sports medicine clinic at the Instituto Tecnológico de Sonora in Ciudad Obregón, Sonora (NW

Mexico) between January and December 2014. Subjects had wound or skin ulceration with a 2nd and 3rd degree risk according to the classification proposed by Heus van Putten et al. (1996). These patients were referred by friends and supporters of the university, and they freely requested to receive treatment. All patients were questioned about their epidemiological history related to their illness. Subjects with a risk greater than the 3rd degree (according to the Wagner classification) were excluded in order to avoid exposing them to any unnecessary risk. In addition, consent was obtained from all participants.

### 2.4. Healing protocol

The injured tissue was washed with a physiological saline solution at 0.9% (Pisa, Guadalajara, Jalisco, Mexico) and dried with a sterile gauze. Subsequently, some chitosan gel 2% was spread on the wound using a sterile syringe, allowed to rest for 1 min, and a chitosan film was then immediately placed on the wound. Finally, a band was applied to hold the chitosan film in place. The procedure was repeated every 48 h for the duration of the study. The follow-up period lasted 3 months for each subject in this study.

### 2.5. Clinical response analysis

Visual evidence regarding the wound was obtained at each visit when removing the healing material, any variations in the shape and size of the ulcer were recorded. The evaluation was qualitative, and improvement was regarded as a decrease in ulcer size, presence of granulated tissue and absent or decreased wound infection. Moreover, healing was regarded as wound scarring with an apparent absence of infection or necrotic tissue.

## 3. Results and discussion

### 3.1. Characterization of chitosan

The physicochemical composition of chitosan is related to its quality and functional properties. The ash, protein and moisture content were  $0.15 \pm 0.03\%$ ,  $0.25 \pm 0.01\%$  and  $13.69 \pm 0.03\%$ , respectively. Supplementary characteristics of chitosan included the deacetylation degree ( $97.02 \pm 0.30\%$ ), molecular weight ( $153.15$  kDa) and viscosity (range  $1119.62$ – $3655.09$  cP).

The purity level of chitosan affects its biological properties, solubility and stability (Szymanska and Winnicka, 2015). For biomedical applications the chitosan should be of high purity. Knowledge of the degree of deacetylation allows to predict the biological functionality of the chitosan. As the degree of deacetylation increases, the rate of inflammatory response in the ulcer decreases. Also, this parameter usually has an impact on the immunogenic behavior of the polymer (Kurita et al., 2000). The molecular weight depends mainly on the extraction process and can be determine its antimicrobial properties. It has been reported that lower molecular weight chitosan is able to penetrate into the cell and destroy the microorganism (Hosseinnejad and Jafari, 2016). The chitosan of this research has low molecular weight chitosan, which may induce the destruction of the microorganisms that generate infection in ulcers. Pillai et al. (2009) reported viscosity values in a range of 200–2000 cps and this variation is related to the molecular weight and degree of deacetylation of chitosan.

### 3.2. Characterization chitosan films

The films were a light yellow color, smooth at the surfaces, uniform and with an average transparency value of  $1.40 \pm 0.10$ . The

diameter of the films was  $5.32 \pm 0.04$  cm, the thickness  $0.08 \pm 0.01$  mm and the weight  $0.07 \pm 0.01$  g.

Miranda et al. (2003) report a thickness in chitosan films at 2% of 0.015 mm, but, the thicknesses were reduced to 0.012 mm when films were neutralized. This because the neutralization causes precipitation of the polymer. Bierhalz et al. (2016) reported thickness range of  $55 \pm 5$ – $66 \pm 5$   $\mu\text{m}$  in chitosan films with alginate. The thickness, weight and diameter variations depending on the concentration of chitosan and the volume used for the production of the films. Fernández-Pan et al. (2015) made films at 1% with chitosan from different molecular weights, the thicknesses obtained were of  $72.9 \pm 1.8$  (400 kDa),  $70.6 \pm 1.3$  (180 kDa) y  $68.5 \pm 2.1$  (41 kDa)  $\mu\text{m}$ .

Transparency is an essential parameter in films when they are used for healing, because this allows to observe through them the evolution of wounds. Hosseini et al. (2013) reported 0.95 transparency in films from chitosan at 1.5%, similar to what was found in this research. As the transparency value increases the film tends to be more opaque.

### 3.3. Clinical response analysis

Eight diabetic subjects received treatment. The average age was  $66 \pm 14$  years. Among the observed comorbidities, 3 patients experienced venous insufficiency and rheumatoid arthritis. For 3 of the 8 patients, the wound had been present for a year or more. The general characteristics of the subjects are presented in Table 1.

The majority of lesions were ulcerative lesions located in one of the lower limbs (6 of 8 patients). According to the Wagner classification, 5 lesions were ulcers that compromised the entire thickness of skin tissue without affecting the underlying muscle, and 3 were ulcerated, deep lesions that reached the muscle and ligaments without compromising the bone. No abscesses were observed,

although most of the cases treated (7 of 8) had some degree of local infection. The clinical course of chitosan treatment after more than 6 months of follow-up is presented in Table 2.

This pilot study reports our experience with topical chitosan to treat eight patients with wounds and ulcers associated with diabetes mellitus. The observed results show that chitosan can be a useful and safe treatment for these injuries in the diabetic patient. Our observations are supported by experimental studies in animal models in which the use of chitosan decreased microbial growth against gram-negative and gram-positive bacteria (Rabea et al., 2003; Burkatovskaya et al., 2006).

At the end of the treatment period, only one patient had experienced complete healing of the lesion, and the other patients experienced a significant improvement in their lesions. None of the patients had any complications with the performed procedure. A lesion example is presented at the start and finish of the monitoring period in subjects treated with chitosan (Figs. 1 and 2).

Importantly, most subjects experienced rapid recovery from their injuries during our study. Some of these patients had ulcerations for over a year despite various medical treatments without positive results. Other subjects had advanced infections. After chitosan application, the antibacterial effect was obvious according to our injury tracking data.

The development of ulcerations with delayed wound healing in diabetics is a frequent complication associated with damage to the microcirculation of the tissue. This complication increases treatment (Shobhana et al., 2000) cost and the risk of amputation. Often, ulcers appear on a background of neuropathy (motor, sensory or autonomic) with or without vascular insufficiency and infection (Siavash et al., 2011). Numerous treatments have been tested for diabetic ulcers (White et al., 2006). However, many of the materials that have been developed to treat diabetic foot ulcers are extremely toxic for the host (Nanney and Bennett, 2002), and

**Table 1**  
General characteristics of the study subjects.

|   | Gender | Age | Comorbidity          | Evolution (days) | Occupation     | Wound       | Location |
|---|--------|-----|----------------------|------------------|----------------|-------------|----------|
| 1 | Female | 73  | None                 | 30               | Housewife      | Ulcer       | Toe/foot |
| 2 | Female | 55  | Venous insufficiency | >365             | Salesperson    | Ulcer       | Ankle    |
| 3 | Male   | 63  | Venous insufficiency | >365             | Factory worker | Ulcer       | Foot     |
| 4 | Male   | 49  | None                 | –                | Salesperson    | Ulcer       | Foot     |
| 5 | Female | 58  | Venous insufficiency | >365             | Factory worker | Ulcer       | Ankle    |
| 6 | Male   | 77  | None                 | 30               | Office worker  | Ulcer       | Hip      |
| 7 | Female | 92  | Rheumatic arthritis  | 365              | Housewife      | Ulcer       | Buttock  |
| 8 | Male   | 62  | None                 | 365              | Blacksmith     | Ulcer/wound | Arm      |

**Table 2**  
Clinical course of chitosan treatment after more than 6 months of follow-up.

|   | Location | Wagner <sup>a</sup> | Infection |       | Improvement/Healing | Complications |
|---|----------|---------------------|-----------|-------|---------------------|---------------|
|   |          |                     | Initial   | Final |                     |               |
| 1 | Toe/Foot | 1                   | Yes       | No    | Yes/No              | No            |
| 2 | Ankle    | 1                   | Yes       | No    | No/Yes              | No            |
| 3 | Foot     | 2                   | Yes       | No    | Yes/No              | No            |
| 4 | Foot     | 2                   | Yes       | No    | Yes/No              | No            |
| 5 | Ankle    | 1                   | Yes       | No    | Yes/No              | No            |
| 6 | Hip      | 1                   | No        | No    | Yes/No              | No            |
| 7 | Buttock  | 2                   | Yes       | No    | Yes/No              | No            |
| 8 | Arm      | 1                   | Yes       | No    | Yes/No              | No            |

Grade 0: Absence of foot ulcers in high-risk.

Grade 1: Superficial ulcer involving the entire skin thickness but not underlying tissues.

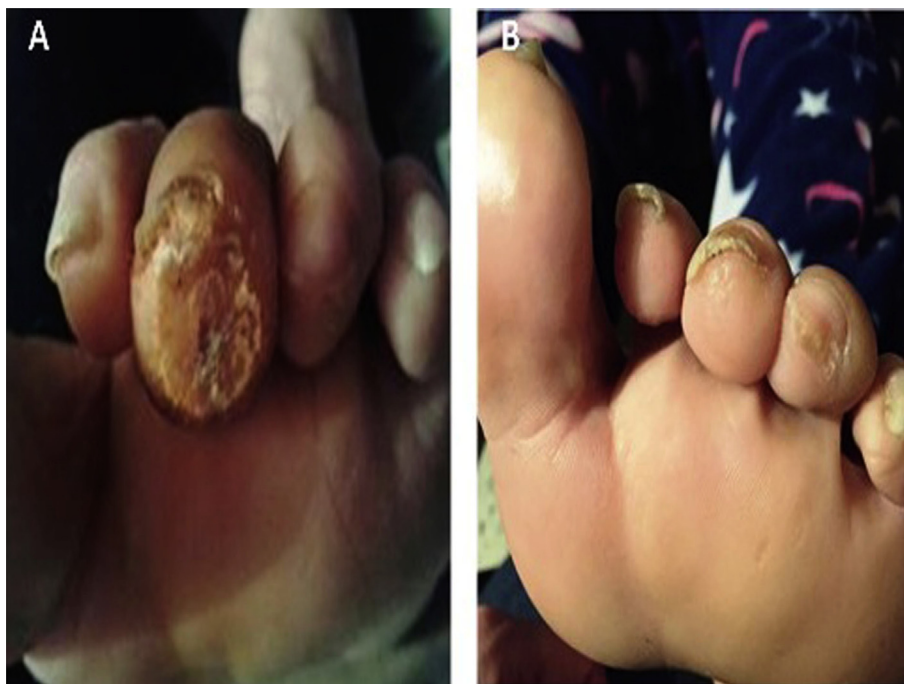
Grade 2: Deep ulcer, penetrating down to ligaments and muscles but no bone involvement or abscess formation.

Grade 3: Deep ulcer with cellulitis or abscess formation, often with osteomyelitis.

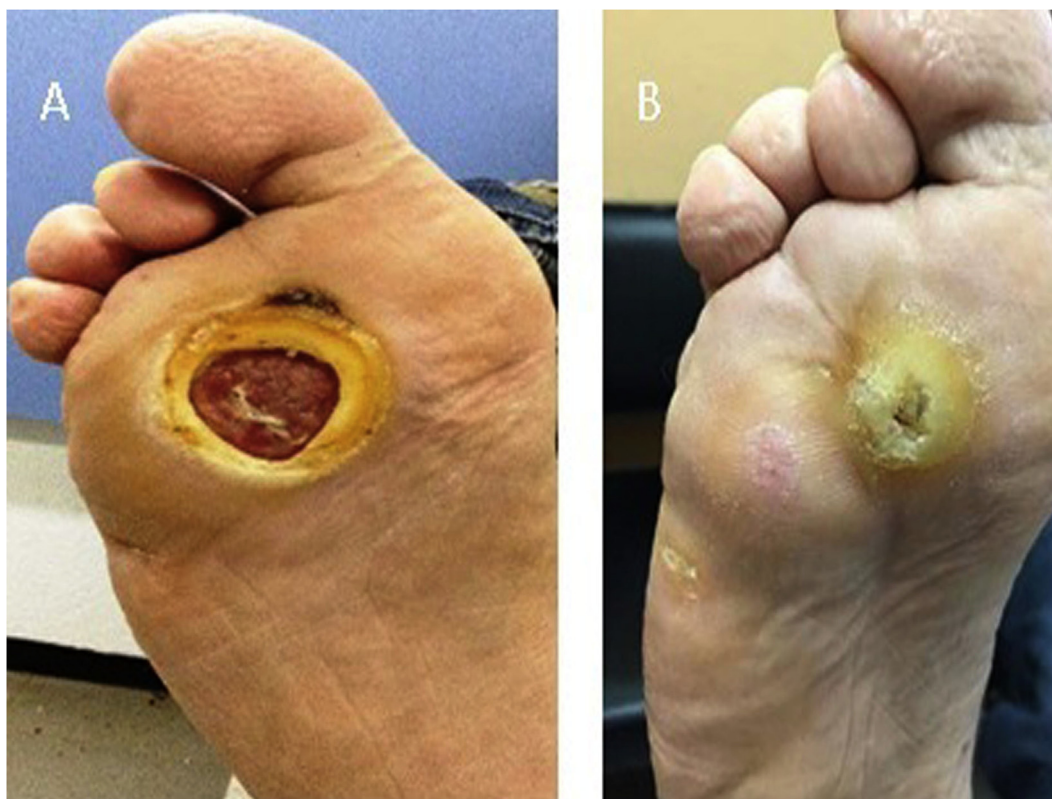Grade 4: Gangrene localized.

Grade 5: Extensive gangrene involving the entire foot.

<sup>a</sup> Wagner Classification of diabetic foot ulcers.



**Fig. 1.** A 73-year-old female with diabetic ulceration of the third toe of the left foot. (A) Prior to treatment, an initial Wagner grade 1 ulceration was observed on the left side of the toe. (B) After treatment with topical chitosan for 30 days, the wound closed, and no evidence of infection was observed.



**Fig. 2.** A 49-year-old male with a diabetic plantar ulceration of the right foot. (A) The initial ulceration observed on the left foot (A) was Wagner grade 2. (B) After treatment with topical chitosan for 90 days, almost complete closure of the lesion was observed without evidence of infection.

this toxicity interferes with the tissue repair process by increasing inflammation (Burkatovskaya et al., 2008).

Reports about the effects of chitosan for the treatment of skin ulcers include *in vitro* and *in vivo* models. Hamilton et al. (2006)

reported increased fibroblast proliferation (Hamilton et al., 2006). This finding may explain the beneficial effect of chitosan on wound healing, because fibroblasts are involved in fibroplasia and granulation tissue formation. Furthermore, the increase in extracellular

matrix (collagen and fibronectin) plays an important role in cell adhesion to the extracellular matrix to guide the migration of cells (Midwood et al., 2004).

Likewise, Mori et al. (2005) reported that chitosan activated macrophages by increasing the expression of major histocompatibility complex class I, class II, and various cell receptors associated with cell proliferation. Similarly, an X-ray experiment performed in dogs by Ueno et al. (2007) in which chitosan was applied to skin ulcers observed an increase in neovascularization. Kojima et al. (2004) reported an increase in collagen synthesis and prolyl hydroxylase enzyme activity in the presence of ascorbic acid (vitamin C, involved in the protein synthesis of extracellular matrix) (Midwood et al., 2004).

Further research will be needed to accurately assess the effects of chitosan on microcirculation and the formation of extracellular matrix and to evaluate the direct effect on the healing process. These investigations will require a formally planned study with a longer follow-up in diabetic subjects and a sample size that reduces interference bias and confounding factors.

In the investigations of our big project, this work will be complemented with trials to evaluate the sensitivity of microorganisms isolated from infected lesions of patients to chitosan films. As well as by the measurement of tissue pro-inflammatory factors. Also, the ulcers will be monitored with photographs every week to clarify doubts by clinical judgment.

#### 4. Conclusions

This report represents one of the few published clinical trials using chitosan for the treatment of skin lesions in diabetic subjects. We consider the results relevant and are evidenced the potential benefits of chitosan in the treatment of chronic ulcers. The preparation of these biomaterials of chitosan is simple and economic, which will allow its mass production. The application of the chitosan films can directly impact in the cost for the treatment of the diabetic foot, surgeries for amputation and in the days of medical incapacity.

#### Financing

This research was funded by the Instituto Tecnológico de Sonora (Project PROFAPI-00471) and by the National Council for Science and Technology (PDCPN2014: 248160).

#### Conflicts of interests

The authors declare no conflicts of interest.

#### Acknowledgments

PhD scholarship from: CONACYT (CVU 417707: AA Escárcega-Galaz and PRODEP (ITSON – 426: DI Sánchez-Machado). We thank Dr. Enrique Ruiz Sabag for his observations and technical support during the development of clinical evaluations for the patients included in this study.

#### References

Aytekin, A., Morimura, S., Kida, K., 2011. Synthesis of chitosan-caffeic acid derivatives and evaluation of their antioxidant activities. *J. Biosci. Bioeng.* 111 (2), 212–216.

Bierhalz, A.C.K., Buzatto, C., Moraes, A., 2016. Comparison of the properties of membranes produced with alginate and chitosan from mushroom and from shrimp. *Int. J. Biol. Macromol.* 91, 496–504.

Boada, A., 2012. Lesiones cutáneas en el pie diabético. *Actas Dermos.* 103 (5), 348–356.

Brito-Zurita, O.R., Ortega-López, S., López del Castillo-Sánchez, D., Vázquez-Téllez, A. R., Ornelas-Aguirre, J.M., 2013. Índice tobillo-brazo asociado a pie diabético. *Estudios de casos y controles. Cir Cir* 81, 131–137.

Burkatovskaya, M., Castano, A.P., Demidova-Rice, T.N., Tegos, G.P., Hamblin, M.R., 2008. Effect of chitosan acetate bandage on wound healing in infected and noninfected wounds in mice. *Wound Repair Regen.* 16 (3), 425–443.

Burkatovskaya, M., Tegos, G.P., Swietlik, E., Demidova, T.N., Castano, A.P., Hamblin, M.R., 2006. Use of chitosan bandage to prevent fatal infections developing from highly contaminated wounds in mice. *Biomaterials* 27, 4157–4164.

Correa-Murrieta, M.A., López-Cervantes, J., Sánchez-Machado, D.I., Sánchez-Duarte, R.G., Rodríguez-Núñez, J., Núñez-Gastélum, J., 2012. Fe(II) and Fe(III) adsorption by chitosan-tripolyphosphate beads: kinetic and equilibrium studies. *J. Water Supply Res. Tech.* 61 (6), 331–341.

Dai, T., Huang, Y., Sharma, S., Hashmi, J.T., Kurup, D.B., Hamblin, M.R., 2010. Topical antimicrobials for burn wound infections. *Recent Pat. Antiinf. Drug Discov.* 5 (2), 124–151.

Dieckmann, C., Renner, R., Milkova, L., Simon, J.C., 2010. Regenerative medicine in dermatology: biomaterials, tissue engineering, stem cells, gene transfer and beyond. *Exp. Dermatol.* 19, 697–706.

Dutta, P., Tripathi, S., Mehrotra, G., Dutta, J., 2009. Perspectives for chitosan based antimicrobial films in food applications. *Food Chem.* 114 (4), 1173–1182.

Fernández-Pan, I., Maté, J.I., Gardra, C., Coma, V., 2015. Effect of chitosan molecular weight on the antimicrobial activity and release rate of carvacrol-enriched films. *Food Hydrocolloid.* 51, 60–68.

Hamilton, V., Yuan, Y., Rigney, D.A., Puckett, A.D., Ong, J.L., Yang, Y., et al., 2006. Characterization of chitosan films and effects on fibroblast cell attachment and proliferation. *J. Mater. Sci. Mater. Med.* 17, 1373–1381.

Heus van Putten, M.A., Schaper, N.C., Bakker, K., 1996. The clinical examination of the diabetic foot in daily practice. *Diabetic Med.* 13, 555–558.

Hosseini, S.F., Rezaei, M., Zandi, M., Ghavi, F.F., 2013. Preparation and functional properties of fish gelatin-chitosan blend edible films. *Food Chem.* 136, 1490–1495.

Hosseinnejad, M., Jafari, S.M., 2016. Evaluation of different factors affecting antimicrobial properties of chitosan. *Int. J. Biol. Macromol.* 85, 467–475.

Kurita, K., Kaji, Y., Mori, T., Nishiyama, Y., 2000. Enzymatic degradation of  $\beta$ -chitin: susceptibility and the influence of deacetylation. *Carbohydr. Poly.* 42, 19–21.

Kojima, K., Okamoto, Y., Kojima, K., Miyatake, K., Fujise, H., Shigemasa, Y., et al., 2004. Effects of chitin and chitosan on collagen synthesis in wound healing. *J. Vet. Med. Sci.* 66, 1595–1598.

Liu, D., Wei, Y., Yao, P., Jiang, L., 2006. Determination of the degree of acetylation of chitosan by UV spectrophotometry using dual standards. *Carbohydr. Res.* 341, 728–785.

Midwood, K.S., Williams, L.V., Schwarzbauer, J.E., 2004. Tissue repair and the dynamics of the extracellular matrix. *Int. J. Biochem. Cell Biol.* 36 (6), 1031–1037.

Miranda, S.P., Cárcenas, G., López, D., Lara, A.V., 2003. Comportamiento de películas de quitosán compuesto en un modelo de almacenamiento de aguacate. *Rev. Soc. Qupim. Méx.* 47 (4), 331–336.

Mori, T., Murakami, M., Okumura, M., Kadosawa, T., Uede, F., Fujinaga, T., 2005. Mechanism of macrophage activation by chitin derivatives. *J. Vet. Med. Sci.* 67, 51–56.

Nanney, L.B., Bennett, L.L., 2002. Comparative evaluation of topical antiseptic/antimicrobial treatment on aspects of wound repair in the porcine model. *Ostomy Wound Manage. Suppl.*, 14–19.

Odhayani, A.A.A., Tayel, S.A.S., Al-Madi, F., 2017. Foot care practices of diabetic patient in Saudi Arabia. *Saudi J. Biol. Sci.* 24, 1667–1671.

Pillai, C.K.S., Paul, W., Sharma, C., 2009. Chitin and chitosan polymers: chemistry, solubility and fiber formation. *Prog. Polym. Sci.* 34, 641–678.

Rabea, E.I., Badawy, M.E., Stevens, C.V., Smagghe, G., Steurbaut, W., 2003. Chitosan as antimicrobial agent: applications and mode of action. *Biomacromol* 4 (6), 1457–1465.

Rodríguez-Núñez, J.R., Madera-Santana, J., Sánchez-Machado, D.I., López-Cervantes, J., Soto, H., 2014. Chitosan/hydrophilic plasticizer-based films: preparation, physicochemical and antimicrobial properties. *J. Polym. Environ.* 22, 41–51.

Rubio, J., Jiménez, S., Martínez-Izquierdo, M., Guadalupe, G., 2012. Infección necrotizante en el pie diabético: una urgencia que amenaza la pérdida de la extremidad. *Endocrinol. Nutr.* 59 (7), 466–468.

Sánchez-Duarte, R.G., Sánchez-Machado, D.I., López-Cervantes, J., Correa-Murrieta, M.A., 2012. Adsorption of allura red dye by crosslinked chitosan from shrimp waste. *Water Sci. Technol.* 65 (4), 618–623.

Shobhana, R., Rama, R.P., Lavanya, A., Viswanathan, V., Ramachandra, A., 2000. Cost burden to diabetic patients with foot complications: a study from southern India. *JAPI* 48, 1147–1150.

Siavash, M., Shokri, S., Haghghi, S., Mohammadi, M., Ali Shahtalebi, M., Farajzadehgan, Z., 2011. The efficacy of topical Royal Jelly on diabetic foot ulcers healing: a case series. *J. Res. Med. Sci.* 16 (7), 904–909.

Szymanska, E., Winnicka, K., 2015. Stability of chitosan—a challenger for pharmaceutical and biomedical applications. *Mar. Drugs* 3, 1819–1846.

Solis, Y., Peniche, C., García, R., Davidenko, N., 2007. Un procedimiento biomimético novedoso para obtener composites de quitosana-hidroxiapatita. VII Congreso de la Sociedad Cuaba de Bioingeniería Habana.

- Ueno, H., Ohya, T., Ito, H., Kobayashi, Y., Yamada, K., Sato, M., 2007. Chitosan application to X-ray irradiated wound in dogs. *J. Plast. Reconstr. Aesthet. Surg.* 60, 304–310.
- Valentine, R., Athanasiadis, T., Moratti, S., et al., 2010. The efficacy of a novel chitosan gel on hemostasis and wound healing after endoscopic sinus surgery. *Am. J. Rhinol. Allergy* 24 (1), 70–75.
- Velazco, G., Gonzalez, A., Ortiz, R., 2012. Chitosan films for the diabetic foot treatment. *Avan. Biomed.* 1 (1), 38–41.
- Wagner, H.L., 1985. The Mark-Houwink-Sakurada equation for the viscosity of atactic polystyrene. *J. Phys. Chem. Ref. Data* 14 (4), 1101–1106.
- White, R.J., Cutting, K., Kingsley, A., 2006. Topical antimicrobials in the control of wound bioburden. *Ostomy Wound Manage.* 52, 26–28.