

Uridine triacetate for severe 5-fluorouracil toxicity in a patient with thymidylate synthase gene variation: Potential pharmacogenomic implications

SAGE Open Medical Case Reports
Volume 6: 1–4
© The Author(s) 2018
Reprints and permissions:
sagepub.co.uk/journalsPermissions.nav
DOI: 10.1177/2050313X18786405
journals.sagepub.com/home/sco



Candice Baldeo, Prakash Vishnu, Kabir Mody
and Pashtoon Murtaza Kasi

Abstract

Adverse drug reactions can be unpredictable. However, pharmacogenomic testing can help identify patients who may be more susceptible to the toxic effects of certain drugs. Genetic variations in the dihydropyrimidine dehydrogenase and thymidylate synthase genes have been shown to increase the risk of 5-fluorouracil toxicity. 5-Fluorouracil toxicity can be life threatening. Fortunately, there is treatment available for 5-fluorouracil toxicity, called uridine triacetate. Although, the indications for its use limit its administration to within 96 h of receiving 5-fluorouracil, we report a case of effective therapy in a patient started on uridine triacetate beyond the recommended 96 h, who was found to carry a thymidylate synthase gene variation but no dihydropyrimidine dehydrogenase mutations. This provides important implications for pharmacogenomic testing.

Keywords

Oncology, pharmacogenomics, uridine triacetate, 5-fluorouracil toxicity

Date received: 4 February 2018; accepted: 11 June 2018

Introduction

Fluorouracil (5-FU) and capecitabine are cytotoxic antimetabolites. They result in disruption of nucleic acid metabolism in cells, where 5-FU is converted to the intermediates 5-fluoro-2'-deoxyuridine-5'-monophosphate and 5-fluorouridine triphosphate. 5-Fluoro-2'-deoxyuridine-5'-monophosphate inhibits thymidylate synthase (*TYMS*), affecting production of thymidine and ultimately, DNA replication and repair. 5-Fluorouridine triphosphate causes its cytotoxic effects by affecting RNA. Studies have reported a 0.5% incidence of mortality from 5-FU- or capecitabine-based regimens.

Uridine triacetate is a pyrimidine analog and acetylated prodrug of uridine. Uridine competitively inhibits cell death caused by 5-FU. Uridine triacetate delivers four- to six-fold more uridine into systemic circulation than equimolar doses of uridine alone. Furthermore, when given orally, uridine triacetate's time-to-peak plasma concentration is 2–3 h.¹ Uridine is converted to uridine triphosphate, which competes with 5-fluorouridine triphosphate for incorporation into RNA.

We present a case of severe 5-FU toxicity which was treated with uridine triacetate beyond the recommended 96-h

interval after receiving 5-FU. The rationale behind this was the presence of the *TYMS* gene variation (2R/3RC genotype), as an etiology for 5-FU toxicity, as a result of decreased metabolism.

Case presentation

A 56-year-old white woman presented with a history of several years of constipation. After months of rectal bleeding and rectal pain, an anal biopsy showed severe squamous dysplasia and carcinoma in situ. She initially opted for topical treatment with imiquimod, but her symptoms persisted. A repeat anal biopsy was done 1 month after completing

Division of Hematology and Oncology, Mayo Clinic Jacksonville, Jacksonville, FL, USA

Corresponding Author:

Pashtoon Murtaza Kasi, Division of Hematology and Oncology, Mayo Clinic Jacksonville, 4500 San Pablo Road, Jacksonville, FL 32224, USA.
Email: kasi.pashtoon@mayo.edu



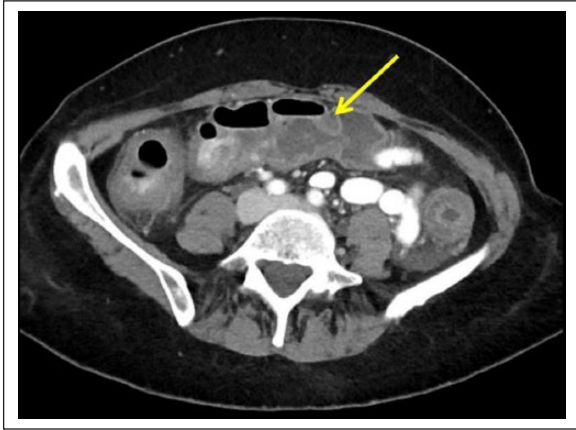

Figure 1. Diffuse colitis seen on computed tomography image (arrow).

treatment, revealing one site positive for invasive squamous cell carcinoma. Magnetic resonance imaging of the abdomen and pelvis did not show any definitive anal mass. Positron emission tomography/computed tomography showed abnormal uptake in the anorectal region. Human immunodeficiency virus serology was nonreactive.

The patient was started on definitive chemoradiation therapy with a plan for a 3060-cGy dose (180 cGy/fraction, total of 17 fractions), together with mitomycin C (10 mg/m² = 16 mg given on day 1) and 5-FU (4000 mg/m² = 6320 mg administered over 4 days from day 1 to day 4). Within 24 h of starting chemoradiation therapy, she began experiencing severe diarrhea. She reported at least eight episodes of loose, watery stools per day with intermittent streaks of bright red blood and concomitant stool incontinence. She also had crampy abdominal pain with each diarrheal episode. Daily doses of loperamide and atropine/diphenoxylate were started without adequate symptom relief. Octreotide was added, but did not provide additional relief. She had nausea, but denied any vomiting or fevers. She was placed on ondansetron and promethazine which only minimally helped. Subsequently, she developed oropharyngeal mucositis with little relief from the mouthwash formulation which was prescribed, which was composed of diphenhydramine, viscous lidocaine and nystatin suspension.

Blood tests revealed severe neutropenia and thrombocytopenia, with an absolute neutrophil count of $0.34 \times 10^9/L$; platelet count, $60 \times 10^9/L$ and hemoglobin, 9.6 g/dL. She was hospitalized on day 9 (5 days post completion of 5-FU infusion) for further management of her gastrointestinal (GI) symptoms and cytopenias. Computed tomography of the abdomen and pelvis showed diffuse colitis involving the entire colon and rectum (Figure 1). *Clostridium difficile* testing was negative, and empiric broad-spectrum antibiotics were started.

The rapid onset of adverse effects from GI toxicity and cytopenias prompted pharmacogenomic testing for 5-FU

sensitivity. Genotype testing for mutations in dihydropyrimidine dehydrogenase (*DPYD*) deficiency and *TYMS* was done. However, the severity of symptoms necessitated treatment with uridine triacetate 10 g orally every 6 h which was started 7 days after the last administration of 5-FU. The antidote was ordered 6 days post last infusion of 5-FU but given 7 days post infusion, since it is not readily stocked. A total of 20 doses were administered. Within 12 h of initiation of uridine triacetate, the patient noted a decrease in volume of each diarrheal episode. She also reported improvement in her crampy abdominal pain within the next 2 days. An increase in her white blood cell and neutrophil counts was seen about 2 days after starting treatment (Figure 2). 5-FU sensitivity genotype testing eventually showed the presence of a *TYMS* gene variation (2R/3RC genotype). There were no *DPYD* polymorphisms.

By completion of uridine triacetate treatment, the patient's stools had become more formed, with a notable decrease in number of bowel movements to about three per day. She no longer experienced stool incontinence. She discharged from the hospital with close follow-up in the outpatient clinic. After about a week, her GI symptoms had completely resolved and blood counts had returned to baseline. She resumed radiation therapy only and completed 9 weeks of treatment. The planned second dose of chemotherapy was not given due to the severe side effects.

At 6-month follow-up, there was no residual disease with direct visualization using anoscopy.

Discussion

Each year, hundreds and thousands of patients in the United States are treated with either 5-FU or capecitabine for a variety of malignancies, including multiple GI malignancies and breast cancer.² According to the National Institutes of Health (NIH), roughly 275,000 patients in the United States receive 5-FU every year, and capecitabine, a prodrug enzymatically converted to 5-FU, has about 60,000 treatment packages sold per year.³ Approximately 3% of these patients develop serious toxicities, and more than 8000 toxic reactions and 1300 deaths every year are attributed to 5-FU and capecitabine.³

There are multiple adverse effects associated with 5-FU, including GI symptoms such as abdominal pain, diarrhea and mucositis; hematologic effects such as myelosuppression and central nervous system symptoms. Genetic variations causing *DPYD* deficiency have been known to predispose patients to the toxic effects of 5-FU and capecitabine. However, little is known about gene variations of *TYMS* resulting in 5-FU toxicity.⁴

Uridine triacetate was approved by the US Food and Drug Administration (FDA) in December 2015 to treat overdoses and early-onset, severe or life-threatening toxicities from 5-FU.⁵ The FDA approved emergency treatment with uridine triacetate for adults and pediatric patients within 96 h after 5-FU or capecitabine administration, who present either (1)

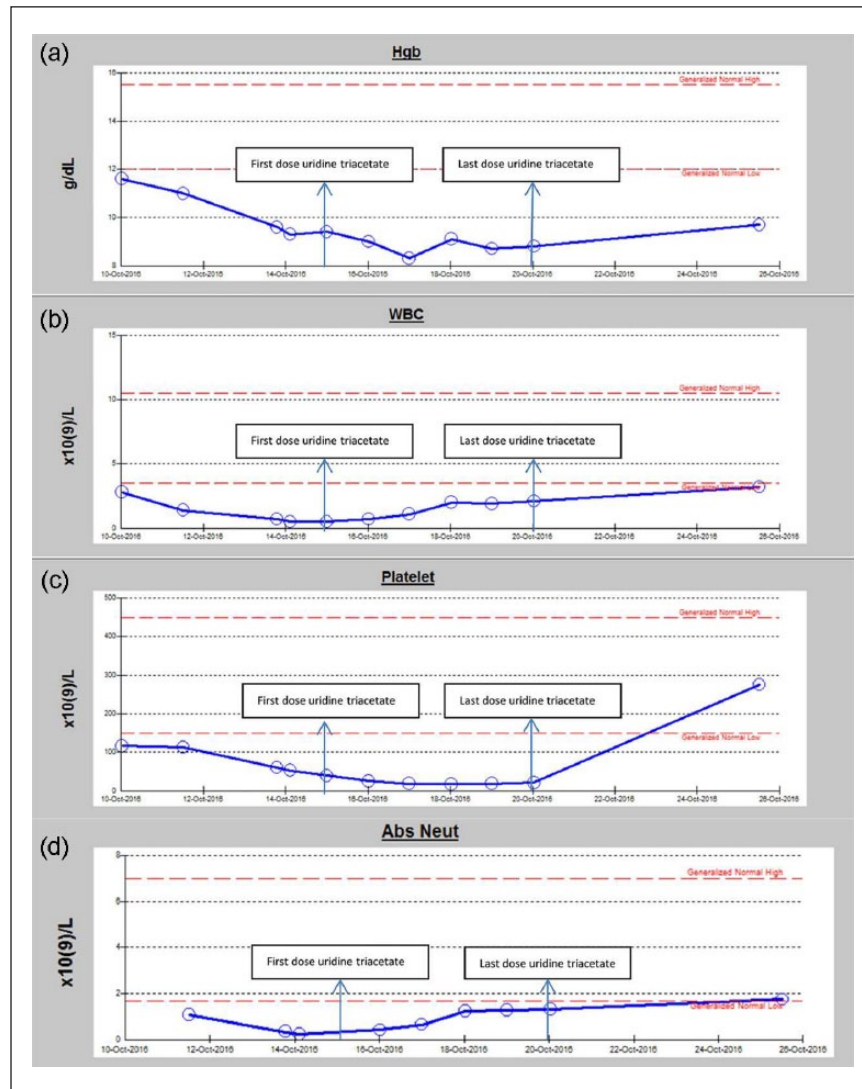


Figure 2. Different cell lines and response to therapy: (a) pattern of hemoglobin, (b) white blood cell counts, (c) platelet and (d) absolute neutrophil count after receiving 5-FU. Abs Neut: absolute neutrophil; Hgb: hemoglobin; WBC: white blood cell.

following a 5-FU or capecitabine overdose, even in the absence of symptoms, or (2) early-onset, severe or life-threatening toxicity or unusually severe adverse effects.⁵ In a clinical trial of 135 patients with 5-FU toxicity who received treatment with uridine triacetate within 96h of administration of 5-FU, approximately 96% survived and about half were able to resume their chemotherapy regimens within 3 weeks after overexposure.³ Our case describes successful treatment of 5-FU overdose with uridine triacetate in a patient beyond 96h of administration of 5-FU.

Cases of *DPYD* gene deficiency benefiting from uridine triacetate have already been reported.⁶ *DPYD* deficiency occurs due to mutations in the *DPYD* gene. Patients with these mutations are prone to 5-FU poisoning and hence, dose reductions or avoidance of 5-FU altogether may be warranted.⁷ There have been variations in the reported prevalence of *DPYD* across multiple studies. Population studies

indicate that at least 3% of the general population could be partially deficient for *DPYD* enzyme activity. Approximately 3%–5% of white patients have partial *DPYD* deficiency and 0.2% have complete *DPYD* deficiency.⁷

TYMS is an enzyme involved in conversion of deoxyuridylate to deoxythymidylate, part of DNA synthesis. 5-FU irreversibly inhibits *TYMS*.⁵ The variation of *TYMS* gene expression has been shown to influence response to 5-FU, with lower levels of expression showing improved responses and a greater risk of toxicity.⁴ Conversely, higher levels of expression of *TYMS* are associated with a poorer response and interestingly, less 5-FU toxicity.⁴ The prevalence of *TYMS* variants associated with 5-FU toxicity is not well documented.

Drug adverse effects are often unpredictable in severity and frequency. The importance of pharmacogenomic testing in identifying patients who are at greater risk of toxicity cannot

be overemphasized. Results of pharmacogenomic testing can be used to individualize care by appropriately adjusting drug doses to avoid these adverse effects. The total cost of hospitalization for this patient exceeded US\$180,000. This case highlights the cost-effectiveness of incorporating pharmacogenomic testing in real practice. Our recommendation would be to do the same for patients receiving fluoropyrimidine-based regimens to test for *DPYD* and *TYMS* gene mutations.

Furthermore, our case demonstrates the importance of identifying 5-FU toxicity promptly, especially with the advent of an FDA-approved treatment. In addition, in the study which led to the approval of uridine triacetate, it allowed for the resumption of chemotherapy within 30 days, indicating prompt recovery.⁸

Our case report underlines the importance of pharmacogenomic testing for *TYMS* and *DPYD* mutations to help personalize therapy and prevent toxicity in these patients. Another case was recently reported by Zurayk et al.⁹ The rationale for using the antidote beyond the recommended 96 h was due to the decreased metabolism of 5-FU which results in prolonged exposure as in our case. Therefore, successful use of uridine triacetate usage beyond the recommended 96 h treatment window should hopefully support its use to manage these detrimental effects of 5-FU toxicity.

An important limitation to note is that even with the relief of symptoms coinciding with the administration of uridine triacetate, causation in this case cannot be completely determined. Further studies are needed in order to explore the use of uridine triacetate after the 96-h period. We looked at our own data at Mayo Clinic Jacksonville and found that a higher prevalence of gene variants (*UGT1A1* and *DPYD*) was reported in our patient cohort than what is reported in the literature.¹⁰ Consideration may be given to administer uridine triacetate when pharmacogenomic testing reveals mutations implicated in decreased clearance of 5-FU.

Conclusion

In conclusion, physicians should promptly recognize and treat 5-FU poisoning with uridine triacetate, the only FDA-approved specific treatment available for this toxicity. However, prompt recognition may be challenging, as symptoms related to 5-FU toxicity may be delayed and may be due to underlying genetic alterations which take time to diagnose. Our case describes a patient with 5-FU-induced toxicity, who was successfully treated with uridine triacetate beyond the recommended 96 h after 5-FU administration.

Declaration of conflicting interests

The author(s) declared no potential conflicts of interest with respect to the research, authorship and/or publication of this article.

Funding

The author(s) received no financial support for the research, authorship and/or publication of this article.

Ethics approval

Our institution does not require ethical approval for reporting individual cases or case series.

Informed consent

Written informed consent was obtained from the patient for their anonymized information to be published in this article.

References

1. Cada DJ, Mbogu U, Bindler RJ, et al. Uridine triacetate. *Hosp Pharm* 2016; 51(6): 484–488.
2. Ison G, Beaver JA, McGuinn WD Jr, et al. *FDA approval: uridine triacetate for the treatment of patients following fluorouracil or capecitabine overdose or exhibiting early-onset severe toxicities following administration of these drugs*. *Clin Cancer Res* 2016; 22(18): 4545–4549.
3. Santos C, Morgan BW and Geller RJ. The successful treatment of 5-fluorouracil (5-FU) overdose in a patient with malignancy and HIV/AIDS with uridine triacetate. *Am J Emerg Med* 2017; 35(5): 802.e7–802.e8.
4. Wang B, Walsh SJ and Saif MW. Pancytopenia and severe gastrointestinal toxicities associated with 5-fluorouracil in a patient with thymidylate synthase (*TYMS*) polymorphism. *Cureus* 2017; 8(9): E798.
5. Wellstat Therapeutics Corporation. *Vistogard [package insert]*. Gaithersburg, MD: Wellstat Therapeutics Corporation, 2015.
6. Saif MW and Diasio RB. Benefit of uridine triacetate (Vistogard) in rescuing severe 5-fluorouracil toxicity in patients with dihydropyrimidine dehydrogenase (*DPYD*) deficiency. *Cancer Chemother Pharmacol* 2016; 78(1): 151–156.
7. He Z-X and Zhou S-F. Pharmacogenetics-guided dosing for fluoropyrimidines in cancer chemotherapy. *Adv Pharmacoepidemiol Drug Safety* 2014; 3(1): e125.
8. Ma WW, Saif MW, El-Rayes BF, et al. Emergency use of uridine triacetate for the prevention and treatment of life-threatening 5-fluorouracil and capecitabine toxicity. *Cancer* 2017; 123(2): 345–356.
9. Zurayk M, Keung YK, Yu D, et al. Successful use of uridine triacetate (Vistogard) three weeks after capecitabine in a patient with homozygous dihydropyrimidine dehydrogenase mutation: a case report and review of the literature. *J Oncol Pharm Pract*. Epub ahead of print 1 January. DOI: 10.1177/1078155217732141.
10. Baldeo C, Hughes C and Kasi PM. Feasibility and value of incorporating pharmacogenomic testing for genetic variants in *UGT1A1* and *DPYD* genes in patients receiving irinotecan and/or 5-fluorouracil chemotherapy. *J Clin Oncol* 2018; 36(Suppl. 4): 814.