

Biomechanical Testing of Scapular Spine Autograft for Anterior Glenoid Bone Augmentation

Marcus Mittelsteadt,* MD, Bradley J. Nelson,*[†] MD, Eric M. Rohman,* MD, Robert A. Arciero,[‡] MD, and Marc A. Tompkins,*^{†§} MD

Investigation performed at TRIA Orthopedic Center, Bloomington, Minnesota, USA, and University of Minnesota, Minneapolis, Minnesota, USA

Background: Augmentation of anterior glenoid defects with bone graft can improve shoulder stability and reduce the risk of redislocation. Several characteristics of the scapular spine may make it a suitable harvest site, avoiding the disadvantages associated with other glenoid augmentation procedures.

Purpose: To evaluate the capacity of scapular spine autograft to restore the stabilizing joint-reaction forces of the shoulder in simulated scenarios of bony anterior shoulder instability.

Study Design: Controlled laboratory study.

Methods: We obtained 6 matched pairs of fresh-frozen cadaveric shoulders. Skin, subcutaneous tissues, and non-rotator cuff muscles were removed from the specimens, leaving intact the rotator cuff musculature and shoulder capsule. A customized testing device was used to translate the humerus 1 cm anteriorly on the glenoid under 25 N of axial compression force. The peak joint-reaction force of the glenohumeral joint was then measured under 3 conditions: (1) specimen with intact glenoid, (2) specimen after a bone defect measuring 25% of the maximal width of the glenoid was made in the anteroinferior glenoid, and (3) specimen after size-matched glenoid augmentation with a scapular spine tricortical autograft. The primary outcome was the change in peak joint-reaction forces between the defect state and augmented state.

Results: One matched pair was removed from final analysis secondary to anatomic concerns that undermined the accuracy of test results. Among the 10 remaining specimens, all showed a significant decrease in peak joint-reaction force after the glenoid defect was created compared with the intact state ($P < .001$). All remaining specimens showed an increase in peak joint-reaction force in the augmented state compared with the defect state ($P < .001$). On average, the augmented state restored 81% of the peak reaction force of the glenohumeral joint compared with the intact state, a nonsignificant difference ($P = .07$).

Conclusion: The study findings indicated that autograft harvested from the scapular spine increased the bony restraint to anterior shoulder dislocation in shoulders with glenoid bone loss.

Clinical Relevance: The scapular spine is an alternative for bony augmentation of glenoid defects in shoulder instability.

Keywords: glenoid augmentation; shoulder instability; scapular spine

Dislocation of the glenohumeral joint is a common injury. Many patients with instability as a result of traumatic glenohumeral dislocation have associated bony lesions to the glenoid, so-called bony Bankart lesions, which, if not addressed adequately, can result in bone loss and increased risk for further instability. Patients can also have increasing bone loss with redislocations and resulting chronic instability. Although Bankart repair, open or arthroscopic, is a successful procedure in many cases of shoulder instability, multiple studies have documented that increasing

glenoid bone loss is a risk factor for recurrence of instability.^{1,5,6} In such cases, it has been shown that augmentation of these bony defects with bone graft can improve stability.^{7,9}

Reconstitution of these defects typically involves transfer of the coracoid process (Latarjet procedure), tricortical iliac crest autograft (Eden-Hybinette procedure), or allograft to the anterior glenoid. These procedures have demonstrated clinical and biomechanical success.^{2,7,8,16} However, each procedure has disadvantages that must be accounted for when performing anterior shoulder stabilization. The Latarjet procedure requires dissection directly adjacent to the important neurovascular structures of the upper extremity for harvest of the coracoid and alters the normal

The Orthopaedic Journal of Sports Medicine, 10(5), 23259671221096682

DOI: 10.1177/23259671221096682

© The Author(s) 2022

This open-access article is published and distributed under the Creative Commons Attribution - NonCommercial - No Derivatives License (<https://creativecommons.org/licenses/by-nc-nd/4.0/>), which permits the noncommercial use, distribution, and reproduction of the article in any medium, provided the original author and source are credited. You may not alter, transform, or build upon this article without the permission of the Author(s). For article reuse guidelines, please visit SAGE's website at <http://www.sagepub.com/journals-permissions>.

TABLE 1
Specimen, Defect, and Graft Information

Specimen	Sex	Age, y	Defect Size, Width × Length, mm	Augmented Bone Size, Depth × Length, mm
1	Female	54	6 × 2	6 × 25
2	Male	65	7 × 30	7 × 25
3	Female	50	7 × 28	7 × 25
4	Female	50	5 × 25	5 × 25
5	Female	60	7.5 × 30	7.5 × 25
6	Male	52	9 × 35	9 × 25
7	Male	61	7.5 × 30	7 × 25
8	Male	58	8.5 × 34	7 × 25
9	Male	58	10 × 35	9 × 25
10	Male	57	7 × 27	7 × 25

anatomic characteristics of the anterior shoulder. The Eden-Hybinette procedure is performed through a separate surgical field and is often associated with pain at the harvest site after surgery. Allograft procedures pose risks of decreased healing and incorporation.

A recent computed tomography study of scapular spine dimensions confirmed that the scapular spine had suitable dimensions as a bone block for glenoid reconstruction.¹³ Additionally, several characteristics of the scapular spine may make it a suitable harvest site, avoiding the disadvantages of other glenoid augmentation procedures, such as adequacy of tricortical bone stock, relative proximity to the shoulder compared with the iliac crest, anatomic ease of harvest, and lack of focal muscular attachments or intimate neurovascular structure.

In this study, we present biomechanical data on a surgical procedure using structural autograft from the scapular spine to augment bony defects of the anterior glenoid. Our aim was to evaluate the capacity of scapular spine autograft to restore the stabilizing joint-reaction forces of the shoulder in simulated scenarios of bony anterior shoulder instability. We hypothesized that the scapular spine would be an acceptable alternative for tricortical autograft in shoulder instability surgery.

METHODS

Specimens and Preparation

Ethics committee approval was waived for this cadaveric study. A total of 12 intact cadaveric shoulders (9 donors

[3 pairs]; 4 women, 5 men; age range, 50-65 years) were obtained. In addition, we obtained 1 pilot specimen that was predetermined not to be included in the study data but was used to ensure that the testing protocol was appropriate.

The primary outcome measure was peak joint-reaction force as determined under 3 test conditions: (1) specimen with an intact glenoid, (2) specimen after creation of an anterior defect in the glenoid bone measuring 25% of the anteroposterior diameter of the glenoid at its greatest width, and (3) specimen after a tricortical scapular spine autograft was affixed to the anterior glenoid at its defect. Table 1 provides specimen, defect, and graft information.

Skin and subcutaneous tissue were dissected from the shoulder specimens, leaving the rotator cuff musculature and shoulder capsule intact. The rotator cuff was found to be intact in all specimens, and no other pathology was found in the shoulders. The humeral diaphysis and angle of the scapula were then potted (Figure 1) for attachment to a customized testing device (Uniaxial MTS 858; Bionix).

Testing Conditions

The testing protocol was based on that used by Yamamoto et al¹⁷ in similar studies. Specimens were loaded to a customized testing device in 90° of external rotation and 90° of abduction (relative to the medial aspect of the scapula), an at-risk position for anterior shoulder dislocation (Figure 1). A total of 25 pounds (111 N) was applied perpendicular to the glenoid in a compressive load using weights (Figure 2).

§Address correspondence to Marc A. Tompkins, MD, Department of Orthopedic Surgery, University of Minnesota, 2450 Riverside Avenue South, Suite R200, Minneapolis, MN 55455, USA (email: tompkinsm@hotmail.com).

*Department of Orthopedic Surgery, University of Minnesota, Minneapolis, Minnesota, USA.

†TRIA Orthopedic Center, Bloomington, Minnesota, USA.

‡Department of Orthopedic Surgery, UConn Health, Farmington, Connecticut, USA.

Final revision submitted February 16, 2022; accepted February 25, 2022.

One or more of the authors has declared the following potential conflict of interest or source of funding: B.J.N. has received education payments from Arthrex and consulting fees from Marrow Access Technologies. R.A.A. has received research funding from Arthrex, education payments from Don-Joy, and consulting fees and stock options from Bio-rez. M.A.T. has received grant support from DJO and hospitality payments from Aesculap. AOSSM checks author disclosures against the Open Payments Database (OPD). AOSSM has not conducted an independent investigation on the OPD and disclaims any liability or responsibility relating thereto.

Ethical approval for this study was waived by the University of Minnesota (ref No. 1602M84102).

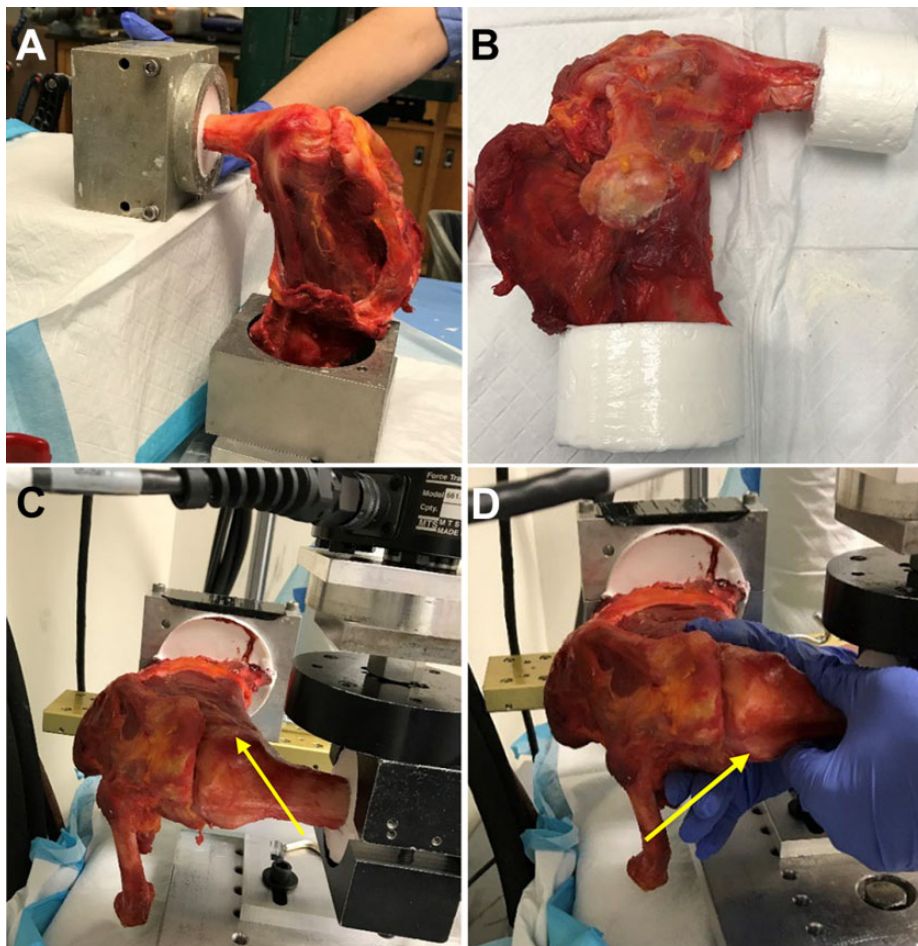


Figure 1. (A, B) Specimens were dissected free of subcutaneous tissue and potted using the humeral diaphysis and the angle of the scapula. Specimens were positioned in the MTS device at (C) 90° of abduction (relative to the trunk) and (D) 90° of external rotation (the yellow arrows demonstrate the position of the bicipital groove).

The neutral position of the humeral head on the glenoid was identified by locating the position with the least resistance on the testing machine. This was evaluated a minimum of 2 times and accepted once it was demonstrated that it could be replicated; the position was also double-checked with direct visualization. To re-create anterior glenohumeral subluxation, the humeral head was advanced anteriorly on the glenoid a distance of 10 mm at 2 mm/s. Each test condition was performed 3 times, and the mean value from the 3 trials was used.

Testing Procedure

After completion of test condition 1 (intact state), a capsulotomy through the rotator interval was used to access the anterior glenoid. The width of the bony glenoid was measured in an anterior to posterior manner at the location of maximal diameter. With the use of an oscillating saw, a coronal section measuring 25% of the maximal width of the glenoid was removed from the anterior glenoid (Figure 3A). The anterior labrum and capsular tissues were separated

from the removed bone and otherwise maintained. The defect sizes are noted in Table 1.

The second test condition was then performed. The surgical procedure to augment the anterior glenoid with scapular spine autograft was performed by 2 experienced, sports fellowship-trained orthopaedic surgeons. The area of maximal width at the flare of the scapular spine was identified. Typically, this location is about 5 cm medial to the scapular notch¹³ but lateral to the base so as to avoid any risk of fracture. At this harvest site, the periosteum was sharply incised over 2 to 3 cm. Subperiosteal dissection was carried deep, leaving the soft tissues intact but exposing the superior and inferior surfaces of the scapula at the harvest site. A fragment of the spine measuring 2.5 cm in length from medial to lateral was then sectioned using an osteotome at the base of the spine; this was between 6 and 9 mm in depth on the superior surface of the scapular spine (Table 1 and Figure 3B). We took care to prevent the osteotomy line from passing deeper than the base of the spine. No harvest site entered the suprascapular notch or resulted in fracture of any portion of the scapula. In all

specimens, this produced enough bone stock to completely fill the glenoid defect.

Two fully threaded, 3.75-mm screws were then used in a lag fashion to secure the scapular spine augmentation to the glenoid defect. This was placed in such a way so as to ensure that no step-off existed between the arc of the articular surface of the glenoid and the arc of the superior surface of the scapular spine autograft (Figure 3C). No interval closure was performed. The third test condition was then performed.




Figure 2. Test setup with the joint compression using dead weight (arrow).

Statistical Analysis

Statistical significance testing was performed using analysis of variance to confirm that a significant difference existed between the means of the 3 states (intact, with defect, augmented). We used *t* tests to compare results between 2 distinct states (intact vs with defect, with defect vs augmented, intact vs augmented). For all analyses, $P < .05$ was set as the threshold for statistical significance.

RESULTS

Of the 12 shoulders tested, 2 specimens (specimens 11 and 12) from the same patient (a 59-year-old woman) showed clinically and mechanically inconsistent results. The left shoulder showed an increase in the joint-reaction force after the glenoid defect was removed, and the right shoulder showed a decrease in the joint-reaction force after glenoid augmentation. In both specimens, the joint reference neutral position could not be accurately found during baseline testing. Both specimens came from the same donor, and it was noted that the rotator cuff musculature and capsule, although intact, were especially lax and hypermobile, which may have contributed to testing inconsistencies. These 2 specimens were excluded from the final analysis. The results from the remaining specimens ($N = 10$) are presented in Table 2 and Figure 4. The data for each test condition were normalized with respect to its intact state.

When the glenoid defect was created, the peak reaction forces were only slightly decreased compared with their intact condition in 2 specimens (specimens 7 and 5): ~10% in specimen 7 and ~20% in specimen 5. In the remaining specimens, reaction forces were significantly reduced between 50% and 75% compared with the intact condition.

After the bone augmentation procedure, two of the specimens (specimens 3 and 7) showed increased peak reaction forces compared with the peak forces recorded in their intact state: by 40% in specimen 3 and 30% in specimen 7. In two specimens (specimens 4 and 5), the reaction forces

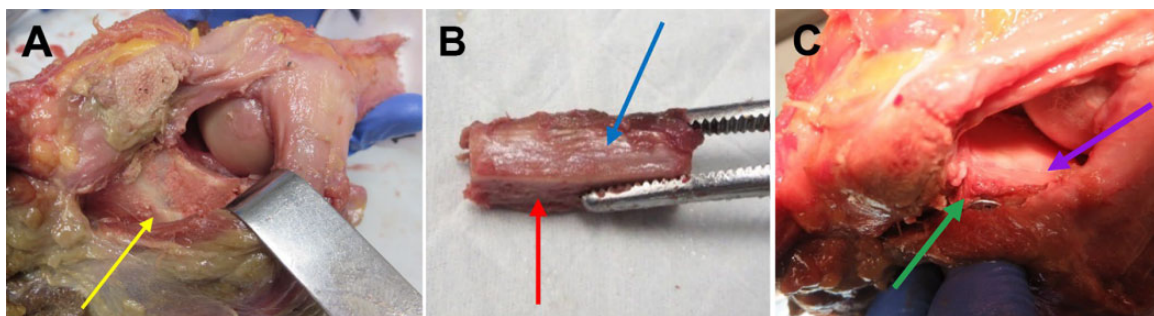


Figure 3. Augmentation procedure. (A) Glenoid after creation of a defect (yellow arrow). (B) Example of bone graft harvested from superior scapular spine showing the superior (blue arrow) and posterior (red arrow) surfaces of the graft. (C) Specimen after augmentation of the joint with a scapular spine autograft. The green arrow indicates the posterior surface of the scapular spine graft through which the screw is placed, and the purple arrow indicates the interface between the glenoid and graft; it is possible to see that the contour of the superior surface of the graft is similar to that of the glenoid.

TABLE 2
Peak and Normalized Joint-Reaction Force Under the Intact, With Defect, and Augmented Conditions (N = 10 Shoulders)

Specimen	Side	Peak Joint-Reaction Force, N ^a			Normalized Relative to Intact		
		Intact	With Defect	Augmented	Intact	With Defect	Augmented
1	Right	66.9 ± 0.6	34.1 ± 2.2	41.1 ± 1.2	1.00	0.51	0.61
2	Right	55.2 ± 1.8	14.5 ± 1.7	33.6 ± 1.2	1.00	0.26	0.61
3	Left	49.5 ± 1.3	16.6 ± 3.0	72.1 ± 4.1	1.00	0.34	1.46
4	Right	122.2 ± 2.0	32.0 ± 8.3	120.7 ± 1.2	1.00	0.28	1.05
5	Right	70.1 ± 1.8	56.0 ± 0.5	79.0 ± 1.6	1.00	0.80	1.06
6	Right	101.2 ± 2.2	28.3 ± 7.8	28.3 ± 2.2	1.00	0.28	0.28
7	Left	32.2 ± 1.6	30.4 ± 1.6	42.3 ± 0.5	1.00	0.94	1.31
8	Left	47.5 ± 3.8	18.0 ± 0.1	33.6 ± 0.6	1.00	0.38	0.71
9	Right	68.1 ± 2.9	15.8 ± 0.3	32.8 ± 1.1	1.00	0.23	0.48
10	Left	73.0 ± 8.5	22.0 ± 0.6	40.0 ± 0.7	1.00	0.29	0.53

^aData are reported as mean ± SD.

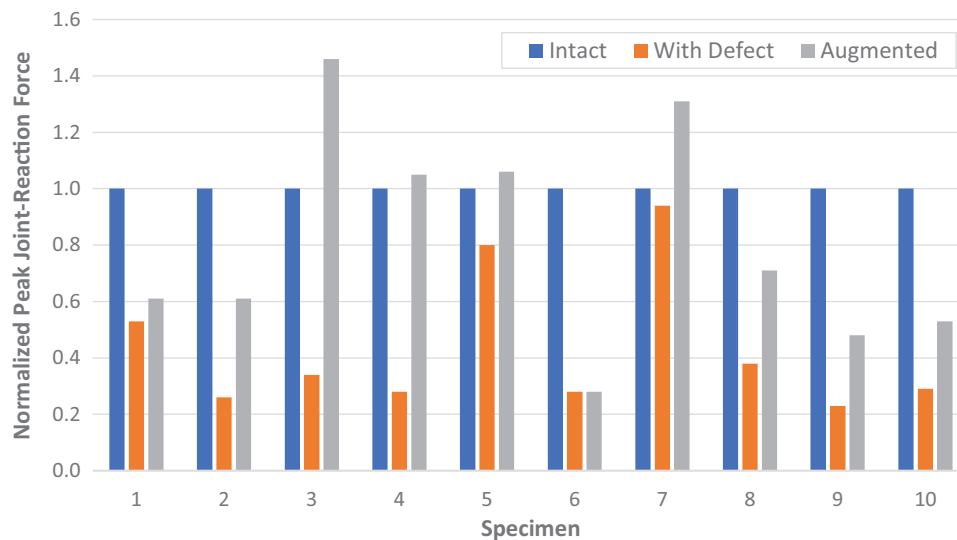


Figure 4. Normalized peak joint-reaction force of intact specimens, specimens after creation of a defect, and specimens after augmentation with scapular spine autograft.

TABLE 3
Results of Statistical Comparisons Between the Testing Conditions^a

Statistical Comparison	P
ANOVA	
Intact vs with defect vs augmented	<.001
<i>t</i> test	
Intact vs with defect	<.001
With defect vs augmented	<.001
Intact vs augmented	.07

^aBoldface *P* values indicate statistically significant difference between states (*P* < .05). ANOVA, analysis of variance.

were similar to the peak reaction forces observed in their intact state. In 1 specimen (specimen 6), bone augmentation did not affect the value of the peak reaction force

compared with the glenoid defect condition. In the rest of the specimens, bone augmentation increased the peak reaction force compared with the glenoid defect condition; however, these values were below the peak reaction forces observed in the intact condition.

Results indicated that in all specimens, the peak joint-reaction force was reduced after the glenoid defect was created and significantly increased after the bone augmentation (Table 3).

DISCUSSION

The primary finding of our study was that augmentation of the anterior glenoid with scapular spine autograft improved the bony stability of the joint in cadaveric specimens. In final analysis, joint-reaction forces were decreased from the native state with creation of a bony defect whereas

grafting of the defect with scapular spine autograft significantly increased joint stability. In accordance with our hypothesis, results indicated that the scapular spine is an acceptable alternative for tricortical autograft in shoulder instability surgery.

In 1989, Fronek et al⁴ described using the scapular spine for bone block augmentation of the glenoid in posterior glenohumeral instability. Although the scapular body is a well-documented source for vascularized pedicle harvest,^{10,14,15} the literature has been scarce regarding the use of the scapular spine for autograft in orthopaedic procedures. One cadaveric study, using nonstructural scapular spine autograft as an alternative to iliac crest autograft for lumbar spinal fusions, documented both the adequacy of bone stock and the relative ease of the procedure.¹⁵ Rohman et al¹³ compared computed tomography measurements of the scapular spine to those of other autograft harvest sites for anterior shoulder instability. Those investigators found the scapular spine to have similar dimensions to the coracoid and iliac crest, with 96% of scapular spines providing adequate bone stock ($8 \times 8 \times 20$ mm) compared with 85% of coracoids.¹³ A cadaveric study comparing distal tibial allograft and scapular spine autograft for reconstruction of posterior glenoid defects found that both procedures restored stability of the glenohumeral joint to that of the defect-free state.¹¹ To our knowledge, our study is the first biomechanical study to evaluate the scapular spine as an alternative to other autograft methods in anterior glenohumeral instability surgery.

The presence of a bony glenoid defect is an important predictor of recurrent instability after shoulder injury. In that situation, restoration of the bony morphology of the glenoid has been shown in multiple studies to help restore glenohumeral stability.^{1,12,17,18} In a cadaveric study simulating anterior glenoid osseous defects, Yamamoto et al¹⁸ demonstrated that restoration of the glenoid concavity with a free coracoid graft increased peak translational force of the humerus on the glenoid to that of the defect-free state. In their study, soft tissue procedures alone failed to restore the stability of the shoulder to its native state in any size of defect. Conversely, bone grafting alone restored stability for all sizes of defects, indicating that perhaps the most important factor in restoring stability is re-creating the bony concavity and arc length of the glenoid. In another cadaveric study, Pauzenberger et al¹² found that using an iliac crest "J-graft" to restore glenoid concavity resulted in glenohumeral contact areas and stability comparable to a defect-free state.

In the current study, using scapular spine autograft delivered similar results. We found that peak joint-reaction forces were not significantly different from those of a native state when grafting of the defect was performed. Additionally, visual inspection of the augmented glenohumeral joint demonstrated consistent restoration of the articular arc and concavity with scapular spine bone grafting using the superior aspect of the scapular spine adjacent to the glenoid surface.

In addition to demonstrating that scapular spine autograft adequately restored bony stability to the shoulder, we noted advantages relative to other stabilization procedures.

Similar to the Latarjet procedure, using scapular spine autograft offers the advantage of requiring only 1 surgical field, obviating the need for a separate surgical preparation such as with iliac crest harvest. In contrast to the Latarjet procedure, scapular spine autograft entails less alteration of the anatomic characteristics of the anterior shoulder. It is also possible that use of a scapular spine autograft carries a lower complication risk compared with iliac crest autograft or the Latarjet procedure; iliac crest autograft harvest is well known for issues with wound drainage and postoperative pain, whereas the Latarjet procedure carries the unique risk of neurological injury cited between 1% and 20%.³ Distal tibial allograft, although avoiding the surgical complications of autograft harvest, carries concerns of increased resorption, increased cost, and limited availability relative to autograft procedures.¹⁵

The scapular spine is easily accessible and requires minimal mobilization of muscular tissue without posing danger to important neurovascular structures. In each of our specimens, the scapular spine had sufficient length, width, and depth to provide adequate tricortical autograft. Furthermore, we noted that the scapular spine, at its flare, had a shape and radius of curvature on the superior surface that visually matched those of the glenoid and provided an excellent, smoothly contoured substitute for the defect of the glenoid. Potential downsides of scapular spine autograft include harvest site morbidity with pain or irritation at the site; there is also potential for scapular fracture if careful technique is not used during harvest.

Limitations

This study has several limitations. Using cadaveric specimens to test a dynamic process does not fully reflect conditions in vivo. The rotator interval was opened for the second and third testing states, which may have led to different outcomes than first testing state with the rotator interval intact. We attempted to match the joint-reaction force provided by native musculature, capsule, and intra-articular negative pressure with dead weight; this method, although used widely in the literature, is nonetheless only a simple substitute for the dynamic forces seen in vivo. No other graft options, such as coracoid or iliac crest, were used in this study; however, based on the study by Rohman et al,¹³ it appeared that similar sizing possibilities exist between scapular spine autograft and other glenoid augmentation graft options. It is also possible that this study was underpowered to detect a difference between the augmented and intact states; however, the statistical significance was much more pronounced in the other analyses. Finally, because this represents a time-zero study, this study does not provide information about healing potential of the graft or the long-term health of the shoulder.

CONCLUSION

Augmentation of anterior glenoid defects with scapular spine autograft led to increased stability of the glenohumeral joint during anterior translation in a cadaveric model.

Additionally, the scapular spine offered consistently adequate bone stock for glenoid augmentation while visually matching the contour and anatomic characteristics of the native glenoid. The results suggest that the scapular spine may be a useful local alternative for autogenous bone graft in anterior shoulder instability surgery.

ACKNOWLEDGMENT

The authors acknowledge Excelen Lab as the testing site.

REFERENCES

- Ahmed I, Ashton F, Robinson CM. Arthroscopic Bankart repair and capsular shift for recurrent anterior shoulder instability: functional outcomes and identification of risk factors for recurrence. *J Bone Joint Surg Am.* 2012;94(14):1308-1315.
- Boileau P, Th  lu C, Mercier N, et al. Arthroscopic Bristow-Latarjet combined with Bankart repair restores shoulder stability in patients with glenoid bone loss. *Clin Orthop Relat Res.* 2014;472(8):2413-2424.
- Domos P, Lunini E, Walch G. Contraindications and complications of the Latarjet procedure. *Shoulder Elbow.* 2018;10(1):15-24.
- Fronek J, Warren RF, Bowen M. Posterior subluxation of the glenohumeral joint. *J Bone Joint Surg Am.* 1989;71(2):205-216.
- Itoi E, Lee SB, Berglund LJ, Berge LL, An KN. The effect of a glenoid defect on anteroinferior stability of the shoulder after Bankart repair: a cadaveric study. *J Bone Joint Surg Am.* 2000;82(1):35-46.
- Kim SH, Ha KI, Cho YB, Ryu BD, Oh I. Arthroscopic anterior stabilization of the shoulder: two to six-year follow-up. *J Bone Joint Surg Am.* 2003;85(8):1511-1518.
- Longo UG, Loppini M, Rizzello G, et al. Latarjet, Bristow, and Eden-Hybinette procedures for anterior shoulder dislocation: systematic review and quantitative synthesis of the literature. *Arthroscopy.* 2014;30(9):1184-1211.
- Mascarenhas R, Raleigh E, McRae S, et al. Iliac crest allograft glenoid reconstruction for recurrent anterior shoulder instability in athletes: surgical technique and results. *Int J Shoulder Surg.* 2014;8(4):127-132.
- Montgomery WH Jr, Wahl M, Hettrich C, et al. Anteroinferior bone-grafting can restore stability in osseous glenoid defects. *J Bone Joint Surg Am.* 2005;87(9):1972-1977.
- Muramatsu K, Doi K, Ihara K, Shigetomi M, Kawai S. Recalcitrant posttraumatic nonunion of the humerus: 23 patients reconstructed with vascularized bone graft. *Acta Orthop Scand.* 2003;74(1):95-97.
- Nacca C, Gil JA, DeFroda SF, Badida R, Owens BD. Comparison of a distal tibial allograft and scapular spinal autograft for posterior shoulder instability with glenoid bone loss. *Orthop J Sports Med.* 2018;6(7):2325967118786697.
- Pauzenberger L, Dyrna F, Obopilwe E, et al. Biomechanical evaluation of glenoid reconstruction with an implant-free J-bone graft for anterior glenoid bone loss. *Am J Sports Med.* 2017;45(12):2849-2857.
- Rohman E, Gronbeck K, Tompkins M, et al. Scapular spine dimensions and suitability as a glenoid bone graft donor site. *Am J Sports Med.* 2019;47(10):2469-2477.
- Sullivan MJ, Carroll WR, Baker SR, Crompton R, Smith-Wheelock M. The free scapular flap for head and neck reconstruction. *Am J Otolaryngol.* 1990;11(5):318-327.
- Tubbs RS, Wartmann CT, Louis RG Jr, et al. Use of the scapular spine in lumbar fusion procedures: cadaveric feasibility study. Laboratory investigation. *J Neurosurg Spine.* 2007;7(5):554-557.
- Warner JJ, Gill TJ, O'Hollerhan JD, Pathare N, Millett PJ. Anatomical glenoid reconstruction for recurrent anterior glenohumeral instability with glenoid deficiency using an autogenous tricortical iliac crest bone graft. *Am J Sports Med.* 2006;34(2):205-212.
- Yamamoto N, Muraki T, An KN, et al. The stabilizing mechanism of the Latarjet procedure: a cadaveric study. *J Bone Joint Surg Am.* 2013;95(15):1390-1397.
- Yamamoto N, Muraki T, Sperling JW, et al. Stabilizing mechanism in bone-grafting of a large glenoid defect. *J Bone Joint Surg Am.* 2010;92(11):2059-2066.