

Neuroendocrine Tumor Diagnosed Through Endoscopic Ultrasound-Guided Fine-Needle Biopsy of a Lung Mass

Mohamed Abdallah, MD¹, Nicholas McDonald, MD¹, Brian Hanson, MD^{1,2}, Gaurav Suryawanshi, MD¹, and Mohammad Bilal, MD^{1,2}

¹Division of Gastroenterology, Hepatology and Nutrition, University of Minnesota, Minneapolis, MN

²Division of Gastroenterology and Hepatology, Minneapolis VA Health Care System, Minneapolis, MN

ABSTRACT

Endoscopic ultrasound-guided fine-needle biopsy (EUS-FNB) is an excellent modality for tissue acquisition and has been shown to be superior to EUS-fine-needle aspiration in several studies. Although tissue sampling of lung nodules using EUS-fine-needle aspiration has been reported in the literature, the use of EUS-FNB for tissue acquisition of parenchymal lung mass has rarely been reported in the literature. Our report highlights that EUS-FNB is safe and effective for lung lesions that are near the esophageal wall.

INTRODUCTION

Endoscopic ultrasound (EUS) is an essential diagnostic tool to evaluate and sample cystic or solid lesions in the pancreas, gastrointestinal tract, posterior mediastinum, and retroperitoneum.¹ EUS-fine-needle aspiration (EUS-FNA) has been used historically for tissue acquisition by puncturing lesions, followed by aspiration of cells or fluid for cytology. However, small tissue samples, distortion of tissue architecture, and limited diagnostic accuracy are a few limitations of EUS-FNA.² EUS-fine-needle biopsy (EUS-FNB) has emerged as an alternative to FNA because of its larger caliber, which enables obtaining core biopsies with larger tissue specimens,

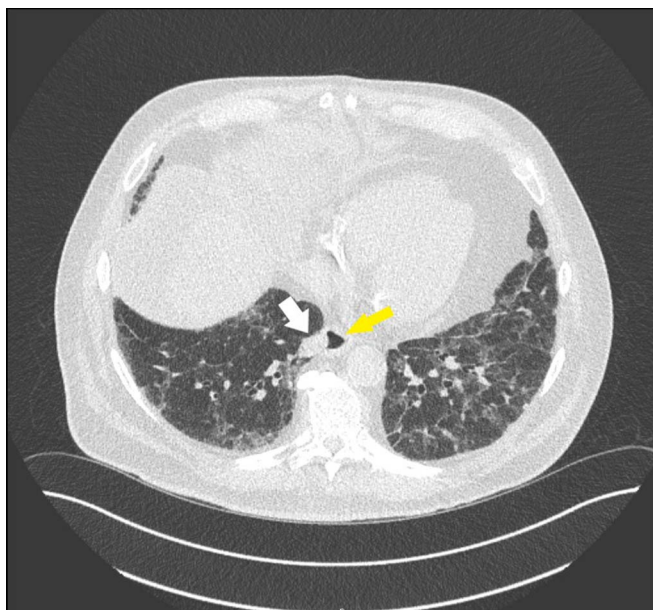


Figure 1. Noncontrast computed tomography of the chest showing a 19 × 13 mm lung mass in the right lower lobe (white arrow) that is abutting the esophagus (yellow arrow).

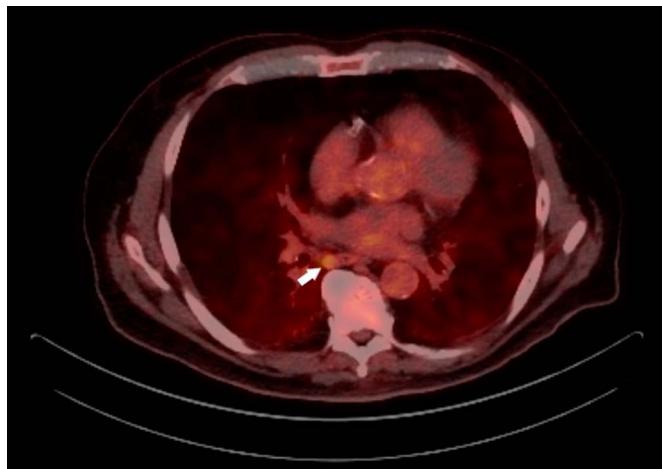


Figure 2. Positron emission tomography demonstrating a mild fluorodeoxyglucose uptake of the right lower lobe lung nodule.

thereby preserving tissue architecture and permitting histology and immunohistology staining rather than cytologic examination only.³ Multiple studies demonstrated excellent diagnostic accuracy and technical success of EUS-FNB and superiority in comparison with EUS-FNA for solid lesions in the pancreatobiliary tree, lymph node sampling, and mediastinal lesions.⁴⁻⁶ In this study, we present a case of the use of EUS-FNB for tissue acquisition of a lung mass.

CASE REPORT

A 77-year-old man with a medical history of interstitial lung disease, cirrhosis secondary to nonalcoholic steatohepatitis complicated by ascites, type 2 diabetes mellitus, and remote tobacco use was found to have a 16 × 11 mm lung mass on the right lower lobe on computed tomography (CT) ordered for a follow-up of interstitial lung disease. A 6-week repeat noncontrast CT scan showed enlargement of the mass to 19 × 13 mm abutting the esophagus (Figure 1). Positron emission tomography performed 1 week later showed a mild fluorodeoxyglucose uptake of 4.7 SUV, in addition to an enlarged subcarinal lymph node of SUV 3.5 (Figure 2). This case was discussed in a multidisciplinary conference with interventional radiology, pulmonology, thoracic surgery, medical oncology, and radiation oncology and was deemed to be challenging to be sampled by endobronchial ultrasound and interventional radiology-guided

percutaneous sampling. The patient was referred for consideration of EUS.

A linear echoendoscope (GF-UCT180; Olympus, Center Valley, PA) was used, and a 25 × 14 mm hypoechoic subpleural round lung mass with well-defined borders was identified at 32 cm from the incisors in the esophagus (Figure 3). In addition, a 15 × 10 mm oval paraesophageal mediastinal lymph node was identified. A transesophageal FNB using a 25-gauge needle biopsy (Acquire; Boston Scientific, Natick, MA) of the lung mass and lymph node was performed after the color Doppler did not show significant vascular structures within the needle path (Figure 3). Four passes were made each from the lung mass and lymph node using the slow-pull technique. A visible core of the tissue was obtained. Pneumothorax was monitored intra-procedurally by tracking oxygenation and change in hemodynamics, and after the procedure, the patient was observed in the postoperative area for 2 hours. No imaging was needed after the procedure. No pneumothorax or bleeding was reported during or at the end of the procedure, and the patient was discharged home the same day. There were no reports of chest pain or shortness of breath on the postprocedure follow-up. Histopathology of the lung mass showed tumor cells growing in an organoid pattern in cords, nests, and rosette-like structures with neuroendocrine differentiation evident by INSM1, chromogranin, and synaptophysin reactivity (Figure 4). These features were consistent with high-grade neuroendocrine carcinoma, with a Ki-65 proliferation index of 30%. Lymph node biopsy was negative for malignancy. The patient was started on definitive chemoradiotherapy.

DISCUSSION

Intraparenchymal lung lesions are typically biopsied through endobronchial ultrasound bronchoscopy or CT-guided percutaneous biopsy.⁷ Surgical biopsies are rarely used but may be required for tissue acquisition.⁸ Tissue sampling of lung nodules using EUS-FNA has been reported in the literature; however, this has been limited to few case reports and case series.⁹⁻¹¹ Contrarily, the use of EUS-FNB for tissue acquisition of parenchymal lung mass has been reported only twice in the literature.^{12,13} In the first report, Adler et al reported 2 successful lung tissue acquisition cases using EUS-FNB.¹² The first patient was a 66-year-old man with a

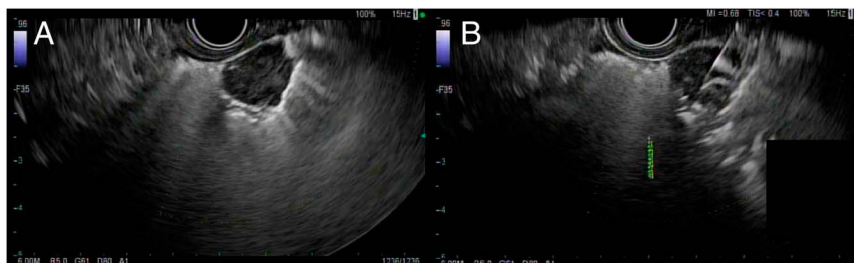

Figure 3. (A) Linear endoscopic ultrasonography showing a 25 × 14 mm hypoechoic subpleural round lung mass. (B) EUS-FNB of the lung mass using a 25-gauge needle biopsy. EUS-FNB, endoscopic ultrasound-guided fine-needle biopsy.

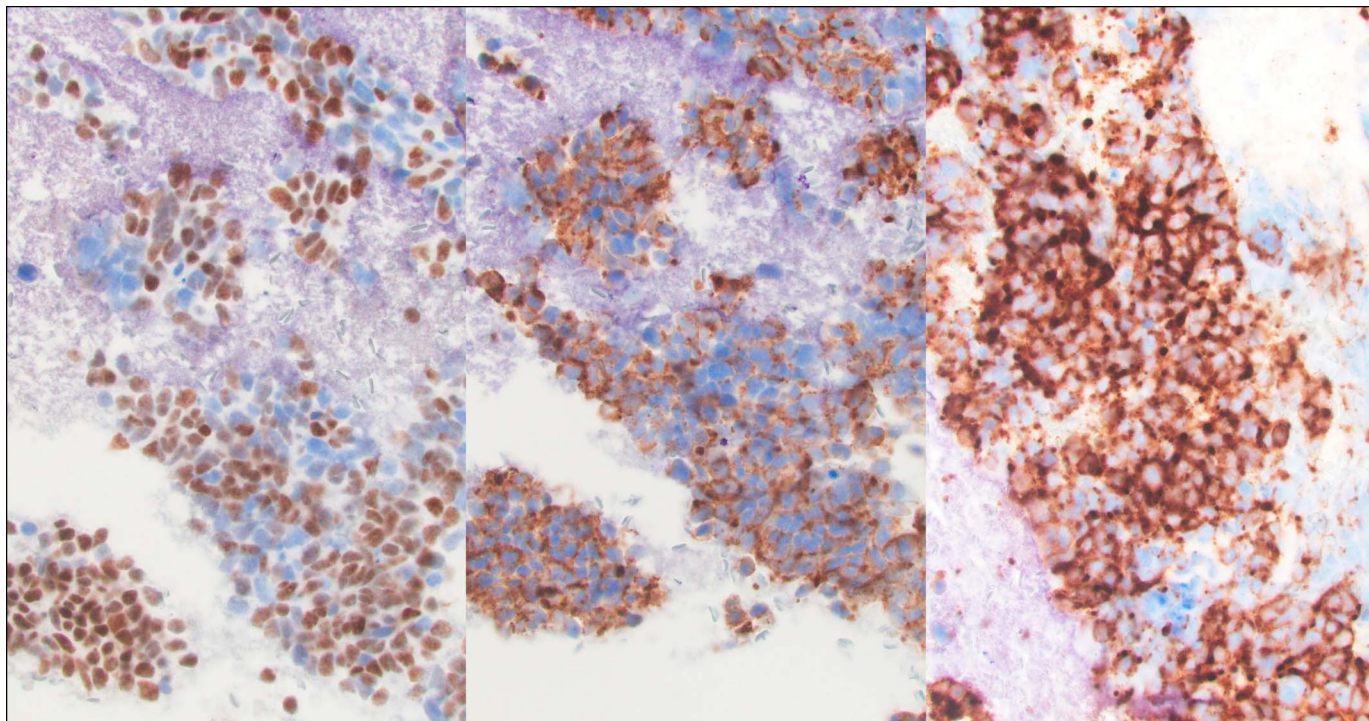


Figure 4. Immunohistochemistry staining showing reactivity for INSM1 (left), chromogranin (center), and synaptophysin (right), consistent with a diagnosis of neuroendocrine tumor.

9 × 11 mm subpleural nodule in the medial right upper lobe. EUS-FNB using 25-gauge needle biopsy (Acquire; Boston Scientific) yielded 2 passes and was diagnostic for non-small-cell lung carcinoma. The second patient was a 60-year-old man with a speculated 6.5 × 40 mm left upper lobe periaortic lesion. Four transesophageal EUS-FNB passes were obtained using a 22- and 25-gauge needle biopsy (Acquire; Boston Scientific) and were negative for malignancy. In both patients, lesions were not in direct contact with the esophageal wall on EUS, showing that EUS-FNB may be performed in such scenarios. In the second report, Tosoni et al reported the case of a 72-year-old man who had a large paramediastinal pulmonary mass completely occupying the superior portion of the right hemithorax, associated with multiple enlarged mediastinal lymph nodes. A transesophageal EUS-FNB using a 22-gauge fork-tip needle (SharkCore; Medtronic, Dublin, Ireland) was performed on both the mass and the subcarinal lymph. Histology showed a reactive lymph node, but the lung mass demonstrated a poorly differentiated neoplasm consistent with the recurrence of cerebral glioblastoma.¹³

EUS-FNA has been the mainstay for sampling pancreatic and non-pancreatic masses for more than 2 decades. However, it has several limitations: insufficient tissue volume, the need for core tissue to establish a diagnosis, and the availability of rapid on-site evaluation.^{3,11} EUS-FNB with specialized needles—fork-tip and Franseen— was introduced to provide histologic quality tissue samples.³ The performance characteristics (including histologic adequacy) of fork-tip and Franseen needles seem to be equivalent in many studies, including a randomized controlled trial.¹⁴ In addition to common adverse events of bleeding, postprocedural pain, and pancreatitis associated with EUS-guided tissue acquisition,

pneumothorax was reported using EUS-FNA in lung tissue sampling.^{3,6,15} Although pneumothorax has not been reported using EUS-FNB, necessary precautions before, during, and after the procedure must be implemented before considering EUS-FNB for lung tissue acquisition.

Our report highlights that EUS-guided FNB is safe and effective for lung lesions that are near the esophageal wall. A multidisciplinary discussion with interventional radiology and pulmonology should take place before sampling for lung lesions by EUS. The risk of pneumothorax should also be mentioned when obtaining the informed consent.

DISCLOSURES

Author contributions: M. Abdallah: manuscript writing and manuscript review. N. McDonald and G. Suryawanshi: manuscript writing. B. Hanson: manuscript review and intellectual input. M. Bilal: manuscript review, intellectual input, and is the article guarantor.

Financial disclosures: None to report.

Informed consent was obtained for this case report.

Received December 19, 2021; Accepted July 26, 2022

REFERENCES

1. Friedberg SR, Lachter J. Endoscopic ultrasound: Current roles and future directions. *World J Gastrointest Endosc.* 2017;9(10):499–505.

2. Cazacu IM, Luzuriaga Chavez AA, Saftoiu A, Vilmann P, Bhutani MS. A quarter century of EUS-FNA: Progress, milestones, and future directions. *Endosc Ultrasound*. 2018;7(3):141–60.
3. El H, IIAI-Haddad M. EUS-FNA giving way to fine-needle biopsy: Is it time to retire your old trusted needles?. *Gastrointest Endosc*. 2018;87(6):1439–42.
4. Li DF, Wang JY, Yang MF, et al. Factors associated with diagnostic accuracy, technical success and adverse events of endoscopic ultrasound-guided fine-needle biopsy: A systematic review and meta-analysis. *J Gastroenterol Hepatol*. 2020;35(8):1264–76.
5. Cheng B, Zhang Y, Chen Q, et al. Analysis of fine-needle biopsy vs fine-needle aspiration in diagnosis of pancreatic and abdominal masses: A prospective, multicenter, randomized controlled trial. *Clin Gastroenterol Hepatol*. 2018;16(8):1314–21.
6. Li H, Li W, Zhou QY, Fan B. Fine needle biopsy is superior to fine needle aspiration in endoscopic ultrasound guided sampling of pancreatic masses: A meta-analysis of randomized controlled trials. *Medicine (Baltimore)*. 2018;97(13):e0207.
7. VanderLaan PA, Wang HH, Majid A, Folch E. Endobronchial ultrasound-guided transbronchial needle aspiration (EBUS-TBNA): An overview and update for the cytopathologist. *Cancer Cytopathol*. 2014;122(8):561–76.
8. Righi L, Franzi F, Montarolo F, et al. Endobronchial ultrasound-guided transbronchial needle aspiration (EBUS-TBNA)-from morphology to molecular testing. *J Thorac Dis*. 2017;9(Suppl 5):S395–s404.
9. Bugalho A, Ferreira D, Eberhardt R, et al. Diagnostic value of endobronchial and endoscopic ultrasound-guided fine needle aspiration for accessible lung cancer lesions after non-diagnostic conventional techniques: A prospective study. *BMC Cancer*. 2013;13:130.
10. Dincer HE, Gliksberg EP, Andrade RS. Endoscopic ultrasound and/or endobronchial ultrasound-guided needle biopsy of central intraparenchymal lung lesions not adjacent to airways or esophagus. *Endosc Ultrasound*. 2015;4(1):40–3.
11. Annema JT, Veselić M, Rabe KF. EUS-guided FNA of centrally located lung tumours following a non-diagnostic bronchoscopy. *Lung Cancer*. 2005;48(3):357–61; discussion 363-354.
12. Adler DG, Gabr M, Taylor LJ, Witt B, Pleskow D. Initial report of transesophageal EUS-guided intraparenchymal lung mass core biopsy: Findings and outcomes in two cases. *Endosc Ultrasound*. 2018;7(6):413–7.
13. Tosoni A, Gessi M, Rindi G, Larghi A. Recurrent metastatic lung gliosarcoma diagnosed by EUS-guided fine-needle biopsy. *Endosc Ultrasound*. 2021;10(2):147–8.
14. Bang JY, Hebert-Magee S, Navaneethan U, Hasan MK, Hawes R, Varadarajulu S. Randomized trial comparing the Franseen and Fork-tip needles for EUS-guided fine-needle biopsy sampling of solid pancreatic mass lesions. *Gastrointest Endosc*. 2018;87(6):1432–8.
15. Vazquez-Sequeiros E, Levy MJ, Van Domselaar M, et al. Diagnostic yield and safety of endoscopic ultrasound guided fine needle aspiration of central mediastinal lung masses. *Diagn Ther Endosc*. 2013;2013:150492.

Copyright: © 2022 The Author(s). Published by Wolters Kluwer Health, Inc. on behalf of The American College of Gastroenterology. This is an open access article distributed under the terms of the Creative Commons Attribution-Non Commercial-No Derivatives License 4.0 (CCBY-NC-ND), where it is permissible to download and share the work provided it is properly cited. The work cannot be changed in any way or used commercially without permission from the journal.