

Contents lists available at [ScienceDirect](https://www.sciencedirect.com)

International Journal of Surgery Case Reports

journal homepage: www.casereports.com

Arthroscopic treatment for Morel-Lavallée lesion of the thigh: A case report and literature review

Tomofumi Kage*, Jinso Hirota, Naoya Yamamoto, Yosuke Kawasaki, Shin Asai, Liuzhe Zhang, Satomi Ugawa, Atsushi Seichi

Department of Orthopaedic Surgery, Mitsui Memorial Hospital, Tokyo, Japan

ARTICLE INFO

Article history:

Received 10 November 2020

Received in revised form

26 November 2020

Accepted 28 November 2020

Available online 2 December 2020

Keywords:

Arthroscopic debridement

Arthroscopy

Closed degloving injury

Morel-Lavallée lesion

Negative pressure wound therapy

ABSTRACT

INTRODUCTION: Morel-Lavallée lesion (MLL) is a posttraumatic closed degloving soft tissue injury, in which the subcutaneous tissues are separated from the underlying fascia. Surgical treatment is recommended if conservative management fails. The conventional surgical treatment for the lesion is surgical drainage and debridement.

PRESENTATION OF CASE: A 51-year-old male patient presented with swelling of the right thigh incurred during a traffic accident. The lesion was diagnosed with MLL. The MLL was successfully treated with a minimally invasive arthroscopic treatment after failure of conservative treatment. The arthroscopic treatment was chosen because of the patient's comorbidity that posed a risk of surgical wound complications. In addition, negative pressure wound therapy (NPWT) was performed postoperatively to ensure healing and to prevent recurrence of the lesion. The patient was successfully treated and the healing of the lesion was also confirmed with MRI.

DISCUSSION: In a patient with a risk of wound complications due to a comorbidity, this minimally invasive arthroscopic treatment is useful. In addition, NPWT was used to ensure healing and to prevent recurrence. Although the use of NPWT combined with endoscopic treatment has not been reported, additional NPWT reported in this case may be helpful to ensure healing.

CONCLUSION: In case of MLL with a risk of surgical complications, the arthroscopic treatment is a reasonable method and achieves the goal of an open surgical debridement without increased morbidity.

© 2020 The Author(s). Published by Elsevier Ltd on behalf of IJS Publishing Group Ltd. This is an open access article under the CC BY-NC-ND license (<http://creativecommons.org/licenses/by-nc-nd/4.0/>).

1. Introduction

Morel-Lavallée lesion (MLL) is a post-traumatic closed degloving soft tissue injury, first described by French surgeon Morel-Lavallée in 1863 [1]. The lesion is caused by high-impact shearing force, creating a dead space between the plane of subcutaneous tissue and the underlying muscular fascia [2]. This dead space fills with blood, lymph, and necrotic fatty tissue. The lesion causes pain, inflammation, persistent swelling, and sometimes infection without treatment. If an MLL is suspected by history and physical examination, ultrasound and magnetic resonance imaging (MRI) are useful to confirm diagnosis [3]. Moreover, optimal management of MLL lacks consensus. The options are conservative therapy such as compression, percutaneous aspiration, and sclerotherapy; how-

ever, the symptoms sometimes persist without complete healing [4,5]. If conservative management fails, open drainage and surgical debridement of the necrotic tissues are the most standard surgical treatment [6].

This report describes an arthroscopic treatment to address an MLL of the thigh. This method was chosen because of the patient's comorbidity and to minimize surgical complications such as infection. The aim of this study was to describe and evaluate the effectiveness and usefulness of the arthroscopic treatment of MLL with comorbidity that had a risk of surgical wound complications. This paper has been written in line with the SCARE criteria [7,8].

2. Presentation of case

A 51-year-old male patient presented with swelling of the right thigh incurred during a traffic accident between a bicycle and a car. After lateral contact with the car, the right thigh of the patient was sandwiched between the frame of the bicycle and the car. After the accident, the patient visited a clinic via ambulance and the patient's injuries were only bruises and abrasion of the thigh. However, the patient gradually developed swelling within 1–2 weeks. Therefore, the patient was referred to our hospital to scrutinize

* Corresponding author. Present address: Department of Orthopaedic Surgery, Mitsui Memorial Hospital, 1 Kandaizumicho, Chiyoda-ku, Tokyo 101-8643, Japan.

E-mail addresses: kage.calcio@gmail.com (T. Kage), hirotaji-tky@umin.ac.jp (J. Hirota), nyama4391@yahoo.co.jp (N. Yamamoto), kawasakiortho@gmail.com (Y. Kawasaki), asashin1203@gmail.com (S. Asai), ryutetsu.g@gmail.com (L. Zhang), ugawa.satomi@gmail.com (S. Ugawa), seichi-spine@mitsuihosp.or.jp (A. Seichi).

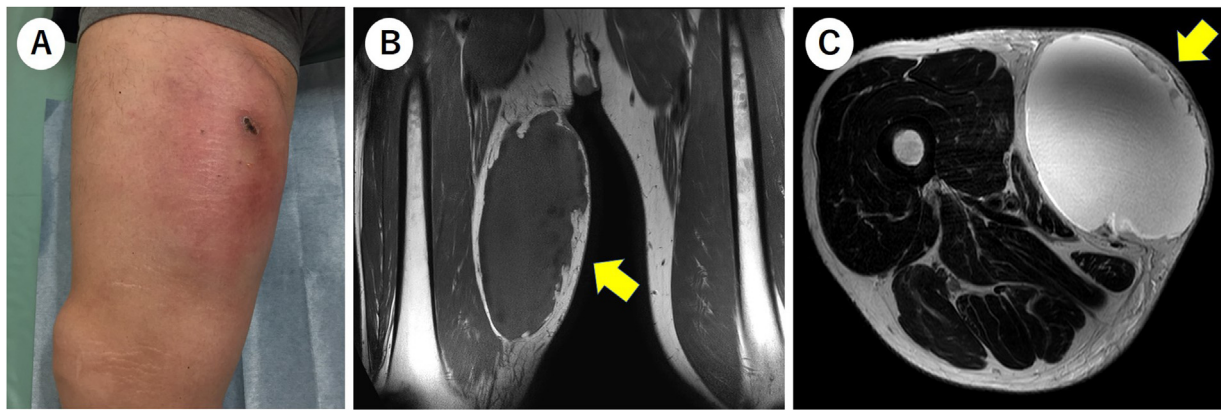


Fig. 1. Photograph and MR images before surgery.

(A) The lesion was observed on the medial thigh. On the coronal view of the T1-weighted image (B) and the axial view of the T2-weighted image (C), the lesions were observed (yellow arrow).

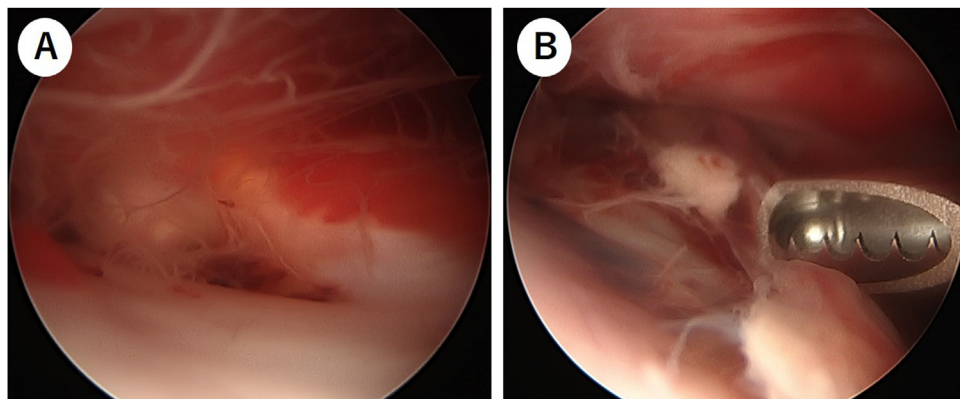


Fig. 2. Intraoperative arthroscopic images.

(A) The internal space between the muscular fascia and the subcutaneous side was filled with reddish fluid and white scars forming like a spiderweb were observed. (B) Scars were removed and refreshed using shaver and curette.

and treat the lesion. The patient had diabetes mellitus (DM) since he was 45-year-old and was once prescribed oral medicine; however, the patient himself discontinued the treatment. On physical examination, swelling and redness were observed on the medial side of the thigh (Fig. 1A). In addition, a wave motion was felt on the swelling. The circumference of the right thigh was 63.5 cm compared with 54.5 cm of the left thigh. As a differential diagnosis, a cellulitis after the trauma or intramuscular hematoma was assumed except MLL. To differentiate the diagnoses, the blood test was performed to confirm whether the inflammation existed or not. Additionally, the MRI was performed to confirm the localization of the lesion. On the blood test, no sign of inflammation was seen and the value of hemoglobin A1c was 10.7% (normal: <5.6%). On MRI examination, fluid and some debris were detected between the subcutaneous soft tissue and the muscular fascia (Fig. 1B and C). A diagnosis of MLL was made based on these findings.

After diagnosis, a conservative therapy was done first. Approximately 500 mL of reddish fluid was aspirated on percutaneous aspiration. Despite several sessions of percutaneous aspiration and compression by the bandage, fluid continued to accumulate. Therefore, we decided to perform surgical treatment. Arthroscopic debridement was chosen as the method of the surgical treatment because of poorly controlled DM and to minimize surgical wound complications such as infection. Before the surgery, the patient consulted a DM specialist, and insulin therapy was started. When the

patient was admitted to our hospital, insulin glargine and metformin had been used.

The surgery was performed in the supine position under general anesthesia. The procedure was performed by the author (T.K.) and the author (J.H.) took part in the procedure as the assistant. After proximal and distal portals were made, the internal space of the MLL was observed by arthroscopy. The 4-mm-diameter arthroscope (Stryker Orthopedics, Mahwah, NJ, USA) for knee arthroscopy was used. The internal space was filled with reddish fluid and scars existed elsewhere like a spiderweb. White scar was formed within the dead space on both the muscular fascia side and subcutaneous side (Fig. 2A). The scar was removed and refreshed using shaver and curette until there was bleeding (Fig. 2B). Two indwelling drainage catheters and negative pressure wound therapy (NPWT) device (RENASYS, Smith & Nephew, Memphis, TN, USA) were set up on the drainage holes to ensure drainage (Fig. 3). The total amount of bleeding in this surgery was 80 mL. As a pain relief medication, oral loxoprofen 180 mg per day was used for 3 days postoperatively. At postoperative day 17, the NPWT device was removed after confirmed reduction of the amount of drainage. At postoperative days 19 and 23, the 2 drainage catheters were removed sequentially after confirmed reduction of the amount of drainage. After complete removal of drainage, compression bandage was used. During the outpatient follow-up, recurrence of fluid accumulation and surgical wound complications were not observed. On the 6th month after surgery, healing was confirmed with MRI, which showed that

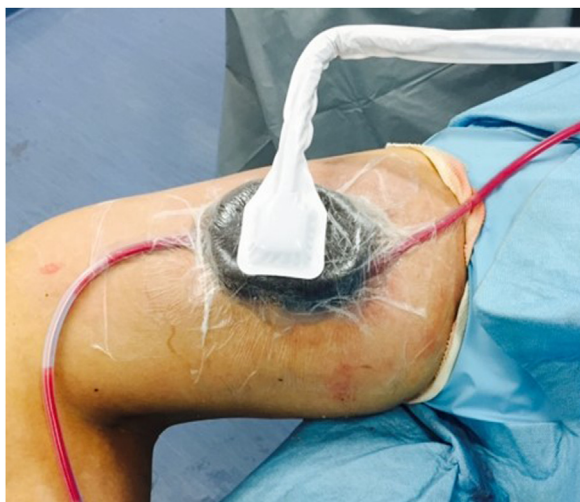

Fig. 3. Photograph after surgery. Two drainage catheters and negative pressure wound therapy (NPWT) device were set up to ensure drainage.

the dead space of the right thigh completely disappeared and the lesion was healed leaving a scar (Fig. 4A and B).

The patient was informed that the data would be submitted for publication and provided written informed consent.

3. Discussion

MLL is caused by a shearing force and commonly involves the pelvis, greater trochanter, flank, lumbar spine, scapula, thigh, and knee. MLL usually occurs after trauma and motor vehicle accidents are believed to be the main cause [9,10]. The other cause of MLL except trauma is sports injuries such as football and soccer [11,12]. Because of lack of clinical experience with MLL and various symptoms, many patients could be misdiagnosed and could not be treated properly [9]. The lesion causes pain, inflammation, persistent swelling, and infection without proper treatment [13].

Many options for the treatment of MLL have been reported; however, the consensus of strategies is not determined. The first choice of treatment is conservative therapy such as elastic compression bandage, aspiration, and sclerotherapy. However, the conservative treatment is unsuccessful in the presence of a pseu-

docapsule as it will prevent fluid reabsorption [14]. If conservative therapy fails, surgical treatment is imperative.

Open drainage and debridement are the conventional and standard method of surgical treatment of MLL. Although this method is effective, there is a risk of functional deficit and infection. A previous report showed that the deep infection rate was 13% in 24 patients with MLL of the pelvic area treated by open debridement [13]. Recently, endoscopic methods have been attempted to minimize the complications because of open surgical debridement. Compared with open surgical debridement, endoscopic debridement of MLL is less invasive and results in less pain and faster recovery. MLL is a rare entity but treatment with arthroscopic treatment is a familiar and useful choice for orthopaedic surgeons. Several case reports described successful endoscopic management [12,15]. Koc et al. reported a successful management with endoscopic debridement and fibrin glue injection [12]. Kim et al. reported a successful management with endoscopic treatment and sclerotherapy using doxycycline [15]. Liu et al. also described a case series of endoscopic debridement combined with percutaneous cutaneous suture technique among 8 patients [16]. In our case, endoscopic debridement and additional NPWT was performed instead of sclerotherapy or suture technique. Several studies reported the positive effect of NPWT on wound healing [17,18]. In addition, various reports recommend NPWT to prevent surgical site infections [19–21]. Willy et al. described that proper use of NPWT should be based on the presence of risk factors and operation-related risk factors in orthopaedic procedures [21]. From these perspectives, our use of NPWT was believed to be reasonable.

There is a limitation in this study. The effectiveness of only use of arthroscopic treatment was unclear. The arthroscopic treatment only without NPWT might have induced different results (e.g., infection or recurrence of the lesion). However, we performed NPWT concurrently in addition to arthroscopic treatment to ensure healing and to prevent recurrence.

In this report, we presented a case of successful arthroscopic treatment of MLL of the thigh. The arthroscopic treatment was chosen because the patient had DM and to minimize surgical wound complications such as infection. Particularly, in a patient with a risk of wound complications due to a comorbidity, this minimally invasive arthroscopic treatment is useful. In addition, NPWT was used to ensure healing and to prevent recurrence. Although the use of NPWT combined with endoscopic treatment has not been reported, additional NPWT reported in this case may be helpful to ensure healing.

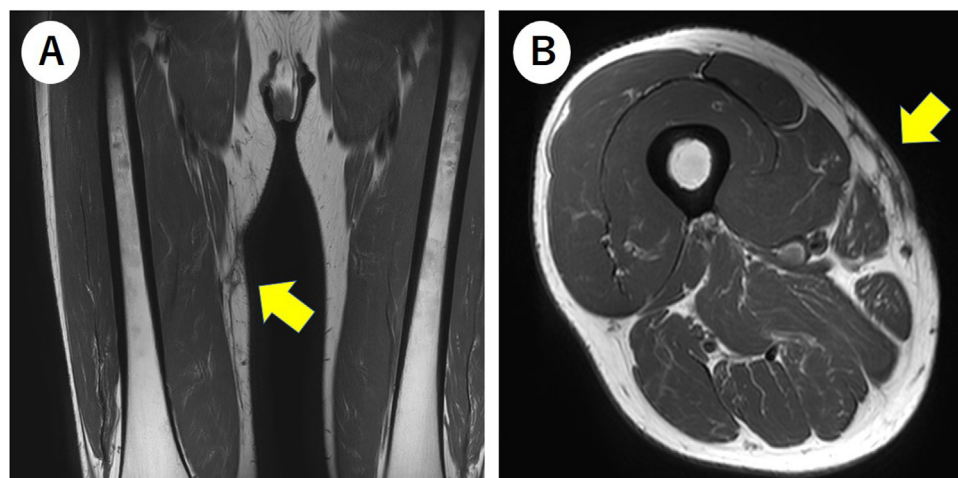


Fig. 4. Postoperative MR images of the right thigh.

On the coronal view of the T1-weighted image (A) and the axial view of the T2-weighted image (B), the dead space completely disappeared and the lesion was healed leaving scar (yellow arrow).

4. Conclusion

We recommend arthroscopic debridement in the treatment of MLL with comorbidity that has a risk of surgical wound complications. Additional NPWT might be a potential treatment choice to ensure healing without recurrence and wound complications.

Conflicts of interest

The authors declare that there is no conflict of interests regarding the publication of this article.

Sources of funding

The authors declare there are no funding resources for this article.

Ethical approval

Institutional review board approval was not required because all data were collected from clinical records and imaging systems for routine preoperative planning and follow-up.

Consent

Written informed consent was obtained from the patient for publication of this case report and accompanying images. A copy of the written consent is available for review by the Editor-in-Chief of this journal on request.

Author contribution

TK wrote this paper. JH attended the surgery, and all authors read this paper.

Registration of research studies

Not applicable.

Guarantor

Tomofumi Kage is the corresponding author of this paper.

Provenance and peer review

Not commissioned, externally peer-reviewed.

Patient perspective

The patient shared his perspective on the treatment when his wound was healed completely.

Acknowledgement

This research did not receive any specific grant from funding agencies in the public, commercial, or not-profit sectors.

References

- [1] J.A. Scolaro, T. Chao, D.P. Zamorano, The Morel-Lavallee lesion: diagnosis and management, *J. Am. Acad. Orthop. Surg.* 24 (October (10)) (2016) 667–672.
- [2] T. Nakajima, K. Tada, M. Nakada, M. Matsuta, H. Tsuchiya, Two cases of Morel-Lavallee lesion which resulted in a wide skin necrosis from a small laceration, *Case Rep. Orthop.* 2020 (2020), 5292937.
- [3] K. Mukherjee, S.M. Perrin, P.M. Hughes, Morel-Lavallee lesion in an adolescent with ultrasound and MRI correlation, *Skeletal Radiol.* 36 (June (Suppl 1)) (2007) S43–S45.
- [4] A. Bansal, N. Bhatia, A. Singh, A.K. Singh, Doxycycline sclerodesis as a treatment option for persistent Morel-Lavallee lesions, *Injury* 44 (January (1)) (2013) 66–69.
- [5] R. Singh, B. Rymer, B. Youssef, J. Lim, The Morel-Lavallee lesion and its management: a review of the literature, *J. Orthop.* 15 (December (4)) (2018) 917–921.
- [6] E.P. Palacio, G.G. Di Stasi, E.H. Lima, R.R. Mizobuchi, A.D. Junior, J.A. Galbiatti, Results from surgical treatment of Morel-Lavallee lesions: prospective cohort study, *Rev. Bras. Ortop.* 50 (March–April (2)) (2015) 148–152.
- [7] R.A. Agha, M.R. Borrelli, R. Farwana, K. Koshy, A.J. Fowler, D.P. Orgill, The SCARE 2018 statement: updating consensus Surgical CAse REport (SCARE) guidelines, *Int. J. Surg.* 60 (December) (2018) 132–136.
- [8] R.A. Agha, T. Franchi, C. Sohrabi, G. Mathew, A. Kerwan, The SCARE 2020 guideline: updating consensus Surgical CAse REport (SCARE) guidelines, *Int. J. Surg.* (November (9)) (2020).
- [9] T.P. Nickerson, M.D. Zielinski, D.H. Jenkins, H.J. Schiller, The Mayo Clinic experience with Morel-Lavallee lesions: establishment of a practice management guideline, *J. Trauma Acute Care Surg.* 76 (February (2)) (2014) 493–497.
- [10] I. Bonilla-Yoon, S. Masih, D.B. Patel, E.A. White, B.D. Levine, K. Chow, C.J. Gottsegen, G.R. Matcuk Jr., The Morel-Lavallee lesion: pathophysiology, clinical presentation, imaging features, and treatment options, *Emerg. Radiol.* 21 (February (1)) (2014) 35–43.
- [11] S.G. Tejwani, S.B. Cohen, J.P. Bradley, Management of Morel-Lavallee lesion of the knee: twenty-seven cases in the national football league, *Am. J. Sports Med.* 35 (July (7)) (2007) 1162–1167.
- [12] B.B. Koc, N. Somorjai, E. PMK, K. Vanderdood, M. Meesters-Caberg, F.W. Draijer, E.J. Jansen, Endoscopic debridement and fibrin glue injection of a chronic Morel-Lavallee lesion of the knee in a professional soccer player: a case report and literature review, *Knee* 24 (January (1)) (2017) 144–148.
- [13] D.J. Hak, S.A. Olson, J.M. Matta, Diagnosis and management of closed internal degloving injuries associated with pelvic and acetabular fractures: the Morel-Lavallee lesion, *J. Trauma* 42 (June (6)) (1997) 1046–1051.
- [14] C. Shen, J.P. Peng, X.D. Chen, Efficacy of treatment in peri-pelvic Morel-Lavallee lesion: a systematic review of the literature, *Arch. Orthop. Trauma Surg.* 133 (May (5)) (2013) 635–640.
- [15] S. Kim, Endoscopic treatment of Morel-Lavallee lesion, *Injury* 47 (May (5)) (2016) 1064–1066.
- [16] M. Liu, L. Liu, X. Zhou, L. Wu, J. Wang, L. Qi, C. Cai, A novel surgical technique for treatment of Morel-Lavallee lesion: endoscopic debridement combined with percutaneous cutaneo-fascial suture, *Injury* 49 (August (8)) (2018) 1630–1633.
- [17] C. Huang, T. Leavitt, L.R. Bayer, D.P. Orgill, Effect of negative pressure wound therapy on wound healing, *Curr. Probl. Surg.* 51 (July (7)) (2014) 301–331.
- [18] V. Pappalardo, F. Frattini, V. Ardita, S. Rausei, Negative Pressure Therapy (NPWT) for management of surgical wounds: effects on wound healing and analysis of devices evolution, *Surg. Technol. Int.* 34 (May (15)) (2019) 56–67.
- [19] A. Agarwal, Management of closed incisions using negative-pressure wound therapy in orthopedic surgery, *Plast. Reconstr. Surg.* 143 (January (15 Management of Surgical Incisions Utilizing Closed-Incision Negative-Pressure Therapy)) (2019) 21s–26s.
- [20] B. Allegranzi, B. Zayed, P. Bischoff, N.Z. Kubilay, S. de Jonge, F. de Vries, S.M. Gomes, S. Gans, E.D. Wallert, X. Wu, M. Abbas, M.A. Boermeester, E.P. Dellinger, M. Egger, P. Gastmeier, X. Guirao, J. Ren, D. Pittet, J.S. Solomkin, New WHO recommendations on intraoperative and postoperative measures for surgical site infection prevention: an evidence-based global perspective, *Lancet Infect. Dis.* 16 (December (12)) (2016) e288–e303.
- [21] C. Willy, A. Agarwal, C.A. Andersen, G. Santis, A. Gabriel, O. Grauhan, O.M. Guerra, B.A. Lipsky, M.B. Malas, L.L. Mathiesen, D.P. Singh, V.S. Reddy, Closed incision negative pressure therapy: international multidisciplinary consensus recommendations, *Int. Wound J.* 14 (April (2)) (2017) 385–398.

Open Access

This article is published Open Access at [sciencedirect.com](https://www.sciencedirect.com). It is distributed under the [IJSCR Supplemental terms and conditions](#), which permits unrestricted non commercial use, distribution, and reproduction in any medium, provided the original authors and source are credited.