



## Case report

# Acute suppurative thyroiditis seeded from infective endocarditis and intravenous drug use



Brian Cheung<sup>a,b,\*</sup>, Chris Levy<sup>a</sup>, Michelle Cheung<sup>c</sup>, Amirtharaj Dhanaraja<sup>b</sup>, Renny Abraham<sup>b</sup>, Chitharanjan Duvooi<sup>b</sup>

<sup>a</sup>Western Michigan University Homer Stryker M.D. School of Medicine, 1000 Oakland Drive, Kalamazoo, MI, 49008, United States

<sup>b</sup>Saint Bernards Healthcare, 300 Carson Street, Jonesboro, AR, 72401, United States

<sup>c</sup>California State University – Fullerton, 800 North State College Boulevard, Fullerton, CA, 92831, United States

## ARTICLE INFO

## Article history:

Received 30 April 2021

Received in revised form 6 July 2021

Accepted 6 July 2021

## Keywords:

Acute suppurative thyroiditis

Infective endocarditis

Prostatic abscess

Thyroiditis

Thyrotoxicosis

## ABSTRACT

Acute suppurative thyroiditis (AST) is a rare infection of the thyroid gland, and most patients are euthyroid upon presentation. We present an interesting case of a 42-year-old man with a history of intravenous drug use (IVDU) and poorly controlled type 2 diabetes mellitus who was admitted for sepsis and thyrotoxicosis from infective endocarditis (IE), AST, prostate abscess, and pyelonephritis. He suffered from a cerebral vascular accident (CVA) from septic embolic showering. Thyroid-stimulating hormone (TSH) was <0.10 mIU/L, and free thyroxine (T4) levels were >90 pmol/L. Methicillin-resistant *Staphylococcus aureus* (MRSA) was cultured in the patient's blood and urine. He was treated with prompt intravenous (IV) antimicrobials and source control from a transurethral resection of the prostate. This case demonstrates that AST can be a potential complication of IE and IVDU.

© 2021 Published by Elsevier Ltd. This is an open access article under the CC BY-NC-ND license (<http://creativecommons.org/licenses/by-nc-nd/4.0/>).

## Introduction

Acute suppurative thyroiditis (AST) is a rare infection involving the thyroid gland, which is not commonly susceptible to infection due to the high concentration of iodine and hydrogen peroxide. Other structural components that protect the thyroid against infections are the highly vascular nature, lymphatic drainage system, and its fibrous capsule [1–3]. AST is exceedingly uncommon and consists of <1% of all thyroid disease [2,4]. Mortality rate is around 3%, and prior analyses indicate that men and women are equally affected [2,3]. While the source of infection is not apparent in many cases, AST can be seen in patients with infective endocarditis (IE), diabetes mellitus, or a history of intravenous (IV) drug use [1,3,5]. We present a rare case of AST being a complication of hematogenous spreading from IE due to IV drug use (IVDU).

## Case

This is a 42-year-old African American man with a history of IV methamphetamine use and poorly controlled type 2 diabetes

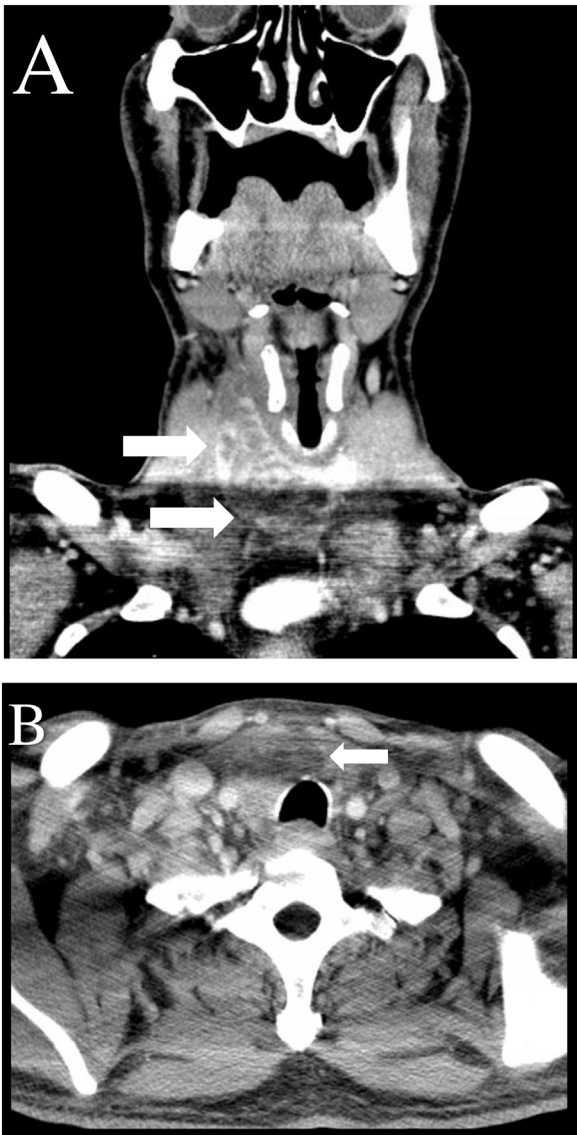
mellitus who presented to the emergency department with a chief complaint of a 3-day history of palpitations and sharp atypical chest pain at rest that was localized to his sternum. He also complained of fatigue, tactile pyrexia, chills, sore throat, odynophagia with solid food and liquids, dysuria, and polyuria. He denied dysphonia. Other past medical history includes hypertension, dyslipidemia, a 60-pack-year cigarette smoking history, and marijuana use. Family history is pertinent for diabetes mellitus type 2 and coronary heart disease. He worked at a logging mill in Arkansas, but denied any pets, military service, or recent travel outside of the United States.

The highest recorded temperature was 38.1 °C. His heart rate peaked at 130 beats/minute with a respiratory rate of 24 breaths/minute. Physical examination was pertinent for a goiter with exquisite tenderness of the anterior aspect of the right neck, retropharyngeal swelling, tachycardia, tachypnea, hyperactive bowel sounds, and hyperreflexia. He declined digital rectal exam.

Laboratory testing indicated white blood cells (WBC) peaking at  $16.9 \times 10^9$  cells/L with band neutrophils at 14 %. Thyroid-stimulating hormone (TSH) was <0.10 mIU/L, and free thyroxine (T4) levels were >90 pmol/L. Antibodies against thyroglobulin and thyroid peroxidase were not detected. Urinary analysis was positive for nitrites, leukocyte esterase, 16–20 red blood cells/high power field (HPF), and 36–40 WBC/HPF. His urinary drug screen was positive for opioids and methamphetamine. Over the course of the first 7 days of admission, 2 sets of blood cultures were

\* Corresponding author at: 300 Carson Street, Jonesboro, AR, 72401, United States.

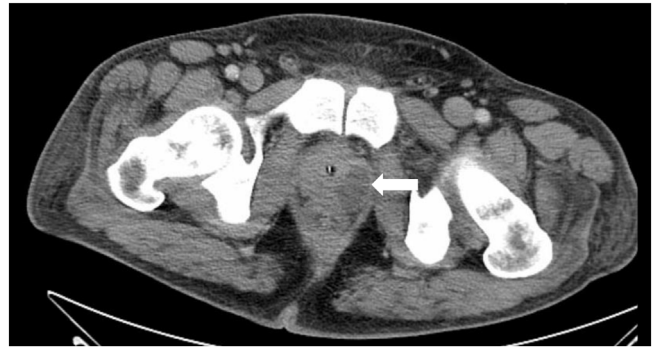
E-mail address: [JonesborolM@gmail.com](mailto:JonesborolM@gmail.com) (B. Cheung).



**Fig. 1.** Computed tomography imaging of the head and neck showing an enlargement of the right thyroid lobe measuring  $21.6 \times 28.6$  mm. **Fig. 1A** shows the thyroid along the coronal plane. **Fig. 1B** shows the thyroid along the axial plane.

drawn every 48 h, and 7 out of 8 peripheral blood cultures were positive for methicillin-resistant *Staphylococcus aureus* (MRSA) with a minimum inhibitory concentration of vancomycin of 1 micrograms per milliliter. Follow up blood cultures drawn on admission day 9 indicated no growth. MRSA was also cultured from the patient's urine. Computed tomography (CT) imaging indicated a  $21.6 \times 28.6$  mm enlargement of the right lobe and isthmus of the thyroid gland, bilateral pyelonephritis, and a 30.1 mm prostate abscess (Figs. 1A, B, and 2). Thyroid ultrasound (US) revealed markedly heterogeneous thyroid parenchyma on the right lobe. Transnasal flexible fiberoptic laryngoscopy only revealed mild swelling of his uvula, epiglottis, and right-sided aryepiglottic fold. The patient was started on IV piperacillin/tazobactam and vancomycin. He received source control from a transurethral resection of the prostate (TURP). Serial troponins, electrocardiography, transthoracic echocardiogram (TTE), and transesophageal echocardiogram (TEE) on admission were all within normal limits.

On admission day 3, the patient had a cerebral vascular accident (CVA) with new onset diffuse weakness with 3/5 strength in the hip flexors bilaterally and 4/5 strength in the gastrocnemius,



**Fig. 2.** Computed tomography imaging showing a prostatic abscess measuring 30.1 mm.

tibialis anterior, and throughout the upper extremities bilaterally. Magnetic resonance imaging (MRI) of the head indicated ischemic infarctions in the cortical and deep white matter bilaterally, left occipital lobe, and left cerebellum. Repeat TEE indicated  $4 \times 6$  mm vegetation on the ventricular aspect of right coronary cusp of the aortic valve, causing partial prolapse of the leaflet. Vancomycin was stopped, and daptomycin was started on an outpatient basis for the ease of once daily dosing.

The patient was discharged in stable condition; however, he continued to use IV methamphetamine. He unfortunately suffered from multiple CVA, received an aortic valve replacement that was later infected, and ultimately died from a myocardial infarction.

## Discussion

This is an unfortunate case of AST from MRSA that was most likely seeded from hematogenous spread from IE. Despite source control at the prostate via TURP and being on appropriate antimicrobial therapy, the patient still suffered multiple CVA from showering of septic emboli to the central nervous system.

AST can be seeded from hematogenous spread from different sites of infection or inoculation via septic emboli from IE, as was seen in our patient [2]. Other vehicles of infection include trauma to the neck, esophageal perforation, abscess extension from neighboring structures, and direct inoculation via IVDU or procedures such as fine needle aspiration [1,2]. AST may have had hematogenous spread from his prostate abscess or pyelonephritis, which are known sources of infection for AST [2,3]. However, the most common sources of infection are pharyngitis or upper respiratory tract infection. Other possible nidus includes otitis, mastoiditis, glossitis, dental infections, postpartum infections, and erysipelas [2].

As with our patient with his poorly controlled diabetes mellitus, about 25 % of patients with AST are immunocompromised from human immunodeficiency virus infection (HIV), inherited immunodeficiency, or being recipient of an organ transplant [1,2]. Patients >20 years of age with AST are more likely of being in an immunocompromised state compared to younger patients [2]. However, the most prevalent risk factor for AST is having a history thyroid disease or structural abnormalities, as about 60–70 % patients with AST have this risk factor [2,3]. Patients that are <20 years of age with AST are more likely to have structural abnormalities, such as pyriform sinus fistulae, compared to older patients [1,2].

The most frequent organism cultured from AST is gram-positive aerobes, as *Staphylococcus aureus* and *Streptococcus* species (spp.) account for about 40 % of AST cases. Gram-negative aerobes, such as *Enterobacteriaceae* spp. and *Pseudomonas aeruginosa*, account for about 25 % of all AST cases. *Pneumocystis jiroveci* is responsible for

about 15 % of the cases, and *Mycobacterium* spp. is detected in about 10 % of AST cases. Anaerobic organisms, such as *Bacteroides* spp., *Peptostreptococcus* spp., *Actinomyces* spp., and *Fusobacterium* spp., account for about 10 % of AST cases [1]. Other microbes that may be responsible for AST include aerobic *Nocardia* spp., *Aspergillus* spp., and *Candida* spp. About 30 % of all AST cases is polymicrobial infections [1,2].

Patients with AST can have a broad spectrum of presentation. While >80 % of patients are euthyroid, some can present with hyperthyroidism or hypothyroidism [2,6]. Some patients can be asymptomatic or present with a more indolent course [1]. However, dysphagia, dysphonia, and pharyngitis are the most common symptoms and occur in about >70 % of patients [2,3]. Other signs and symptoms include fever, leukocytosis, local warmth, erythema, neck pain, pharyngitis, dysphagia, or cough [2,3,7]. Other complications include extension of the abscess into neighboring structures, necrotizing mediastinitis, and perforation of the trachea or esophagus [1]. Most patients do not present with chest pain or palpitations, as our patient did.

The initial management involves protecting the airway with intubation if necessary [1].  $\beta$ -blockers can symptomatically treat thyrotoxicosis, but anti-thyroid drugs should not be used in the management of AST [6]. Broad-spectrum empiric antimicrobial therapy with penicillinase-resistant penicillin and beta-lactimase inhibitor, such as piperacillin/tazobactam and vancomycin in our patient, can be initiated [1,6]. Antimicrobial therapy can be deescalated to suit susceptibility data when it becomes available. Patients with a pyriform sinus tract can have antimicrobial therapy continued until elective resection or obliteration of the tract. This is typically recommended after clinical resolution of symptoms and reduces the likelihood of recurrent AST infections. Otherwise, antimicrobial therapy can be continued for a 14-day course or when clinical resolution is achieved [1].

Surgical or transcutaneous drainage is indicated in patients who have compromised airways, clinically deterioration, or persistence of the abscess after receiving more than 2 US guided FNAs [1,6]. Thyroidectomy is indicated in patients with extensive disease. Otherwise, US guided FNA drainage may suffice [1].

## Conclusion

This case demonstrates that AST can be seeded from IE due to IVDU in patients that are relatively immunosuppression from poorly controlled diabetes mellitus. The prompt recognition and appropriate treatment of this rare condition are imperative given the potential morbidity and mortality.

## Sources of funding

This research did not receive any specific grant from funding agencies in the public, commercial, or not-for-profit sectors.

## Consent

Written informed consent was obtained from the patient for publication of this case report and accompanying images. A copy of the written consent is available for review by the Editor-in-Chief of this journal on request.

## CRedit authorship contribution statement

**Brian Cheung:** Conceptualization, Resources, Visualization, Writing - original draft, Writing - review & editing. **Chris Levy:** Conceptualization, Resources, Visualization, Writing - original draft, Writing - review & editing. **Michelle Cheung:** Conceptualization, Resources, Writing - original draft, Writing - review & editing. **Amirtharaj Dhanaraja:** Conceptualization, Project administration, Resources, Writing - review & editing. **Renny Abraham:** Conceptualization, Project administration, Supervision, Writing - original draft, Writing - review & editing. **Chitharanjan Duvoor:** Conceptualization, Project administration, Supervision, Writing - original draft, Writing - review & editing.

## Declaration of Competing Interest

None.

## Acknowledgements

We would like to thank the patient for giving us consent to tell his story so that others may learn.

## References

- [1] Paes JE, Burman KD, Cohen J, et al. Acute bacterial suppurative thyroiditis: a clinical review and expert opinion. *Thyroid Off J Am Thyroid Assoc* 2010;20:247–55, doi:<http://dx.doi.org/10.1089/thy.2008.0146>.
- [2] Yu EH, Ko WC, Chuang YC, Wu TJ. Suppurative *Acinetobacter baumannii* thyroiditis with bacteremic pneumonia: case report and review. *Clin Infect Dis An Off Publ Infect Dis Soc Am* 1998;27:1286–90, doi:<http://dx.doi.org/10.1086/514998>.
- [3] Berger SA, Zonszein J, Villamena P, Mittman N. Infectious diseases of the thyroid gland. *Rev Infect Dis* 1983;5:108–22, doi:<http://dx.doi.org/10.1093/clinids/5.1.108>.
- [4] Al-Dajani N, Wootton SH. Cervical lymphadenitis, suppurative parotitis, thyroiditis, and infected cysts. *Infect Dis Clin North Am* 2007;21:523–41, doi:<http://dx.doi.org/10.1016/j.idc.2007.03.004> viii.
- [5] Yegya-Raman N, Copeland T, Parikh P. Acute suppurative thyroiditis in an intravenous drug user with a preexisting goiter. *Case Rep Med* 2018;2018:5098712, doi:<http://dx.doi.org/10.1155/2018/5098712>.
- [6] Ross DS, Burch HB, Cooper DS, et al. 2016 American thyroid association guidelines for diagnosis and management of hyperthyroidism and other causes of thyrotoxicosis. *Thyroid Off J Am Thyroid Assoc* 2016;26:1343–421, doi:<http://dx.doi.org/10.1089/thy.2016.0229>.
- [7] Falhammar H, Wallin G, Calissendorff J. Acute suppurative thyroiditis with thyroid abscess in adults: clinical presentation, treatment and outcomes. *BMC Endocr Disord* 2019;19:130, doi:<http://dx.doi.org/10.1186/s12902-019-0458-0>.