

CASE REPORT

Pregnancy-triggered pemphigus vulgaris with favorable fetal outcomes: A case report

Fatemeh Mohaghegh  | Zabihollah Shahmoradi | Maryam Alizadeh 

Department of Dermatology, Skin Diseases and Leishmaniasis Research Center, Isfahan University of Medical Sciences, Isfahan, Iran

Correspondence

Maryam Alizadeh, Department of Dermatology, Skin Diseases and Leishmaniasis Research Center, Isfahan University of Medical Sciences, Isfahan, Iran.

Email: maryam.alizadeh87@gmail.com

Funding information

This study has received no funding

Abstract

Pemphigus vulgaris is an autoimmune bullous dermatosis which if occurred during pregnancy may result in neonatal complications. In this study we report a 41 years old woman with pemphigus vulgaris that triggered by pregnancy in first trimester of pregnancy followed by the premature birth of a healthy neonate.

KEYWORDS

bullous dermatoses, infant, pemphigus, pregnancy

1 | INTRODUCTION

Pemphigus vulgaris (PV) is an autoimmune bullous dermatosis which affects people of all races with equal prevalence in men and women.¹ The etiology of PV still remains unknown. Pathophysiologically, the binding of circulating autoantibodies against desmoglein 1 and 3 to keratinocytes causes the loss of cell–cell adherence in basal and suprabasal layers of epidermis and results in bullous formation.² The cutaneous manifestation of PV often includes widespread vesicles followed by erosions and ulcerations which heal without scarring as these lesions are entirely epidermal.³ Nasal and oral mucosae are often involved in PV which may either be the only manifestation of PV or proceeded by cutaneous lesions.⁴ Pemphigus vulgaris is diagnosed by direct immunofluorescence (DIF) (demonstrating in-vivo deposits of antibodies and other immunoreactants such as complements) and indirect immunofluorescence (IIF) as well as skin biopsy.⁵ The histopathologic findings of PV include acantholysis and suprabasal cleft formation. Corticosteroids and immunosuppressive drugs are considered as effective

treatments and have reduced the mortality rate of PV to 5%–15%.⁶

Pemphigus vulgaris during pregnancy may result in neonatal complications. Maternal antibodies may cross the placenta resulting in neonatal pemphigus.^{7,8} Also, corticosteroid treatment can be associated with low birth weight, prematurity, adrenal insufficiency, and infection in newborns.^{9,10} We report a case of pregnancy-triggered pemphigus vulgaris in first trimester of pregnancy followed by the premature birth of a healthy neonate.

2 | CASE REPORT

An otherwise healthy 41-year-old pregnant woman presented to our dermatology department with the chief complaint of widespread blistering lesions. She was 8 weeks through her fourth pregnancy at the time and her past pregnancies had all resulted in fetal deaths as a result of severe metabolic disorders following a consanguineous marriage. Cutaneous involvement started as papular and urticarial lesions on her trunk and abdomen at 4 weeks

This is an open access article under the terms of the Creative Commons Attribution-NonCommercial-NoDerivs License, which permits use and distribution in any medium, provided the original work is properly cited, the use is non-commercial and no modifications or adaptations are made.

© 2022 The Authors. *Clinical Case Reports* published by John Wiley & Sons Ltd.

of gestation. At 8th week of pregnancy, the patient developed bullous lesions on oral and genital mucosae in addition to vesicles on her back, trunk, and abdomen. In physical examination, there were several blisters in average size of 2×2 cm on her abdomen, chest, arms, and back (Figure 1A,B). Urticarial lesions were also noted on her abdomen and back. Buccal and vulvar mucosae were also involved. These blisters were not tender or pruritic and there were no signs of excoriation. Skin biopsy reported a suprabasal bulla, the floor of which was lined by a single layer of basal cell tombstone appearance and a moderate lymphocytic infiltrate and a few eosinophils in the dermis (Figure 2A,B). Indirect immunofluorescence (IIF) reported positive anti-desmoglein 1 and 3 antibodies with the titer of 1:32 and 1:320, respectively (Figure 3). Since the clinical and pathological findings were consistent with pemphigus vulgaris, treatment was initiated by 65 mg/days of prednisolone. After 4 weeks, her lesions partially improved and she did not develop any new lesions (Figure 4) so we decided to lower the dosage of prednisolone. Prednisolone dosage was gradually tapered to 20 mg/days after 5 months. Pregnancy follow-up was normal and the patient did not develop any new lesions. At 33 weeks of gestation, she underwent a cesarean section because of the premature rupture of membranes. A healthy male infant was born, weighing 2520 g. Apgar scores and cord blood gases were all within normal ranges. Physical examination of the premature newborn was normal and his skin and mucosae were intact. After 3 days, IIF of newborn's serum reported positive anti-desmoglein 3 antibody with the titer of 1:100 (Figure 3). The newborn was then screened for adrenal insufficiency and metabolic disorders, all of which were reported negative. The infant was followed up for 8 weeks and did not develop any cutaneous or mucosal lesions. Pemphigus vulgaris in

mother was also controlled by low dose prednisolone in postpartum period, and she had not complained of new lesions ever since.

3 | DISCUSSION

Pemphigus vulgaris is a dermatologic condition with an estimated incidence of 0.68 cases per 100,000 persons each year.¹¹⁻¹⁴ PV in pregnancy can be more complicated regarding the alteration in clinical status, treatment options, and outcome of pregnancy. Pemphigus vulgaris is associated with infertility in active phases which explains the even lower incidence of PV during pregnancy.¹⁵ Most reported cases of PV in pregnancy describe the condition and outcome of PV in pregnant women who were already diagnosed with PV. Pregnancy as a triggering factor of PV is a rare phenomenon. To our knowledge, there is only one reported case of pregnancy-triggered maternal PV with persistent gingival lesions.¹⁴ Also, a retrospective study on 66 pregnant patients with pemphigus reported that in 18 patients the disease onset was during pregnancy and 17 (94.4%) of them had pemphigus vulgaris.¹⁶ One important differential diagnosis for PV in pregnancy is pemphigoid gestationis. Pemphigoid gestationis is a rare autoimmune disease during pregnancy and postpartum period. It is characterized by intense itching and erythematous papules that later form vesicles. They appear on the trunk and abdomen and spare the face and mucosal surfaces.¹⁷ Clinical manifestations (not involving mucosal surfaces), histopathological findings (subepidermal vesicles with lymphocyte and eosinophil infiltration), and immunofluorescence findings (C3 and IgG in a linear band along the basement membrane) of pemphigoid gestationis can differentiate it from PV in pregnancy.¹⁸ In the present case report, pregnancy triggered PV, as the patient had no history of cutaneous and mucosal lesions of any kind.

According to previous case reports and retrospective studies, the outcomes of pregnancy in the presence of PV include normal live birth, stillbirth, spontaneous abortion, intrauterine fetal death, premature delivery, and neonatal pemphigus.¹⁹ Most cases are followed by the birth of a healthy and full-term newborn which demands the cooperation of dermatologists and obstetricians in providing the best care for the mother and fetus.¹⁵ Neonatal pemphigus is another outcome of PV in pregnancy. It is described as transient flaccid blisters on the skin of the neonate which are not progressive and are mostly self-limiting. Neonatal pemphigus does not require any specific treatments and it does not result in any particular complications for the newborn.²⁰⁻²² The transmission of antibodies (mostly IgG4) through placenta is responsible

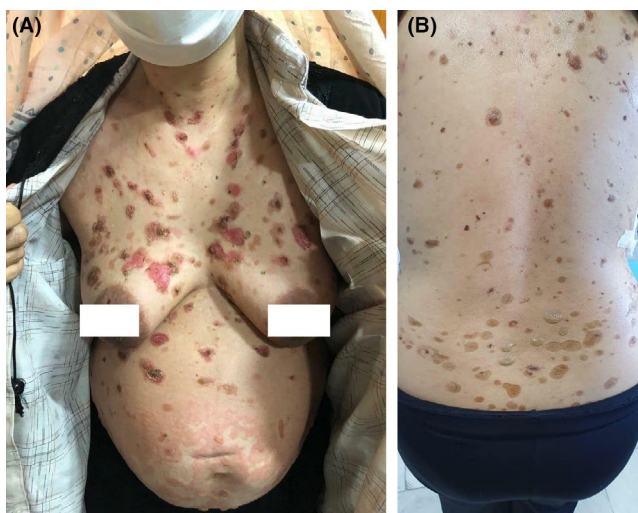


FIGURE 1 (A and B) Bullous lesions on trunk and abdomen

FIGURE 2 (A) Suprabasal acantholytic blister containing keratinocytes (H&E×100). (B) Suprabasal acantholytic blister containing keratinocytes (H&E×400)

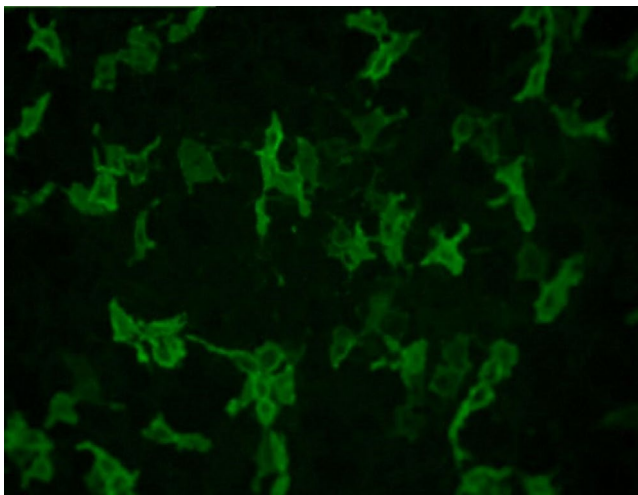
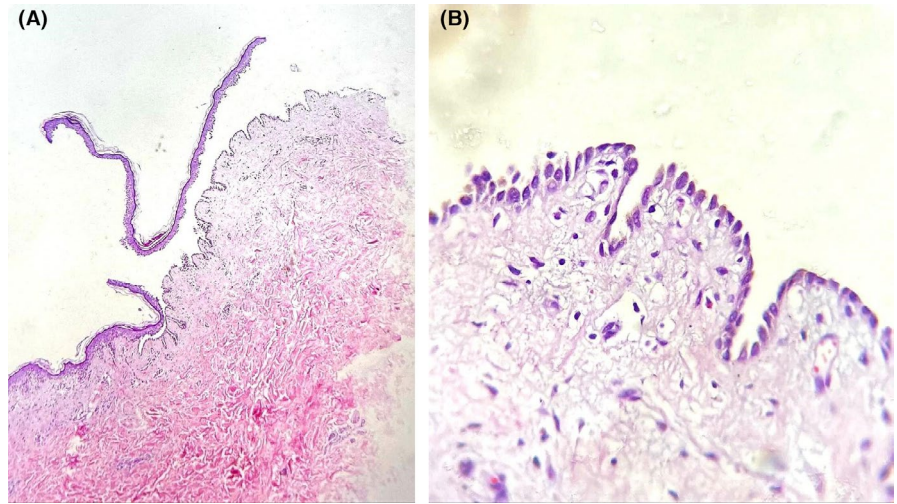


FIGURE 3 Fluorescent microscopic image for anti-desmoglein 3 antibody

for neonatal pemphigus. In this case, regardless of positive anti-desmoglein 3 antibody the newborn did not have any cutaneous or mucosal lesions which could suggest that the presence of anti-desmoglein 3 antibody is not necessarily accompanied by clinical presentations of PV in newborns. Although further research is demanded to confirm it, efficient treatment of PV in pregnancy is critical as it reduces the risk of postpartum flare-up and also controls the fetal outcomes. Prednisolone with low maintenance dosage is considered as first line of treatment. Like other corticosteroids, prednisolone can cross placenta and increase the risk of premature birth, infection, and mortality if used in high doses.⁹ In our case, although prednisolone was tapered to low doses after the patient recovered considerably, premature rupture of membranes resulted in premature birth. Premature birth in our case could be a result of prednisolone therapy or triggered by other factors including the gynecological history of the patient.

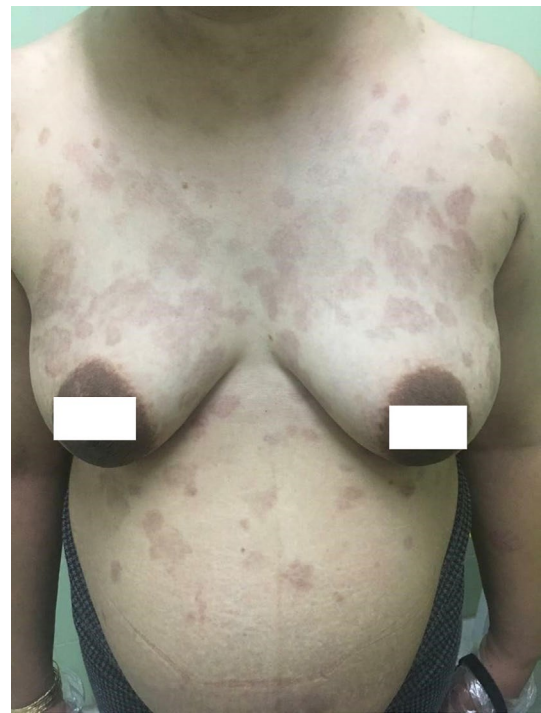

FIGURE 4 Improvement of lesions after treatment

In summary, this case report presents a pregnancy-triggered pemphigus vulgaris in a 41-year-old woman that resulted in the premature birth of a healthy newborn with positive anti-desmoglein 3 antibody in the absence of any clinical presentation of neonatal pemphigus. Pemphigus vulgaris in the mother was efficiently controlled by low-dose prednisolone through pregnancy and postpartum period.

ACKNOWLEDGEMENTS

None.

CONFLICT OF INTEREST

The authors have no conflicts of interest to declare.

AUTHOR CONTRIBUTIONS

F. M was responsible for visiting the patient and histopathology examination and reviewing the manuscript. Z. SH was responsible for dermatology consultation. M. A was responsible for visiting the patient, follow-up the outcome, and drafting the manuscript.

ETHICAL APPROVAL

All of the procedures are performed according to the World Medical Association Declaration of Helsinki and patient consent. We also obtained the patient's informed consent to publish this study.

CONSENT

Written informed consent was obtained from the patient to publish this report in accordance with the journal's patient consent policy.

DATA AVAILABILITY STATEMENT

All data collected or analyzed during this study are included in this published article.

ORCID

Fatemeh Mohaghegh  <https://orcid.org/0000-0002-8492-2410>

Maryam Alizadeh  <https://orcid.org/0000-0001-6602-6252>

REFERENCES

- Fainaru O, Mashiach R, Kupferminc M, Shenhav M, Pauzner D, Lessing JB. Pemphigus vulgaris in pregnancy: a case report and review of literature. *Hum Reprod.* 2000;15(5):1195-1197.
- Hertl M, Laffitte E, Borradori L, et al. Autoimmune bullous skin disorders. In: *Autoimmune Diseases of the Skin*. Springer; 2001:39-122.
- Kitajima Y, Aoyama Y. A perspective of pemphigus from bedside and laboratory-bench. *Clin Rev Allergy Immunol.* 2007;33(1-2):57-66.
- Kneisel A, Hertl MJP. Autoimmune bullous skin diseases: Part 1: Clinical manifestations. *J Dtsch Dermatol Ges.* 2011;1:844-857.
- Bhol K, Mohimen A, Ahmed RJD. Correlation of subclasses of IgG with disease activity in pemphigus vulgaris. *Dermatology.* 1994;189(Suppl. 1):85-89.
- Razzaque Ahmed A, Moy R. Death in pemphigus. *J Am Acad Dermatol.* 1982;7(2):221-228.
- Renner R, Sticherling MJDH. Chronisch entzündliche und autoimmun vermittelte Dermatosen in der Schwangerschaft. *Der Hautarzt.* 2010;61(12):1021-1026.
- Hern S, Vaughan Jones SA, Setterfield J, et al. Pemphigus vulgaris in pregnancy with favourable foetal prognosis. *Clin Exp Dermatol.* 1998;23(6):260-263.
- Lehman JS, Mueller KK, Schraith DF. Do safe and effective treatment options exist for patients with active pemphigus vulgaris who plan conception and pregnancy? *Archives Dermatol.* 2008;144(6):783-785.
- Ganji Z, Dana HF, Ebrahimi-Dehkordi S, Alidoust F, Bahmani K. Methotrexate as a safe immunosuppressive agent during the COVID-19 pandemic. *Int Immunopharmacol.* 2021;101:108324.
- Fainaru O, Mashiach R, Kupferminc M, Shenhav M, Pauzner D. Pemphigus vulgaris in pregnancy: a case report and review of literature. *Hum Reprod.* 2000;15(5):1195-1197.
- Langan S, Smeeth L, Hubbard R, Fleming K, Smith C, West J. Bullous pemphigoid and pemphigus vulgaris—incidence and mortality in the UK: population based cohort study. *BMJ.* 2008;337:160-163.
- Simon DG, Krutchkoff D, Kaslow RA, Zarbo R. Pemphigus in hartford county, connecticut, from 1972 to 1977. *Arch Dermatol.* 1980;116(9):1035-1037.
- Bialynicki-Birula R, Dmochowski M, Maj J, Gornowicz-Porowska J. Pregnancy-triggered maternal pemphigus vulgaris with persistent gingival lesions. *Acta Dermatovenerol Croat.* 2011;19(3):170-175.
- Kardos M, Levine D, Gürcan HM, Ahmed ARJO. Pemphigus vulgaris in pregnancy. *Obstet Gynecol Surv.* 2009;64(11):739-749.
- Daneshpazhooch M, Chams-Davatchi C, Valikhani M, et al. Pemphigus and pregnancy: a 23-year experience. *Indian J Dermatol Venereol Leprol.* 2011;77(4):534
- Sävervall C, Sand FL, Thomsen SFJC. Pemphigoid gestationis: current perspectives. *Clin Cosmet Investig Dermatol.* 2017;10:441.
- Lardenoije CM, van de Water M, Mertens HJ, Gondrie ET. Pemphigoidgestationis. *BMJCaseRep.* 2011;2011:bcr0120102623.
- Meurer M. Pemphiguserkrankungen bei Kindern und Jugendlichen. *Der Hautarzt.* 2009;60(3):208-216.
- Chowdhury MM, Natarajan S. Neonatal pemphigus vulgaris associated with mild oral pemphigus vulgaris in the mother during pregnancy. *Br J Dermatol.* 1998;139(3):500-503.
- Merlob P, Metzker A, Hazaz B, Rogovin H, Reisner SH. Neonatal pemphigus vulgaris. *Pediatrics.* 1986;78(6):1102-1105.
- Wasserstrum N, Laros RKJJ. Transplacental transmission of pemphigus. *JAMA.* 1983;249(11):1480-1482.

How to cite this article: Mohaghegh F, Shahmoradi Z, Alizadeh M. Pregnancy-triggered pemphigus vulgaris with favorable fetal outcomes: A case report. *Clin Case Rep.* 2022;10:e05734. doi:[10.1002/ccr3.5734](https://doi.org/10.1002/ccr3.5734)