

Long-term results after endoscopic VUR-treatment using dextranomer / hyaluronic acid copolymer – 5-year experience in a single-center

Joerg Seibold, Maren Werther, Saladin H. Alloussi, Stefan Aufderklamm, Georgios Gakis, Tilman Todenhöfer, Arnulf Stenzl, Christian Schwentner

Department of Urology, Eberhard-Karls-University, Tübingen, Germany

KEY WORDS

vesicoureteral reflux ▶ minimally invasive therapy
▶ dextranomer/hyaluronic acid ▶ health-related quality of life ▶ subureteral injection

ABSTRACT

Background. A number of bulking agents have been used for the endoscopic correction of vesicoureteral reflux in children. We present our long-term results of endoscopic use of dextranomer/hyaluronic acid copolymer (Deflux®) for VUR treatment in children.

Patients and methods. Between 2004 and 2008, 21 children underwent endoscopic subureteral injection of Deflux® in 30 ureters as an outpatient procedure. Twelve children had unilateral reflux (2 duplicated systems) and nine had bilateral reflux. Median age was 5-years (6-months to 14.9-years). Six weeks postoperatively, a voiding cystourethrogram was performed. This study examined the disappearance of VUR and urinary tract infection (UTI) in the long-term follow-up as well as QoL (questionnaire of the parents).

Results. No intra- or postoperative complications had been noticed. In 25 ureters (83%), VCUG showed no VUR 6-weeks postoperatively. Three children received a 2nd injection (two successful). After a median follow-up of 2.5 years, 27 ureters in 17 children (90%) had no urinary tract infection and VUR. The questionnaire results in regard to quality of life (QoL) were very good in the successfully treated children and the parents would choose the same treatment option again.

Conclusion. Subureteral injection of Deflux® for children with VUR is an effective treatment option with a low complication rate.

INTRODUCTION

Vesicoureteral reflux (VUR) is one of the most common diseases during childhood. Incidence is about 1% in clinically inconspicuous children and increases to 30-50% in children with urinary tract infections (UTI) [1-5]. The aim of VUR treatment is to prevent the ascent of infection and pyelonephritis as well as the possibly resulting reflux nephropathies in the case of febrile UTI. When a VUR is diagnosed, conservative treatment by means of antibiotic prophylaxis, open anti-reflux surgery, and endoscopic reflux therapy are available treatment options depending on symptomatology and severity of the reflux. Table 1. shows the current EAU recommendations for VUR therapy.

Depending on unilateral or bilateral occurrence, different techniques are used for surgical re-implantation of the ureter with a success rate of about 98%. All techniques are based on the prolongation of the intramural part of the ureter by means of submucosal tunneling for reconstruction of the passive reflux protection mechanism.

Minimally invasive endoscopic subureteral injection at the aperture with dextranomer/hyaluronic acid (Deflux®) has been established over the last few years. Modifications to the injection technique resulted in a significant increase in the success rates that are almost as high as with open surgery, depending on the grade of reflux [6-12]. Hereby, subureteral injection with the substance is performed dorsally, starting from the intramural part of the ureter. A 2nd injection is conducted in the area of the orifice at 6-o'clock.

The non-allergenic biologic material with low side effects and the low morbidity of the technique have to be pointed out [12].

During 5-year long-term follow-up the results of endoscopic Deflux® injection were evaluated retrospectively and the quality of life (QoL) of the children after surgery was analyzed by means of a questionnaire (parents).

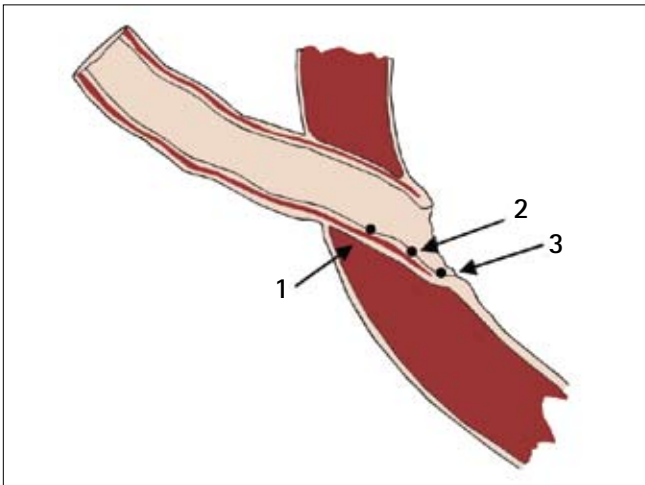
PATIENTS AND METHODS

Between January 2004 and January 2008, subureteral injection of Deflux® in 30 ureters (unilateral or bilateral VUR) of 21 children (17 girls, 3 boys) and follow-up control were performed in our department. All patients were diagnosed by means of a micturition cystourethrography (MCU). Reflux stages were defined according to the International Reflux Classification. Breakthrough infections or concomitant urogenital deformities were indications for subureteral injection for reflux. Bladder function was assessed in toilet-trained children using flow-analysis and surface electromyography. Residual urine measurements were done using standard 2-D ultrasound. Only those children with normal bladder function and hence primary reflux underwent injection therapy. The intervention was performed as an outpatient procedure. A postoperative MCU was conducted after 6-weeks. The absence of urinary tract infection was controlled during long-term follow-up [8]. Quality of life (QoL) with regard to the intervention was inquired via questionnaire. Additionally, the parents were interrogated by telephone.

Endoscopic injection was conducted according to the double-HIT-technique [6]. Depending on the irrigation flow, which is directed on the orifice, the feasibility to wash up the intramural part of the ureter was defined. Subureteral injection is started with intramural submucosal dorsal injection. Subsequently, an additional injection is performed in the area of the orifice at 6 o'clock (Fig. 1). Marks at the needle (3.7F x 23G tipp, Q-Med, Uppsala) facilitate the correct depth of injection and consequently the correct placement of the depot. At the end of the injection, the course of the ureter should be configured mountain chain-like and the area of the orifice volcanic cone-like. The mucosa should shimmer whitely.

Table 1. Age- and stage-dependent EAU recommendations for therapy (Guidelines 2010)

<1 year		Conservative
1-5 years	Grade I-III	Conservative
	Grade IV-V	Surgical
>5 years	Boys	Rare indication for surgery (low incidence of UTI)
	Girls	Surgical (high risk of UTI)
In case of breakthrough infections in spite of antibiotic prophylaxis or additional urogenital deformities (e.g. Hutch diverticulum, duplex kidney)		Surgical (at an early stage in case of urogenital deformities)

**Fig. 1.** Needle placement in endoscopic treatment of VUR. Injection spots 1 and 2 correspond to the intramural dorsal injection spots, injection spot 3 corresponds to the subureteral injection at 6 o'clock.

RESULTS

Between January 2004 and January 2008, 21 children were treated minimally invasively with dextranomer/hyaluronic acid in our clinic. Nine children had bilateral and 12 children unilateral reflux. Two of the patients with unilateral reflux had a duplex kidney with reflux into the lower part; consequently subureteral injection was performed in 30 ureters in total. Medium operating time was 12 minutes (6-20 minutes). There was no case of perioperative complications.

Medium age at the time of surgery was 60.6 months (6-months – 14.9 years). Three of the ureters had a grade I reflux, eight had a grade II reflux, 13 had grade III reflux, and six had grade IV reflux.

The average amount of Deflux® was 1.3 ml (0.9-1.9 ml). Median follow-up was 2.5 years (5-months – 5.2 years). In 17 children and 25 ureters (83%), postoperative MCU showed no reflux. The success rates with regard to the grade of reflux are depicted in Table 2.

Four children (three children with grade IV, one child with grade III) were re-injected using the HIT-technique due to persisting reflux and infections. During the 2nd injection no reflux depots

could be detected in all four children. Two children were reflux- and infection-free after the 2nd injection, which equates to a success rate of 50%. The success rates after 2nd injection are also shown in Table 2 with regard to the grade of reflux.

The remaining two children with unsuccessful injection (one patient with reflux grade III and one patient with reflux grade IV) received ureter re-implantation according to Lich-Gregoir.

DISCUSSION

In recent years, endoscopic treatment of VUR has been established as a treatment alternative. In 2001, dextranomer/hyaluronic acid (Deflux®) had been officially approved for endoscopic reflux injection in children by the American FDA (Food and Drug Administration). Since 2004, modifications to the original injection technique according to the STING method have lead to significantly improved results almost comparable to open surgery [6, 13]. In children biologic materials that are non-allergenic and do not migrate should be used [14]. Deflux® consists of dextranomer microspheres in a gel of stabilized non-animal hyaluronic acid. The micro-particles have a size of 80-250 µm and therefore do not migrate into surrounding tissue or organs [14]. Simultaneously, a technically easy application prevents iatrogenic lesions of the fine structures in infants and children. Bovine collagen showed good short-term results, however, the recurrence rate was 90% during long-term clinical course [15]. Lackgren et al. showed the technical application with Deflux® and good long-term results in contrast to bovine collagen [8, 9]. Our investigations verified unproblematic application and tolerance. No undesired side effects occurred intra- or postoperatively. Nor was there a recurrence of contralateral reflux in any of the children in the course. However, long-term outcome analysis is mandatory since recurrent reflux might be found in up to 20% of children with a regular postoperative cystography [8]. Nevertheless, it is important to bear in mind that repeat MCG is only justified in case of symptomatic urinary tract infection.

The success rate of 83% absence of reflux after subureteral injection is comparable to the data from the current literature [6-8, 12, 16]. Kirsch et al. were able to obtain a 72% success rate; Puri et al. reported a success rate of 86% [7, 10].

Subureteral injection with the HIT-technique showed an increase in the success rate. With regard to the treated ureters, the

Table 2. Success rate depending on the grade of reflux after 1st and 2nd subureteral injection with Deflux®

Grade of reflux (n=ureters)	Mean age at Deflux® treatment (in months)	Success rate (%) after 1 st injection	Success rate (%) after 2 nd injection
1 (3)	18.5	100%	N/A
2 (8)	72.8	87%	N/A
3 (14)	63.5	77%	85%
4 (6)	35.2	67%	83%

study conducted by Kirsch et al. had success rates of 92% compared to the STING technique with only 79% [6]. In our study the success rate for reflux grade III and IV was 77 and 67%, respectively. However, there was an increase to 85% and 83%, respectively after 2nd injection (see Table 2), which is comparable to the results of Elmore et al. 2008 [17]. They had demonstrated an infection-free rate of 95% after subureteral Deflux[®] injection compared to a 76% infection-free rate after antireflux plasty. Wadie et al. reported an infection-free rate of 77.4% after the 1st Deflux[®] treatment and 83.9% after 2nd injection [16]. However, our favorable success rates may be somewhat related to the relatively high proportion of low-grade refluxing ureters in our cohort. As such, isolated low-grade reflux does not require treatment. In the underlying study only those ureters were treated if a significant contralateral reflux was present.

An important aspect is the impact of the intervention on quality of life (QoL). A questionnaire to the parents of the children and an interrogation by telephone showed that all of the successfully treated children would choose this therapy again. No negative impact of the intervention on the children was reported. Reasons are the feasibility of Deflux[®] treatment as an outpatient procedure and its minimal invasiveness. This was also confirmed by Capozza et al. who reported that 80% of the parents prefer this treatment to the other therapy options (antibiotic long-term therapy/open surgery with anti-reflux plasty) [18].

Antibiotic long-term therapy is reported with a low success rate of 38% together with a low compliance rate of 17% [19, 20]. Data from the US showing a 288% increase in Deflux[®] injections in children confirm the growing importance of subureteral Deflux[®] injection as the primary treatment option for VUR [21]. This was shown by data analyses in 37 US hospitals between 2002 and 2004. The number of anti-reflux treatment measurements had increased by 55% during this period of time; the number of open surgical anti-reflux plasties had remained the same [21].

Since the implementation of dextranomer/hyaluronic acid (Deflux[®]) and the modification of the surgical technique in the endoscopic treatment of infantile VUR the success rates of this treatment modality have increased significantly depending on the grade of reflux and are almost comparable to those of the open surgical intervention. The low morbidity of the intervention and an excellent post-operative QoL show the advantages of this therapy. Thus, subureteral injection with Deflux[®] should be offered to the parents as a minimally invasive treatment alternative with a low complication rate.

REFERENCES

- Jacobson SH, Hansson S, Jakobsson B: *Vesico-ureteric reflux: occurrence and long-term risks*. Acta Paediatr 1999; 88 Suppl (431): 22-30.
- Riccabona M: *Management of recurrent urinary tract infection and vesicoureteral reflux in children*. Curr Opin Urol 2000; 10 (1): 25-28.
- Bourchier D, Abbott GD, Maling TM: *Radiological abnormalities in infants with urinary tract infections*. Arch Dis Child 1984; 59 (7): 620-624.
- Hautkappe A, Goepel M, Rübber H: *Harnwegsinfekte im Kindesalter*. Urologe B 1995; 35: 65-67.
- Winberg J, Andersen HJ, Bergstrom T et al: *Epidemiology of symptomatic urinary tract infection in childhood*. Acta Paediatr Scand Suppl 1974 (252): 1-20.
- Kirsch AJ, Perez-Brayfield M, Smith EA et al: *The modified sting procedure to correct vesicoureteral reflux: improved results with submucosal implantation within the intramural ureter*. J Urol 2004; 171 (6 Pt 1): 2413-2416.
- Kirsch AJ, Perez-Brayfield MR, Scherz HC: *Minimally invasive treatment of vesicoureteral reflux with endoscopic injection of dextranomer/hyaluronic acid copolymer: the Children's Hospitals of Atlanta experience*. J Urol 2003; 170 (1): 211-215.

- Holmdahl G, Brandström P, Läckgren G et al: *The Swedish reflux trial in children: II. Vesicoureteral reflux outcome*. J Urol. 2010; 184 (1): 280-285.
- Läckgren G, Wahlin N, Skoldenberg E et al: *Long-term follow-up of children treated with dextranomer/hyaluronic acid copolymer for vesicoureteral reflux*. J Urol 2001; 166 (5): 1887-1892.
- Puri P, Chertin B, Velayudham M et al: *Treatment of vesicoureteral reflux by endoscopic injection of dextranomer/hyaluronic Acid copolymer: preliminary results*. J Urol 2003; 170 (4 Pt 2): 1541-1544; discussion 1544.
- Puri P, Mohanan N, Menezes M et al: *Endoscopic treatment of moderate and high-grade vesicoureteral reflux in infants using dextranomer/hyaluronic acid*. J Urol 2007; 178 (4 Pt 2): 1714-1716; discussion 1717.
- Stenberg A, Läckgren G: *A new bioimplant for the endoscopic treatment of vesicoureteral reflux: experimental and short-term clinical results*. J Urol 1995; 154 (2 Pt 2): 800-803.
- O'Donnell B, Puri P: *Treatment of vesicoureteric reflux by endoscopic injection of Teflon*. Br Med J (Clin Res Ed) 1984; 289 (6436): 7-9.
- Stenberg AM, Sundin A, Larsson BS et al: *Lack of distant migration after injection of a 125iodine labeled dextranomer based implant into the rabbit bladder*. J Urol 1997; 158 (5): 1937-1941.
- Haferkamp A, Contractor H, Mohring K et al: *Failure of subureteral bovine collagen injection for the endoscopic treatment of primary vesicoureteral reflux in long-term follow-up*. Urology 2000; 55 (5): 759-763.
- Wadie GM, Tirabassi MV, Courtney RA et al: *The deflux procedure reduces the incidence of urinary tract infections in patients with vesicoureteral reflux*. J Laparoendosc Adv Surg Tech A 2007; 17 (3): 353-359.
- Elmore JM, Kirsch AJ, Heiss EA et al: *Incidence of urinary tract infections in children after successful ureteral reimplantation versus endoscopic dextranomer/hyaluronic acid implantation*. J Urol 2008; 179 (6): 2364-2367; discussion 2367-2368.
- Capozza N, Lais A, Matarazzo E et al: *Treatment of vesico-ureteric reflux: a new algorithm based on parental preference*. BJU Int 2003; 92 (3): 285-288.
- Capozza N, Caione P: *Dextranomer/hyaluronic acid copolymer implantation for vesico-ureteral reflux: a randomized comparison with antibiotic prophylaxis*. J Pediatr 2002; 140 (2): 230-234.
- Hensle TW, Hyun G, Grogg AL et al: *Part 2: Examining pediatric vesicoureteral reflux: a real-world evaluation of treatment patterns and outcomes*. Curr Med Res Opin 2007; 23 Suppl. 4: S7-13.
- Lendvay TS, Sorensen M, Cowan CA et al: *The evolution of vesicoureteral reflux management in the era of dextranomer/hyaluronic acid copolymer: a pediatric health information system database study*. J Urol 2006; 176 (4 Pt 2): 1864-1867.

Correspondence

Christian Schwentner
 Professor of Urology
 Department of Urology
 University Hospital Tübingen
 3, Hoppe-Seyler Street
 72076 Tübingen, Germany
 phone: 07071/29 803 49
 christian.schwentner@googlemail.com