

Received: 2016.06.23
Accepted: 2016.09.22
Published: 2016.12.20

ISSN 1941-5923
© Am J Case Rep, 2016; 17: 967-972
DOI: 10.12659/AJCR.900226

Desmoid Fibromatosis Presenting as Deep Venous Thrombosis: A Case Report and Discussion

Authors' Contribution:
Study Design A
Data Collection B
Statistical Analysis C
Data Interpretation D
Manuscript Preparation E
Literature Search F
Funds Collection G

AEF 1 **Lisa M. Marks**
AEF 2 **Susan J. Neuhaus**

1 Department of Phlebology and Laser, Adelaide Plastic Surgery, Adelaide, SA, Australia
2 Department of Surgery, University of Adelaide, Adelaide, SA, Australia

Corresponding Author: Lisa M. Marks, e-mail: lisamarks@apsa.com.au
Conflict of interest: None declared

Patient: **Male, 40**
Final Diagnosis: **Desmoid fibromatosis**
Symptoms: **Discomfort**
Medication: **—**
Clinical Procedure: **Surgery and radiotherapy**
Specialty: **Surgery**

Objective: **Rare disease**





Background: Venous thromboembolism (VTE), comprising deep vein thrombosis (DVT) and pulmonary embolism (PE), is a common, serious cardiovascular event. Predisposing factors include genetic disorders, immobility, and underlying malignancy. Soft tissue tumors are by contrast rare, but should be included in the differential etiology of DVT, especially when the patient is young and has few thrombotic risk factors.

Case Report: We present a 40-year-old patient whose initial diagnosis was spontaneous DVT of the lower leg, treated conventionally. Subsequently, he developed progressive calf swelling, which was diagnosed as multifocal desmoid fibromatosis, a rare and complex soft tissue tumor.

Conclusions: DVT is common but soft tissue tumors are rare. The disparity in incidence of these very distinct pathologies may contribute to late diagnosis of occult soft tissue pathology. We discuss the incidence, etiology, pathology, diagnosis, and best management of both desmoid fibromatosis and DVT, which may co-exist in a causative way.

MeSH Keywords: **Fibromatosis, Aggressive • Lower Extremity • Soft Tissue Neoplasms • Venous Thrombosis**

Full-text PDF: <http://www.amjcaserep.com/abstract/index/idArt/900226>

 2484   4  20



Background

Venous thromboembolism (VTE) is a common condition associated with significant clinical and economic burden [1]. In contrast, deep soft tissue tumors, both benign and malignant, are rare.

Occult neoplasms are a known risk factor for venous thromboembolic events. Accordingly, although rare, soft tissue neoplasms should be considered in the setting of spontaneous DVT and pulmonary embolus (PE), especially in young patients without risk factors.

Case Report

We present the case of a 40-year-old male, whose initial event was a lower limb DVT 3 years prior to the diagnosis of desmoid fibromatosis.

Original presentation was with pain and swelling in the left leg. A DVT was diagnosed on ultrasound.

There was no history of recent surgery, trauma, travel, or other predisposing causes; therefore, it was considered to be a spontaneous, unprovoked left lower limb VTE event.

He was fit and well, regularly cycling 12 km a day. There was no other relevant family or past medical history.

Thrombophilia screening was not performed at initial presentation or at subsequent public hospital outpatient follow-up appointments. This was offered but declined due to concerns about the impact on future medical insurance premiums and a lack of evidence that a positive screen would change his current management.

He was managed with standard anticoagulant therapy; subcutaneous enoxaparin (Clexane®) followed by oral vitamin K antagonist (Warfarin) for 6 months and the use of compression stockings. Eight months after the initial diagnosis, a repeat ultrasound demonstrated no evidence of persistent DVT.

Twenty-two months after cessation of anticoagulation, he represented with increasing diameter of his left calf and occasional discomfort. There were no other symptoms.

Ultrasound showed a heterogeneous lesion (11×4×3cm) with in the soleus muscle, and a similar but slightly smaller lesion beneath the fascia of the medial gastrocnemius muscle. A hematoma was proposed as the possible pathology. On this basis, he was managed conservatively with review planned at 3 months. Subsequent ultrasound showed an increase in size

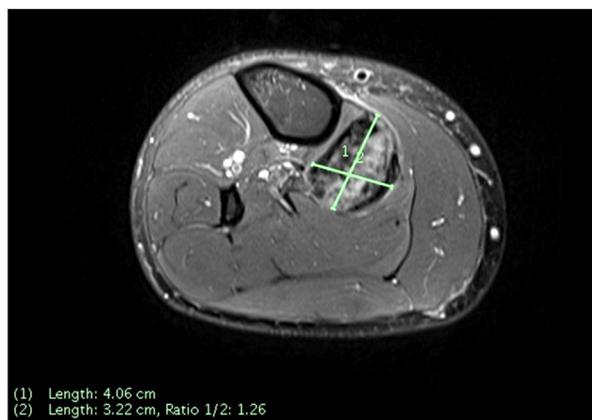


Figure 1. MRI image transverse calf.

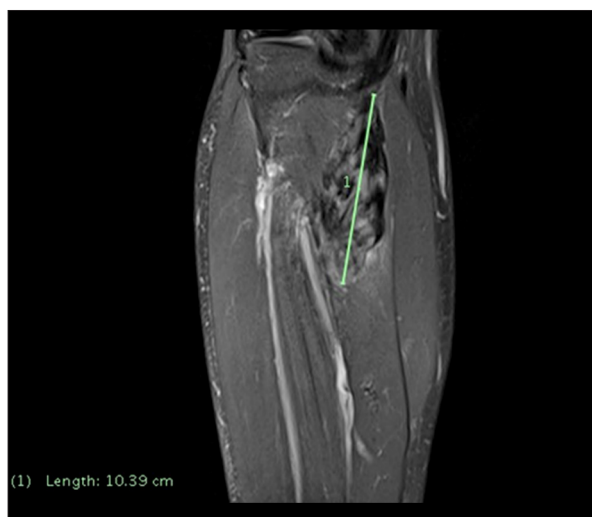

Figure 2. MRI image sagittal calf.

of the muscular lesions, so he was further investigated with magnetic resonance imaging (MRI) (see Figures 1, 2).

MRI demonstrated multifocal, infiltrative lesions located deep in the lower leg musculature corresponding with the lesions previously identified on ultrasound. These measured 21×9×61 mm and 41×3×104 mm. Positron emission tomography (PET) scanning demonstrated uptake of F-fluorodeoxyglucose (FDG) within the lesion and popliteal lymph nodes, suggesting regional metastatic involvement.

Core biopsies were performed and demonstrated features suspicious of a soft tissue sarcoma. The biopsy specimen showed a low-grade spindle cell neoplasm lacking well-developed myxoid areas or inflammatory components suggestive of possible fibromyxoid sarcoma.

He was managed in a multidisciplinary soft tissue tumor unit. Given the presumptive diagnosis of sarcoma and the multifocality of his disease, a decision for limb conservation was

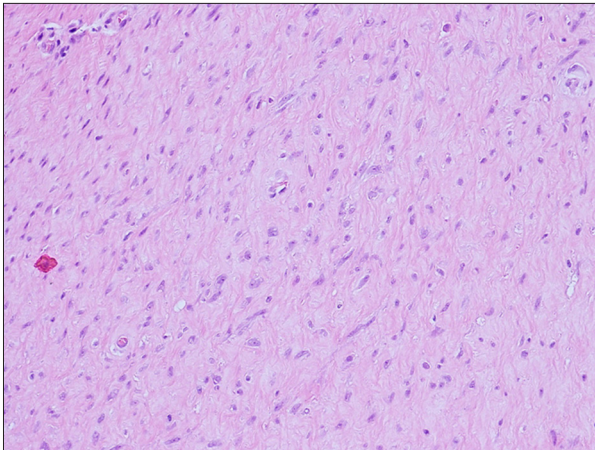


Figure 3. Histopathology.

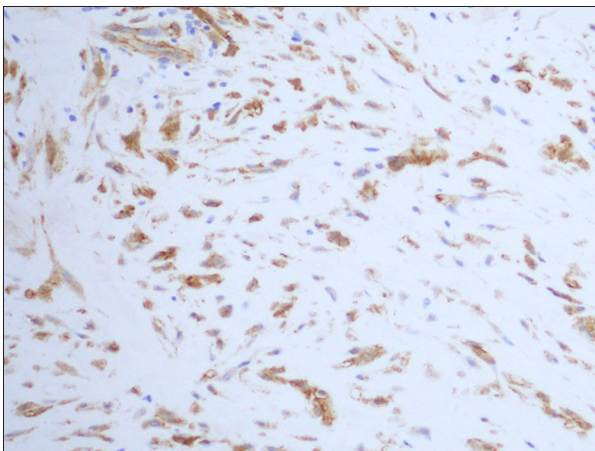


Figure 4. Staining for beta-catenin.

made. Preoperative radiotherapy was given, followed by surgical resection.

At surgery, the tumor was adherent to the tibial nerves, vessels, and periosteum. A wide compartmental resection was undertaken with preservation of the neurovascular structures.

Formal histopathological analysis of the resected surgical specimen demonstrated features consistent with a desmoid tumor (aggressive fibromatosis) rather than fibromyxoid sarcoma. Two separate tumor masses were contained within skeletal muscle, measuring 105 and 55 mm, respectively, in maximal diameter. Histopathological sections revealed loose fascicular aggregates of mildly pleomorphic spindle cells. On immunohistochemical staining, the tumor was positive for CD34, desmin, and nuclear β -catenin, indicating connective tissue or stromal cell involvement (see Figures 3, 4).

At the time of reporting, the patient had made a good functional recovery, was walking unaided, and had returned to work and cycling. He remains anticoagulated and wears compression

stockings. Further planned investigations include screening for the known genetic association of familial adenomatous polyposis (FAP).

Discussion

VTE comprising both deep vein thrombosis and pulmonary embolism is the third most common cardiovascular disease after myocardial infarction and stroke. VTE is common and associated with significant economic and clinical burden [1]. VTE incidence is 1–2 per 1000 in the general population and even higher in hospitalized patients [2].

In contrast, soft tissue tumors are uncommon. They may be benign or malignant [2–4]. Desmoid fibromatosis represents less than 3% of all soft tissue tumors [5].

DVT as a presentation of an underlying malignancy is well recognized and should always be considered in the differential diagnosis. The risk of VTE is 4–7 times higher in patients with cancer, due to mechanisms inherent to the cancer, the systemic effects of malignancy, and in response to cancer treatments [2].

Investigation in patients with suspected VTE includes history, examination, pulse oximetry, duplex ultrasonography of the affected and contra-lateral limb, D-dimer testing, and, if indicated, pulmonary investigations such as computed tomography pulmonary angiography (CTPA).

Thrombophilia screening may also provide useful clinical information, especially when predisposing factors are not evident. Follow-up imaging should be performed to monitor resolution of the thrombus.

Alternate imaging techniques should be employed if there is suspicion of soft tissue tumor or the clinical course varies from what is expected. MRI is superior to ultrasound in delineating soft tissue lesions, especially desmoid tumors [6]. Preoperative staging is indicated if malignancy is suspected [4].

Quality histological specimens are required to make management decisions. Biopsy tracts carry a theoretical risk of tumor seeding and should be located within the planned surgical field, such that they are excised during “en bloc” surgery [3,4]. A pathologist experienced in soft tissue disorders should examine the specimen [3,7]. Diagnosis relies on morphology, immunohistochemistry, and molecular biology [4]. The primary mimic of DF is fibromyxoid sarcoma [7].

When a soft tissue mass lesion is found, malignancy should be suspected if the mass is enlarging, greater than 5 cm in size, deep to deep fascia, and/or painful [4].

Anticoagulant therapy is the mainstay treatment for VTE. Current guidelines recommend low molecular weight heparin (LMWH) or fondaparinux initially, overlapping with a vitamin K antagonist (VKA). The VKA should then be continued solely and the LMWH or fondaparinux ceased once the international normalized ratio (INR) has reached the therapeutic range. The VKA is continued when long-term anticoagulation is required [1].

Desmoid fibromatosis (DF) is histologically benign; however, clinical management is similar to that for sarcoma and requires multidisciplinary management. Treatment options include observation, surgery, radiotherapy, adjuvant chemotherapy, hormonal therapy, non-steroidal anti-inflammatories, and targeted and cytotoxic therapy [6,8,9]. DF has no known inherent prothrombotic tendency but has the potential to cause DVT by compression or vessel encasement [8]. Prior to 2000, primary treatment aims were identical to those for soft tissue sarcoma, emphasizing clear surgical margins [7]. More recently, clear margin status has been tempered with prioritization of functional outcomes [7,9].

In some specialized centers, patients with progressive, locally invasive extremity DF have been treated with isolated limb perfusion with tumor necrosis factor alpha (TNF- α) and melphalan [7].

The World Health Organization (WHO) definition of desmoid fibromatosis is “a fibroblastic proliferation that arises in deep soft tissues and is characterized by infiltrative growth and a tendency towards local recurrence but an inability to metastasize” [7]. It is classified by anatomical location: intra- or extra-abdominal [10,11]. McFarlane published the first case report in 1832 with the term “desmoid tumor” coined by Muller in 1838 [5].

Derived from the Greek word *desmos*, meaning “tendon-like”, these monoclonal tumors arise from mesenchymal cells. They may be multifocal and locally infiltrative, growing along fascial planes and muscle fibers. They lack a pseudo-capsule and may arise from muscle fascia, and may affect any part of the body, including extremities and abdomen [6–8,12,13].

There is wide variation in presentation and clinical behavior of these tumors. They are most prevalent in patients 15–60 years of age, with peak incidence at age 30 years [6–10,14].

DF has an estimated annual incidence of 2–4 per million or approximately 0.03% of all neoplasms, with a slight female preponderance [5,6,8,13]. This sex difference relates to the known association of these tumors with high oestrogen states such as in pregnancy and oral contraceptive use. Trauma and surgery are additional risk factors [5–7].

Macroscopically, DF tumors are dense, nodular, bulky masses with spiculated extensions along tissue planes. Multifocality is seen in 10% of cases [7].

Histologically, desmoid tumors show monoclonal spindle-shaped fibroblasts in a dense, voluminous, collagenous matrix [6]. Myofibroblasts may be seen oriented in a fascicular pattern with abundant, dilated, rough endoplasmic reticulum [10]. Vessels are evenly spaced in the tumor, and myxoid (mucous-like) changes may be seen [7]. Encapsulation and necrosis are not seen with DF [10,15]. Differentiation from fibromyxoid sarcoma is of paramount importance [10].

Cytologically, DF cells lack malignant features. Molecular studies show DF is the result of a clonal process and not the product of an intense inflammatory fibrous reaction [9,14].

Markers include smooth muscle antibodies (denoting presence of smooth muscle), vimentin (mesenchymal cell marker), and β -catenin (cell adhesion molecule) [10].

Clinical presentation is often with a painless mass. On occasion, there are symptoms due to compression of local structures [10].

Desmoid fibromatosis may be sporadic or inherited, each with distinct underlying genetic mutations. Sporadic DF demonstrates mutations in the CTNNB1 gene in 80% of cases, whereas hereditary tumors show genetic abnormalities most frequently in the adenomatous polyposis coli (APC) gene on 5q21-q22 [6,10,12,15]. Hereditary desmoids may arise in individuals affected by polyposis syndromes, most notably Gardner's syndrome and familial adenomatous polyposis (FAP) [7,11,12,16].

Patients with Gardner's syndrome have both colonic polyposis and coexistent extra-colonic tumors, including sebaceous and epidermoid cysts, fibroids, desmoid tumors, and osteomas. Gardner's syndrome carries a 5–15% risk of developing a desmoid tumor as one of its potential extra-intestinal manifestations.

FAP is inherited in an autosomal dominant manner, with 80% showing mutations in the APC gene. This leads to inactivation of the *Wnt* signalling pathway, uncontrolled cell growth, and accumulation of β -catenin [9,11].

Due to the strong association between these polyposis syndromes and DF, colonic screening should be undertaken in all fibromatosis patients [9].

Imaging of DF tumors shows variable texture lacking central necrosis. Magnetic resonance imaging (MRI) is the ideal modality for characterizing DF. MRI allows delineation of size, depth, invasion, and neurovascular involvement. Gadolinium

uptake may show moderate or avid enhancement. Appearances may vary within or between lesions, but low signal intensity on T2-weighted images generally represents fibrous tissue. Other features in DF include an infiltrative pattern and multiplicity. Fibromyxoid sarcoma has a similar appearance, making biopsy essential [6,7].

Ultrasound provides information about adjacent soft tissue and vascular structures. Duplex ultrasound is the first-line investigation if deep vein thrombosis or vessel involvement is suspected. PET scanning is increasingly being used in preoperative delineation of tumor extent, possible metastatic spread, and response to treatment [7].

Management in a multidisciplinary soft tissue tumor unit with an individualized treatment plan is recommended due to the varied presentation, clinical behavior, and range of treatment options available for these tumors [7,13].

Systemic therapies include non-steroidal anti-inflammatories (NSAIDs), hormonal therapies, tyrosine kinase inhibitors, cytotoxic chemotherapy regimens, and interferon [6,10,15,8].

There may be variability in response to therapies due to underlying genetic mutations [6,9]. Fibroblasts have been shown to proliferate in response to estrogen, and receptors have been identified on a subset of DF tumors; therefore, anti-estrogen hormonal therapies have been implemented in some cases of DF [5,6,9].

Radiotherapy may be used pre- or postoperatively, depending on tumor characteristics and management decisions. Preoperative radiotherapy may be employed if malignancy is suspected or confirmed, or postoperatively if there are positive margins or recurrent disease [9]. Radiotherapy aims to aid in local control of DF, both in adjuvant and primary settings [13,17].

Cytotoxic chemotherapy agents are an alternative treatment option in DF. The regimes used are commonly doxorubicin based or combined low dose vinblastine and methotrexate [6,9].

Although there are some reports of success, a judgement must be made about the use of a potentially toxic agent in a localized, benign disease [9]. In extremity DF, where curative surgery may adversely affect functional outcome, isolated limb perfusion with tumor necrosis factor alpha (TNF α) and melphalan may be an effective option [7].

Surgical resection is the primary treatment modality in extremity tumors [9]. DF has an infiltrative growth pattern, which may result in a high recurrence rate. Some authors have reported that positive margins increase the risk of local recurrence, but others have found no difference in local recurrence rates with

either positive or negative margins. This is one of the enigmas in the behavior of these tumors [9]. Functional preservation is a high priority when planning surgical interventions [6,7].

In addition, a wait-and-watch approach has been successfully employed in management of some cases of DF [7,17].

Supportive measures such as pain and symptom control, psychological counselling, social support, education, and access to rehabilitation are also important aspects of management. A plan for long-term ongoing surveillance and management is essential [5,7].

Survival is approximately 96% at 15 years, but this does not reflect the morbidity associated with this disease [5]. Spontaneous regression may occur in 5–15% of cases [7,9]. Macroscopically clear resection margins should be the primary aim of treatment but should be balanced with functional and structural preservation [9,17].

Predictors of local recurrence include age at diagnosis and the size and location of the primary tumor [9]. Recurrences are seen in 20–68% of patients, most frequently at 1.5–5 years after initial treatment [6].

Age younger than 26 years is associated with higher recurrence, as is tumor size greater than 10 cm in maximum diameter. Abdominal wall tumor location is associated with the best prognosis, while chest wall, intra-abdominal, and extremity locations are associated with worse prognostic outcomes [18]. Neither margin status nor radiotherapy was found to be statistically significant in affecting outcome [18].

Overall, local disease control rates are approximately 75% at 5 years. Gross or residual disease may not affect survival [9].

Conclusions

This case highlights the need to consider less common potential differential diagnoses in the presentation of DVT, partly due to the absence of etiological factors. We also highlight the need for serial imaging and clinical follow-up. Imaging may need to include repeated ultrasounds or the use of alternative imaging modalities such as CT or MRI. There should be a high index of suspicion in patients with symptoms that are not resolving or who re-present.

The red flags in this case are the patient's young age and lack of risk factors for deep vein thrombosis. Persistence or recurrent symptomatology may indicate other underlying pathologies, although post-thrombotic syndrome should also be considered [2,3]. Furthermore, recurrent or refractory venous thrombosis should alert the treating practitioner to occult pathology [2].

This case highlights the need for a systematic approach to investigation and management of patients presenting with venous thromboembolism. Soft tissue tumors should be considered in the differential.

Acknowledgements

We would like to acknowledge the assistance of Dr. S. McCoy in the preparation of this manuscript. Assistance was with

writing preparation, proof reading, language, technical editing, and critical reviewing of the manuscript.

In addition, we also thank Dr. Craig James of Adelaide Pathology Partners for provision of the histopathology images.

Conflicts of interest

None.

References:

1. Macrae S: Treatment options for venous thromboembolism: Lessons learnt from clinical trials. *Thromb J*, 2014; 12: 27
2. Perisano C, Maffuli N, Colelli P et al: Misdiagnosis of soft tissue sarcomas of the lower limb. *BMC Musculoskel Disord*, 2011; 14: 64
3. Clark MA, Fisher C, Judson I, Thomas JM: Soft tissue sarcomas in adults. *N Engl J Med*, 2005; 353: 701–11
4. Grimer R, Judson I, Peake D, Seddon B: Guidelines for the management of soft tissue sarcomas. *Sarcoma*, 2010; 2010: 506182
5. Kallam AR, Ramakrishna BV, Kishore GR, Karthik KRV: Desmoid tumors: Our experience of six cases and review of the literature. *J Clin and Diag Res*, 2014; 8(10): NE01–04
6. Devata S, Chugh R: Desmoid tumor. A comprehensive review of the evolving biology, unpredictable behaviour, and myriad of management options. *Hematol Oncol Clin N Am*, 2013; 27: 989–1005
7. Kasper B, Baumgarten C, Bonvalot S et al. Desmoid Working Group: Management of sporadic desmoid-type fibromatosis: a European consensus approach based on patients' and professionals' expertise – A sarcoma Patients EuroNet and European Organisation for Research and Treatment of Cancer/Soft Tissue Bone and Sarcoma Group initiative. *Eur J Cancer*, 2015; 51: 127–36
8. Hamada S, Futamura N, Ikuta K et al: CTNNB1 S45F mutation predicts poor efficacy of meloxicam treatment for desmoid tumors: A pilot study. *PLoS One*, 2014; 9(5): e0096391
9. Hong H, Nadesan P, Poon R, Alman BA: Testosterone regulates cell proliferation in aggressive fibromatosis (desmoid tumour). *Br J Cancer*, 2011; 104: 1452–58
10. Palladino E, Nsenda J, Siboni R, Lechner C: A giant mesenteric desmoid tumour revealed by acute pulmonary embolism due to compression of the inferior vena cava. *Am J Case Rep*, 2014; 15: 374–77
11. Lewis JL, Boland PJ, Leung DHY, Woodruff JM: The enigma of desmoid tumors. *Ann Surg*, 1999; 229(6): 866–72; discussion 872–73
12. Fisher C, Thway K: Aggressive fibromatosis. *Pathology*, 2014; 46(2): 135–40
13. Nicolas G, Kfoury T, Shimplati R et al: Incidental finding and management of mesenteric fibromatosis. *Am J Case Rep*, 2016; 17: 389–94
14. Robanus-Maandag R, Bosch C, Amini-Nik S et al: Familial adenomatous polyposis-associated desmoids display significantly more genetic changes than sporadic desmoids. *PLoS One*, 2011; 6(9): e24354
15. Von Allmen D: Intestinal polyposis syndromes: progress in understanding and treatment. *Curr Opin Paediatr*, 2006; 18: 316–20
16. Slowik V, Attard T, Dai H et al: Desmoid tumors complicating Familial Adenomatous Polyposis: A meta-analysis mutation spectrum of affected individuals. *BMC Gastroenterol*, 2015; 15: 84
17. Kucuk L, Kececi B, Sabah D, Yuceturk G: Aggressive fibromatosis: Evaluation of prognostic factors and outcomes of surgical treatment. *Acta Orthop Traumatol Turc*, 2014; 48(1): 55–60
18. Place T, Mezahir JJ: Molecular characterization of desmoid tumors: decryption of the enigma. *Editorial. Onkologie*, 2012; 35: 641–42
19. Prodingier PM, Rechi H, Keller M et al: Surgical resection and radiation therapy of desmoid tumors of the extremities: results of a supra-regional tumour centre. *Int Orthop*, 2013; 37(10): 1987–93
20. Crago AM, Denton B, Salas S et al: A prognostic nomogram for prediction of recurrence in desmoid fibromatosis. *Ann Surg*, 2013; 258(2): 347–53