

# Catheter-directed thrombectomy with the JETi8 in the treatment of acute superior vena cava syndrome

Raffaella Emsley, Claude Haller, MD, and Laure Arts, MD, Sion, Switzerland

## ABSTRACT

Superior vena cava syndrome can lead to significant morbidity and mortality, particularly in acute settings. We report a case of an acute Port-a-Cath-associated thrombosis of the superior vena cava. Percutaneous catheter-directed thrombectomy was performed using the JETi8 thrombectomy device with additional angioplasty and stenting, allowing rapid flow restoration and rapid clinical recovery. Postoperative anticoagulation was initiated and pursued lifelong. This report is unique in illustrating how JETi8 thrombectomy seems to be a safe and effective therapy, allowing rapid flow restoration, rapid clinical improvement, and persistent patency at 6 months. (*J Vasc Surg Cases Innov Tech* 2022;8:545-8.)

**Keywords:** Superior vena cava syndrome; Catheter-directed thrombectomy; JETi8 thrombectomy system; Abre stent

Increased use of intravenous devices has led to a higher rate of superior vena cava syndrome (SVCS). Although malignant causes remain the most frequent etiology, intravenous device-related SVCS accounts for approximately 30% of cases.<sup>1</sup> SVCS can lead to significant morbidity and mortality, particularly in acute life-threatening SVC obstruction. We report a case of acute severe SVCS, treated with JETi8 thrombectomy followed by angioplasty and stenting of the SVC. The patient consented to the procedure and the publication of this case report.

## CASE REPORT

We present the case of a 56-year-old woman with a history of breast cancer treated surgically followed by radiochemotherapy through a Port-a-Cath (PAC) placed in the left subclavian vein 3 years ago; currently taking hormone therapy (anastrozole). She presented to the emergency with severe upper body edema, facial cyanosis, and mild consciousness alteration. She reported intermittent upper body edema after receiving the second dose a severe acute respiratory syndrome coronavirus 2 vaccine 3 months earlier. Computed tomography angiography (CTA) was performed 1 month ago showing patent SVC and well-placed PAC (Fig 1) No other measures were taken; however, intermittent facial edema persisted.

At admission, she was hemodynamically stable (137/74 mm Hg) with mild tachypnea (25/min) and patent airways. Anaphylaxis was initially suspected and clemastine, methylprednisolone, and ephedrine were administered. CTA showed complete SVC occlusion over 5 cm (Fig 2), with the tip of the PAC in the right subclavian vein. Ultrasound examination revealed no extremity deep vein thrombosis (DVT), but the absence of blood flow in the subclavian, axillar, and jugular veins owing to upstream SVC occlusion.

She became hemodynamically unstable presenting hypotension (89/67 mm Hg) and tachycardia (100/min). A massive pulmonary embolism was suspected, which warranted administration of systemic thrombolysis and ephedrine. A transthoracic echocardiogram showed no signs of massive pulmonary embolism. The instability was short-lived and needed no further acute interventions. She was then transferred to the intensive care unit for surveillance. Intravenous unfractionated heparin was initiated. An endovascular thrombectomy was planned for the next day because the necessary inventory was not immediately available.

Intervention was performed in supine position under general anesthesia. Venous access was achieved through a left femoral central venous catheter. A hydrophile, 0.035-inch, stiff guidewire was inserted and the central venous catheter replaced with a 6F sheath. A pigtail catheter was placed in the SVC under fluoroscopy. Phlebography showed a complete venous thrombosis at the superior cavoatrial junction with patent innominate, jugular, and subclavian veins (Fig 3, A) The pigtail was replaced for a long steerable guiding sheath Ocor Destino Twist of 8.5F. The occlusion was passed using the guidewire and a vertebral catheter up to the right subclavian vein. We performed percutaneous catheter-directed thrombectomy of the SVC using the JETi 8F device (Abbott, Walk Vascular, LCC, Abbott Park, IL) inserted through the sheath allowing a rotational directed thrombectomy, without additional lysis. Phlebography showed flow restoration with residual stenosis (Fig 3, B and C) Angioplasty of the SVC was performed using a high-pressure AltoSa XL Percutaneous Transluminal Angioplasty balloon (AndraTec) of 14 mm

From the Department of Vascular Surgery, Centre Hospitalier du Valais Romand.

Author conflict of interest: none.

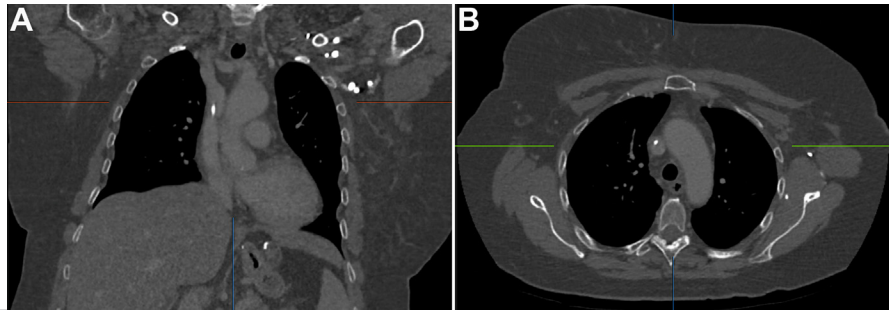
Correspondence: Laure Arts, MD, Av du Grand-Champsec 80, CH-1950 Sion, Switzerland (e-mail: [lauremarie.arts@hopitalvs.ch](mailto:lauremarie.arts@hopitalvs.ch)).

The editors and reviewers of this article have no relevant financial relationships to disclose per the Journal policy that requires reviewers to decline review of any manuscript for which they may have a conflict of interest.

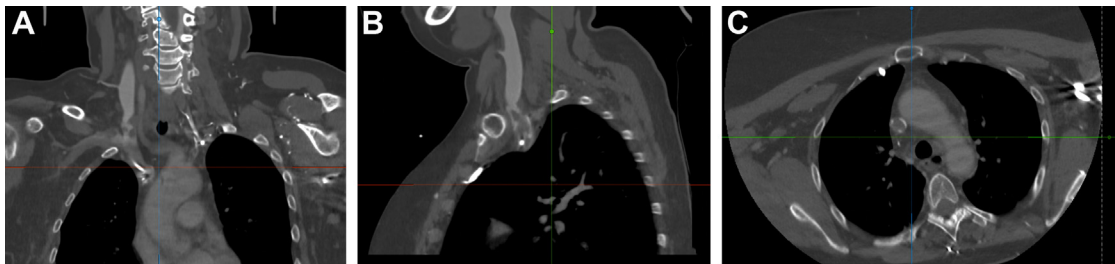
2468-4287

© 2022 The Authors. Published by Elsevier Inc. on behalf of Society for Vascular Surgery. This is an open access article under the CC BY-NC-ND license (<http://creativecommons.org/licenses/by-nc-nd/4.0/>).

<https://doi.org/10.1016/j.jvscit.2022.07.009>



**Fig 1.** Coronal (A) and axial (B) computed tomography (CT) images showing patent superior vena cava (SVC) and a well-placed Port-a-Cath (PAC) 1 month before admission.



**Fig 2.** Coronal (A), sagittal (B) and axial (C) computed tomography (CT) images showing a superior vena cava (SVC) occlusion. Port-a-Cath (PAC) in the left subclavian vein with its distal extremity in the right subclavian vein (A).

followed by a 16-mm balloon, allowing deployment of an Abre stent of 16 × 60 mm (Medtronic, PLC, Dublin, Ireland). Phlebography showed total SVC recanalization without residual stenosis and complete stent deployment (Fig 3, D). The PAC was withdrawn over a guidewire under fluoroscopy. Immediate clinical improvement was seen with complete regression of facial cyanosis and edema. She returned to intensive care unit for surveillance and was extubated on postoperative day 2. Low-molecular-weight heparin followed by oral anticoagulation (rivaroxaban 20 mg/day) were introduced and pursued lifelong. Rapid clinical recovery allowed discharge after 9 days. Postoperative CTA at 1 (Fig 4) and 6 months showed persistent vessel patency without clinical complications. A screening for thrombophilia showed a heterozygote mutation of prothrombin (factor II) G20210A.

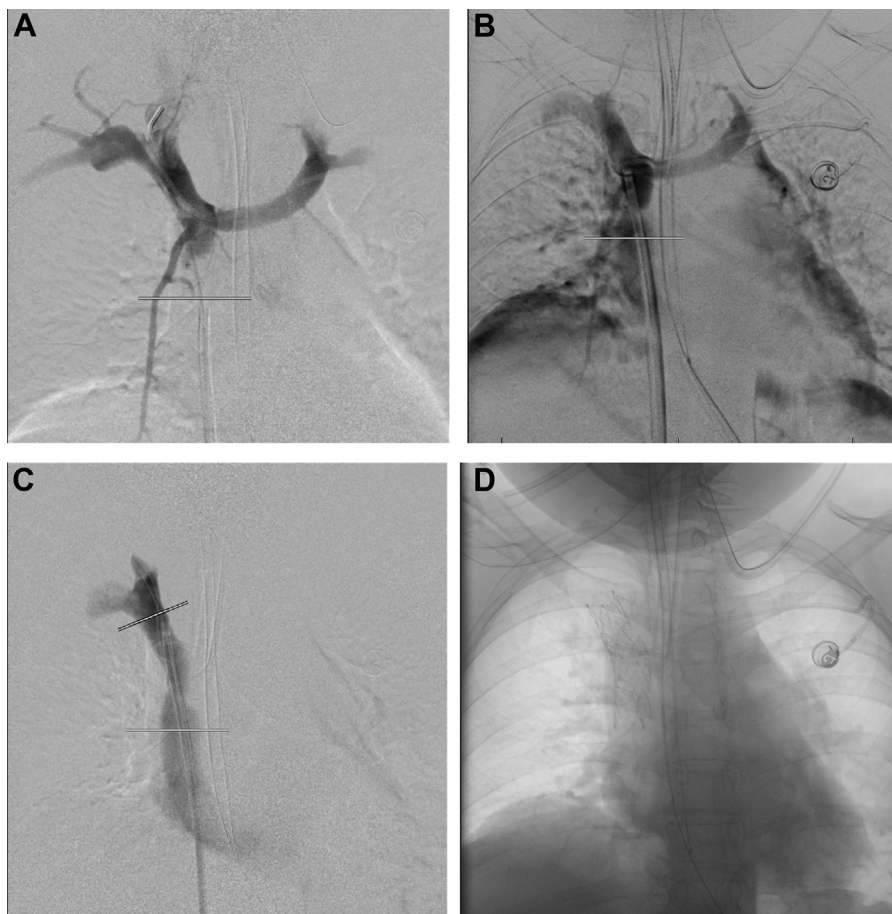
## DISCUSSION

Severe SVCS is rare. However, its incidence is increasing owing to the use of indwelling catheters.

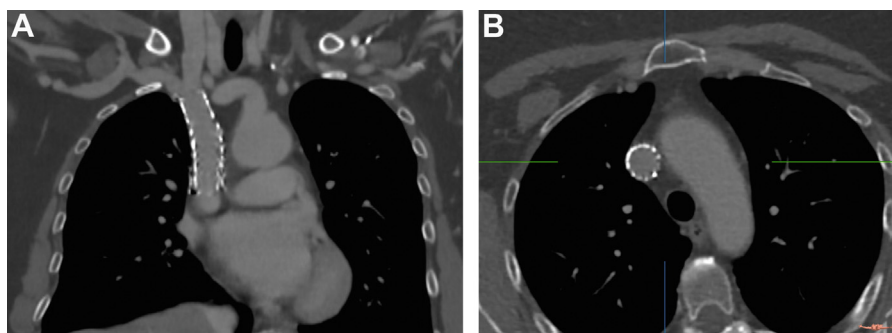
Complete SVC obstruction is only seen in 0.1% to 3.3% of patients, but can be life threatening and requires emergent treatment.<sup>2</sup> Still, no official guidelines for the management of SVCS have been established. Although no randomized trials have been conducted, endovascular treatment of SVCS is currently considered as the first-line treatment.<sup>3</sup> Catheter-directed thrombolysis has been described extensively as an efficient treatment for SVC obstruction with successful outcomes.<sup>4</sup> However, it involves prolonged infusion of thrombolytic agents,

which can lead to a high rate of hemorrhage.<sup>5,6</sup> Also, the rates of rethrombosis can be significant and long-term patency compromised.<sup>7</sup>

Another possibility is catheter-directed thrombectomy, allowing a single-session treatment. It is known that for prompt symptoms relief, rapid recanalization of the SVC is necessary.<sup>8,9</sup> Catheter-directed thrombectomy minimizes the rate of catheter-directed thrombolysis-associated complications such as overnight thrombolytic infusions, hemorrhaging, or hemolytic complications. Only three cases were reported on the use of rheolytic thrombectomy in SVCS, all using the AngioJet thrombectomy device. Rapid relief of SVCS symptoms and SVC patency was achieved with effective short-term clinical success without complications.<sup>2,10,11</sup> However, potentially life-threatening adverse effects have been described with the AngioJet device. A vacuum effect, created by its saline jet, leads to indirect clot aspiration with residual systemic clots fragments, possibly causing hemolysis.<sup>12</sup> Other thrombectomy devices used in peripheral DVT such as end hole aspiration devices can be obstructed when large volumes of thrombi are crossed.<sup>13</sup> The JETi8 thrombectomy system is a single lumen catheter that combines clot fragmentation through a pressurized saline jet with active clot aspiration, minimizing dissemination. It received US Food and Drug Administration clearance in October 2016 for the treatment of coronary and peripheral vessel thrombosis. Only a few studies describe its use, safety, and efficacy in the treatment of



**Fig 3.** Intraoperative phlebography. **A**, Complete venous thrombosis of the superior cavoatrial junction. **B**, Phlebography after JETi8 thrombectomy. **C**, Residual stenosis of the superior vena cava (SVC). **D**, Successful deployment of the Abre stent and complete recanalization of the SVC.



**Fig 4.** Coronal (**A**) and axial (**B**) computed tomography (CT) images showing a patent stent in the superior vena cava (SVC).

acute ilio caval and iliofemoral DVT and none in the SVC. As compared with the Angiojet, no hemolysis was reported with the JETi8.<sup>13-16</sup>

In this case, the thrombus was removed efficiently and blood flow restored without additional thrombolysis. Residual stenosis was seen. Additional stenting in the treatment of SVC occlusion is often needed, especially in chronic lesions or extrinsic compression, and increases

long-term patency.<sup>17,18</sup> In this case, balloon angioplasty and anticoagulation could have sufficed. Still, we opted for stenting so as to ensure long-term patency. There are few dedicated venous stents on the market. A Wallstent (Boston Scientific, Marlborough, MA) of 24 × 70 mm was initially considered; however, because of its flexibility, deployment accuracy can be impaired and stent length can be variable. In this case, the stent

would have protruded into the right atrium.<sup>19</sup> Therefore, we chose the Abre (Medtronic, PLC) stent, a venous self-expandable nitinol stent, CE and US Food and Drug Administration approved (respectively in 2017 and 2020) for the treatment of symptomatic iliofemoral DVT. An ongoing investigational device exemption study (ABRE CSR v1.2 30/JUL/2020) shows easy and accurate stent deployment all the while ensuring radial strength and crush resistance without compromising flexibility.<sup>19</sup> Although this case describes an off-label use of the Abre stent, deployment was precise with a satisfying venogram.

Prothrombin G20210A mutation increases the risk of DVT by two- to five-fold. Hormone therapy is also a known risk factor for venous thromboembolism.<sup>20</sup> This patient combined several risk factors for acute SVCS. Considering these risk factors, despite successful SVC recanalization and PAC removal, there is an indication for life-long anticoagulation.

## CONCLUSIONS

Urgent antegrade flow restoration is essential in acute life-threatening SVCS. The JETi8 thrombectomy system combined with angioplasty and stenting of the SVC seems to be an efficient and safe, percutaneous treatment of acute SVCS. It allows immediate flow restoration and clinical improvement with persistent patency at 6 months follow-up without complications.

## REFERENCES

1. Azizi AH, Shafi I, Shah N, Rosenfield K, Schainfeld R, Sista A, et al. Superior vena cava syndrome. *JACC Cardiovasc Interv* 2020;13:2896-910.
2. Ramjit A, Chen J, Konner M, Landau E, Ahmad N. Treatment of superior vena cava syndrome using AngioJet™ thrombectomy system. *CVIR Endovasc* 2019;2:28.
3. Azizi AH, Shafi I, Zhao M, Chatterjee S, Roth SC, Singh M, et al. Endovascular therapy for superior vena cava syndrome: a systematic review and meta-analysis. *EClinicalMedicine* 2021;37:100970.
4. Kearon C, Akl EA, Ornelas J, Blaivas A, Jimenez D, Bounameaux H, et al. Antithrombotic therapy for VTE disease. *Chest* 2016;149:315-52.
5. Harrison B, Hao F, Koney N, McWilliams J, Moriarty JM. Caval thrombus management: the data, where we are, and how it is done. *Tech Vasc Interv Radiol* 2018;21:65-77.
6. Kalra M, Sen I, Gloviczki P. Endovenous and operative treatment of superior vena cava syndrome. *Surg Clin North Am* 2018;98:321-35.
7. Rizvi AZ, Kalra M, Bjarnason H, Bower TC, Schleck C, Gloviczki P. Benign superior vena cava syndrome: stenting is now the first line of treatment. *J Vasc Surg* 2008;47:372-80.
8. Lanciego C, Chacón JL, Julián A, Andrade J, López L, Martínez B, et al. Stenting as first option for endovascular treatment of malignant superior vena cava syndrome. *Am J Roentgenol* 2001;177:585-93.
9. O'Sullivan GJ, Mhuirheartaigh JN, Ferguson D, DeLappe E, O'Riordan C, Browne AM. Isolated pharmacomechanical thrombolysis plus primary stenting in a single procedure to treat acute thrombotic superior vena cava syndrome. *J Endovasc Ther* 2010;17:115-23.
10. Sessions KL, Anderson JH, Johnson JN, Taggart NW. Angiojet™ thrombolysis of SVC thrombosis after orthotopic heart transplantation: a case report. *Pediatr Transpl* 2016;20:723-6.
11. Amberger H, Baumgartner I, Kucher N, Schindewolf M. Endovascular Port-a-Cath rescue in acute thrombotic superior vena cava syndrome. *J Vasc Surg Cases Innov Tech* 2019;5:169-73.
12. Karthikesalingam A, Young EL, Hincliffe RJ, Loftus IM, Thompson MM, Holt PJE. A systematic review of percutaneous mechanical thrombectomy in the treatment of deep venous thrombosis. *Eur J Vasc Endovasc Surg* 2011;41:554-65.
13. Rohr AM, Kuo WT. Single-session pharmacomechanical catheter-directed thrombolysis using the JETi thrombectomy device for acute iliofemoral deep vein thrombosis refractory to therapeutic anticoagulation. *J Vasc Interv Radiol* 2019;30:1682-5.e1.
14. Courmoyer-Rodrigue J, Bui T-B, Gilbert P, Soulez G, Perreault P, Bouchard L, et al. Percutaneous thrombectomy with the JETi8 peripheral thrombectomy system for the treatment of deep vein thrombosis. *J Vasc Interv Radiol* 2020;31:444-53.e2.
15. Razavi C, Khalsa B, Openshaw L, Razavi MK. Single-session treatment of patients with symptomatic ilioacaval and iliofemoral deep vein thrombosis: technical results of a prospective pilot study. *J Vasc Interv Radiol* 2022;33:183-8.
16. Kasirajan K, Gray B, Ouriel K. Percutaneous AngioJet thrombectomy in the management of extensive deep venous thrombosis. *J Vasc Interv Radiol* 2001;12:179-85.
17. Urruticoechea A. Treatment of malignant superior vena cava syndrome by endovascular stent insertion Experience on 52 patients with lung cancer. *Lung Cancer* 2004;43:209-14.
18. Bornak A, Wicky S, Ris H-B, Probst H, Milesi I, Corpataux J-M. Endovascular treatment of stenoses in the superior vena cava syndrome caused by non-tumoral lesions. *Eur Radiol* 2003;13:950-6.
19. Shamimi-Noori SM, Clark TWI. Venous stents: current status and future directions. *Tech Vasc Interv Radiol* 2018;21:113-6.
20. Ahmed AOE, Elfert KA, Mahfouz AE, Othman FS, Elgassim LA, Yassin MA. Complete superior and inferior vena cava obstruction associated with systemic-to-pulmonary venous shunts in a young female with heterozygous prothrombin G20210A gene mutation. *Case Rep Oncol* 2020;13:515-21.

Submitted Mar 24, 2022; accepted Jul 17, 2022.