

# Lipofibromatous Hamartoma of Digital Nerve: A Case Report

Mohammad M. Soffar, MS\*

Geylan Fadali, GF†

Mahmoud A. Ghalab, MG‡

Ahmed M. Abouzaid, AAS§

**Summary:** A 9-year-old girl was investigated for a long-standing soft tissue swelling in her ring digit that recently developed tenderness and rapid growth within the last 3 months before presentation. Exploration of the swelling was done meticulously with total excision of the swelling from within its attachment to the digital nerve. The swelling was then sent for histopathological examination. The pathology report stated the presence of mature adipose tissue intersected by fibrocellular collagenic stroma infiltrating perineurium, epineurium, and nerve fascicles, which established the diagnosis of lipofibromatous hamartoma (LFH) of the nerve. LFH is a rare benign neoplasm that mainly affects the median nerve, but other nerves all over the body were also reported. Women are more affected than men. (*Plast Reconstr Surg Glob Open* 2021;9:e3981; doi: [10.1097/GOX.0000000000003981](https://doi.org/10.1097/GOX.0000000000003981); Published online 7 December 2021.)

## INTRODUCTION

Lipofibromatous hamartoma (LFH) is a part of a spectrum of adipose tumors of the nerve ranging from compressive external lipomas to diffuse interfascicular fibroadipose proliferation.<sup>1</sup> LFH is a rare benign fibro-fatty tumor characterized by the proliferation of the mature adipocytes within the epineurium and perineurium of the peripheral nerves. The etiology of such a condition is unknown but it likely has a congenital origin.<sup>2</sup>

The median nerve is the most commonly affected nerve accounting for 80% of cases according to literature. Ulnar, radial, sciatic, plantar, and brachial plexus nerves were also reported but were less commonly affected. Also, 62% of cases are associated with macrodactyly, which affects women more prominently than men.<sup>3</sup>

Such a benign tumor was first described by Mason in 1953. WHO established the term lipomatosis of the nerve (LN) in 2002.<sup>4</sup> Many nomenclatures have been used to describe such conditions since then, including

lipofibroma, fibrolipoma, fibrofatty proliferation, and fatty or fibrous neoplasm of the nerve and nerve lipomatosis.<sup>3</sup>

## CASE REPORT

### History

A 9-year-old girl presented with a painless slowly growing mass at the volar aspect of her right ring digit. The condition started 1 year before presentation as described by the parents, and rapid progression was noted by her parents 3 months before presentation.

### Examination

On examination, there was a firm, ill-defined, irregular, nontender, well-circumscribed swelling that was tethered to the overlying skin. There was no numbness at the digit but there was limitation of digit flexion.

Routine laboratory investigations were ordered and their results were within the normal range for age and gender.

Ultrasonography was also ordered and described a heterogeneous soft tissue mass lesion measuring 10 × 6 mm in maximum dimensions, abutting on the flexor tendon with suspected invasion to the ventral aspect of the interphalangeal joint with minimal detected internal vascularity by color Doppler.

### Procedure

Under general anesthesia and local ring block infiltration with a tourniquet around the left arm, Z-plasties were made for good exposure. With loupes magnification meticulous exploration and dissection of the mass from the overlying skin, then dissection was done to

From the \*Plastic, Reconstructive Surgery and Burn Therapy Department, Faculty of Medicine, Alexandria University, Alexandria, Egypt; †Faculty of Medicine, Medical Research Institute, Alexandria University, Alexandria, Egypt; ‡Radiology, Radiodiagnosis and Intervention Department, Faculty of Medicine, Kafrelsheikh University, Kafr el-Sheikh, Egypt; and §Plastic, Reconstructive Surgery, and Burn Therapy Department, Aboqir General Hospital, Alexandria, Egypt.

Received for publication May 28, 2021; accepted October 19, 2021.

Copyright © 2021 The Authors. Published by Wolters Kluwer Health, Inc. on behalf of The American Society of Plastic Surgeons.

This is an open-access article distributed under the terms of the Creative Commons Attribution-Non Commercial-No Derivatives License 4.0 (CCBY-NC-ND), where it is permissible to download and share the work provided it is properly cited. The work cannot be changed in any way or used commercially without permission from the journal.

DOI: [10.1097/GOX.0000000000003981](https://doi.org/10.1097/GOX.0000000000003981)

**Disclosure:** The authors have no conflict of interest in relation to the content of this article.

avoid any neural injury, as the mass involved the digital nerve, emerging from the ulnar side digital nerve abutting the flexor tendons and the radial side digital nerve. (Figs. 1–3).

Histopathological examination (Fig. 4) showed an ovoid firm to rubbery well-defined swelling measuring 2 × 1.2 cm with soft yellowish lobulated surface. Microscopically, specimens were stained by H&E stain and examined under light microscopy magnification to the power of 400x; examination showed mature adipose tissue intersected by fibrocellular collagenic stroma. The growth was infiltrating the nerve fascicles and both the epineurium and the perineurium of the nerve fiber. But no malignancy or atypia was detected.

Follow-up was done through numerous visits up to 3 months at the outpatient clinic. Partial flap necrosis was noticed and was managed conservatively until complete healing, after which the patient's complaint changed and she regained the range of motion.

## DISCUSSION

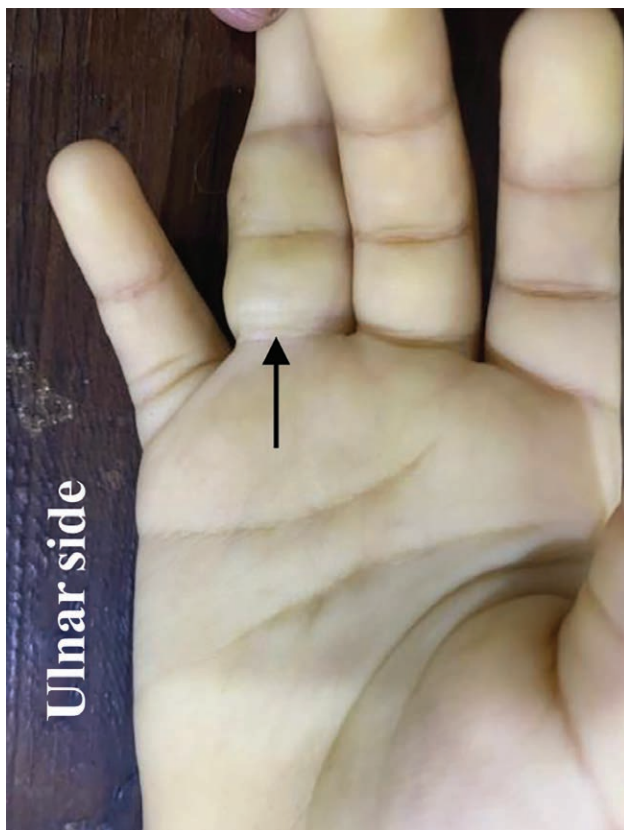
LFH or LN is a rare condition that, according to the literature, affects mainly the median nerve (80% of the cases). Such a lesion is frequently associated with nerve territory overgrowth of bone and soft tissue accounting for 62% of cases. Overgrowth has not been observed in

the subset of LN restricted to the so called predominant sensory nerves.<sup>1</sup> The tumor is caused by hypertrophy of mature fat and fibroblasts—due to unknown causes—within the nerve epineurium, resulting in enlargement of the affected nerve.<sup>5</sup>

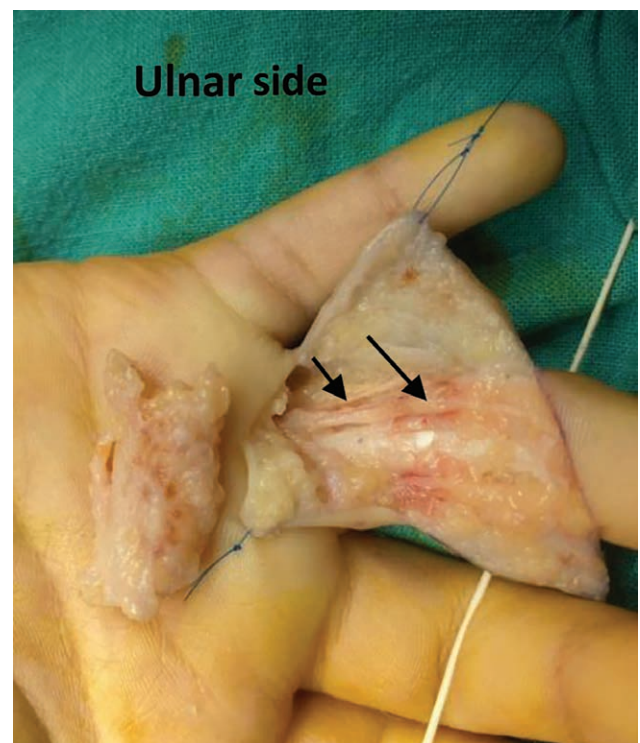
As mentioned, the median nerve is the most affected, especially at the entrapment sites (eg, carpal tunnel), but other nerves were also reported (eg, plantar nerve, radial nerve, ulnar nerve, sciatic nerve, femoral nerve, lumbosacral plexus, brachial plexus, and even cranial nerves that are reported as congenital infiltrating lipomatosis of the face).<sup>4</sup>

Although many advances have been made recently to all these lesions, there is still much we do not understand due to the rarity of the condition, which makes it under-reported as physicians are unfamiliar with such a condition.<sup>4</sup>

The exact etiology of such a condition remains not well known. Some believe that it is congenital/developmental in origin.<sup>6</sup> It was found that most cases have somatic activating mutations in PIK3CA, including p.H1047L, p.H1047R, and p.E545K, with a subset of LN with activating mutations in PIK3CA having no extraneural tissue overgrowth. Such data suggest that other genes may be implicated.<sup>4</sup> Others think that it is an acquired or reactive process due to factors like trauma or nerve irritation. The true etiology might be a combination of both: the genetic predisposition coupled with trauma

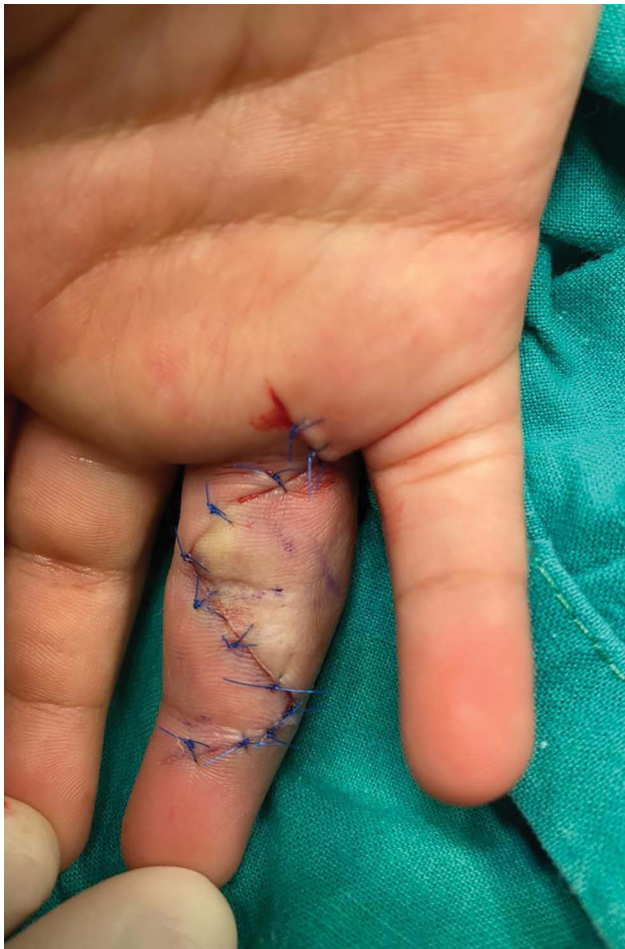


**Fig. 1.** Preoperative view, volar aspect of the right hand showing a fusiform swelling involving the ring digit over the proximal and middle phalanges (black arrow).



**Fig. 2.** Intraoperative view showing the lesion completely dissected, with black arrows pointing to the intact digital nerve along the surgical field at the ulnar aspect of the digit without exposure of the neurovascular bundle at the radial aspect of the digit.



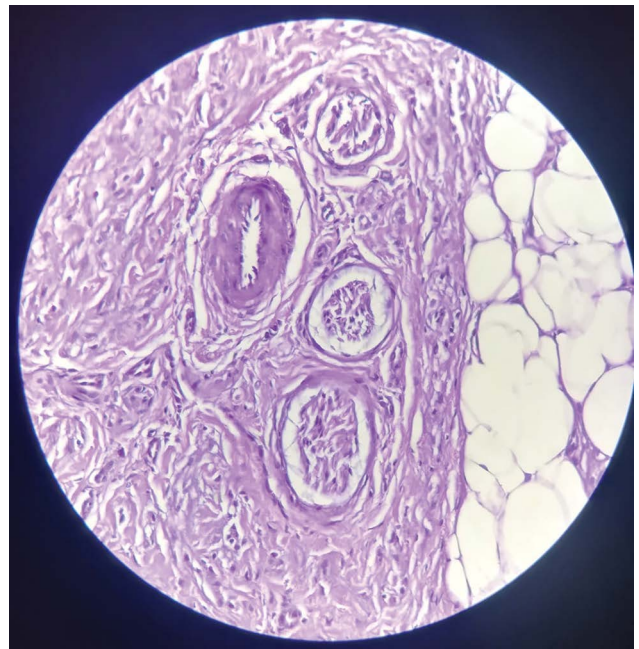


**Fig. 3.** Immediate postoperative view showing direct closure with questionable blood supply to the tip of the flap of the ulnar aspect of the digit.

or nerve irritation that incites the development of such neoplasm.<sup>5</sup>

LFH of the nerve can present as a slowly progressive mass with or without pain, tenderness, or decreased sensation along the nerve distribution. Such signs and symptoms are usually longstanding, maybe for years before presentation.<sup>8</sup>

Several differential diagnoses were described, like intraneural lipoma, diffuse lipomatosis, ganglionic cysts, vascular malformations, traumatic neuromas, fibromatosis, and schwannomas.<sup>7</sup> Diagnosis can be made with the aid of multiple imaging modalities, including MRI, CT, or ultrasonography; however, MRI is the best tool for distinguishing between benign lesions and liposarcomas. Ultrasonography can also be used; however, diagnosis might be challenging for deep lesions in the body.<sup>4</sup> Biopsy is not recommended as a diagnostic tool because it poses a significant risk of permanent neurological deficits; however, it shows smooth, rounded, and thickened hypoechoic or anechoic fascicles surrounded by echogenic fatty tissue.<sup>1,8</sup>



**Fig. 4.** Light microscopic examination of H&E stained section (400 $\times$  magnification) of the excised lesion showing two nerve bundles and a blood vessel are entrapped among proliferation fibrocellular collagenic and fatty stroma.

Grossly, it is a fusiform, irregular tumor, yellowish in color, with a mass within the affected nerve that can be elongated and/or enlarged. Microscopically, it is intraneural lipomas with mixed tissue, including fibrous tissue, cartilaginous tissue, and eosinophilic cells with hyaline matrix, or it shows fibrofatty infiltration of the epineurium, perineurium, and maybe the endoneurium; however, surrounding tissue shows no involvement or inflammation. Unlike lipomas, LFH shows an infiltrative pattern with an asymmetric fat distribution between fascicles.<sup>4-6</sup>

The rarity of the lesion precludes randomized controlled trials to specify the optimal treatment option with best practice protocols. Published literature and reports range from recommendations of observation to microsurgical intraneuronal neurolysis. Therapeutic options are then determined on a case-by-case basis, with aggressive surgical interventions reserved for symptomatic cases.<sup>5</sup>

Some authors reported that such lesions might be self-limiting and may show a natural decrease in size if left untreated. Therefore, no interventional treatment is required for asymptomatic cases.<sup>9</sup>

Microsurgical interfascicular dissection is indicated for patients with progressive symptoms and/or nerve compression. Such intervention is at a high risk for complications due to the involvement of the intraneural elements, and the postoperative fibrous healing response may jeopardize the long-term function of the nerve, as fibrosis can interfere with nerve conduction.<sup>10,11</sup> Nevertheless, optimal treatment is guided by the condition's severity of symptoms on a case-by-case basis. Therefore, raising the clinical awareness about such

conditions for surgeons, radiologists, and pathologists is of vital importance for best practice management.<sup>5</sup>

**Ahmed M. Abouzaid, AA**

6 Aziz Kahel, San Stefano

13 Shaarawy St., Loran

Alexandria 21527

Egypt

E-mail: dr\_abouzaid@live.com

## REFERENCES

1. Marek T, Spinner RJ, Syal A, et al. Surgical treatment of lipomatosis of nerve: a systematic review. *World Neurosurg.* 2019;128:587–592.e2.
2. Shekhani HN, Hanna T, Johnson JO. Lipofibromatous hamartoma of the median nerve: a case report. *J Radiol Case Rep.* 2016;10:1–7.
3. Al-Jabri T, Garg S, Mani GV. Lipofibromatous hamartoma of the median nerve. *J Orthop Surg Res.* 2010;5:71.
4. Marek T, Mahan MA, Carter JM, et al. What's known and what's new in adipose lesions of peripheral nerves? *Acta Neurochir (Wien).* 2021;163:835–842.
5. Senger JL, Classen D, Bruce G, et al. Fibrolipomatous hamartoma of the median nerve: A cause of acute bilateral carpal tunnel syndrome in a three-year-old child: a case report and comprehensive literature review. *Plast Surg (Oakv).* 2014;22:201–206.
6. Hankins CL. Carpal tunnel syndrome caused by a fibrolipomatous hamartoma of the median nerve treated by endoscopic release of the carpal tunnel. *J Plast Surg Hand Surg.* 2012;46:124–127.
7. Louaste J, Zejjari H, Chkoura M, et al. Carpal tunnel syndrome due to fibrolipomatous hamartoma of the median nerve. *Hand (N Y).* 2011;6:76–79.
8. Mohammed Saeed MA, Dawood AA, Mahmood HM. Lipofibromatous hamartoma of the median nerve with macrodactyly of middle finger. *J Clin Orthop Trauma.* 2019;10:1077–1081.
9. Jung SN, Yim Y, Kwon H. Symmetric lipofibromatous hamartoma affecting digital nerves. *Yonsei Med J.* 2005;46:169–172.
10. Robinson AJ, Basheer MH, Herbert K. An unusual cause of carpal tunnel syndrome. *J Plast Reconstr Aesthet Surg.* 2010;63:e788–e791.
11. Jain TP, Srivastava DN, Mittal R, et al. Fibrolipomatous hamartoma of median nerve. *Australas Radiol.* 2007;51 Spec No.:B98–B100.