

# Superselective Transcatheter Arterial Embolization in the Treatment of Angiodysplasia

Túlio Fabiano de Oliveira Leite<sup>1,2</sup> and Osvaldo Ignacio Pereira<sup>3</sup>

<sup>1</sup>Ribeirão Preto Medical School, University of São Paulo, São Paulo, Brazil. <sup>2</sup>Department of Interventional Radiology and Endovascular Surgery, Santa Genoveva Hospital, Uberlândia, Brazil. <sup>3</sup>University of São Paulo, São Paulo, Brazil.

Clinical Medicine Insights: Case Reports  
Volume 12: 1–4  
© The Author(s) 2019  
Article reuse guidelines:  
sagepub.com/journals-permissions  
DOI: 10.1177/1179547619842581



**ABSTRACT:** Acute nonvariceal upper gastrointestinal hemorrhage is a frequent condition associated with significant morbidity and mortality. Angiodysplasia is a common cause of bleeding in the gastrointestinal tract in the elderly. This case report discusses about a 75-year-old woman clinically stable with melena for 2 years due to arteriovenous fistula of upper mesenteric artery branches without adequate clinical and therapeutic treatment. The goal of this article is to report the safety and efficacy of superselective transcatheter arterial embolization with coils in treating lower gastrointestinal bleeding caused by angiodysplasia that was unresponsive to internal medicine treatment and enteroscopy management.

**KEYWORDS:** colonic angiodysplasia, gastrointestinal hemorrhage, selective embolization, microcoils, interventional procedures

**RECEIVED:** March 11, 2019. **ACCEPTED:** March 16, 2019.

**TYPE:** Case Report

**FUNDING:** The author(s) received no financial support for the research, authorship, and/or publication of this article.

**DECLARATION OF CONFLICTING INTERESTS:** The author(s) declared no potential conflicts of interest with respect to the research, authorship, and/or publication of this article.

**CORRESPONDING AUTHOR:** Túlio Fabiano de Oliveira Leite, Department of Interventional Radiology and Endovascular Surgery, Santa Genoveva Hospital, Uberlândia, Minas Gerais, Rua Lisboa, 257, Apto 72, São Paulo 05413-000, Brazil. Email: tuliofabiano@hotmail.com

## Introduction

Lower gastrointestinal (GI) bleeding is defined as bleeding distal to the ligament of Treitz that includes jejunal, ileal, colonic, and rectal bleeding. Of the patients with lower GI bleeding, 25% may present with recurrence of hemorrhage after treatment, of which 1% to 10% die. The causes of low GI bleeding have multifactorial origin as diverticular disease, neoplasia, inflammatory bowel disease, and angiodysplasia being more common in the elderly.<sup>1</sup>

It was first described by Goldabine, characterized by microvascular anomalies in the mucosa and submucosa of the GI tract.<sup>2</sup> Angiodysplasia is a small vascular malformation of the bowel with lesions' ectasia and dilated, thin-walled vessels that are lined by endothelium, either alone or with small amounts of smooth muscle. The thin-walled vessels can rupture readily and cause bleeding.<sup>3</sup> There are various types of treatment methods for gastrointestinal hemorrhage (GIH), for example, conservative, endoscopic therapy, surgery, and endovascular embolization.<sup>4</sup>

This report states that treatment of the angiodysplasia by using endovascular embolization as a primary treatment method of choice is safe. Patient signed a free and informed consent form to divulge the treatment images and the disclosure for the uncommon case.

## Case Report

A 75-year-old woman without comorbidities reports having symptoms of weakness, melena without bleeding, or hematemesis for approximately 2 years. She sought a gastroenterologist who started research with endoscopy, colonoscopy, and abdominal tomography without diagnosis of the cause of bleeding. An enteroscopy was performed, and a lesion was identified in the

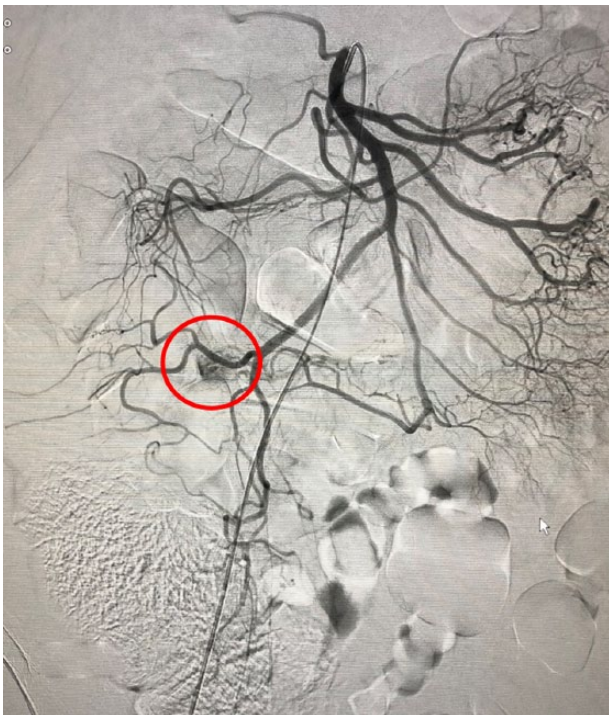terminal ileum and cecum that suggested angiodysplasia. She underwent cauterization with argon during enteroscopy with temporary stopping of melena for 3 months. After this period, the patient returns with the same symptoms. The gastroenterologist advises the patient to undergo arteriography, which was performed in another service, with arteriovenous fistula coming from the terminal branches of the superior mesenteric artery. During the diagnostic arteriography, fistula embolization was not performed and the patient continued with the same clinical procedure. Patient sought several services without definitive treatment, and she received 40 units of blood products in 2 years. Internal patient electively in our service with melena, stable hemodynamically, without need of vasoactive drugs, hemoglobin of 8 mg/dL to prepare the colon. The treatment decision was made by the coloproctology team. The interventional radiology suite is then referred for arteriography and embolization of the known arteriovenous fistula after reviewing the examinations performed in other services. Under general anesthesia, the techniques used were access to the right common femoral artery with 5 French introducer, superior mesenteric arteriography with Cobra 2 (Cordis) catheter, and indirect portography; initially, a small blush was identified in the arterial phase in terminal branches of the superior mesenteric artery (Figure 1). After a coaxial microcatheterization with Renegade STC microcatheter (Boston Scientific, Boston, MA, USA), a new superselective arteriography identified 2 sites of a vessel encasing ectasias with arterial blush and early venous return, characterizing angiodysplasia in the terminal ileum and cecum (Figure 2A to C). A selective embolization with interlock-18 micromoles 2 mm × 2.3 cm in the 2 sites of angiodysplasia is performed (Figure 3A and B). Control arteriography did not identify the arterial blush and the fistula, and



patient was referred to the intensive care unit for acute ischemic abdomen surveillance (Figure 4). Patient remained in the intensive care unit for 24 hours without interurrences and then referred to the ward, who also had no complications and was referred from the hospital for 48 hours after embolization with hemoglobin of 10 mg/dL. Patient returns for reassessment after 1 month, without melena and with hemoglobin of 12 mg/dL and with excellent clinical status.

## Discussion

Angiodysplasia is a vascular malformation of the bowel, prevailing in the terminal ileum, right colon and cecum, and pathologically expansive blood capillary between artery and vein.

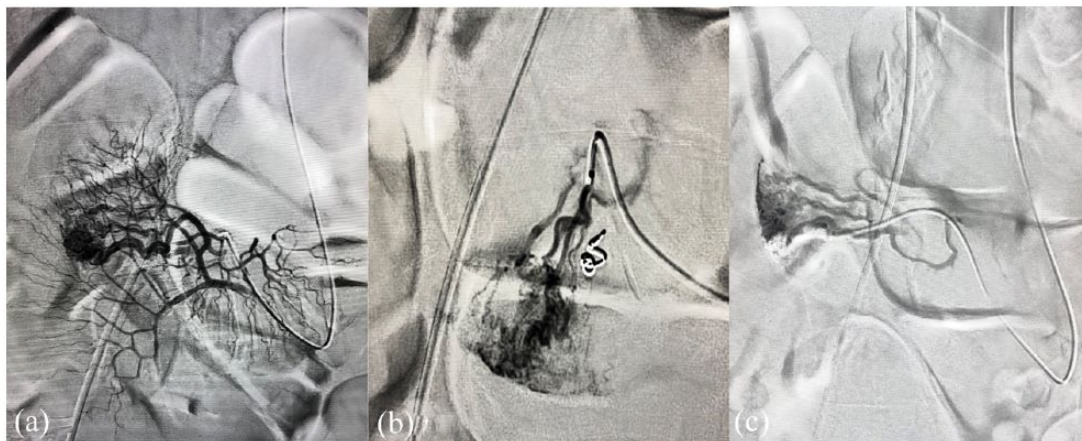


**Figure 1.** Small blush identified in the arterial phase in terminal branches of the superior mesenteric artery (red circle).

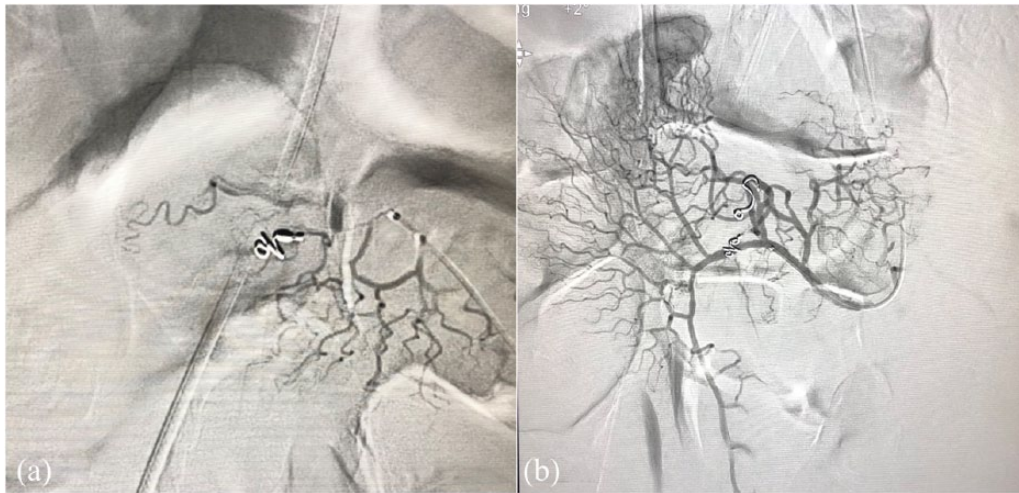
The mechanism may be the smooth muscle contraction of intestinal tract leading to the repeatedly low intensity of obstruction in the venule of intestinal wall. It can be a common cause of unexplained GI bleeding and anemia and it increases in frequency with aging. The increasing pressure in the capillary bed can induce functional failure of the anterior sphincter of capillary and forms the arteriovenous fistula finally.<sup>5</sup> Some cases present subtle blood loss, predominating anemia symptoms, recurrent episodes of melena, and iron deficiency anemia.<sup>1</sup> Angiodysplasia in 30% to 40% of the cases is caused by the low intestinal hemorrhage of indeterminate cause.<sup>6</sup>

There are various therapeutic options including endoscopy, surgery, and vasopressin infusion. Endoscopy is often the first method that is used to investigate lower GI bleeding. Failure in endoscopic diagnosis or treatment can reach up to 32% because of the large amount of blood in the site, as well as difficulty in accessing by colonoscopy or enteroscopy.<sup>7</sup> Surgical treatment by enterotomy may be a definitive treatment option, but it is associated with a high mortality rate. Most of the patients with angiodysplasia are elderly, with numerous comorbidities, such as cardiovascular disease, chronic kidney disease, and use of anticoagulants and antiplatelet agents; in others words, they have relatively poor tolerance for surgery. The mortality rate can reach 9% to 47%.<sup>8</sup>

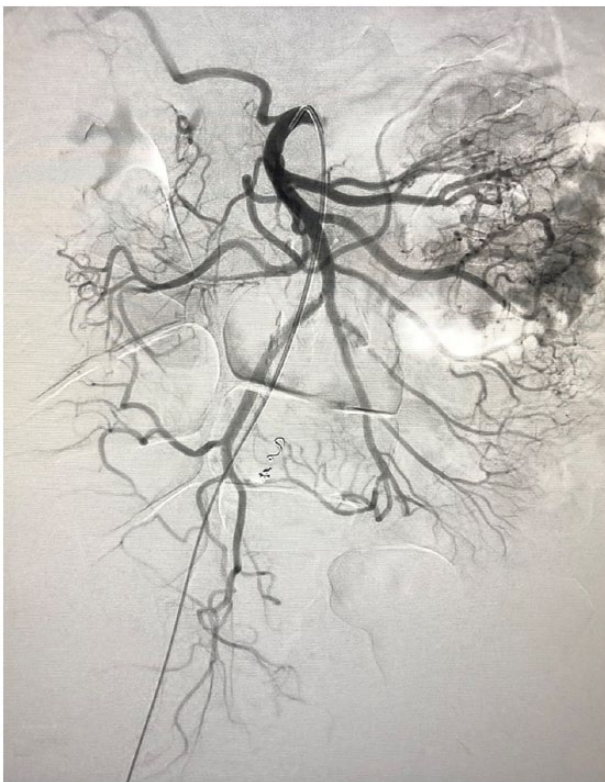Treatment with intraarterial embolization was first described by Bookstein et al.<sup>9</sup> in 1974. Angiography has become the main method of treating low digestive bleeding in the vascular lesions by endovascular embolization. The sensitivity of angiography for the diagnosis of angiodysplasia ranges from 58% to 86% and depends on whether there is active bleeding at the time of the procedure.<sup>10</sup> Extravasation of the contrast medium representing active bleeding can be demonstrated in only 6% to 20% of patients.<sup>11</sup> The angiographic signs found are densely opacified, dilated, tortuous, and slowly emptying intramural veins and a vascular tuft representing dilated mucosal venules and capillaries in the arterial phase and at the latest stage arteriovenous communication due to precapillary sphincter loss.<sup>12</sup>



**Figure 2.** (A) First site of intestinal angiodysplasia, (B) second site of intestinal angiodysplasia, and (C) early venous return due to arteriovenous fistula.



**Figure 3.** (A) Control of selective embolization with interlock-18 of the first angiodysplasia and (B) control of selective embolization with interlock-18 of the second angiodysplasia.



**Figure 4.** Control arteriography did not identify the arterial blush and the fistula.

The most used embolic agents include polyvinyl alcohol (PVA), Gelfoam, coils, autologous coagulum, and n-butyl cyanoacrylate (NBCA)<sup>13</sup>. Among these agents, we prefer the coils because they are well visualized during direct fluoroscopy and precision in the release of the coils, avoid the reflux of particles, and fulfill the objective of reducing the perfusion pressure while allowing collateral flow to prevent the infarction. We prefer to use controlled release coils to have greater accuracy of occlusion of the bleeding vessel. By using this type of device

provides inadvertent embolization reduction purchased from free release coils.

The rate of early rebleeding, defined as less than 30 days, after successful initial embolization is reported between 10% and 30% and that the successful rate of embolization to intestinal peripheral small arterial branch using microtubule is 80% to 100%.<sup>14</sup> It is not clear in the literature whether the new episodes of bleeding are due to recanalization of the previously embolized site or new sources of bleeding in the GI tract.

Intestinal necrosis is the most feared complication in an embolization during treatment of GI bleeding. Intestinal infarction due to embolization in the treatment of low digestive hemorrhage is observed in up to 22%.<sup>15</sup> It is correlated with the number of embolized straight arteries. Superselective catheterization and embolization of abnormal arterial vessels can prevent this type of complication.

In conclusion, superselective microcoil embolization is a safe and efficacious method in the management of low digestive hemorrhage in bowel angiodysplasia. While surgery may preclude subsequent endovascular embolization, the endovascular embolization does not preclude surgery. The embolization can be considered as a definitive treatment for stable patients without the need for further surgical resection.

Patient signed a free and informed consent form to divulge the treatment images and the disclosure of the rare case report.

### Author Contributions

Conceived and designed the experiments: TFOL; OIP. Analyzed the data: : TFOL; OIP. Wrote the first draft of the manuscript: : TFOL; OIP. Contributed to the writing of the manuscript: : TFOL; OIP. Agree with manuscript results and conclusions: : TFOL; OIP. Jointly developed the structure and arguments for the paper: TFOL; OIP. Made critical revisions and approved final version: : TFOL; OIP. All authors reviewed and approved of the final manuscript.

## REFERENCES

1. Zhao Y, Li G, Yu X, Xie P. Evaluation of superselective transcatheter arterial embolization with n-butyl cyanoacrylate in treating lower gastrointestinal bleeding: a retrospective study on seven cases. *Gastroenterol Res Pract.* 2016;2016: 8384349.
2. Pires D, Leandro A, Eliseu T, et al. Gastrointestinal angiodysplasia. Estrogen-progesterone therapy. *Acta Medica Portuguesa.* 1994;7:631–633.
3. Höchter W, Weingart J, Kühner W, Frimberger E, Ottenjann R. Angiodysplasia in the colon and rectum. *Endoscopy.* 1985;17:182–185.
4. Xu M, Zhu X, Liu Y, et al. Embolization of arterial gastrointestinal hemorrhage with Fuaile medical adhesive. *J Chin Med Assoc.* 2018;81:636–642.
5. Triadafilopoulos G. Management of lower gastrointestinal bleeding in older adults. *Drugs Aging.* 2012;29:707–715.
6. Brown C, Subramanian V, Wilcox CM, Peter S. Somatostatin analogues in the treatment of recurrent bleeding from gastrointestinal vascular malformations: an overview and systematic review of prospective observational studies. *Dig Dis Sci.* 2010;55:2129–2134.
7. Ali M, Ul Haq T, Salam B, Beg M, Sayani R, Azeemuddin M. Treatment of nonvariceal gastrointestinal hemorrhage by transcatheter embolization. *Radiol Res Pract.* 2013;2013:604328.
8. Suh SW, Choi YS, Kim H, Kim BG. Small bowel ischemia after angiographic embolization for angiodysplasia of lower gastrointestinal tract: the case for conservative management. *Clin Res Hepatol Gastroenterol.* 2011;35: 819–822.
9. Bookstein JJ, Chlosta EM, Foley D, Walter JF. Transcatheter hemostasis of gastrointestinal bleeding using modified autogenous clot. *Radiology.* 1974;113:277–285.
10. Hasanefendioglu Bayrak A, Cantasdemir M, Bas A, Numan F. Occult bleeding of small bowel: endovascular embolization and literature review. *J Dig Dis.* 2009;10:152–156.
11. Richardson JD, Max MH, Flint LM, Schweisinger W, Howard M, Aust JB. Bleeding vascular malformations of the intestine. *Surgery.* 1978;84:430–436.
12. Nguyen N, Croser D, Madigan D, Abu-Sneineh A, Bartholomeusz D, Schoeman M. Embolotherapy for small bowel angiodysplasia. *Gastrointest Endosc.* 2003;58:797–800.
13. Funaki B, Kostelic JK, Lorenz J, et al. Superselective microcoil embolization of colonic hemorrhage. *Am J Roentgenol.* 2001;177:829–836.
14. Raphaeli T, Menon R. Current treatment of lower gastrointestinal hemorrhage. *Clin Colon Rectal Surg.* 2012;25:219–227.
15. Maleux G, Roeflaer F, Heye S, et al. Long-term outcome of transcatheter embolotherapy for acute lower gastrointestinal hemorrhage. *Am J Gastroenterol.* 2009;104:2042–2046.