






ORIGINAL RESEARCH

Prognostic factors after transoral resection of early hypopharyngeal cancer

Keisuke Iritani MD¹  | Daryl Anne A. del Mundo MD^{1,2} | Shinobu Iwaki PhD³ |
 Kuriko Masuda MD^{1,4} | Maki Kanzawa MD, PhD⁵ | Tatsuya Furukawa MD¹  |
 Masanori Teshima MD, PhD¹ | Hirotaka Shinomiya MD, PhD¹  |
 Koichi Morimoto MD⁶ | Naoki Otsuki MD, PhD⁷  | Ken-ichi Nibu MD, PhD¹ 

¹Department of Otolaryngology-Head and Neck Surgery, Kobe University Graduate School of Medicine, Kobe, Japan

²Department of Otorhinolaryngology, University of the Philippines Manila- Philippine General Hospital, Manila, Philippines

³Division of Rehabilitation Medicine, Kobe University Hospital, Kobe, Japan

⁴Pennsylvania State University, State College, Pennsylvania, USA

⁵Department of Diagnostic Pathology, Kobe University Graduate School of Medicine, Kobe, Japan

⁶Morimoto E.N.T. Clinic, Osaka, Japan

⁷Department of Otolaryngology, Kindai University Hospital, Osaka, Japan

Correspondence

Hirotaka Shinomiya, Department of Otolaryngology-Head and Neck Surgery, Kobe University Graduate School of Medicine, 7-5-1, Kusunoki-cho, Chuo-ku, Kobe, Hyogo 650-0017, Japan.
 Email: hshino@med.kobe-u.ac.jp

Abstract

Objective: This study aimed to investigate risk factors predictive of local recurrence and/or lymph node metastasis after transoral resection of early hypopharyngeal cancer.

Methods: Forty-nine consecutive patients who underwent transoral videolaryngoscopic surgery (TOVS) as an initial treatment for hypopharyngeal cancer were evaluated. On univariate and multivariate analysis, local recurrence rates were assessed respectively using log-rank test and cox regression analysis according to the following parameters: subsite, pT, mucosal margin, lymphatic invasion, vessel invasion, tumor thickness (> 4 mm vs ≤4 mm), history of esophageal cancer, and multiple Lugol-voiding lesions (LVLs) in the esophagus. Categorical variables were evaluated for their associations with lymph node metastasis using chi-squared test or Fisher's exact test.

Result: The subsites of primary lesions were piriform sinus in 24 patients, posterior wall in 15 patients, and postcricoid in 10 patients. Thirty patients had esophageal cancer. Local recurrence occurred in 14 patients. Three patients had lymph node metastasis at the time of diagnosis and four patients developed lymph node metastasis after the initial treatment, resulting a total of seven patients having lymph node metastasis. While mucosal margin and LVLs showed significant associations with local recurrence on univariate analysis, only LVLs remained as a significant risk factor on multivariate analysis ($P = .0395$; hazard ratio = 8.897; 95% confidence interval, 1.113-71.15). Most cases of local recurrence were satisfactorily controlled by repeated TOVS. While multivariate analysis could not be performed due to the small number of the patients with lymph node metastases, venous invasion ($P = .0166$) and tumor thickness ($P = .0092$) were significantly associated with lymph node metastasis on univariate analysis.

Keisuke Iritani and Daryl Anne A. del Mundo contributed equally to this article.

This is an open access article under the terms of the Creative Commons Attribution-NonCommercial-NoDerivs License, which permits use and distribution in any medium, provided the original work is properly cited, the use is non-commercial and no modifications or adaptations are made.

© 2021 The Authors. *Laryngoscope Investigative Otolaryngology* published by Wiley Periodicals LLC. on behalf of The Triological Society.

Conclusions: Local recurrence was more frequent in patients with LVLs, but most of them were salvaged by repeated TOVS. Patients with venous invasion and/or tumor thickness greater than 4 mm should be followed up with special attention to lymph node metastasis.

Level of Evidence: 3.

KEYWORDS

hypopharyngeal cancer, multiple Lugol-voiding lesions, transoral videolaryngoscopic surgery, tumor thickness, vascular invasion

1 | INTRODUCTION

The detection rate of superficial hypopharyngeal cancer has been increasing due to the introduction of regular screening for hypopharyngeal cancer in patients with esophageal cancer and the prevalence of narrow-band imaging (NBI).¹ Since the hypopharynx and adjacent organs, as well as the larynx, can directly influence vocal and swallowing functions, minimally invasive treatment is required for early-stage cancers arising from their lesions. NCCN guideline recommends definitive radiotherapy (RT) or partial laryngopharyngectomy with neck dissection for hypopharyngeal carcinoma.² However, RT may cause laryngopharyngeal dysfunction³ and carotid artery stenosis/thrombus⁴ as late adverse events. In addition, second occurrences of primary head and neck and/or esophageal cancers are common in patients with hypopharyngeal cancer, especially in chronic drinkers with heterozygous ALDH2, which is common in Japan and East Asian countries.⁵ Thus, there have been a trend toward treating early hypopharyngeal cancer by less invasive surgery without RT to save RT for the possible future secondary primary head and neck cancer and/or esophageal cancer in Japan.⁶ Accordingly, various surgical techniques, including microlaryngosurgery (MLS), endoscopic laryngopharyngeal surgery (ELPS), transoral videolaryngoscopic surgery (TOVS), and transoral robotic surgery (TORS) have been developed for transoral resection of hypopharyngeal cancers. Among them, ELPS and TOVS have been widely performed in Japan with favorable functional and oncological results.⁶ However, to date, only a few studies have investigated the risk factors predictive of local recurrence and/or lymph node metastasis after transoral resection of early hypopharyngeal cancer. The purpose of this study was to investigate the prognostic factors after transoral resection of hypopharyngeal cancer.

2 | PATIENTS AND METHODS

Among patients with hypopharyngeal cancer treated by transoral resection as initial treatment at the Department of Otolaryngology-Head and Neck Surgery of the Kobe University Hospital between 2012 and 2019, 49 who had been followed up for more than 12 months or until the time of death were included in this study. Local lesions were treated with TOVS in all patients. Preoperatively, all lesions were precisely evaluated with videolaryngoscopy and NBI

(Visera Elite Video System, CLV-S190, Olympus, Japan). TOVS was performed under general anesthesia. Consistent with the technique described in previous studies,⁶ the laryngopharyngeal lesion was exposed during TOVS using the FK-WO retractor (Olympus Medical Systems, Tokyo, Japan) and a malleable endoscope Endoeye Flex (Olympus Medical Systems, Tokyo, Japan). The extents of the lesions were evaluated by NBI and/or iodine solution staining. Generally, a microsurgery needle with a diameter of 3 mm (Colorado Microdissection Needle) was used for dissection. The lesions were principally resected en bloc with 5 to 10 mm surgical margins (Figure 1). The surgical specimens were carefully reviewed for tumor thickness and adequacy of resection using the mucosal and deep margins as well as lymphatic and vessel invasion (Figure 2). TNM classification was assessed according to the eighth AJCC staging system. The patients were regularly followed up using endoscopy with NBI at the outpatient clinic monthly for the first year, every 2 mo for the second year, and every 3 mo thereafter. Computed tomography (CT) was employed as indicated.

Survival was determined as the duration from the day of TOVS to the last visit or the time of death. Overall survival, disease-specific survival, and local-recurrence-free survival were calculated using the Kaplan-Meier method. Using the log-rank test, the differences in local-recurrence-free survival were assessed using the univariate analysis. The following parameters were entered into the log-rank test: subsites (piriform sinus (PS)/posterior wall (PW)/postcricoid (PC)), pT (pTis vs pT1-3), mucosal margin (margin negative/carcinoma in situ (CIS) positive/squamous cell carcinoma (SCC) positive), lymphatic invasion, vessel invasion, tumor thickness (> 4 mm vs ≤4 mm), history of esophageal cancer, and multiple Lugol-voiding lesions (LVLs) in the esophagus.⁷ The confirmation of LVLs in patients with a history of total esophagectomy was based on the record of upper gastrointestinal endoscopic findings before the treatment of esophageal cancer. Baseline variables with *P*-values of <.05 during the univariate analysis were included in the multivariate analysis. Cox regression analysis was used for the multivariate models. Using the chi-squared test or Fisher's exact test, the categorical variables were evaluated for their associations with lymph node metastasis. *P*-values of <.05 were considered statistically significant, and all the tests were two-sided. EZR version 3.5.2 was used for the statistical analyses.⁸ For functional assessment, we examined the laryngeal preservation rate, requirement of tracheostomy, and postoperative swallowing function (requirement of tube feeding and type of diets at the time of discharge).

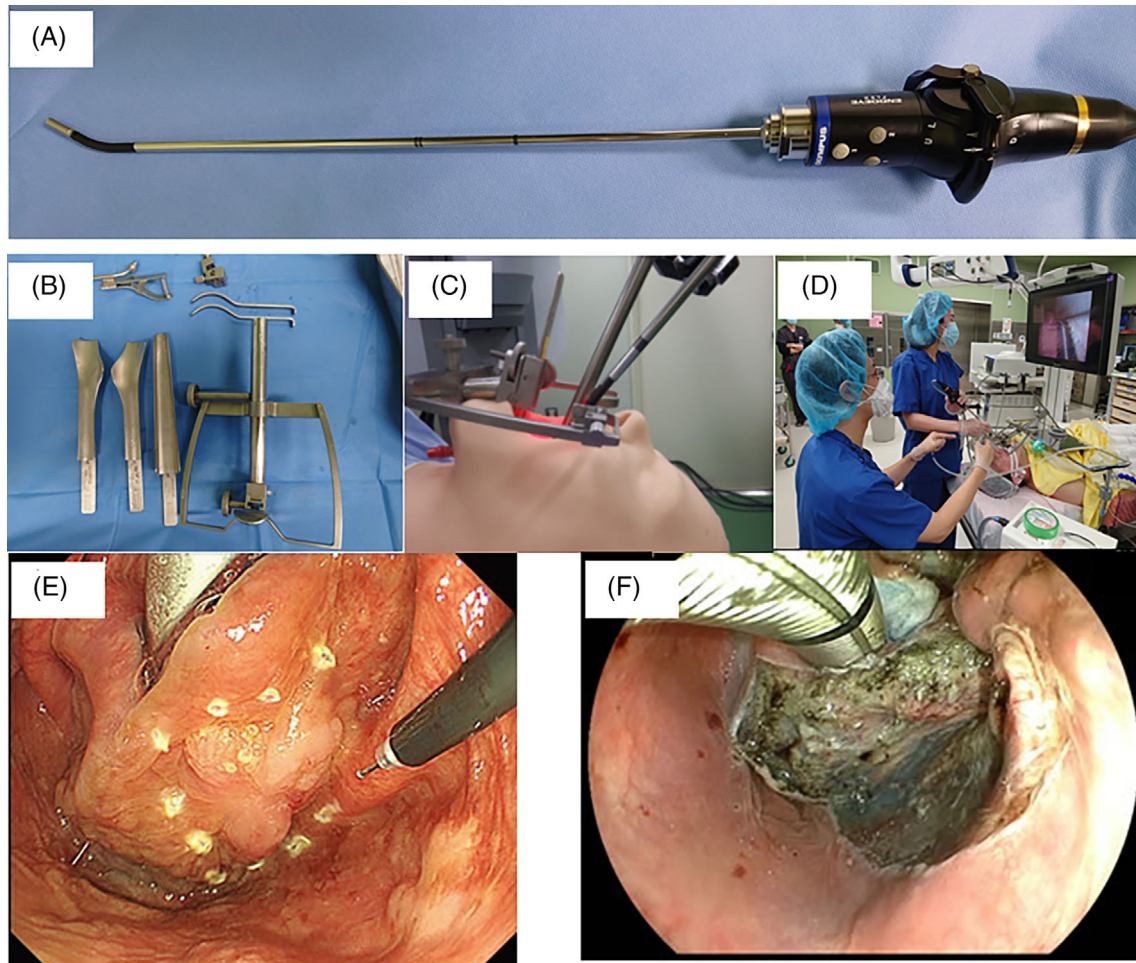


FIGURE 1 Surgical setup and procedure of TOVS. A, Endoeye Flex. B, FK-WO retractor. C, To expose the hypopharynx, FK-WO retractor was orally inserted and fixed. D, Surgical set-up of TOVS. E, Marking by electrode. F, After en bloc resection

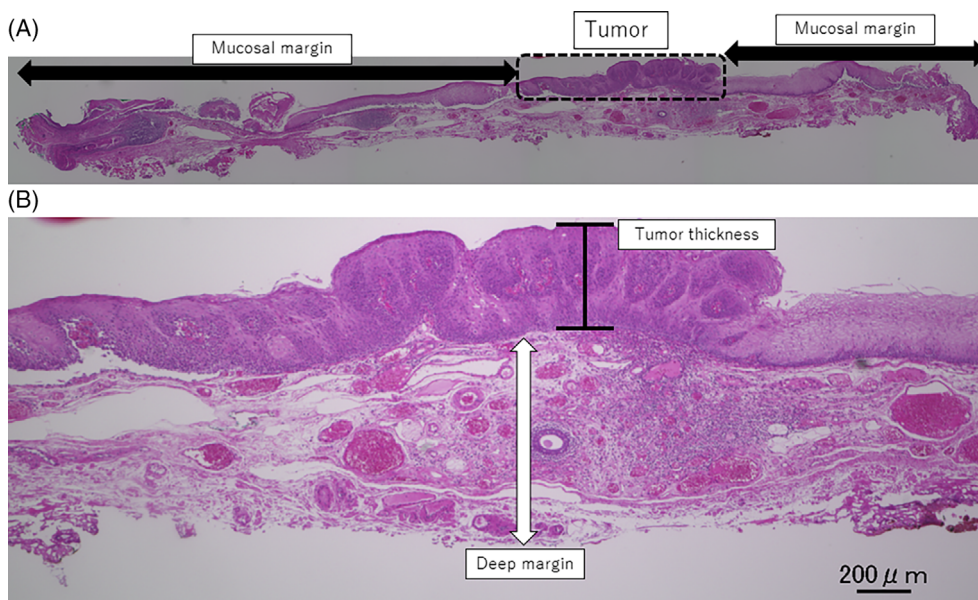


FIGURE 2 Histological evaluation of surgical specimen. A, A lateral cut-end was evaluated as a mucosal margin in the cross-section of the specimen. B, A deep cut-end was evaluated as a deep margin. Tumor thickness indicates the distance from the top to the bottom of the tumor

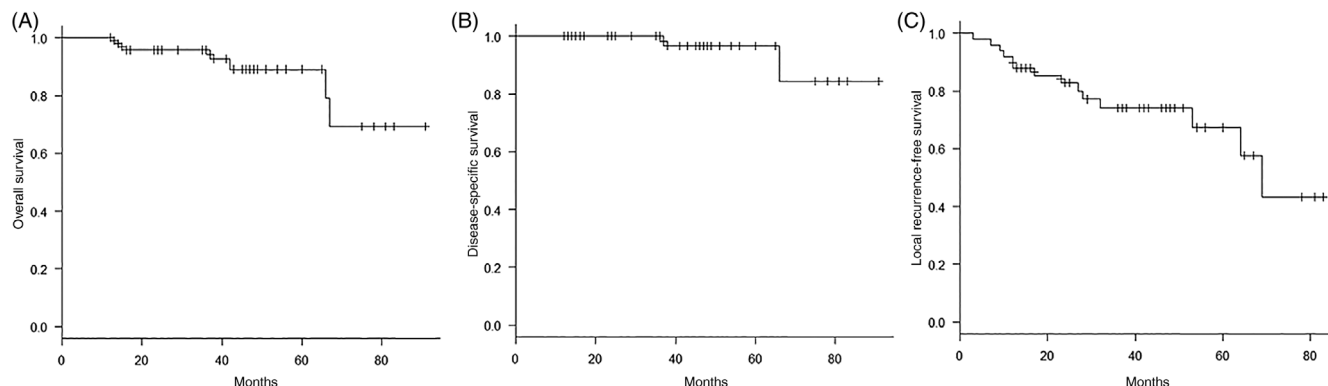


FIGURE 3 Kaplan-Meier curves of the 49 patients who underwent TOVS. A, Overall survival, B, disease-specific survival, C, local-recurrence-free survival

All observational studies in this report were conducted with the approval of the institutional review board of Kobe University Hospital (#180101). Written informed consent was obtained from all participants.

3 | RESULTS

3.1 | Background of the patients

The participants included 44 males and five females, with an average age of 68.9 years and a range of 45-89 years. All patients had a history of alcohol consumption, and 43 (87.8%) patients had a smoking history. Thirty (61.2%) patients had an esophageal cancer. Twenty-eight of them were treated for esophageal cancer at least 1 y before the diagnosis of hypopharyngeal cancer, and two patients were found to have thoracic esophageal cancer as simultaneous primary cancer at the time of diagnosis of hypopharyngeal cancer. Fifteen patients were treated with endoscopic submucosal dissection (ESD), seven patients were treated with RT or chemoradiotherapy (CRT), and eight patients were treated by total esophagectomy. There were no lesions contiguous to the previously treated esophageal cancer at the time of transoral resection of hypopharyngeal cancer. In addition, no esophageal cancer invaded to hypopharynx in this series. Thirty-two (65.3%) patients had LVL (LVL+), and 15 (30.6%) patients had no LVL (LVL-). Information about LVL could not be obtained in the other two patients.

3.2 | Treatment strategies and oncological outcomes

At the time of initial diagnosis, metastases to the cervical lymph nodes were observed (cN+) in three patients, who were treated by simultaneous neck dissection (ND) and transoral resection. No other patients had neck dissection at the time of initial treatment. Two of the three patients underwent ipsilateral ND, and the other patient had bilateral ND. The median follow-up duration was 41 months, with a range of 12 to 91 months. During the observation period, one patient was lost

TABLE 1 Pathological outcomes of the surgical specimens

Factor	Total number of patients (%)
Subsite (%)	
PS	24 (49.0)
PW	15 (30.6)
PC	10 (20.4)
pT (%)	
pTis	22 (44.9)
pT1	15 (30.6)
pT2	11 (22.4)
pT3	1 (2.0)
Mucosal margin (%)	
–	16 (32.7)
CIS+	25 (51.0)
SCC+	8 (16.3)
Deep margin (%)	
–	48 (98.0)
CIS+	0 (0)
SCC+	1 (2.0)
Vascular invasion (%)	
ly+v+	2 (4.0)
ly+v–	6 (12.2)
ly–v+	3 (6.1)
ly–v–	38 (77.6)
Tumor thickness (median) [Min-Max] (mm)	1 [0.125-11]

Abbreviations: CIS, carcinoma in situ; ly, lymphovascular invasion; PC, postcricoid; PS, piriform sinus; PW, posterior wall; SCC, squamous cell carcinoma; v, vascular invasion.

to follow-up at the 35th months. The 3-y overall survival, 3-y disease-specific survival, and 3-y local-recurrence-free survival rates were 95.7%, 100%, and 74.0%, respectively (Figure 3). Two patients died of distant metastases 66 months and 37 months after initial treatment,

TABLE 2 Characteristics of local recurrence

Factor	Group	n	Univariate analysis		Multivariate analysis		
			3-year-local recurrence survival	P-value	HR	95% CI	P-value
Subsite	PC	10	0.583 (0.230-0.821)	.236			
	PS	24	0.809 (0.492-0.938)				
	PW	15	0.727 (0.425-0.888)				
pT	pTis	22	0.741 (0.423-0.901)	.996			
	pT1-3	27	0.722 (0.500-0.857)				
Mucosal margin	–	16	0.938 (0.632-0.991)	.0393			
	CIS+	25	0.609 (0.325-0.803)				
	SCC+	8	0.600 (0.195-0.852)				
Ly	–	41	0.744 (0.557-0.862)	.55			
	+	8	0.750 (0.315-0.931)				
V	–	44	0.741 (0.566-0.854)	.82			
	+	5	0.750 (0.128-0.961)				
Tumor thickness	≤4 mm	41	0.800 (0.619-0.901)	.293			
	>4 mm	8	0.500 (0.152-0.775)				
Esophageal cancer	–	19	0.835 (0.570-0.944)	.14			
	+	30	0.669 (0.436-0.823)				
LVLs	–	15	0.923 (0.566-0.989)	.0149	8.897	1.113–71.15	.0395
	+	32	0.665 (0.445-0.814)				

Abbreviations: CIS, carcinoma in situ; LVLs, multiple Lugol-voiding lesions; PC, postcricoid; PS, piriform sinus; PW, posterior wall; SCC, squamous cell carcinoma.

respectively. Other four patients died of other diseases (brainstem bleeding, lung cancer, esophageal cancer, and interstitial pneumonia).

Regarding the histopathologic type, 29 patients had squamous cell carcinoma (SCC), one patient had SCC with a carcinosarcoma component, and 20 patients had carcinoma in situ (CIS). The locations of the primary lesions were piriform sinus (PS) in 24 (49.0%) patients, posterior wall (PW) in 15 (30.6%) patients, and postcricoid (PC) in 10 (20.4%) patients. Twenty-two (44.9%) patients had pTis, 15 (30.6%) patients had pT1, 11 (22.4%) patients had pT2, and one (2.0%) patient had pT3. The mucosal surgical margin was positive for SCC (SCC+) in eight patients and negative for SCC but positive for CIS (CIS+) in 25 patients. The deep surgical margin was positive for SCC in one patient (Table 1). Tumor thickness (from the top to the bottom of the tumor) ranged from 0.125 to 11 mm with a median of 1 mm. Among the three patients who underwent neck dissection, two were diagnosed as pN2b and the other was diagnosed as pN3b. Postoperative RT was performed in one patient with marked muscle invasion and another patient with an extranodal invasion of the lymph nodes who underwent simultaneous neck dissection and transoral resection.

3.3 | Characteristics of local recurrence

Local recurrence occurred in 14 patients at the primary lesion. Univariate analysis showed that the mucosal margin (SCC+ and/or CIS+ vs SCC–/CIS–) ($P = .0393$) and LVLs ($P = .0149$) were significantly

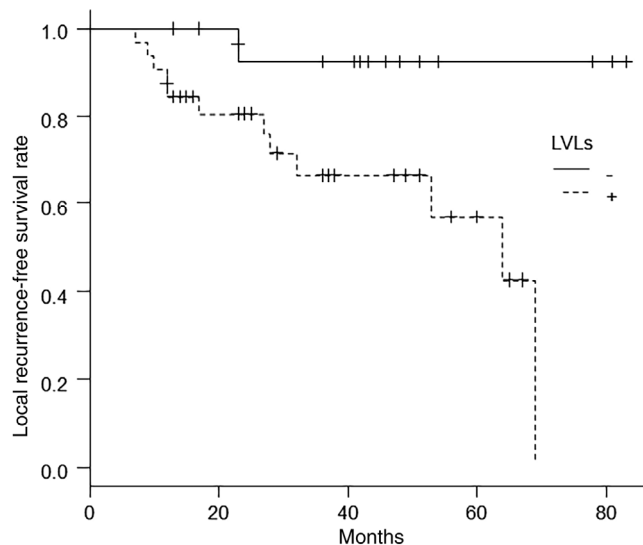


FIGURE 4 Kaplan-Meier curves on 3-year-local recurrence survival for LVL vs non-LVL group

associated with local-recurrence-free survival, whereas subsite, pT classification, lymphatic invasion, venous invasion, tumor thickness, and the history of esophageal cancer were not. The mucosal margin and the presence of LVLs, both of which had low P -values ($< .05$) on univariate analysis, were included as variables in Cox's regression analysis. In the multivariate analysis with stepwise selection, only the

TABLE 3 Characteristics of lymph node metastases

Factor	LN+, n = 7	LN-, n = 42	P-value
Subsite (%)			.759
PS	3 (42.8)	21 (50.0)	
PW	3 (42.8)	12 (28.6)	
PC	1 (14.2)	9 (21.4)	
pT (%)			1
pTis	3 (42.8)	19 (45.2)	
pT1-T3	4 (57.1)	23 (54.8)	
Mucosal margin (%)			.859
-	3 (42.8)	13 (31.0)	
CIS+	3 (42.8)	22 (52.4)	
SCC+	1 (14.2)	7 (16.7)	
Ly			.32
-	2 (28.6)	6 (14.3)	
+	5 (71.4)	36 (85.7)	
V			.0166
-	3 (42.8)	2 (4.8)	
+	4 (57.1)	40 (95.2)	
Tumor thickness			.0092
≤4 mm	3 (42.8)	38 (90.5)	
>4 mm	4 (57.1)	4 (9.5)	
Esophageal cancer (%)			1
-	3 (42.8)	16 (23.8)	
+	4 (57.1)	26 (47.6)	
LVLs (%)			1
-	2 (28.6)	13 (31.0)	
+	5 (71.4)	27 (64.3)	

Abbreviations: CIS, carcinoma in situ; LVLs, multiple Lugol-voiding lesions; PS, piriform sinus; PW, posterior wall; PC, postcricoid; SCC, squamous cell carcinoma.

presence of an LVL remained as a significant risk factor ($P = .0395$; hazard ratio = 8.897; 95% confidence interval, 1.113-71.15) (Table 2, Figure 4).

For the 14 patients with local recurrence, salvage treatments were performed as follows: TOVS: once in five patients, twice in three patients, three times in two patients, and six times in one patient; RT in two patients; CRT in one patient. Twelve of them without delayed lymph node metastasis were still alive, whereas the other two with delayed lymph node metastases died of distant metastases. Both of the two patients who died of distant metastasis had LVLs and a history of esophageal cancer.

3.4 | Characteristics of lymph node metastases

Three patients had lymph node metastasis at the time of diagnosis and four patients had regional recurrence after the initial treatment. Thus, a total of seven patients had lymph node metastasis. Univariate

analysis showed that venous invasion ($P = .0166$) and tumor thickness ($P = .0092$) were significantly associated with lymph node metastasis, whereas subsite, pT classification, mucosal margin, lymphatic invasion, and history of esophageal cancer and LVLs were not (Table 3).

3.5 | Functional outcomes

Regarding functional outcomes, the laryngeal preservation rate was 98.0% (48 of 49 patients). One patient underwent total pharyngolaryngo-esophagectomy for cervical esophageal cancer 29 months after TOVS. No local recurrence of hypopharyngeal cancer was observed in this patient. Tracheostomy was performed in one patient due to postoperative bleeding, but it was eventually closed during the hospital stay. No patient required tracheostomy due to airway obstruction or aspiration. Two patients temporarily required tube feeding using nasogastric tubes. No patient had permanent swallowing impairment and patients maintained normal oral intake of regular diets. None of the 11 patients who underwent multiple transoral resections, including one patient who underwent six transoral resections, had permanent dysphagia.

3.6 | Discussion

In the present study, univariate analysis showed that the local recurrence rates were significantly higher for patients with CIS and/or SCC positive mucosal margins than for those with negative margins. However, local control was achieved in more than half of the positive patients, and local recurrence was well-controlled by repeated TOVS in most patients. Multivariate analysis showed that the local recurrence rate was significantly higher in patients with esophageal LVLs than in those without LVLs. LVLs are frequently detected by chromoendoscopy using iodine dye in patients with esophageal cancer, especially in chronic drinkers with heterozygous ALDH2, which is common in Japan and Asian countries.⁵ Shimizu et al.⁹ reported that the metachronous recurrence rate of esophageal cancer was higher in patients with a large number of scattered Lugol voiding patterns of the background mucosa than in those with a uniform type. Other previous studies demonstrated that the presence of several irregularly shaped multiform LVLs was associated with synchronous and metachronous SCC in patients with head and neck squamous cell carcinomas.¹⁰ Thus, what was observed as local recurrence in the present series may be metachronous multiple occurrences instead of recurrence. Shinozaki et al.¹¹ reported the effectiveness of planned surveillance for detecting second occurrences of primary head and neck cancers after endoscopic resections of esophageal squamous cell carcinomas. The present findings suggest that superficial and early hypopharyngeal cancers should be treated by transoral surgery when possible, and RT should be saved for second occurrences of primary cancers in the head and neck and/or esophagus.

It should also be noted that RT and CRT for pharyngeal cancer are accompanied by the risk of laryngopharyngeal dysfunction³ and

carotid artery stenosis/thrombus⁴ as late adverse events. On the other hand, several recent reports^{6,12} and the findings of the present study suggest that TOVS is a minimally invasive treatment with favorable postoperative laryngopharyngeal function and acceptable complications.

Although it is desirable to obtain negative margins, local lesions are ultimately well-controlled by repeated TOVS even if the surgical margins are positive. In particular, patients with esophageal LVLs are at a high risk of metachronous occurrence regardless of the surgical margins. Based on the concept of field cancerization, careful periodical follow-up using endoscopic examination with NBI is mandatory for preparation for local recurrences and/or metachronous new lesions.

Pathological examination of the resected specimen revealed that lymph node metastasis was significantly more probable in patients with venous invasion or tumor thickness greater than 4 mm, which was consistent with previous reports.^{13,14} Therefore, these patients should be followed up with special attention to lymph node metastasis.

A weakness of the present study is the high rates of mucosal margins during the initial surgery. This may be attributable to our surgical technique. The surgical field was sometimes limited, especially for PC and PW lesions, and we occasionally experienced difficulty in securing negative mucosal margins for these lesions. Recently, various surgical instruments have been developed for transoral laser microsurgery (TLM),¹⁵ endoscopic laryngopharyngeal surgery (ELPS),^{16,17} and transoral robotic surgery (TORS)^{18,19} and the usefulness of a curved blade for the FKWO retractor¹² has been reported. To address this weakness, we recommend these instruments and techniques. Second, the median follow-up duration (41 months) may not have been adequate for evaluating the local recurrence rate. Third, few patients had lymph node metastasis. The ongoing nationwide multi-institutional study will validate our present findings.

4 | CONCLUSIONS

Local control was achieved in more than half of the patients with positive surgical margins by initial transoral resection of hypopharyngeal cancer. Local recurrence rates were higher in patients with LVLs. Repeated TOVS ultimately controlled the recurrent or metachronous lesions satisfactorily. Careful follow-up, especially in patients with LVLs, should be performed for early detection of recurrent or metachronous lesions. Lymph node metastases were significantly higher in patients with venous invasion and/or tumor thickness greater than 4 mm. Postoperative RT or ND should be considered in these cases.

CONFLICT OF INTEREST

The authors declare no conflicts of interest.

ORCID

Keisuke Iritani  <https://orcid.org/0000-0002-7856-4100>

Tatsuya Furukawa  <https://orcid.org/0000-0003-4127-3569>

Hirota Shinomiya  <https://orcid.org/0000-0003-1667-7545>

Naoki Otsuki  <https://orcid.org/0000-0002-9682-2548>

Ken-ichi Nibu  <https://orcid.org/0000-0002-5461-4871>

BIBLIOGRAPHY

- Muto M, Minashi K, Yano T, et al. Early detection of superficial squamous cell carcinoma in the head and neck region and esophagus by narrow band imaging: a multicenter randomized controlled trial. *J Clin Oncol*. 2010;28(9):1566-1572. <https://doi.org/10.1200/JCO.2009.25.4680>.
- Kwon DI, Miles BA, (AHNS) ECotAHaNS. Hypopharyngeal carcinoma: do you know your guidelines? *Head Neck*. 2019;41(3):569-576. <https://doi.org/10.1002/hed.24752>.
- Huh G, Ahn SH, Suk JG, et al. Severe late dysphagia after multimodal treatment of stage III/IV laryngeal and hypopharyngeal cancer. *Jpn J Clin Oncol*. 2020;50(2):185-192. <https://doi.org/10.1093/jjco/hyz158>.
- Trojanowski P, Sojka M, Trojanowska A, Wolski A, Roman T, Jargiello T. Management of Radiation Induced Carotid Stenosis in head and neck cancer. *Transl Oncol*. 2019;12(8):1026-1031. <https://doi.org/10.1016/j.tranon.2019.05.001>.
- Avinçsal MO, Shinomiya H, Teshima M, et al. Impact of alcohol dehydrogenase-aldehyde dehydrogenase polymorphism on clinical outcome in patients with hypopharyngeal cancer. *Head Neck*. 2018;40(4):770-777. <https://doi.org/10.1002/hed.25050>.
- Tateya I, Shiotani A, Satou Y, et al. Transoral surgery for laryngopharyngeal cancer - the paradigm shift of the head and cancer treatment. *Auris Nasus Larynx*. 2016;43(1):21-32. <https://doi.org/10.1016/j.anl.2015.06.013>.
- Katada C, Muto M, Tanabe S, et al. Factors associated with the presence of multiple Lugol-voiding lesions in patients with esophageal squamous-cell carcinoma. *Dis Esophagus*. 2014;27(5):457-462. <https://doi.org/10.1111/j.1442-2050.2012.01429.x>.
- Kanda Y. Investigation of the freely available easy-to-use software 'EZR' for medical statistics. *Bone Marrow Transplant*. 2013;48(3):452-458. <https://doi.org/10.1038/bmt.2012.244>.
- Shimizu Y, Tukagoshi H, Fujita M, Hosokawa M, Kato M, Asaka M. Metachronous squamous cell carcinoma of the esophagus arising after endoscopic mucosal resection. *Gastrointest Endosc*. 2001;54(2):190-194. <https://doi.org/10.1067/mge.2001.116877>.
- Muto M, Hitomi Y, Ohtsu A, Ebihara S, Yoshida S, Esumi H. Association of aldehyde dehydrogenase 2 gene polymorphism with multiple oesophageal dysplasia in head and neck cancer patients. *Gut*. 2000;47(2):256-261. <https://doi.org/10.1136/gut.47.2.256>.
- Shinozaki T, Katada C, Shiga K, et al. Effectiveness of planned surveillance for detecting second primary head and neck cancers after endoscopic resection of esophageal squamous cell carcinoma. *Jpn J Clin Oncol*. 2020;50(10):1162-1167. <https://doi.org/10.1093/jjco/hyaa087>.
- Tomifujii M, Araki K, Uno K, et al. Transoral videolaryngoscopic surgery for laryngeal and hypopharyngeal cancer - technical updates and long-term results. *Auris Nasus Larynx*. 2020;47(2):282-290. <https://doi.org/10.1016/j.anl.2019.09.003>.
- Tomifujii M, Imanishi Y, Araki K, et al. Tumor depth as a predictor of lymph node metastasis of supraglottic and hypopharyngeal cancers. *Ann Surg Oncol*. 2011;18(2):490-496. <https://doi.org/10.1245/s10434-010-1219-5>.
- Ye LL, Rao J, Fan XW, Kong FF, Hu CS, Ying HM. The prognostic value of tumor depth for cervical lymph node metastasis in hypopharyngeal and supraglottic carcinomas. *Head Neck*. 2019;41(7):2116-2122. <https://doi.org/10.1002/hed.25667>.
- Weiss BG, Ihler F, Wolff HA, et al. Transoral laser microsurgery for treatment for hypopharyngeal cancer in 211 patients. *Head Neck*. 2017;39(8):1631-1638. <https://doi.org/10.1002/hed.24814>.
- Kishimoto Y, Tateya I, Funakoshi M, Miyamoto SI, Muto M, Omori K. Endoscopic laryngopharyngeal surgery for hypopharyngeal lesions. *Oral*

- Oncol.* 2020;106:104655. <https://doi.org/10.1016/j.oraloncology.2020.104655>.
17. Tateya I, Muto M, Morita S, et al. Endoscopic laryngo-pharyngeal surgery for superficial laryngo-pharyngeal cancer. *Surg Endosc.* 2016;30(1):323-329. <https://doi.org/10.1007/s00464-015-4213-y>.
 18. Mazerolle P, Philouze P, Garrel R, et al. Oncological and functional outcomes of trans-oral robotic surgery for pyriform sinus carcinoma: a French GETTEC group study. *Oral Oncol.* 2018;86:165-170. <https://doi.org/10.1016/j.oraloncology.2018.09.014>.
 19. Park YM, Jung CM, Cha D, Kim SH. The long-term oncological and functional outcomes of transoral robotic surgery in patients with

hypopharyngeal cancer. *Oral Oncol.* 2017;71:138-143. <https://doi.org/10.1016/j.oraloncology.2017.06.016>.

How to cite this article: Iritani K, del Mundo DAA, Iwaki S, et al. Prognostic factors after transoral resection of early hypopharyngeal cancer. *Laryngoscope Investigative Otolaryngology.* 2021;6(4):756–763. <https://doi.org/10.1002/lio2.611>