

Teaching Case

Successful Use of Absorbable Hydrogel Rectal Spacers (SpaceOAR) Before Salvage Radiation Therapy After Previous Prostate Cryotherapy

James Applewhite,^a Jerry Barker Jr, MD, FACR,^{b,*} and James C. Vestal, MD^c^aUniversity of Notre Dame, South Bend, Indiana; ^bTexas Cancer Specialists, Fort Worth, Texas; and ^cUrology Partners of North Texas, Arlington, Texas

Received 26 September 2020; accepted 5 January 2021



Introduction

Cryotherapy is a minimally invasive procedure used to treat localized prostate cancer with low surgical risk¹ and acceptable morbidity² in selected patients.³ For some patients, particularly those diagnosed with higher risk disease, local recurrence can occur after cryoablation.^{4,5} Salvage radiation therapy has been shown to be an effective treatment in these cases.⁶

Although radiation therapy (RT) is widely accepted as an effective treatment for prostate cancer, the rectum, owing to its anatomic proximity, is a dose-limiting structure.⁷ Various injectable agents have been inserted as spacing materials into the space between the prostate and rectum to reduce rectal dose during prostate radiation.⁸ Absorbable hydrogel rectal spacer (SpaceOAR) is a widely studied injectable polyethylene glycol hydrogel that shifts the anterior rectal wall away from the prostate⁹ and maintains adequate space for approximately 3 months and is completely absorbed in 6 months.¹⁰ Because of its simple application procedure and low rate of complications¹¹ as well as its proven efficacy in reducing rectal radiation dose and long-term toxicity,⁷ SpaceOAR

application is a Food and Drug Administration–cleared procedure before prostate RT.

Prostate cryoablation uses continuous transrectal ultrasound guidance to insert cryoneedles transperineally into the prostate. Argon and helium gases are used for cooling and warming, respectively.¹² Real-time ultrasound gives visualization of ice-ball formation,³ and freezing/thawing cycles are repeated as needed to cover the target. Various techniques aim to adequately freeze/destroy malignant tissue while protecting normal tissues (eg, warming urethral catheter, warm saline rinses to anterior rectal wall). However, whole gland cryoablation results in universal erectile dysfunction,³ suggesting some extraprostatic tissue damage. Presumably for this reason, some physicians have expressed concerns about whether absorbable hydrogel spacers could be safely and effectively used in patients who have been previously treated with cryosurgery.^{13,14} Herein we present the first reported cases where absorbable hydrogel spacers were successfully used after previous prostate cryotherapy.

SpaceOAR Technique

SpaceOAR is introduced into the potential space between the rectum and prostate using transperineal technique. With the patient in the dorsal lithotomy position, the perineum is cleaned and anesthetized using local anesthesia. Under continuous transrectal ultrasound guidance, a needle is introduced into the space between prostate and rectum and injectable sterile saline is used to

Sources of support: This work had no specific funding.

Disclosures: none.

Data Sharing Statement: Research data are stored in an institutional repository and will be shared upon request to the corresponding author.

* Corresponding author: Jerry Barker, Jr, MD, FACR; E-mail: jbarker@txcsfw.com.

<https://doi.org/10.1016/j.adro.2021.100647>

2452-1094/© 2021 The Authors. Published by Elsevier Inc. on behalf of American Society for Radiation Oncology. This is an open access article under the CC BY-NC-ND license (<http://creativecommons.org/licenses/by-nc-nd/4.0/>).

hydrodissect that space. Two solutions (a trilycine buffer/polyethylene glycol solution and a salt buffer accelerant solution) are then mixed together via a Y-connector and simultaneously injected into the established space via an 18-gauge needle. When mixed, the solutions cross link to form a solid hydrogel within seconds. This hydrogel spacer persists for approximately 3 months and then gradually liquefies via hydrolysis.

Case Reports

Case 1

A 73-year-old man originally presented with a screening prostate specific antigen (PSA) of 5.99 ng/mL. Transrectal ultrasound-guided needle biopsy of the prostate revealed a Gleason 7 (4 + 3) adenocarcinoma involving 1 of 12 cores from the left mid apex. Staging studies demonstrated nonmetastatic disease. The patient elected to have treatment with definitive cryotherapy. PSA levels decreased to 0.4 ng/mL 1 month after cryoablation. However, 8 months later his PSA increased to 2.1 ng/mL. A restaging magnetic resonance imaging (MRI) scan demonstrated a PI-RADS 4 lesion involving the bilateral anterior apex to the mid of the peripheral gland. An MRI-fusion prostate biopsy was performed, showing Gleason 6 (3 + 3) adenocarcinoma in 2 cores (RMA is a biopsy from the right medial apex of the prostate gland. LMA is a biopsy from the left medial apex of the prostate gland) and Gleason 7 (3 + 4) adenocarcinoma in the lesion-directed biopsy. The patient elected to pursue salvage radiation therapy. Before the start of radiation therapy, an absorbable hydrogel spacer was surgically placed. There was no technical challenge in delivering the spacer between the prostatic fascia and the rectum, and postprocedure MRI demonstrated excellent hydrogel spacer placement (Fig. 1). He was then treated with cone beam computed tomography (CT) image guided intensity

modulated radiation therapy to a total dose of 7920 cGy in 44 fractions, which he tolerated without complication.

Case 2

A 72-year-old man initially presented with a screening PSA of 5.8 ng/mL. Transrectal ultrasound-guided needle biopsy of the prostate demonstrated Gleason 7 (3 + 4) adenocarcinoma in 1 of 12 cores, Gleason 6 (3 + 3) adenocarcinoma in 2 of 12 cores, and a small focus of atypical glands in 1 of 12 cores. Initial staging studies demonstrated nonmetastatic disease. The patient elected to have definitive treatment using cryoablation. His PSA nadir was 4 months posttreatment at 1.28 ng/mL. During the next 15 months, his PSA slowly increased to as high as 6.0 ng/mL. A restaging Axumin positron emission tomography/CT scan demonstrated uptake in the prostate gland, but without evidence of metastatic disease. The patient elected to pursue salvage radiation therapy. An absorbable hydrogel spacer (SpaceOAR) was surgically placed before the start of salvage radiation therapy. There was no technical challenge in delivering the spacer between the prostatic fascia and the rectum, and postprocedure MRI demonstrated excellent hydrogel spacer placement (Fig. 2). He was then treated with cone beam CT image guided intensity modulated radiation therapy to a total dose of 7920 cGy in 44 fractions, which he tolerated without complication.

Discussion

Prostate cryoablation is a localized treatment option for selected patients with localized prostate cancer.^{3,15,16} Some patients develop locally recurrent disease after definitive cryoablation⁶ and are often candidates for additional local treatment with curative intent. Although some patients can be treated with repeat courses of salvage cryotherapy,¹⁷ additional local treatment using

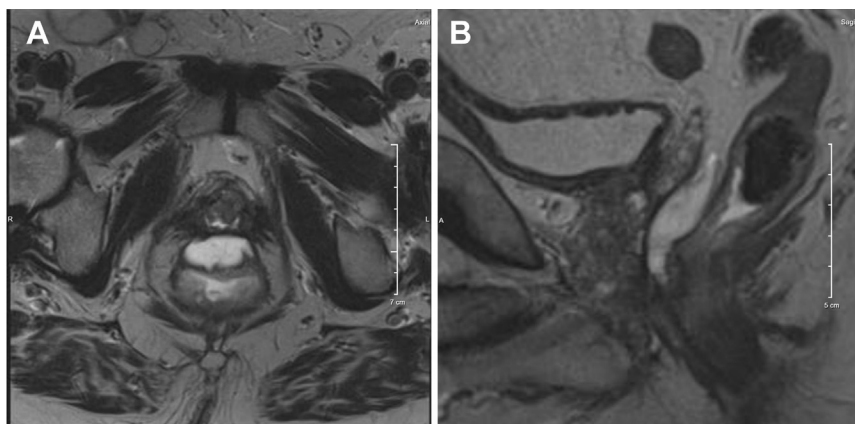


Figure 1 (A) Axial MRI image demonstrating absorbable hydrogel spacer (SpaceOAR) situated between rectum and prostate/seminal vesicles (Case 1). (B) Sagittal MRI image demonstrating absorbable hydrogel spacer (SpaceOAR) situated between rectum and prostate/seminal vesicles (Case 1).

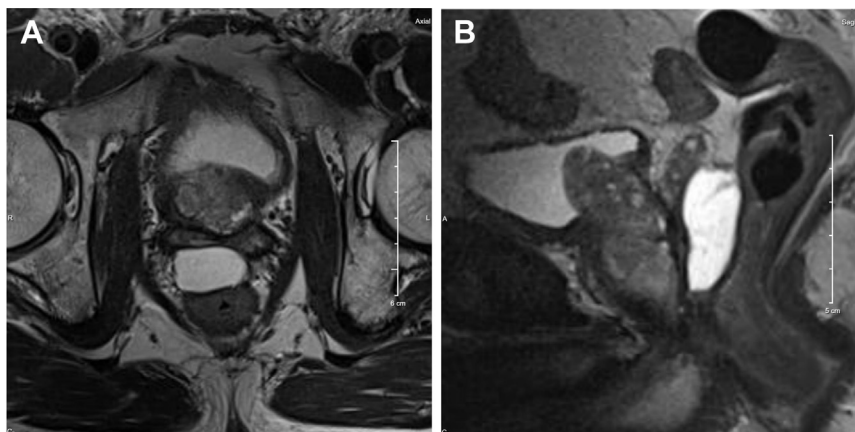


Figure 2 (A) Axial MRI image demonstrating absorbable hydrogel spacer (SpaceOAR) situated between rectum and prostate/seminal vesicles (Case 2). (B) Sagittal MRI image demonstrating absorbable hydrogel spacer (SpaceOAR) situated between rectum and prostate/seminal vesicles (Case 2).

conformal external beam radiation therapy has also been used successfully.

External beam radiation therapy for prostate cancer requires that ablative radiation doses¹⁸ be applied to a treatment volume situated immediately adjacent to the dose-limiting rectum.¹⁹⁻²¹ Modern highly conformal radiation therapy techniques have been successfully used to reduce the risk of rectal toxicity while delivering tumoricidal doses to the prostate gland.²⁰ In addition, over the last several years the use of absorbable hydrogel spacers (eg, SpaceOAR) have been used to further improve the therapeutic window.²² These hydrogel spacers have been demonstrated to consistently reduce rectal doses^{10,11} (>90% patients achieving reduction in rectal V70 of at least 25% in a randomized trial¹¹) and improve quality of life^{23,24} with little toxicity (rate of grade 1 or greater rectal acute adverse events or procedure adverse events through 6 months similar to the control group in a randomized trial¹¹) for men receiving high-dose radiation therapy for prostate cancer, and these spacers have achieved Food and Drug Administration clearance and widespread acceptance.

Successful transperineal instillation of absorbable hydrogel spacers requires the use of injectable sterile saline to hydrodissect the space between prostate and rectum before hydrogel is injected. Some authors have raised concerns that previous prostate cancer treatment (eg, cryotherapy, high-intensity focused ultrasound) may prevent successful dissection of this space, resulting in sub-optimal spacer placement or procedural complication.^{13,14} However, previous reports have described successful use of hydrogel spacers after previous prostatectomy, external beam radiation therapy, and high-intensity focused ultrasound.^{6,16,25} In this report, we have shown that absorbable hydrogel spacers can also be effectively used in patients previously treated with prostate cryoablation, without periprocedural complication.

Conclusions

We have demonstrated the feasibility of using SpaceOAR before salvage RT after previous prostate cryoablation. Our ongoing work is evaluating the dosimetric benefits of spacers in this setting. In addition, we will continue to evaluate additional similar cases, seeking to identify selection criteria for optimal candidates for hydrogel placement before salvage radiation therapy.

Absorbable hydrogel spacers can be safely and effectively used before salvage radiation therapy for selected patients who have been previously treated with prostate cryoablation.

References

- Rodríguez SA, Arias Fúnez F, Bueno Bravo C, et al. Cryotherapy for primary treatment of prostate cancer: Intermediate term results of a prospective study from a single institution. *Prostate Cancer*. 2014; 2014:571576.
- Katz AE, Rewcastle JC. The current and potential role of cryoablation as a primary therapy for localized prostate cancer. *Curr Oncol Rep*. 2003;5:231-238.
- American Urological Association. Clinically localized prostate cancer: AUA/ASTRO/SUO guideline. Available at: <https://www.auanet.org/guidelines/prostate-cancer-clinically-localized-guideline>. Accessed November 29, 2020.
- Bahn DK, Lee F, Badalament R, Kumar A, Greski J, Chernick M. Targeted cryoablation of the prostate: 7-year outcomes in the primary treatment of prostate cancer. *Urology*. 2002;60(Suppl 1):3-11.
- Chin JL, Al-Zahrani AA, Autran-Gomez AM, et al. Extended follow-up oncologic outcome of randomized trial between cryoablation and external beam therapy for locally advanced prostate cancer (T2c-T3b). *J Urol*. 2012;188:1170-1175.
- McDonough MJ, Feldmeier JJ, Parsai I, Dobelbower RR Jr, Selman SH. Salvage external beam radiotherapy for clinical failure after cryosurgery for prostate cancer. *Int J Radiat Oncol Biol Phys*. 2001;51:624-627.

7. Karsh LI, Gross ET, Pieczonka CM, et al. Absorbable hydrogel spacer use in prostate radiotherapy: A comprehensive review of phase 3 clinical trial published data. *Urology*. 2018;115:39-44.
8. Mahal BA, O'Leary MP, Nguyen PL. Hydrogel spacing for radiotherapy of prostate cancer: A review of the literature. *Urol Pract*. 2014;1:79-85.
9. Food and Drug Administration. De novo classification request for SpaceOAR System: Decision summary. Available at: https://www.accessdata.fda.gov/cdrh_docs/reviews/DEN140030.pdf. Accessed July 16, 2020.
10. SpaceOAR system: Instructions for use. Available at: http://www.spaceoar.com/assets/LCN-80-3101-001-Rev-C_SpaceOAR-System-10mL-IFU-CAN.pdf. Accessed July 16, 2020.
11. Mariados N, Sylvester J, Shah D, et al. Hydrogel spacer prospective multicenter randomized controlled pivotal trial: Dosimetric and clinical effects of perirectal spacer application in men undergoing prostate image guided intensity modulated radiation therapy. *Int J Radiat Oncol Biol Phys*. 2015;92:971-977.
12. Jung JH, Risk MC, Goldfarb R, et al. Primary cryotherapy for localized or locally advanced prostate cancer. *Cochrane Database Syst Rev*. 2018;2018, CD005010.
13. Quinn TJ, Daignault-Newton S, Bosch W, et al. Who benefits from a prostate rectal spacer? Secondary analysis of a phase III trial. *Pract Radiat Oncol*. 2020;10:186-194.
14. Müller AC, Mischinger J, Klotz T, et al. Interdisciplinary consensus statement on indication and application of a hydrogel spacer for prostate radiotherapy based on experience in more than 250 patients. *Radiol Oncol*. 2016;50:329-336.
15. Donnelly BJ, Saliken JC, Brasher PMA, et al. A randomized trial of external beam radiotherapy versus cryoablation in patients with localized prostate cancer. *Cancer*. 2010;116:323-330.
16. Vestal JC. Critical review of the efficacy and safety of cryotherapy of the prostate. *Curr Urol Rep*. 2005;6:190-193.
17. Aminsharif A, Jibara G, Tsivian E, et al. Salvage prostate cryoablation for the management of local recurrence after primary cryotherapy: A retrospective analysis of functional and intermediate-term oncological outcomes associated with a second therapeutic freeze. *Clin Genitourin Cancer*. 2019;17:e831-e836.
18. Pinkawa M, Bornemann C, Escobar-Corral N, et al. Treatment planning after hydrogel injection during radiotherapy of prostate cancer. *Strahlenther Onkol*. 2013;189:796-800.
19. Kuban DA, Tucker SL, Dong L, et al. Long-term results of the MD Anderson randomized dose-escalation trial for prostate cancer. *Int J Radiat Oncol Biol Phys*. 2008;70:67-74.
20. Michalski JM, Yan Y, Watkins-Bruner D, et al. Preliminary toxicity analysis of 3-dimensional conformal radiation therapy versus intensity-modulated radiation therapy on the high-dose arm of the Radiation Therapy Oncology Group 0126 prostate cancer trial. *Int J Radiat Oncol Biol Phys*. 2013;87:932-938.
21. Bruheim K, Guren MG, Skovlund E, et al. Late side effects and quality of life after radiotherapy for rectal cancer. *Int J Radiat Oncol Biol Phys*. 2010;76:1005-1011.
22. Hamstra DA, Nariados N, Sylvester J, et al. Continued benefit to rectal separation for prostate radiation therapy: Final results of a phase III trial. *Int J Radiat Oncol Biol Phys*. 2017;97:976-985.
23. Grodsky MB, Sidani SM. Radiation proctopathy. *Clin Colon Rectal Surg*. 2015;28:103-111.
24. Miller LE, Efstathiou JA, Bhattacharyya SK, et al. Association of the placement of a perirectal hydrogel spacer with the clinical outcomes of men receiving radiotherapy for prostate cancer: A systematic review and meta-analysis. *JAMA Netw Open*. 2020;3:1-12.
25. Nguyen PL, Devlin PM, Beard CJ, et al. High-dose-rate brachytherapy for prostate cancer in a previously radiated patient with polyethylene glycol hydrogel spacing to reduce rectal dose. *Brachytherapy*. 2013;12:77-83.