













# Epipericardial Fat Necrosis in a Pediatric Patient Diagnosed Using Contrast-Enhanced MRI Findings: A Case Report and Literature Review

소아 심장막 주위 지방 괴사 환자에서의 조영증강  
자기공명영상 소견: 증례 보고 및 문헌고찰

Seong Ju Kim, MD , Byoung Hee Han, MD\* , Youngjong Cho, MD ,  
Dae Shick Ryu, MD , Ga Young Yoon, MD ,  
Wooyul Paik, MD , Young Rae Kim, MD 

Department of Radiology, Gangneung Asan Hospital, University of Ulsan College of Medicine,  
Gangneung, Korea

## ORCID iDs

Seong Ju Kim  <https://orcid.org/0000-0002-0677-4627>  
Byoung Hee Han  <https://orcid.org/0000-0001-5449-7014>  
Youngjong Cho  <https://orcid.org/0000-0003-2881-9221>  
Dae Shick Ryu  <https://orcid.org/0000-0001-6590-720X>  
Ga Young Yoon  <https://orcid.org/0000-0003-0933-1570>  
Wooyul Paik  <https://orcid.org/0000-0001-9617-6227>  
Young Rae Kim  <https://orcid.org/0000-0001-5084-279X>

Epipericardial fat necrosis (EPFN) is a relatively rare cause of acute chest pain, with only five pediatric cases having been reported in the English-language medical literature to date. EPFN can be diagnosed based on the clinical symptoms of acute pleuritic chest pain and classic CT features of typically ovoid fatty lesions surrounded by a rim or capsule in the mediastinal or pericardial areas. Previous studies have reported that contrast-enhanced MRI can detect typical fat signal changes in adults with EPFN. We report a pediatric EPFN case diagnosed using gadolinium-enhanced MRI. Thus, contrast-enhanced MRI may be used to confirm EPFN in the differential diagnoses of the causes of acute chest pain.

**Index terms** Fat Necrosis; Pericardium; Magnetic Resonance Imaging

Received September 24, 2021  
Revised November 30, 2021  
Accepted December 28, 2021

## \*Corresponding author

Byoung Hee Han, MD  
Department of Radiology,  
Gangneung Asan Hospital,  
University of Ulsan  
College of Medicine,  
38 Bangdong-gil, Sacheon-myeon,  
Gangneung 25440, Korea.

Tel 82-33-610-3489  
Fax 82-33-610-3490  
E-mail ubf2931@msn.com

This is an Open Access article distributed under the terms of the Creative Commons Attribution Non-Commercial License (<https://creativecommons.org/licenses/by-nc/4.0>) which permits unrestricted non-commercial use, distribution, and reproduction in any medium, provided the original work is properly cited.

## INTRODUCTION

Epipericardial fat necrosis (EPPFN) is an uncommon disease that can cause acute chest pain that mimics myocardial infarction, gastroesophageal reflux, pulmonary thromboembolism, and pericarditis in adults (1). EPPFN is extremely rare in children, with only five pediatric cases having been reported in the English-language medical literature to date (2-6). EPPFN can be diagnosed via the typical CT features and clinical symptoms of acute pleuritic chest pain. However, with the advances in imaging techniques, MRI may be confirmative in the diagnosis with classic fat signal changes and contrast enhancement imaging as reported in adult cases (7, 8). To our knowledge, this is the first reported case of EPPFN that describes gadolinium-enhanced MRI features in the pediatric population.

## CASE REPORT

A 12-year-old female patient presented to the emergency department with a 1-day history of left-sided pleuritic chest pain that worsened upon lying down. The patient had no history of trauma or fever. During the examination, she appeared uncomfortable, with shallow respiration and normal vital signs. Chest auscultation revealed decreased air entry into the left lung. Laboratory tests revealed slightly elevated erythrocyte sedimentation rate and C-reactive protein levels.

In a chest radiograph in the posteroanterior view, a mass-like form that was slightly more radiopaque than normal was noted in the left paracardial region. The inner margin of the radiopacity was obscured due to the heart configuration, indicating an extrapulmonary lesion likely in a pleural or pericardial location (Fig. 1A). Increased retrosternal opacity was also confirmed at the correlated area in the lateral chest radiograph (Fig. 1A).

A CT scan of the chest revealed a low-attenuated round lesion (mean Hounsfield unit  $\pm$  standard deviation =  $-54.8 \pm 22.3$ ) with thickening of adjacent pericardium and surrounded by a capsule of high density in the left anterior mediastinum (Fig. 1B). Combined interlobular septal thickenings of adjacent lung parenchyma were also noted (Fig. 1C). A small amount of left pleural effusion in the posterior pleural space and compressive basal atelectasis in the left lower lobe were also visualized. While we suspected EPPFN based on the CT findings, we recommended an MRI examination to rule out other diseases, including systemic lupus erythematosus, which can cause serositis and viral pericarditis or pleuritis.

T2-weighted breath-hold half Fourier single-shot turbo spin-echo (HASTE) images (repetition time/echo time/flip angle, 450 ms/28 ms/160 degree) revealed a central high-signal lesion with intermediate-signal peripheral rim in the left anterior mediastinum (Fig. 1D). On the same T2 sequence, using the fat saturation technique, the signal of the correlated oval-shaped lesion was suppressed, corresponding to adipose tissue (Fig. 1E). Therefore, we concluded that there was an encapsulated fatty lesion at the epipericardium. Additionally, the pericardium and the pleura adjacent to the lesion showed a high signal intensity, which suggested inflammatory or edematous changes. The epicenter of the inflammation was more likely in the epipericardial fat than in the pericardium or pleura. It was accompanied by scanty pleural fluid loculation in the left anterior pleural space and a small volume of pleural effusion in

**Fig. 1.** A 12-year-old female patient with epipericardial fat necrosis.

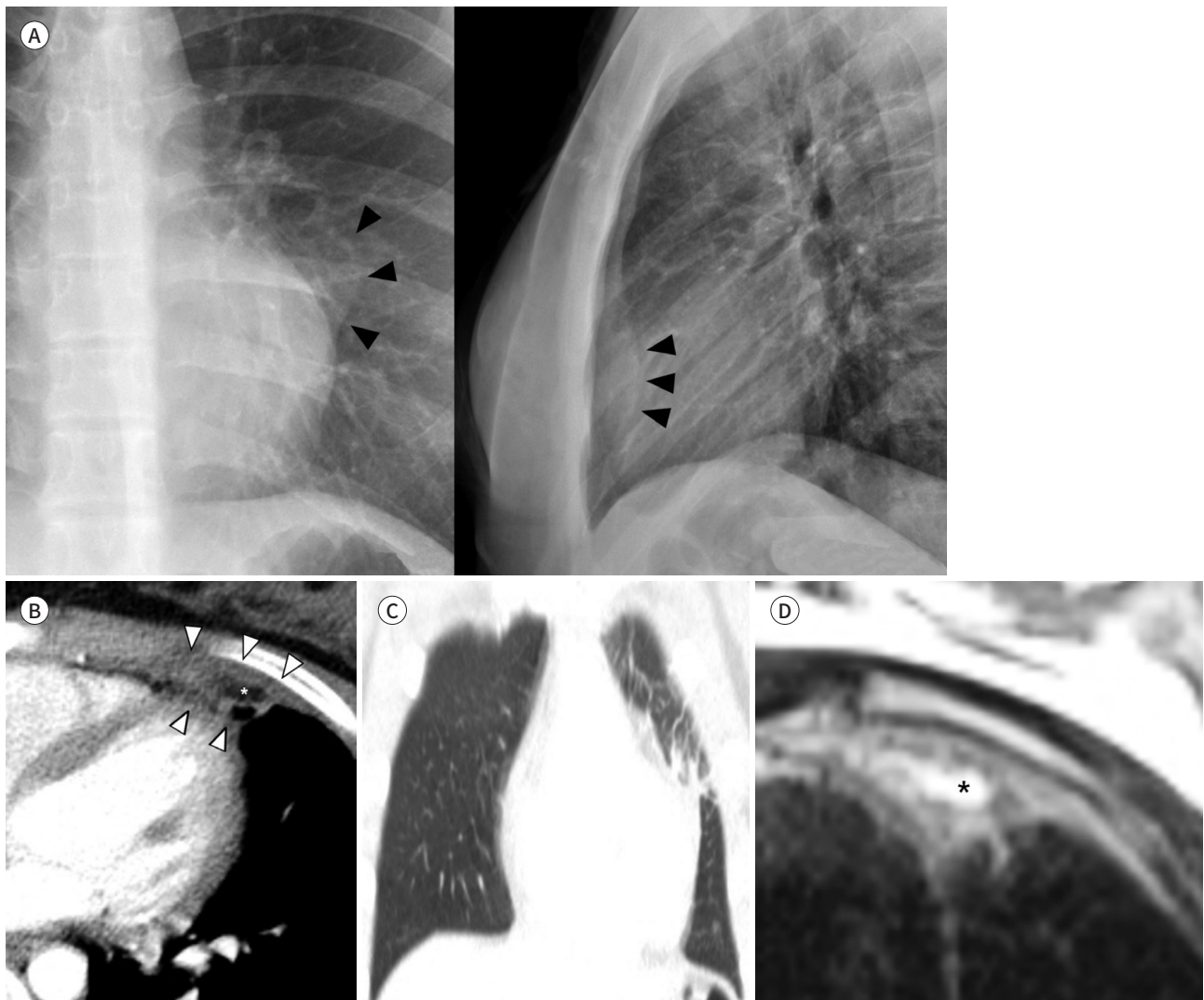
**A.** PA chest radiograph reveals left paracardial opacity with the inner margin partly obscured by the heart configuration (arrowheads), suggesting an extrapulmonary lesion likely in a pleural or pericardial location. The lateral chest radiograph shows increased retrosternal opacity (arrowheads) at the correlated area.

**B.** Contrast-enhanced axial CT scan in the mediastinal window shows that the retrosternal low-attenuation lesion corresponds to epipericardial fat (\*) surrounded by linear opacities and thick peripheral rim, indicating fibrous septa with pleural thickening and pericardial thickening (arrowheads).

**C.** Contrast-enhanced coronal CT scan in the lung window reveals interlobular septal thickening of adjacent epipericardial fat necrosis.

**D.** T2-weighted axial HASTE MR image shows a high-signal lesion (\*) with peripheral intermediate-signal intensity rim adjacent to the pericardium in the left anterior mediastinum. The high-signal lesion displays the same signal intensity as that of subcutaneous fat, likely suggesting epipericardial fat.

PA = posteroanterior, HASTE = half Fourier single-shot turbo spin-echo



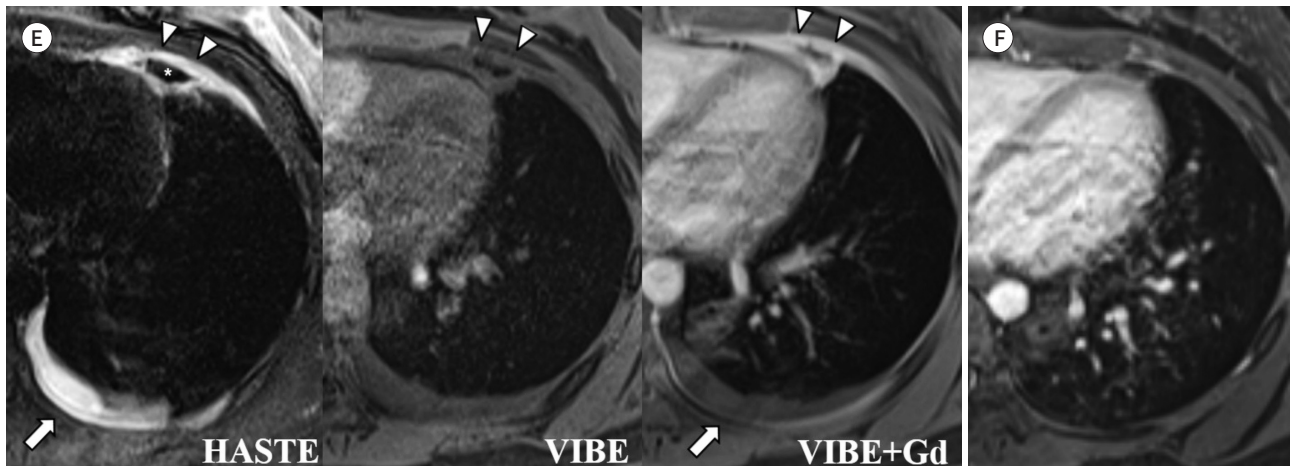
the posterior pleural space on the ipsilateral side. T1-weighted three-dimensional (3D) volumetric interpolated breath-hold examination (VIBE) fat-suppressed images (3.2 ms/1.2 ms/9 degree, section thickness: 3 mm) also revealed a suppressed low-signal lesion with an intermediate-signal rim (Fig. 1E). After gadolinium administration, the peripheral rim in the adjacent pleura were enhanced, suggesting inflammation. The posterior pleural effusion was not

**Fig. 1.** A 12-year-old female patient with epipericardial fat necrosis.

**E.** T2-weighted axial HASTE fat-suppressed image shows a low-signal lesion (\*) with a thin high-signal rim adjacent to the pericardium in the left anterior mediastinum (arrowheads). The low-signal lesion displays the same signal intensity as that of subcutaneous fat, suggesting epipericardial fat. The pericardium and pleura adjacent to the epipericardial fat have a high signal intensity, indicating edematous changes. Additionally, there is a small volume of pleural effusion in the ipsilateral posterior pleural space (arrow). T1-weighted axial VIBE fat-suppressed images after Gd administration show enhancements in the rim (arrowheads) adjacent to the pericardium and pleura compared to the pre-contrast image of the same sequence, indicating inflammatory causes. The posterior pleural effusion is not enhanced and is likely to be of a reactive origin (arrow).

**F.** One-month follow-up T1-weighted axial VIBE fat-suppressed image after Gd administration reveals markedly atrophic changes in the epipericardial fat with minimal to no enhancement, indicating the resolution of the lesion.

Gd = gadolinium, HASTE = half Fourier single-shot turbo spin-echo, VIBE = volumetric interpolated breath-hold examination



enhanced, indicating a reactive origin.

Based on these clinical and radiological findings, the patient was tentatively diagnosed with EPFN. Following treatment with analgesics for one week, the pain gradually decreased and resolved. After one month, the follow-up chest MRI showed marked resolution of the EPFN and the adjacent pericardial thickening, thus confirming our diagnosis (Fig. 1F).

This study obtained an Institutional Review Board approval from the institution, and the need for informed consent was waived (IRB No. GNAH 2021-09-003).

## DISCUSSION

EPFN typically presents as acute pleuritic chest pain in otherwise healthy patients (1, 9). Laboratory data and electrocardiogram findings are often normal. A recent study suggested that proper reporting of EPFN by radiologists can improve by increasing the awareness of the disease (10). While the exact incidence is unknown, a retrospective study indicated that 2.15% of the adult patients who underwent chest CT for acute chest pain were diagnosed with EPFN (9). Only six pediatric EPFN cases have been reported in the English-language literature to date (Table 1) (2-6). The most common presentation of pediatric EPFN is acute pleuritic chest pain with left side dominant. According to 7 cases of pediatric EPFN including our case, all patients were adolescence.

The exact pathogenesis of EPFN remains unknown. Acute torsion of the epipericardial fat may be attributed to ischemic necrosis. Thus, highly positioned epipericardial fat could be a

Table 1. Pediatric Cases of Epipericardial Fat Necrosis Reported in the English Language Literature

| Case No. | Reference                      | Age/<br>Sex | Chief<br>Complaint                                       | CXR Findings   | CT Findings   | MRI Findings  | Size (cm)       | Treatment         |
|----------|--------------------------------|-------------|--|--|---|---|-----------------|-------------------|
| 1        | Aiga et al., 2018 (2)          | 14/F        | Severe chest pain (Lt)                                   | Minimal left pleural effusion  | Nodule with ring enhancement in the pericardial fat of the left anterior mediastinum  | N/A   | 2.2 × 0.7 × 1.8 | AAP, NSAID        |
| 2        | Alomari and Khushaim, 2020 (3) | 13/M        | Pleuritic chest pain (Lt)                                | PA: peripheral opacity lower inferior aspect<br>Lateral: minimal undulation/thickening in lower anterior chest | Ovoid/triangular-shaped mass with internal fat attenuation in the left cardiophrenic sulcus<br>Hyperdense rim, and a central dense dot fat stranding and fluid density in the left cardiophrenic sulcus, with small left-sided pleural effusion | T2WI: heterogeneous predominately bright T2 signal mass with fluid signal in epipericardium<br>T1WI in-phase: an oval shaped mass layered with a rim of intermediate signal, inner wall of high signal and a central low signal<br>T1WI out-of-phase: drop of the high signal | 3.6 × 1.3 × 3.6 | NSAID             |
| 3        | Artunduaga et al., 2020 (4)    | 15/M        | Chest/abdominal pain worsened with deep inspiration (Rt) | N/A  | Mixed fatty and non-fatty soft tissue attenuation mass of uncertain nature abutting the pleura and pericardium  | N/A   | Not available   | AAP               |
| 4        | Bolourchi et al., 2018 (5)     | 15/M        | Sharp non-radiating chest pain (Lt)                      | No abnormalities   | Oval lesion centered within the left epipericardial fat with hyperdense rim, trace left pleural effusion  | N/A   | 2.7 × 1.8 × 3.3 | Analgesics        |
| 5        | Moreira et al., 2020 (6)       | 12/M        | Pleuritic chest pain (Lt)                                | No significant finding   | Ovoid mediastinal fatty lesion in the left cardiophrenic space demarcated by a soft-tissue attenuation rim  | N/A   | 1.5 × 1.4 × 0.9 | NSAID             |
| 6        | Present case                   | 12/F        | Pleuritic chest pain (Lt)                                | PA: left paracardial opacity with incomplete border sign   | Encapsulated fatty lesion with inflammatory changes in left anterior mediastinum  | T2WI fat saturation: high signal intensity of rim of fatty mass as well as adjacent pericardium and pleura<br>T1WI fat saturation with enhancement: enhancing rim of fatty mass as well as adjacent pericardium and pleura  | 1.9 × 0.5 × 1.7 | NSAID (Ibuprofen) |

AAP = acetaminophen, CXR = chest X-ray, N/A = not applicable, NSAID = non-steroidal anti-inflammatory drug, PA = posteroanterior, T1WI = T1-weighted image, T2WI = T2-weighted image



predisposing factor with a higher probability of acute torsion. It is also possible that increased thoracic pressure, such as that induced by the Valsalva maneuver, may raise the capillary pressure, leading to hemorrhagic necrosis (1).

Patients do not require surgical intervention, although excisions were performed to rule out tumorous conditions in the past. The disease has a self-limited course, and treatments with analgesics for one week are sufficient to relieve the chest pain in most cases. Therefore, imaging studies are critical to avoid unnecessary invasive treatments.

The chest CT in our patient revealed an encapsulated fatty lesion with inflammatory changes, including dense strands and thickening of the adjacent pericardium, which were compatible with an EPFN diagnosis (1). These findings are similar to those observed in primary epiploic appendagitis in the peritoneal space. The histopathological findings of fibrous septa in patients with primary epiploic appendagitis correspond to the central linear or dot opacities in the CT. Similarly, central linear opacities in our CT scan may have corresponded to the histopathological findings of fibrous septa in the epipericardial fat. CT on the lung window setting showed subpleural ground glass opacities with interlobular septal thickening, suggesting lymphatic edema due to the inflammatory and edematous changes in the pleura. While we suggested EPFN based on the CT findings, to rule out other diseases that can cause chest pain, such as serositis due to systemic lupus erythematosus or viral infection, we recommended an MRI to confirm EPFN.

The HASTE sequence, a useful breath-hold T2-weighted sequence for the lung parenchyma, was used to obtain a T2-weighted image. Due to its rapid acquisition, HASTE imaging is relatively insensitive to motion artifacts and may be particularly valuable in patients who are unable to hold their breath for longer acquisition periods. We obtained a fat-suppressed HASTE sequence to evaluate the signal change of epipericardial fat. The loss of signal intensity of the central lesion (asterisk) was indicated by the fat saturation pulse, suggestive of adipose tissue (Fig. 1E). The fat-suppressed HASTE sequence is particularly beneficial in diagnosing EPFN, showing a high signal line along the adjacent pericardium and pleura and the rim of epipericardial fat, which suggests inflammatory and edematous changes.

We applied the VIBE sequence, which is a modified fast 3D gradient-echo sequence for further work-up. The VIBE sequence has been known for high image quality, negligible artifacts, and good visualization of the lung anatomy. With contrast enhancement, the rim around the epipericardial fat and the adjacent pericardium and the pleura demonstrated high signal intensities, which may imply inflammatory changes. The enhancement of the central linear signal intensities inside the lesion on MRI may have corresponded with the fibrous septa in the epipericardial fat similar to CT. It was likely caused by the presence of vascularized fibrous or granulation tissue. Combined posterior costal pleural fluid collection without enhancement was considered reactive pleural fluid.

Due to the subtle changes, EPFN may be misinterpreted or overlooked if only a CT scan is used to make a diagnosis. In these patients, MRI can confirm the fat component accurately and depict inflammatory and edematous changes around the lesion better with soft-tissue contrast.

Once fat-containing anterior paracardiac lesion is confirmed, Morgagni hernia or lipoid tumor such as lipoma, thymolipoma or lipoblastoma are also included in differential diagnosis.

In case of Morgagni hernia, omental fat is herniated along the anterior diaphragmatic defect in the cardiophrenic angle, which can be differentiated from EPFN on both CT and MRI by recognition of omental vessels accompanying with herniated omentum. Pericardial lipomas are benign lesions with homogeneous fat mass without enhancing component. Thymolipoma is a rare benign tumor of mediastinum and need surgical resection if compression of the mediastinal structures. Unlike EPFN is usually seen in the healthy pediatric population, thymolipoma can be associated with other disease, such as myasthenia gravis, systemic lupus erythematosus, red cell aplasia, hypogammaglobulinemia, graves' disease and cystic lymphangioma. Lipoblastoma, uncommon mesenchymal tumor with slowly growing, shows well-defined predominantly fatty mass with enhancement which can mimic pediatric EPFN. However, lipoblastoma usually occurs in early childhood, more than 90% before 3 years old. Besides peripheral rim enhancement of EPFN on post-gadolinium MRI is helpful specific finding.

In conclusion, contrast-enhanced MRI may be beneficial in diagnosing EPFN, which can be overlooked when only CT scans are used, and in differentiating EPFN from other causes of acute chest pain.

#### Author Contributions

Conceptualization, R.D.S., C.Y.; data curation, K.S.J.; formal analysis, R.D.S., C.Y., K.S.J.; investigation, K.S.J., C.Y.; methodology, R.D.S., H.B.H.; project administration, H.B.H.; resources, C.Y.; supervision, H.B.H.; validation, K.S.J., H.B.H.; visualization, K.S.J.; writing—original draft, K.S.J., C.Y.; and writing—review & editing, H.B.H., K.Y.R., Y.G.Y., P.W.

#### Conflicts of Interest

The authors have no potential conflicts of interest to disclose.

#### Funding

None

## REFERENCES

1. Pineda V, Cáceres J, Andreu J, Vilar J, Domingo ML. Epipericardial fat necrosis: radiologic diagnosis and follow-up. *AJR Am J Roentgenol* 2005;185:1234-1236
2. Aiga S, Hosoya Y, Nozaki T, Matsusako M. Epipericardial fat necrosis: rare cause of chest pain in children. *Pediatr Int* 2018;60:767-768
3. Alomari L, Khushaim A. Diagnosis of epipericardial fat necrosis on multimodality imaging in a pediatric patient: a case report and review of the literature. *J Radiol Case Rep* 2020;14:16-24
4. Artunduaga M, Fuqua BL, Pierry C, Soto Giordani GA, Roman-Colon AM. Imaging diagnosis of epipericardial fat necrosis in children. *Pediatr Radiol* 2020;50:285-288
5. Bolourchi M, Renjen P, Kovanlikaya A, Baad M, Traister M, Flynn PA, et al. Epipericardial fat pad necrosis—a rare cause of chest pain in an adolescent. *Pediatr Emerg Care* 2021;37:e345-e347
6. Moreira BL, Libânio BB, Pinheiro Santana PR, Marchiori E. Mediastinal fat necrosis. *J Pediatr* 2020;222:250-252
7. Lee HH, Ryu DS, Jung SS, Jung SM, Choi SJ, Shin DH. MRI findings of pericardial fat necrosis: case report. *Korean J Radiol* 2011;12:390-394
8. Neto A, Seabra D, Moreno N, Magalhães S, Pires L, Pinto P. Epipericardial fat necrosis as a differential diagnosis of chest pain—A case report. *Echocardiography* 2020;37:132-134
9. Giassi KS, Costa AN, Bachion GH, Kairalla RA, Filho JRP. Epipericardial fat necrosis: who should be a candidate? *AJR Am J Roentgenol* 2016;207:773-777
10. Haq S, Wilson MP, Manca D. Epipericardial fat necrosis: an uncommon self-limiting cause of pleuritic chest pain. *CMAJ* 2019;191:E1378-E1381

## 소아 심장막 주위 지방 괴사 환자에서의 조영증강 자기공명영상 소견: 증례 보고 및 문헌고찰

김승주 · 한병희\* · 조영종 · 류대식 · 윤가영 · 백우열 · 김영래

심장막 주위 지방 괴사는 급성흉통의 비교적 드문 원인으로서 현재까지 영문으로 보고된 소아 증례는 5건에 불과하다. 심장막 주위 지방 괴사는 급성 흉막통증의 임상증상과 종격동이 나 심장막 부위에 타원형의 피막으로 둘러싸인 지방 병소로 나타나는 전형적인 전산화단층 촬영 소견으로 진단할 수 있다. 성인의 경우 조영증강 자기공명영상 검사가 전형적인 지방 신호 변화를 확인할 수 있어 유용하다는 보고가 있다. 본 논문에서는 저자들은 소아 심장막 주위 지방 괴사 환자의 증례를 통해 조영증강 자기공명영상 소견에 대해 기술하고 급성흉통의 감별진단에 있어 유용성을 보고한다.

울산대학교 의과대학 강릉아산병원 영상의학과