

In vivo observation of intracanalicular changes in association with blinking

Swati Singh, Vikas Mittal, Akshay G Nair¹,
Saurabh Kamal²

Key words: Canaliculus, lacrimal, lacrimal pump, orbicularis

Videos Available on: www.ijo.in	
Access this article online	
Quick Response Code:	Website: www.ijo.in
	DOI: 10.4103/ijo.IJO_240_18

Department of Ophthalmic Plastic Surgery Services, LJ Eye Institute, Ambala, ²Department of Ophthalmic Plastic Surgery and Ocular Oncology Services, EyeHUB Vision Care, Faridabad, Haryana, ¹Department of Ophthalmic Plastic Surgery and Ocular Oncology Services, Advanced Eye Hospital and Institute, Navi Mumbai, Maharashtra, India

Correspondence to: Dr. Swati Singh, LJ Eye Institute, Ambala, Haryana, India. E-mail: dr.swati888@yahoo.com

Manuscript received: 17.02.18; Revision accepted: 14.04.18

Case

We highlight the case of a 60-year-old male where deroofting of the right lower canalicular wall for up to 6 mm was noted. He had previously undergone bilateral lower lid margin mucous membrane grafting for lid margin keratinization.

In this video, we were able to observe the movement of proximal lacrimal system using high-definition videography [Video 1]. The anterior canalicular wall was smooth as compared to the undulations observed along the posterior canalicular wall [Fig. 1a]. The eyelid was gently everted to visualize canaliculus by keeping a Q-tip along the preseptal part of lower eyelid. With eyelid closure, slow motion videography [Video 2] shows collapsing of the canalicular lumen, which creates a siphon-like effect for sucking in tears. The orbicularis contraction around the canaliculus pushes the canalicular walls posteromedially. A near 50% reduction in the canalicular length was noted with near-complete disappearance of the visible canalicular portion on complete closure [Fig. 1b]. No reduction was noted in vertical part of the canaliculus. The punctal and vertical canalicular

This is an open access journal, and articles are distributed under the terms of the Creative Commons Attribution-NonCommercial-ShareAlike 4.0 License, which allows others to remix, tweak, and build upon the work non-commercially, as long as appropriate credit is given and the new creations are licensed under the identical terms.

For reprints contact: reprints@medknow.com

Cite this article as: Singh S, Mittal V, Nair AG, Kamal S. *In vivo* observation of intracanalicular changes in association with blinking. Indian J Ophthalmol 2018;66:1324-5.

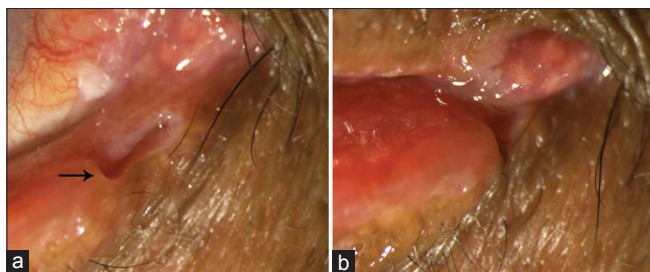


Figure 1: (a) Visible canalicular lumen and walls while eyelid is open (vertical canaliculus marked with arrow). (b) With blinking, canalicular lumen is compressed with visible movement of horizontal canaliculus medially

diameter did not change significantly. Furthermore, the superior and inferior lacrimal punctum approximated at the caruncle with complete closure and reverted to their original position on eyelid opening. The negative pressure created with saline induced narrowing of canalicular wall and the positive pressure caused dilatation of canalicular wall. These changes have been demonstrated with dacryoendoscopy.^[1]

Conclusion

This, we believe, is the first demonstration of *in vivo* canalicular changes in response to blinking. While the absent superior

canalicular wall is less from the ideal and doesn't reflect a true physiological state, but it makes visualization of changes in the other walls and lumen easy. The magnitude of movement of horizontal canaliculus was more compared to vertical canaliculus. The vertical canaliculus maintained its vertical orientation even with eyelid closure [Fig. 1].

Declaration of patient consent

The authors certify that they have obtained all appropriate patient consent forms. In the form, the patient has given his consent for his images and other clinical information to be reported in the journal. The patient understands that name and initials will not be published and due efforts will be made to conceal identity, but anonymity cannot be guaranteed.

Financial support and sponsorship

Nil.

Conflicts of interest

There are no conflicts of interest.

Reference

1. Kakizaki H, Takahashi Y, Mito H, Nakamura Y. Movement of the lacrimal canalicular wall under intracanalicular pressure changes observed with dacryoendoscopy. *Ophthal Plast Reconstr Surg* 2015;31:73-4.