



## Pediatrics

# Giant Congenital Hydronephrosis Obstructing the Gastro Intestinal System and the Contralateral Kidney in a New Born



Ismail Masarwa\*, Zaher Bahouth, Sarel Halachmi

*Urology, Bnai-zion Medical Center, Haifa, Israel*

## ARTICLE INFO

*Article history:*  
Received 27 March 2016  
Received in revised form  
24 April 2016  
Accepted 26 April 2016

*Keywords:*  
Congenital hydronephrosis  
Gastrointestinal obstruction  
Pyelostomy

## ABSTRACT

A 5 day old baby, with known left hydronephrosis which discovered by prenatal US presented with gastrointestinal tract obstruction. Laboratory work up demonstrated abnormal renal function and metabolic acidosis combined with hyperkalemia. Radiology tests showed bilateral hydronephrosis with huge left renal pelvis crossing the midline and causing deviation of the gut laterally. This acute presentation beside inability to receive oral feeding made us prefer immediate left renal drainage with pyelostomy in order to restore renal function, relieve the pressure effect of the huge renal pelvis and stabilize the baby. Dismembered pyeloplasty was done at age of 3 months.  
© 2016 The Authors. Published by Elsevier Inc. This is an open access article under the CC BY-NC-ND license (<http://creativecommons.org/licenses/by-nc-nd/4.0/>).

## Introduction

We report a case of newly born infant with a huge renal pelvis that occupies the left hemi abdomen and crosses the midline affecting adjacent organs and obstructing the bowel and even interfering with drainage of the right kidney.

Bowel obstruction due to giant hydronephrosis is a very rare condition, only few cases reported in the literature. To our knowledge this is the first report describing bowel obstruction in neonate secondary to congenital hydronephrosis.

Beside interesting case description we discussed the need for urgent drainage and offer pyelostomy as the first aid procedure followed by dismembered pyelostomy.

## The case

A 5 day old boy was referred to our hospital due to intestinal obstruction and increased hydronephrosis. He is one of twins and a product of IVF pregnancy delivered by caesarian section at 36 gestational week.

Routine prenatal US screening showed moderate bilateral hydronephrosis with no other abnormal findings.

Initial examination revealed massive abdominal swelling, a large mass was palpated in the left flank and epigastrium. The boy was not able to feed orally and had intermittent vomiting. Laboratory

tests showed abnormal renal function with Cr level of 0.8 mg/dL, Hyperkalemia with K-5.4 meq/L and metabolic acidosis with PH 7.32. Radiology tests included abdominal plain X-ray and Barium Swallow test that showed fullness in the mid abdomen with laterally displaced ascending colon and contrast material that passes through the stomach to small intestine (Fig. 1).

Severe bilateral hydronephrosis with parenchymal thinning and empty urinary bladder was seen in abdominal US (Fig. 2). Voiding cystography showed normal urethra, normal bladder, no reflux and synergic voiding.

Renal MAG-3 scan demonstrated obstructed left kidney with functional impairment. The right kidney had normal perfusion and function but impaired drainage. Split function was 35% for the left kidney and 65% for the right kidney (Fig. 3).

In summary-our patient is a new born with symptoms of intestinal obstruction, abnormal renal function, PH and electrolytes and huge progressive left hydronephrosis secondary to UPJO.

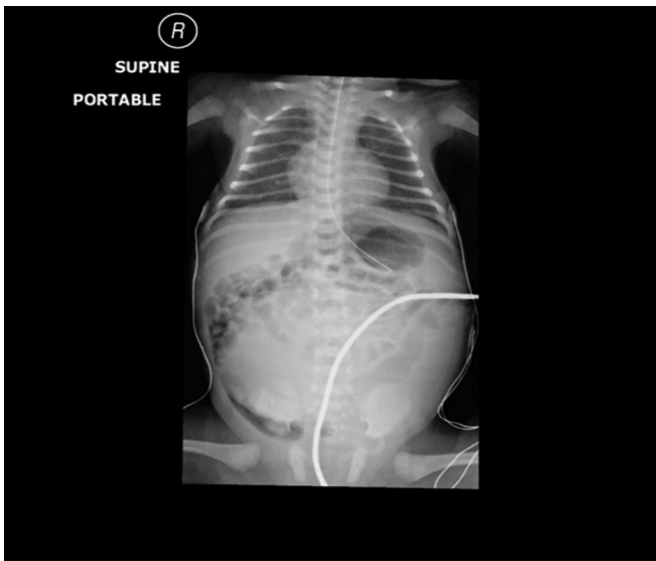## Treatment and follow-up

A nasogastric tube was inserted to decompress the gut and start nutritional supply as soon as possible.

Then the baby was taken to the operating room and a left pyelostomy was performed, when the left renal pelvis was opened more than 200 cc of urine was drained.

A day following the procedure the nasogastric tube was removed and we started oral feeding without any sign of GI obstruction. Hydronephrosis of the right kidney was improved and

\* Corresponding author. Tel.: +97 2 508104112.  
E-mail address: [dr.masarwe@gmail.com](mailto:dr.masarwe@gmail.com) (I. Masarwa).



**Figure 1.** Abdominal X-ray showing fullness in the mid abdomen with laterally displaced ascending colon.

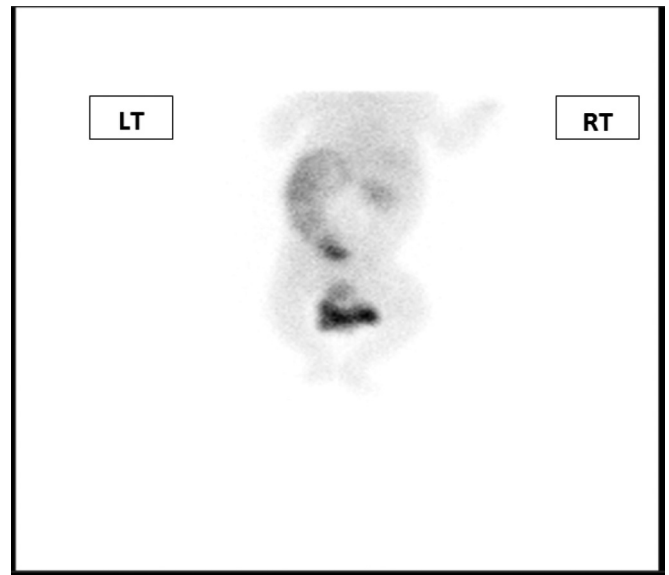
serum CR level declined to 0.4 mg/dL, hyperkalemia and metabolic acidosis resolved and the baby was discharged home at post-operative day 7 in a good general status.

Six weeks later serum CR level remained normal. Renal US showed normal right kidney, marked improvement in the left hydronephrosis and thickening of the parenchyma. These findings show that the left kidney recovered after drainage and that the hydronephrosis seen in the right kidney was secondary to the pressure effect of the huge left renal pelvis.

At age of 3 months we performed an uneventful left dismembered pyeloplasty. Three months after pyeloplasty, the baby is developing well, has normal Cr level and mild left hydronephrosis and improved cortex thickening.

## Discussion

Upjo accounts for 35–50% of all diagnosed congenital uropathies<sup>1</sup> and it is the cause of antenatal hydronephrosis in about 10–30%.<sup>2</sup> Usually UPJO is asymptomatic, however in our unique case the



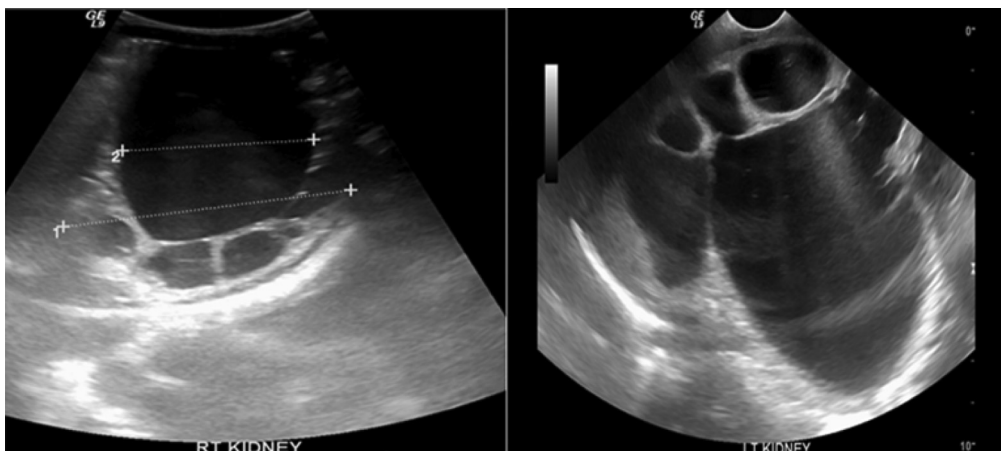
**Figure 3.** Large obstructed left kidney is demonstrated in MAG-3 renal scan.

tremendous hydronephrosis affected adjacent organs and even the contralateral kidney.

The inability to feed orally and deteriorated renal function mandated the need for emergent drainage of the left kidney to restore normal renal function and release the pressure from the gut and adjacent organs.

We performed pyelostomy as it is relatively a short procedure that will give effective large caliber percutaneous drainage unlike the small caliber of nephrostomy tube. Pyelostomy also has the advantage being tubeless, meaning that there is no need for using a foreign body which could be a source of infection and without the risk of migration and spontaneous removal making baby handling problematic for the parents.

Because of the patient acute presentation with deteriorated general status accompanied with acute renal failure, metabolic acidosis and hyperkalemia we preferred to do pyelostomy and not pyeloplasty as it is a shorter and more simple procedure and our goal was to stabilize the baby by minimal intervention. Pyelostomy will achieve effective drainage of the left kidney and release the pressure on the gut with minimal complications that may increase if a more complex surgery done in critically ill new born.



**Figure 2.** Renal US showing sever bilateral hydronephrosis.

Because of the patient age we did not perform nephrectomy aiming to preserve as much as nephron potential as we can and hoping that the kidney will recover after drainage.

Our report presents an interesting rare case of GIT obstruction caused by giant hydronephrosis secondary to UPJO. It also supports the need for antenatal US in detecting congenital urologic malformations and emphasize the need for urgent drainage to relieve the pressure effect caused by the large kidney pelvis and to improve renal function.

#### **Conflict of interest**

There is no conflict of interest.

#### **References**

1. Thomas DFM. Prenatal diagnosis: what do we know of long-term outcomes? *J Pediatr Urol.* 2010;6(3):204–211.
2. Nguyen HT, Herndon CA, Cooper C, et al. The Society for Fetal Urology consensus statement on the evaluation and management of antenatal hydronephrosis. *J Pediatr Urol.* 2010;6(3):212–231.