

## CASE REPORT

# Extra-pulmonary primary small-cell neuroendocrine carcinoma arising from the duodenum: rare tumor, unusual location

Muhammad Awais Aamir<sup>1</sup>, Shaheel Mohammad Sahebally<sup>1</sup> , Hajnalka Gyorffy<sup>2</sup> & Muyiwa Aremu<sup>1</sup>

<sup>1</sup>Department of Surgery, Letterkenny University Hospital, Donegal, Ireland

<sup>2</sup>Department of Pathology, Letterkenny University Hospital, Donegal, Ireland

### Correspondence

Shaheel Mohammad Sahebally, Department of Surgery, Letterkenny University Hospital, Kilmacrenan Road, Donegal, Ireland. Tel: +353-74-9125888; Fax: +353-74-9122824; E-mail: sahebalm@tcd.ie

### Funding Information

No sources of funding were declared for this study.

Received: 1 May 2017; Revised: 29 July 2017; Accepted: 18 October 2017

*Clinical Case Reports* 2017; 5(12): 2117–2120

doi: 10.1002/ccr3.1267

## Introduction

High-grade, poorly differentiated neuroendocrine carcinoma was originally described in the bronchus by Travis et al. [1], and comprises either small-cell or large-cell neuroendocrine carcinoma. However, it can also occur in extra-pulmonary sites, most notably the gastrointestinal tract. Primary, small-cell neuroendocrine carcinoma (SCNC) of the duodenum is extremely rare and was first reported by Swanson et al. [2] in 1986 in an elderly male following a postmortem examination. SCNC carries a poor prognosis despite radical resection and adjuvant therapy, with most cases displaying recurrence and metastasis. We report a fatal case of extra-pulmonary, metastatic primary duodenal SCNC in a young woman.

## Case Presentation

A 40-year-old female was admitted with a 5-week history of worsening epigastric and right upper quadrant

### Key Clinical Message

Small-cell neuroendocrine carcinoma is a high-grade carcinoma rarely encountered in extra-pulmonary sites. A 40-year-old lady presented with epigastric pain and was noted to have an ulcerated small-cell neuroendocrine carcinoma in her duodenum with liver metastases. She underwent palliative chemotherapy but unfortunately passed away. Duodenal SCNC is an unusual malignancy with an aggressive phenotype.

### Keywords

Carcinoma, duodenum, neuroendocrine, small cell.

(RUQ) pain radiating to the back and associated with nausea. Her background history was relevant for endometriosis for which she underwent a previous trans-abdominal hysterectomy. There was no history of gallstone, alcohol intake, or exposure to nonsteroidal anti-inflammatory medications. Physical examination revealed mild epigastric and RUQ tenderness, but Murphy's sign was negative. There were no other pertinent findings on examination.

Blood investigations revealed a deranged liver profile: aspartate aminotransferase (AST) 88 U/L (normal range 0–32 U/L), alanine transaminase (ALT) 75 U/L (normal range 0–33 U/L), alkaline phosphatase (ALP) 310 U/L (normal range 35–104 U/L), gamma-glutamyl transpeptidase (GGT) 311 U/L (normal range 5–36 U/L), and prothrombin time (PT) 12.4 sec (normal range 9.8–11.5 sec). Her hemoglobin was 10.5 g/dL (normal range 11.5–16.5 g/L), and her C-reactive protein (CRP) was 51 mg/L (normal range 0–5 mg/L). There were no other hematological or biochemical abnormalities.

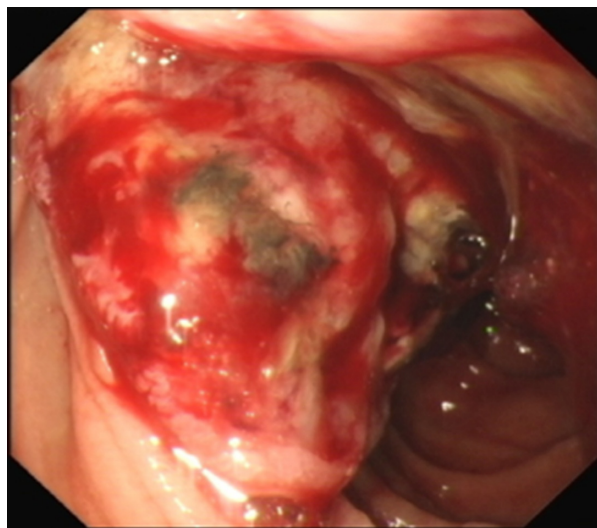
Ultrasound scanning of her abdomen revealed a normal gallbladder and bile duct, but numerous bilobar echogenic hepatic lesions, suspicious for metastases. A contrast-enhanced computerized tomography (CT) scan of her thorax, abdomen, and pelvis confirmed the ultrasonographic hepatic findings (Fig. 1) and showed probable regional aorto-caval lymphadenopathy but did not reveal any primary neoplastic lesions. She proceeded to have an upper oesophago-gastroduodenoscopy, which picked up a nonobstructing ulcerating tumor in the second part of the duodenum (Fig. 2), from which multiple biopsies were taken.

Tumor markers showed a raised CA-125 at 78 U/mL (normal range 0–35 U/mL) and alpha-fetoprotein (AFP) at 10.2 ng/mL (normal range 1.09–8.04 ng/mL). Carcinoembryonic antigen (CEA), carbohydrate antigen (CA 19-9), and CA 15-3 were within normal limits.

Endocrine markers (serotonin, somatostatin, glucagon, and gastrin) were also normal.

Histopathological analysis of duodenal biopsies revealed small tumor cells with hardly visible cytoplasm, demonstrating moderate-to-high pleomorphism. The tumor cells formed no specific architecture, but diffuse infiltration was seen beneath the surface mucosa. Immunohistochemistry showed Cam (anticytokeratin) 5.2, CD56, synaptophysin, and focal CK7 positivity (Fig. 3), while chromogranin, CDX2, CK20, CEA, thyroid transcription factor-1 (TTF-1), CA 19.9, and LCA were negative, consistent with primary duodenal SCNC.

The patient was treated with carboplatin-based chemotherapy but unfortunately her disease progressed



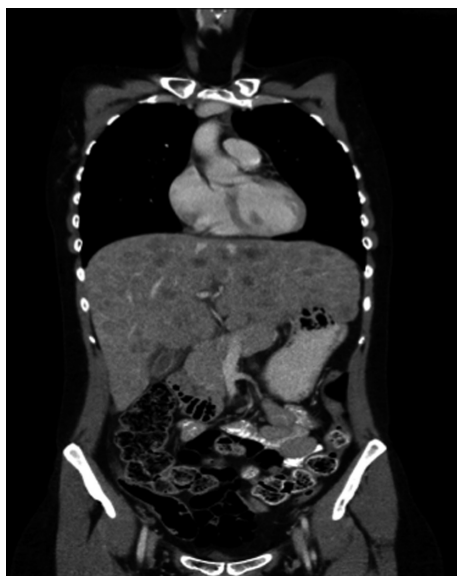**Figure 2.** Oesophago-gastroduodenoscopic image showing an ulcerated, bleeding lesion in the second part of the duodenum, adjacent to the ampulla of Vater.

and she developed bone metastases. She passed away 8 months later.

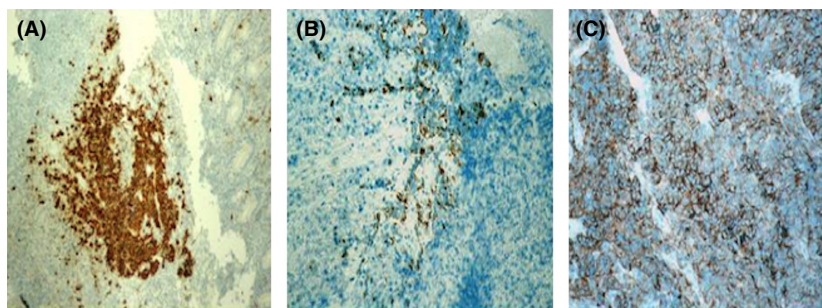
## Discussion

Neuroendocrine tumors (NETs), historically referred to as carcinoids, are potentially malignant tumors originating from enterochromaffin (Kulchitsky) cells located throughout the body [3]. They may secrete vasoactive peptides and neuropeptides, resulting in distinct clinical syndromes, such as the carcinoid syndrome. Gastroenteropancreatic NETs (GEP-NETs) are a heterogeneous group arising from neuroendocrine cells of the embryological gut. While historically classified according to tumor location (i.e., foregut, midgut, or hindgut), the new 2010 World Health Organisation (WHO) subdivides GEP-NETs into three distinct categories: well-differentiated neuroendocrine tumor, well-differentiated neuroendocrine carcinoma, or poorly differentiated neuroendocrine carcinoma (consisting of small-cell and large-cell neuroendocrine carcinoma) [4]. Although these tumors share some common features, they exhibit notable differences in phenotype such as metastatic potential and molecular characteristics. According to the largest NET series reported to date, comprising more than 35,000 cases, the incidence of NET has risen in the last three decades, likely due to improvements in diagnostic imaging and increased use of endoscopy [5, 6].

The highest incidence of NET is seen in the gastrointestinal tract (i.e., gastroenteropancreatic, 67.5%), followed by the bronchopulmonary system (25.3%), with



**Figure 1.** Coronal CT image demonstrating bilobar hepatic lesions, consistent with liver metastases.



**Figure 3.** Immunohistochemical analysis of the tumor demonstrating immunopositivity for (A) CD56, (B) CK7, and (C) synaptophysin (x100).

the rest being distributed between the pancreas, thymus, liver, ovaries, prostate, and kidneys [7]. Among GEP-NETs, most originate from the small intestine (41.8%), rectum (27.4%), appendix (24.1%), and stomach (8.7%) [8]. Duodenal NETs comprise only 5% of all GEP-NETs and are usually well-differentiated tumors [9]. The commonest types of duodenal NETs encountered are gastrinomas, and if functioning may result in Zollinger–Ellison syndrome, while somatostatinomas and gangliocytic paragangliomas are less commonly seen [10]. Small- or large-cell neuroendocrine carcinoma arising from the duodenum is a relatively rare entity. Our case displayed neuroendocrine and small cell morphology, a mitotic count of >13/10 high power field and immunopositivity for the neuroendocrine marker synaptophysin, thus fulfilling the criteria for diagnosis of SCNC. Furthermore, it was a primary duodenal SCNC, and not a pulmonary metastasis, as the tumor was negative for TTF-1, a marker of pulmonary origin, and there were no pulmonary or mediastinal abnormalities on CT. However, the current case did not display a clinical endocrinopathy and serum endocrine markers were normal. Nonetheless, the tumor was associated with an aggressive clinical behavior, manifested by rapid hepatic and bony metastasis, as well as a precipitously fatal course despite treatment with chemotherapy. Although the majority of duodenal NETs are sporadic, they may occasionally be associated with distinct syndromes such as neurofibromatosis type 1 (NF-1) or multiple endocrine neoplasia type 1 (MEN-1) [11, 12]. According to a retrospective study of 28 patients who underwent surgical resection for well-differentiated duodenal NETs, all tumors were noted to demonstrate both arterial and venous phase enhancement during CT examination [13]. This is in contrast to an adenocarcinoma, which is hypovascular and hence nonenhancing.

In summary, this case highlights the aggressive nature of SCNC and underscores the need to incorporate the duodenum as a potential primary site of origin of SCNC in the absence of a pulmonary lesion.

## Authorship

AA, SMS, and MA: involved in patient management; HG: performed histopathological analysis; AA, SMS, and MA: wrote the manuscript; HG and MA: involved in critical appraisal and final approval of manuscript draft.

## Conflict of Interest

None declared.

## References

1. Travis, W. D., R. I. Linnoila, M. G. Tsokos, C. L. Hitchcock, G. B. Jr Cutler, L. Nieman, et al. 1991. Neuroendocrine tumors of the lung with proposed criteria for large-cell neuroendocrine carcinoma. An ultrastructural, immunohistochemical, and flow cytometric study of 35 cases. *Am. J. Surg. Pathol.* 15:529–553.
2. Swanson, P. E., D. Dykoski, M. R. Wick, and D. C. Snover. 1986. Primary duodenal small-cell neuroendocrine carcinoma with production of vasoactive intestinal polypeptide. *Arch. Pathol. Lab. Med.* 110:317–320.
3. Modlin, I. M., K. D. Lye, and M. Kidd. 2003. A 5-decade analysis of 13,715 carcinoid tumors. *Cancer* 97:934–959.
4. Rindi, G. 2010. Nomenclature and classification of neuroendocrine neoplasms of the digestive system. Pp. 13–14 in F. T. Bosman, F. Carneiro, R. H. Hruban and N. D. Theise, eds. *WHO classification of tumors of the digestive system*. IARC Press, Lyon.
5. Yao, J. C., M. Hassan, A. Phan, C. Dagohoy, C. Leary, J. E. Mares, et al. 2008. One hundred years after “carcinoid”: epidemiology of and prognostic factors for neuroendocrine tumors in 35,825 cases in the United States. *J. Clin. Oncol.* 26:3063–3072.
6. Hallet, J., C. H. Law, M. Cukier, R. Saskin, N. Liu, and S. Singh. 2015. Exploring the rising incidence of neuroendocrine tumors: a population-based analysis of epidemiology, metastatic presentation, and outcomes. *Cancer* 121:589–597.

7. Kunz, P. L. 2015. Carcinoid and neuroendocrine tumors: building on success. *J. Clin. Oncol.* 33:1855–1863.
8. Lawrence, B., B. I. Gustafsson, A. Chan, B. Svejda, M. Kidd, and I. M. Modlin. 2011. The epidemiology of gastroenteropancreatic neuroendocrine tumors. *Endocrinol. Metab. Clin. North Am.* 40:1–18, vii.
9. Chang, S., D. Choi, S. J. Lee, W. J. Lee, M. H. Park, S. W. Kim, et al. 2007. Neuroendocrine neoplasms of the gastrointestinal tract: classification, pathologic basis, and imaging features. *Radiographics* 27:1667–1679.
10. Levy, A. D., and L. H. Sobin. 2007. From the archives of the AFIP: Gastrointestinal carcinoids: imaging features with clinicopathologic comparison. *Radiographics* 27:237–257.
11. Scarsbrook, A. F., A. Ganeshan, J. Statham, R. V. Thakker, A. Weaver, D. Talbot, et al. 2007. Anatomic and functional imaging of metastatic carcinoid tumors. *Radiographics* 27:455–477.
12. Gut, P., H. Komarowska, A. Czarnywojtek, J. Waligorska-Stachura, M. Baczyk, K. Ziemnicka, et al. 2015. Familial syndromes associated with neuroendocrine tumours. *Contemp. Oncol. (Pozn)* 19:176–183.
13. Tsai, S. D., S. Kawamoto, C. L. Wolfgang, R. H. Hruban, and E. K. Fishman. 2015. Duodenal neuroendocrine tumors: retrospective evaluation of CT imaging features and pattern of metastatic disease on dual-phase MDCT with pathologic correlation. *Abdom. Imaging* 40:1121–1130.