

# Immunotherapy of Nivolumab with Dendritic Cell Vaccination Is Effective against Intractable Recurrent Primary Central Nervous System Lymphoma: A Case Report

Motomasa FURUSE,<sup>1</sup> Naosuke NONOGUCHI,<sup>1</sup> Naoki OMURA,<sup>1</sup>  
Mitsuaki SHIRAHATA,<sup>2</sup> Koichi IWASAKI,<sup>2</sup> Toshio INUI,<sup>3</sup>  
Toshihiko KUROIWA,<sup>1</sup> Hiroko KUWABARA,<sup>4</sup>  
and Shin-Ichi MIYATAKE<sup>1</sup>

<sup>1</sup>Department of Neurosurgery, Osaka Medical College, Takatsuki, Osaka, Japan;

<sup>2</sup>Department of Neurosurgery, Kitano Hospital, Tazuke Kofukai Medical Research Institute, Osaka, Osaka, Japan;

<sup>3</sup>Saisei Mirai Medical Corporation, Moriguchi, Osaka, Japan;

<sup>4</sup>Department of Pathology, Osaka Medical College, Takatsuki, Osaka, Japan

## Abstract

We report effective treatment with nivolumab of a patient with recurrent primary central nervous system lymphoma (PCNSL) after multiple therapies. A 41-year-old woman with a right parietal PCNSL underwent treatment with high-dose methotrexate and radiotherapy. After recurrence in the left frontal lobe, the patient received several chemotherapies, including methotrexate and rituximab, and underwent surgery. The tumor was refractory to these treatments, and the patient then underwent intensity-modulated radiotherapy (IMRT). Multiple small, new recurrent tumors appeared in the right frontal lobe and the left frontoparietal region 2 months after IMRT. The patient received nivolumab 3 mg/kg with dendritic cell vaccination. Complete remission of the tumors was achieved after six cycles of nivolumab, and remission was maintained for 10 months after the initiation of nivolumab. Nivolumab could be a novel treatment for intractable recurrent PCNSL in the future.

Keywords: immunotherapy, nivolumab, PCNSL, recurrence

## Introduction

Primary central nervous system lymphoma (PCNSL) is a brain tumor sensitive to chemotherapy and radiotherapy. Methotrexate (MTX)-based chemotherapy is a first-line therapy for PCNSL. High-dose methotrexate (HD-MTX) followed by radiotherapy has high response rates.<sup>1,2)</sup> However, PCNSL always relapses after chemo-radiotherapy, and no treatment has had convincing beneficial effects on recurrent PCNSL. Median survival after recurrence is 14 months, even with salvage therapy.<sup>3)</sup> Recurrent PCNSL is one of the intractable brain tumors refractory to any treatment and still has a poor prognosis.

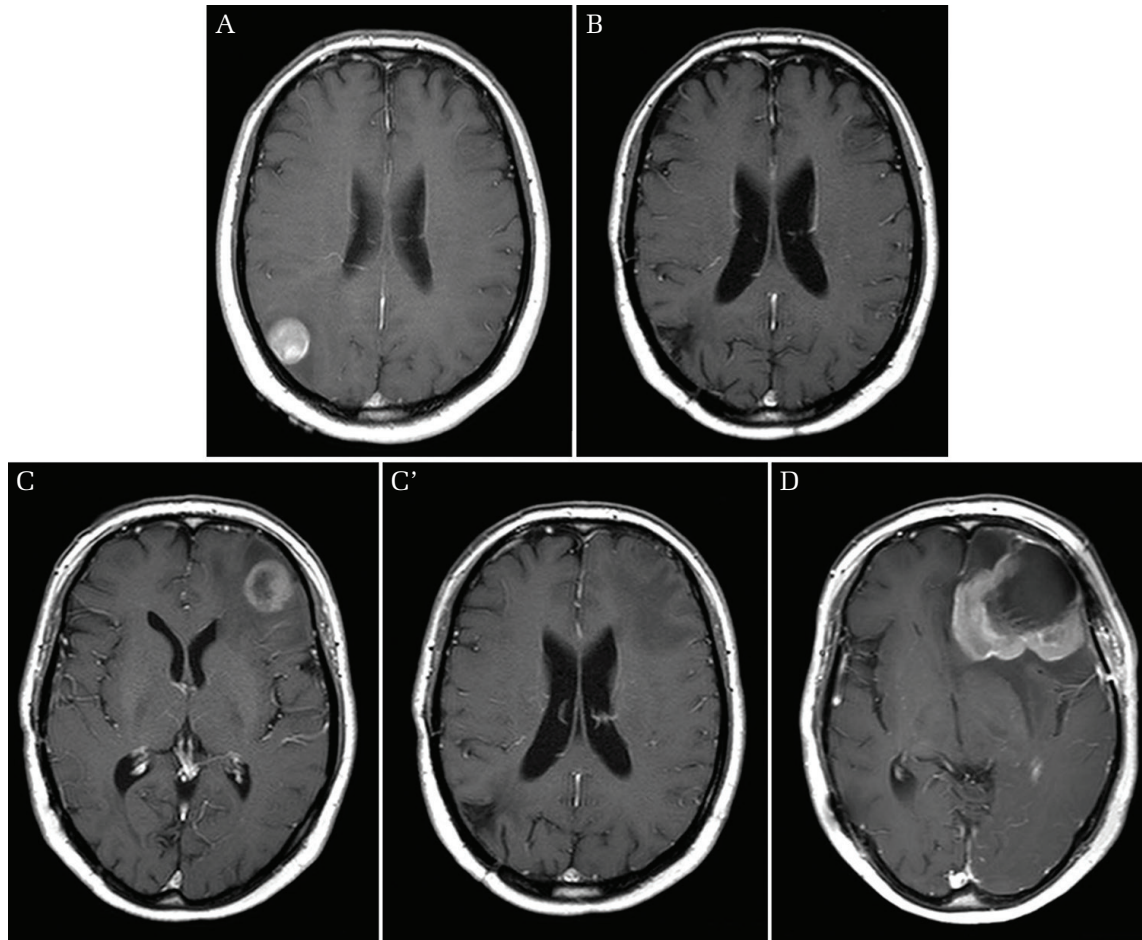
Immunotherapy of cancer by programmed cell death-1 (PD-1) and PD-1 ligand (PD-L1) blockade has attracted attention and led to an expectation of a breakthrough

cancer treatment. Nivolumab has already been approved by the Food and Drug Administration for melanoma, lung cancer, renal cell carcinoma, and Hodgkin's lymphoma.<sup>4-9)</sup> The efficacy of nivolumab for central nervous system malignancy is unknown.

We observed that multiple recurrent tumors underwent complete remission in a patient with recurrent PCNSL after multiple treatments with nivolumab. Our patient also had dendritic cell vaccination while concurrently receiving nivolumab. We report this case here, with a discussion of the possibility of cancer immunotherapy for PCNSL.

## Case Report

A 41-year-old woman with a right parietal tumor (Fig. 1A) underwent surgery with a diagnosis of PCNSL. The tumor recurred soon after the surgery, and the patient had two



**Fig. 1** The patient had a right parietal mass at onset of PCNSL (A). The tumor was completely remitted after two cycles of high-dose methotrexate therapy and whole-brain radiotherapy (B). The tumor recurred in the left frontal lobe without local recurrence of the right parietal tumor 2.5 years after radiotherapy (C and C'). The tumor progressed in spite of multiple sessions of chemotherapy and surgical resection (D).

courses of HD-MTX therapy. The patient received whole-brain radiotherapy after HD-MTX therapy because the tumor did not respond to HD-MTX and progressed. The tumor had been completely remitted after radiotherapy for 2.5 years (Fig. 1B). The patient had a relapse of the tumor in the left frontal lobe without a local recurrence of the original tumor (Figs. 1C and 1C') and received multiple sessions of chemotherapy with several combinations, including rituximab, cytarabine, and MTX with peripheral blood stem-cell transfusion, and cyclophosphamide-hydroxydaunorubicine-vincristine-prednisolone (CHOP) with MTX. The patient also had arterial infusion of carboplatin plus melphalan or carboplatin plus MTX in combination with intravenous infusion of rituximab. All of these chemotherapies failed to control the tumor, and the patient underwent surgery again followed by brentuximab. Although the tumor was grossly totally resected, it soon relapsed again (Fig. 1D). The patient then underwent intensity-modulated radiotherapy (IMRT) and the tumor went into remission. Two months

later, multiple small, new tumors appeared in the right frontal lobe and the left frontoparietal region (Fig. 2A, white arrows). The patient started to receive nivolumab 3 mg/kg with and sometimes without dendritic cell vaccination. The patient underwent nivolumab at her own expense in the private practice clinic (Saisei Mirai Medical Corporation) with sufficient informed consent. The multiple small, new tumors were completely remitted after six cycles of nivolumab (Fig. 2B). After four more cycles, magnetic resonance images taken 7 months after IMRT showed a contrast-enhanced lesion adjacent to the left frontal horn of the lateral ventricle (Fig. 3A), and the patient showed a personality change.  $^{11}\text{C}$ -methionine positron emission tomography (PET) revealed low uptake of methionine in this lesion, which indicated radiation necrosis (Fig. 3B). A single dose of bevacizumab 5 mg/kg was administered for symptomatic radiation necrosis. Complete remission was still maintained 10 months after initiation of nivolumab with dendritic cell vaccination (Fig. 3C).

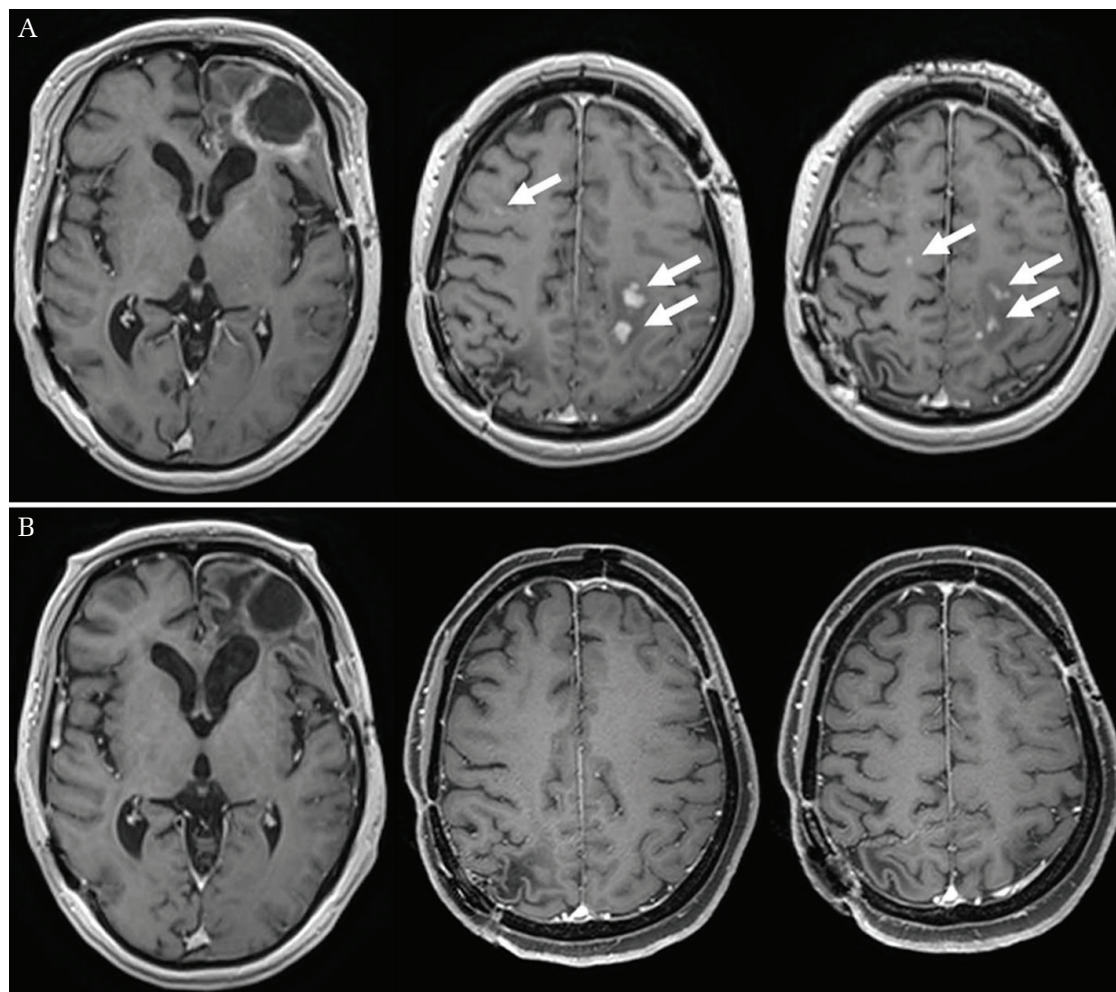


Fig. 2 The left frontal tumor responded to intensity-modulated radiotherapy, but multiple small, new tumors appeared in the right frontal lobe and the left frontoparietal region (*white arrows*) (A). The multiple small, new tumors were completely remitted after nivolumab and dendritic cell vaccination (B).

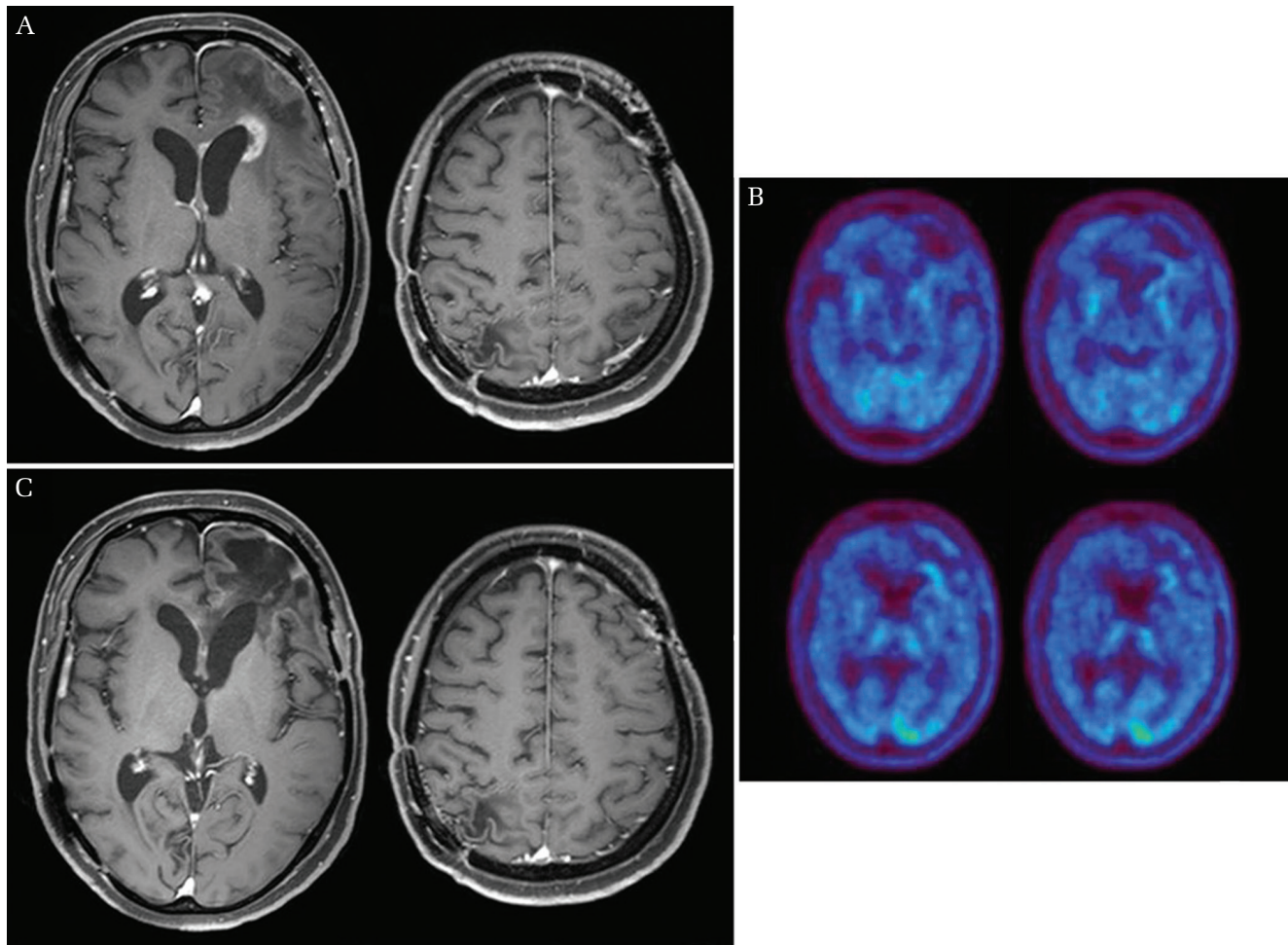
## Discussion

Chemotherapy including MTX at a dose of 3 to 8 mg/m<sup>2</sup> is recommended as first-line treatment for PCNSL.<sup>1,10-12)</sup> The CHOP regimen, with or without rituximab, which is one of the standard treatments for extracranial non-Hodgkin's lymphoma, is not effective against PCNSL because it is difficult for these agents to penetrate the blood-brain barrier. PCNSL is a radio-sensitive tumor, and therefore radiation therapy plays an important role in its treatment. However, the tumor always relapses after radiation therapy, and after recurrence, there is no effective therapy for PCNSL. Rechallenge with HD-MTX is still effective against recurrent tumors in patients who responded to initial HD-MTX.<sup>13)</sup> In cases with relapse after radiation therapy, however, rechallenge with MTX after radiation therapy can carry a risk of leukoencephalopathy, which causes impairment of cognition because

irradiation alters the distribution kinetics of MTX in the brain.<sup>14)</sup> Temozolomide is one of the anticancer drugs that is expected to be effective against PCNSL, and clinical trials have already been performed to test the efficacy of temozolomide for recurrent PCNSL.<sup>15,16)</sup>

Immune checkpoint inhibitors are expected to be novel treatments for many cancers. Tumor cells express PD-L1 to bind PD-1 on T cells to escape the immune response. Therefore, PD-L1 should be the key molecule of this treatment strategy. It has been reported that PD-L1 expression on tumor cells is correlated with an objective response to nivolumab.<sup>17)</sup> We anticipated that the tumor cells in our patient should express PD-L1 abundantly. Figure 4 shows the results of immunohistochemistry (IHC) in this patient. IHC using anti-cluster of differentiation (CD)20 antibody showed strong positive staining, demonstrating the nature of this PCNSL as diffuse large B-cell lymphoma (DLBCL) (Fig. 4A''). Figure 4C shows that the strong immune





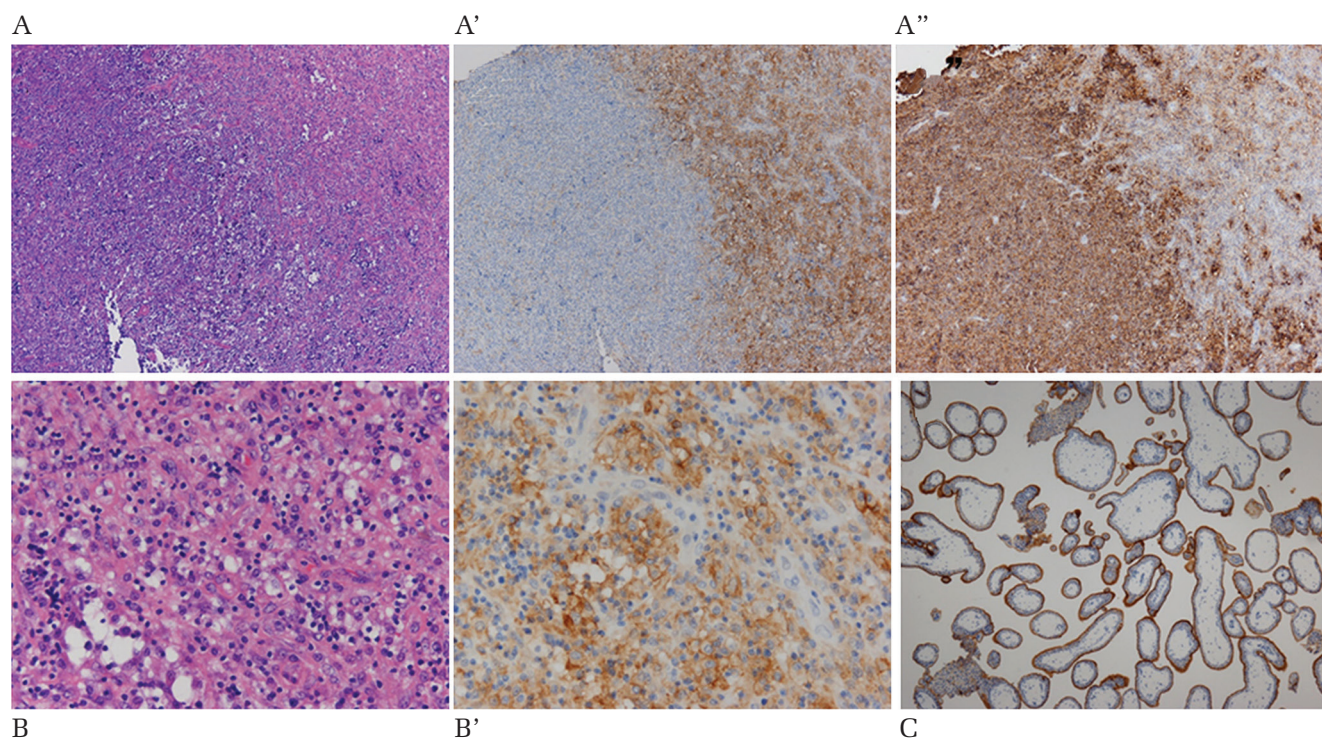
**Fig. 3** A new enhancing lesion appeared in the left frontal lobe 7 months after intensity-modulated radiotherapy, but the multiple small, new tumors were still in remission (A).  $^{11}\text{C}$ -methionine-PET revealed low uptake of the tracer in this enhancing lesion (B). This lesion was diagnosed as radiation necrosis on the basis of PET findings. Complete remission was maintained 10 months after initiation of nivolumab and dendritic cell vaccination with a single dose of bevacizumab (C).

staining of PD-L1 was confirmed in the trophoblastic membrane of human placenta as positive control, showing that this IHC assay worked well. On the other hand, PD-L1 was not expressed on tumor cells in the surgical specimen of our patient, but it was markedly expressed on macrophages, which were stained by CD 68 (data not shown) in the granulomatous tissue around the tumor (Figs. 4A' and B').

According to published reports, PD-L1 expression on tumor cells and immune cells in tumor tissue may predict the response to anti-PD-1/PD-L1 immunotherapy.<sup>18)</sup> In metastatic bladder cancer, PD-L1 expression on immune cells in tumor tissue is the most predictive of the response to an anti-PD-L1 antibody.<sup>19)</sup> A meta-analysis in melanoma, lung, and genitourinary cancers showed that an objective response rate to nivolumab was 22.9% in tumors without PD-L1 expression on tumor cells.<sup>20)</sup> With regard to DLBCL, an objective response rate was 36%, although PD-L1 did not express on tumor cells in all patients from whom

tissue sample was obtained for IHC analysis.<sup>21)</sup> However, PD-L1 expressed on nonmalignant immune cells within the tumor microenvironment in these patients. PD-L1 positive immune cells may be responsible for tumor response to nivolumab in PD-L1 negative tumors which respond to nivolumab. A possible hypothesis in our patient is that PD-L1 on tumor-associated macrophages binds to PD-1 on T cells to inactivate T cell-mediated immunity. Nivolumab may suppress this PD-L1–PD-1 interaction, and consequently T cells are activated, resulting in attacking tumor cells.

During the treatment with nivolumab, the enhanced lesion appeared in the region located in the re-irradiated tumor in spite of maintaining complete remission in new lesions. We diagnosed this lesion as radiation necrosis on the basis of  $^{11}\text{C}$ -methionine PET, and low-dose bevacizumab was administered to treat the radiation necrosis, because this frontal enhanced lesion was symptomatic. We considered that amino acid PET was reliable to



**Fig. 4** Results of hematoxylin and eosin (H&E) staining and immunohistochemistry (IHC) of surgical specimen. A, A', and A'' are  $\times 40$  magnification and show almost the identical photomicrograph field. H&E stain shows tumor cells with granulomatous tissue and infiltrating macrophages (A). Anti-PD-L1 IHC shows that macrophages in granulomatous tissue are positively stained (A'), and tumor cells that are stained by anti-CD 20 IHC (A'') are not stained by anti-PD-L1 IHC. B and B' are higher-powered ( $\times 200$ ) photomicrographs showing H&E staining and anti-PD-L1 IHC of the granulomatous field of A, A', and A''. Oval tumor cells are not stained by anti-PD-L1 IHC (B'). IHC of human placenta shows that the trophoblastic membrane is stained as positive control for PD-L1 expression (C,  $\times 20$ ). Immunostaining was performed with a BOND-MAX autoimmunostainer (Leica Microsystems, Wetzlar, Germany). Deparaffinized and rehydrated sections were subjected to endogenous peroxidase blocking. After heating in antigen unmasking solution, the slides were incubated with PD-L1 (E1L3N, Cell Signaling Technology, Danvers, MA, USA) or with CD20 (L26, Dako, Santa Clara, CA, USA). Color development was performed with DAB, and the slides were counterstained with hematoxylin. Placental tissues were used as positive controls, and procedures without a primary antibody were used as negative controls.

distinguish radiation necrosis from tumor recurrence, and low-dose bevacizumab was effective on radiation necrosis.<sup>22-24</sup> Although we thought that the tumor was not recurred after initiation of nivolumab so far, it should be noted that a case report showed effectiveness of bevacizumab on recurrent PCNSL.<sup>25</sup> Although we experienced only one effective case, nivolumab should be considered as alternative treatment strategy for recurrent PCNSL which is refractory to other treatments. Also vigorous study is necessary regarding PD-L1 and PD-1 expression on PCNSL.

Dendritic cell vaccination is a cancer immunotherapy that dendritic cells which are cultured and loaded with tumor antigen *ex vivo* activate T-cell to attack tumor cells by presenting tumor antigen. Dendritic cell vaccination has been already tested for some of cancers in clinical trials.<sup>26</sup> The results of these trials were not conclusive, but encouraging further study. Treatment effect to combine nivolumab with dendritic cell vaccination is unknown. Inhibition of immune checkpoint by nivolumab and induction of tumor-specific effector T-cells by dendritic cell vaccination are theoretically

reasonable combined cancer immunotherapy. A clinical trial of nivolumab with dendritic cell vaccines is now ongoing for recurrent brain tumors (AVERT trial, NCT02529072). It is to be hoped that clinical trials including AVERT trial will clarify probability of cancer immunotherapy for intractable brain tumors, especially in recurrent PCNSL.

## Conclusion

Immunotherapy of nivolumab with dendritic cell vaccination is expected to be a novel treatment for intractable recurrent PCNSL. Recurrent tumors were completely remitted after nivolumab treatment, although PD-L1 was expressed not on tumor cells but on tumor-associated macrophages in our patient. The correlation between IHC of PD-L1 and the response to nivolumab in PCNSL should be elucidated. The optimal dose and duration of nivolumab should also be clarified in further study, because nivolumab is very expensive, and continuation of a useless treatment puts a burden on patients and medical insurance. Dendritic cell vaccination theoretically reinforces effects of nivolumab



on tumors and the synergistic effect of nivolumab and dendritic cell vaccination should also be elucidated.

### Acknowledgment

We thank Drs. Lakshmi Nayak and David Reardon of the Dana-Farber Cancer Institute, Harvard Medical School, the former for her excellent talk at the Asian Society of Neuro-Oncology 2016 in Sydney and the latter for fruitful discussion of the mechanism of the effectiveness of nivolumab for this case at Society of Neuro-Oncology 2016 in Scottsdale. This work was partly supported by a Grant-in-Aid for Scientific Research (C) (26462222) given to M.F. from the Japanese Ministry of Education, Culture, Sports, Science, and Technology.

### Conflicts of Interest Disclosure

The authors report no conflicts of interest concerning materials used in this case report.

### References

- Glass J, Gruber ML, Cher L, Hochberg FH: Preirradiation methotrexate chemotherapy of primary central nervous system lymphoma: Long-term outcome. *J Neurosurg* 81: 188–195, 1994
- Hiraga S, Arita N, Ohnishi T, Kohmura E, Yamamoto K, Oku Y, Taki T, Sato M, Aozasa K, Yoshimine T: Rapid infusion of high-dose methotrexate resulting in enhanced penetration into cerebrospinal fluid and intensified tumor response in primary central nervous system lymphomas. *J Neurosurg* 91: 221–230, 1999
- Reni M, Ferreri AJ, Villa E: Second-line treatment for primary central nervous system lymphoma. *Br J Cancer* 79: 530–534, 1999
- Robert C, Long GV, Brady B, Dutriaux C, Maio M, Mortier L, Hassel JC, Rutkowski P, McNeil C, Kalinka-Warzocha E, Savage KJ, Hernberg MM, Lebbe C, Charles J, Mihalciou C, Chiarion-Sileni V, Mauch C, Cognetti F, Arance A, Schmidt H, Schadendorf D, Gogas H, Lundgren-Eriksson L, Horak C, Sharkey B, Waxman IM, Atkinson V, Ascierto PA: Nivolumab in previously untreated melanoma without braf mutation. *New Engl J Med* 372: 320–330, 2015
- Weber JS, D'Angelo SP, Minor D, Hodi FS, Gutzmer R, Neyns B, Hoeller C, Khushalani NI, Miller WH, Jr., Lao CD, Linette GP, Thomas L, Lorigan P, Grossmann KF, Hassel JC, Maio M, Sznol M, Ascierto PA, Mohr P, Chmielowski B, Bryce A, Svane IM, Grob JJ, Krackhardt AM, Horak C, Lambert A, Yang AS, Larkin J: Nivolumab versus chemotherapy in patients with advanced melanoma who progressed after anti-ctla-4 treatment (checkmate 037): a randomised, controlled, open-label, phase 3 trial. *Lancet Oncol* 16: 375–384, 2015
- Borghaei H, Paz-Ares L, Horn L, Spigel DR, Steins M, Ready NE, Chow LQ, Vokes EE, Felip E, Holgado E, Barlesi F, Kohlhäufel M, Arrieta O, Burgio MA, Fayette J, Lena H, Poddubskaya E, Gerber DE, Gettinger SN, Rudin CM, Rizvi N, Crinò L, Blumenschein GR, Jr., Antonia SJ, Dorange C, Harbison CT, Graf Finckenstein F, Brahmer JR: Nivolumab versus docetaxel in advanced nonsquamous non-small-cell lung cancer. *N Engl J Med* 373: 1627–1639, 2015
- Brahmer J, Reckamp KL, Baas P, Crinò L, Eberhardt WE, Poddubskaya E, Antonia S, Pluzanski A, Vokes EE, Holgado E, Waterhouse D, Ready N, Gainor J, Aren Frontera O, Havel L, Steins M, Garassino MC, Aerts JG, Domine M, Paz-Ares L, Reck M, Baudelet C, Harbison CT, Lestini B, Spigel DR: Nivolumab versus docetaxel in advanced squamous-cell non-small-cell lung cancer. *New Engl J Med* 373: 123–135, 2015
- Motzer RJ, Escudier B, McDermott DF, George S, Hammers HJ, Srinivas S, Tykodi SS, Sosman JA, Procopio G, Plimack ER, Castellano D, Choueiri TK, Gurney H, Donskov F, Bono P, Wagstaff J, Gaurer TC, Ueda T, Tomita Y, Schutz FA, Kollmannsberger C, Larkin J, Ravaud A, Simon JS, Xu LA, Waxman IM, Sharma P: Nivolumab versus everolimus in advanced renal-cell carcinoma. *N Engl J Med* 373: 1803–1813, 2015
- Ansell SM, Lesokhin AM, Borrello I, Halwani A, Scott EC, Gutierrez M, Schuster SJ, Millenson MM, Cattry D, Freeman GJ, Rodig SJ, Chapuy B, Ligon AH, Zhu L, Grosso JF, Kim SY, Timmerman JM, Shipp MA, Armand P: Pd-1 blockade with nivolumab in relapsed or refractory hodgkin's lymphoma. *New Engl J Med* 372: 311–319, 2015
- Batchelor T, Carson K, O'Neill A, Grossman SA, Alavi J, New P, Hochberg F, Priet R: Treatment of primary CNS lymphoma with methotrexate and deferred radiotherapy: A report of nabtt 96-07. *J Clinical Oncol* 21: 1044–1049, 2003
- Reni M, Ferreri AJ, Guha-Thakurta N, Blay JY, Dell'Oro S, Biron P, Hochberg FH: Clinical relevance of consolidation radiotherapy and other main therapeutic issues in primary central nervous system lymphomas treated with upfront high-dose methotrexate. *Int J Radiat Oncol Biol Phys* 51: 419–425, 2001
- Thiel E, Korfel A, Martus P, Kanz L, Griesinger F, Rauch M, Roth A, Hertenstein B, von Toll T, Hundsberger T, Mergenthaler HG, Leithauser M, Birnbaum T, Fischer L, Jahnke K, Herrlinger U, Plasswilm L, Nägele T, Pietsch T, Bamberg M, Weller M: High-dose methotrexate with or without whole brain radiotherapy for primary CNS lymphoma (g-pcnsl-sg-1): A phase 3, randomised, non-inferiority trial. *Lancet Oncol* 11: 1036–1047, 2010
- Plotkin SR, Betensky RA, Hochberg FH, Grossman SA, Lesser GJ, Nabors LB, Chon B, Batchelor TT: Treatment of relapsed central nervous system lymphoma with high-dose methotrexate. *Clin Cancer Res* 10: 5643–5646, 2004
- Bleyer WA: Neurologic sequelae of methotrexate and ionizing radiation: A new classification. *Cancer Treat Rep* 65 Suppl 1: 89–98, 1981
- Reni M, Mason W, Zaja F, Perry J, Franceschi E, Bernardi D, Dell'Oro S, Stelitano C, Candela M, Abbadessa A, Pace A, Bordonaro R, Latte G, Villa E, Ferreri AJ: Salvage chemotherapy with temozolomide in primary CNS lymphomas: Preliminary results of a phase II trial. *Eur J Cancer*. 40: 1682–1688, 2004
- Enting RH, Demopoulos A, DeAngelis LM, Abrey LE: Salvage therapy for primary CNS lymphoma with a combination of rituximab and temozolomide: *Neurology* 63: 901–903, 2004

- 17) Taube JM, Klein A, Brahmer JR, Xu H, Pan X, Kim JH, Chen L, Pardoll DM, Topalian SL, Anders RA: Association of pd-1, pd-1 ligands, and other features of the tumor immune microenvironment with response to anti-pd-1 therapy. *Clin Cancer Res* 20: 5064–5074, 2014
- 18) Meng X, Huang Z, Teng F, Xing L, Yu J: Predictive biomarkers in pd-1/pd-l1 checkpoint blockade immunotherapy. *Cancer Treat Rev* 41: 868–876, 2015
- 19) Powles T, Eder JP, Fine GD, Braiteh FS, Loria Y, Cruz C, Bellmunt J, Burris HA, Petrylak DP, Teng SL, Shen X, Boyd Z, Hegde PS, Chen DS, Vogelzang NJ: Mpdl3280a (anti-pd-l1) treatment leads to clinical activity in metastatic bladder cancer. *Nature* 515: 558–562, 2014
- 20) Carbone L, Pilotto S, Milella M, Vaccaro V, Brunelli M, Calò A, Cuppone F, Sperduti I, Giannarelli D, Chilosì M, Bronte V, Scarpa A, Bria E, Tortora G: Differential activity of nivolumab, pembrolizumab and MPDL3280A according to the tumor expression of programmed death-ligand-1 (PD-L1): Sensitivity analysis of trials in melanoma, lung and genitourinary cancers. *PLoS One* 10: e0130142, 2015
- 21) Lesokhin AM, Ansell SM, Armand P, Scott EC, Halwani A, Gutierrez M, Millenson MM, Cohen AD, Schuster SJ, Lebovic D, Dhodapkar M, Avigan D, Chapuy B, Ligon AH, Freeman GJ, Rodig SJ, Cattray D, Zhu L, Grosso JF, Bradley Garelik MB, Shipp MA, Borrello I, Timmerman J: Nivolumab in patients with relapsed or refractory hematologic malignancy: preliminary results of a phase Ib study. *J Clin Oncol* 34: 2698–704, 2016
- 22) Furuse M, Kawabata S, Kuroiwa T, Miyatake S: Repeated treatments with bevacizumab for recurrent radiation necrosis in patients with malignant brain tumors: a report of 2 cases. *J Neurooncol* 102: 471–475, 2011
- 23) Furuse M, Nonoguchi N, Kawabata S, Yoritsune E, Takahashi M, Inomata T, Kuroiwa T, Miyatake S: Bevacizumab treatment for symptomatic radiation necrosis diagnosed by amino acid pet. *Jpn J Clin Oncol* 43: 337–341, 2013
- 24) Furuse M, Nonoguchi N, Kuroiwa T, Miyamoto S, Arakawa Y, Shinoda J, Miwa K, Iuchi T, Tsuboi K, Houkin K, Terasaka S, Tabei Y, Nakamura H, Nagane M, Sugiyama K, Terasaki M, Abe T, Narita Y, Saito N, Mukasa A, Ogasawara K, Beppu T, Kumabe T, Nariai T, Tsuyuguchi N, Nakatani E, Kurisu S, Nakagawa Y, Miyatake SI: A prospective, multicentre, single-arm clinical trial of bevacizumab for patients with surgically untreatable, symptomatic brain radiation necrosis. *Neuro Oncol Pract* 3: 272–280, 2016
- 25) Nieto K, Gordon LI, Raizer J: Bevacizumab for recurrent primary central nervous system lymphoma: A new treatment? *Neuro Oncol* 17: 1648–1649, 2015
- 26) Palucka K, Banchereau J: Cancer immunotherapy via dendritic cells. *Nat Rev Cancer* 12: 265–277, 2012

---

Address reprint requests to: Shin-Ichi Miyatake, MD, PhD, Department of Neurosurgery, Osaka Medical College, 2-7 Daigakumachi, Takatsuki, Osaka 569-8686, Japan.  
e-mail: neu070@osaka-med.ac.jp