



2020

Left Ventricular Aneurysmectomy in a Young Female of Unknown Etiology with Pseudoaneurysm: A Case Report

Follow this and additional works at: <https://www.j-saudi-heart.com/jsha>



Part of the [Cardiology Commons](#)



This work is licensed under a [Creative Commons Attribution-Noncommercial-No Derivative Works 4.0 License](#).

Recommended Citation

Ashraf, Tariq; Aziz, Rashid; Khuwaja, Amin M.; Afaque, Syed M.; and Karim, Musa (2020) "Left Ventricular Aneurysmectomy in a Young Female of Unknown Etiology with Pseudoaneurysm: A Case Report," *Journal of the Saudi Heart Association*: Vol. 32 : Iss. 1 , Article 20.

Available at: <https://doi.org/10.37616/2212-5043.1019>

This Case Report is brought to you for free and open access by Journal of the Saudi Heart Association. It has been accepted for inclusion in Journal of the Saudi Heart Association by an authorized editor of Journal of the Saudi Heart Association.

Left ventricular aneurysmectomy in a young female with pseudoaneurysm of unknown etiology

Tariq Ashraf*, Rashid Aziz, Amin Muhammad Khuwaja, Syed Muhammad Afaque, Musa Karim

National Institute of Cardiovascular Diseases (NICVD), Rafiqui (H.J.) Shaheed Road, Karachi 75510, Pakistan

Abstract

A left ventricular pseudoaneurysm is formed when there is free wall rupture of the myocardial wall with discontinuity and roof covered by pericardium mural thrombus or fibrous tissue without any myocardium. A left ventricular pseudoaneurysm is a rare and life-threatening event. We report a young 22-year-old female with unknown etiology of a pseudoaneurysm, who was previously managed as a psychiatric case and for musculoskeletal pain. On subsequent investigation and confirmation with cardiac magnetic resonance imaging, aneurysmectomy was done. This is a rare case in a young 22-year-old woman with a ventricular pseudoaneurysm of unknown etiology. Considering the high risk for rupture of a ventricular pseudoaneurysm, surgical resection was mandatory with no complications intra- and post-procedure.

Keywords: Aneurysmectomy, Case report, Etiology, Left ventricular, Pseudoaneurysm

1. Introduction

A left ventricular (LV) pseudoaneurysm is formed when there is free wall rupture of the myocardial wall with discontinuity and roof covered by pericardium mural thrombus or fibrous tissue without any myocardium [1]. An LV pseudoaneurysm is a rare and life-threatening event. LV aneurysms are potential arrhythmogenic substrates; although LV aneurysm repair and restoration of LV geometry significantly improves ventricular function and symptoms, recurrent malignant ventricular arrhythmia is common and has revealed a high rate of sudden cardiac death [2]. We report a young 22-year-old female with unknown etiology of a pseudoaneurysm, who was previously managed as a psychiatric case and for musculoskeletal pain. On subsequent investigation and confirmation with

cardiac magnetic resonance imaging (MRI), aneurysmectomy was done.

2. Case report

2.1. History of presentation and past medical history

A 22-year-old woman was referred from the northern area of Pakistan for evaluation of chest pain associated with palpitations that had been developing for the past 6–7 years. She was managed in the local hospital for depression, musculoskeletal chest pain, and dyspepsia. Physical examination revealed a heart rate of 110 beats/min, a regular rhythm, a blood pressure of 130/80 mmHg (normotensive), and 20 breaths/min. Pulmonary and abdominal examinations were unremarkable. Written informed consent was obtained from the patient.

Received 14 November 2019; revised 20 November 2019; accepted 20 November 2019.
Available online 17 April 2020

* Corresponding author at: National Institute of Cardiovascular Diseases (NICVD), Rafiqui (H.J.) Shaheed Road, Karachi 75510, Pakistan.
E-mail addresses: tariqash45@gmail.com (T. Ashraf), raziz@nicvd.org (R. Aziz), aminkhuwaja@yahoo.com (A.M. Khuwaja), smafaq101@gmail.com (S.M. Afaque), mkarim.nicvd@gmail.com (M. Karim).



2.2. Differential diagnosis and investigations

A battery of tests was performed to exclude infection, autoimmune disease, and atherosclerotic disease, with laboratory investigations, X-ray chest posteroanterior view, electrocardiogram, echocardiography, and cardiac MRI.

Laboratory investigation included serum anti-dsDNA (IgG), serum C3, C4, antinuclear antibody, antimitochondrial antibodies, serum ENA profile (RNP-antibodies, 5-A/Ro antibodies, B/La antibodies, r1-antibodies, SCI-70 antibodies), and serum creatine phosphokinase were normal.

On cardiovascular examination, pulsatile precordium at the anterior axillary line with a systolic murmur of 2/6 localized at the apex were observed. A 12 lead electrocardiogram showed a regular sinus rhythm with ST-T changes in lead I, augmented Vector Left (aVL), and V4 to V6. A chest X-ray showed cardiomegaly. Echocardiography showed a normal sized left ventricle, with mild systolic dysfunction (ejection fraction 45–50%) (Fig. 1A) and an apical aneurysm.

Coronary angiography was normal (Fig. 2A–2D). To differentiate between a true

aneurysm and a pseudoaneurysm, cardiac MRI (Fig. 3) was performed. This showed a large pseudoaneurysm at the LV apex with a large thrombus in the pseudoaneurysm the size of the neck of which was 8.8 mm. A normal sized left ventricle with normal function (ejection fraction 55%) was observed, and there was no evidence of myocardial infarction.

2.3. Management

Surgery was done as left ventricle aneurysmectomy and LV reconstruction (Dor procedure) with radio-frequency ablation of the LV cavity. Operative findings were a LV apical aneurysm, hard and calcified with a large organized clot with calcification. There was a narrow neck and hard shell around the aneurysmal cavity (Fig. 3A–E). The pathological specimen of the aneurysm is shown in Fig. 3F. Histopathology biopsy of the cardiac ventricular specimen revealed a blood clot with fibrin, lymphocytes, and neutrophils. No formed tissue was identified. The tissue studied showed extensive necrosis, hyalinization, calcification, and foci of ossification indicating a cardiac ventricular pseudoaneurysm.

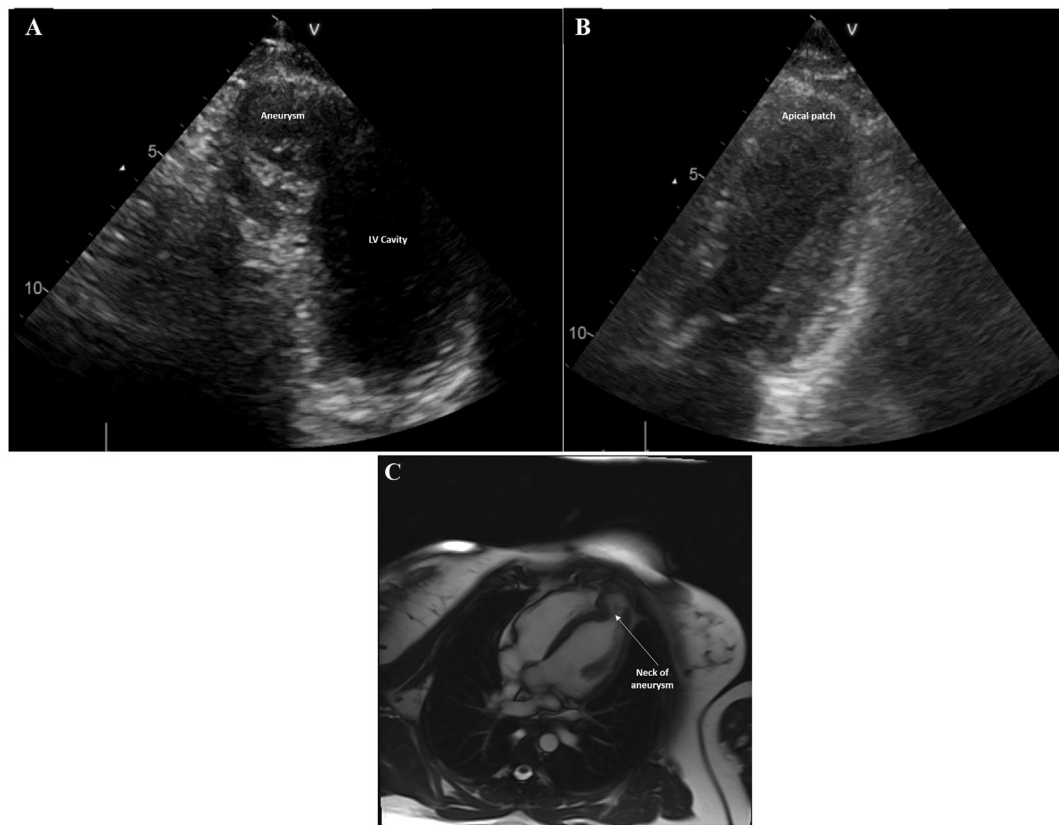


Fig. 1. (A) Preprocedure echocardiography showing ventricular apical pseudoaneurysm; (B) postprocedure echocardiography after surgical resection of pseudoaneurysm; and (C) preprocedure cardiac magnetic resonance imaging (MRI) scan showing left ventricular (LV) apical aneurysm.

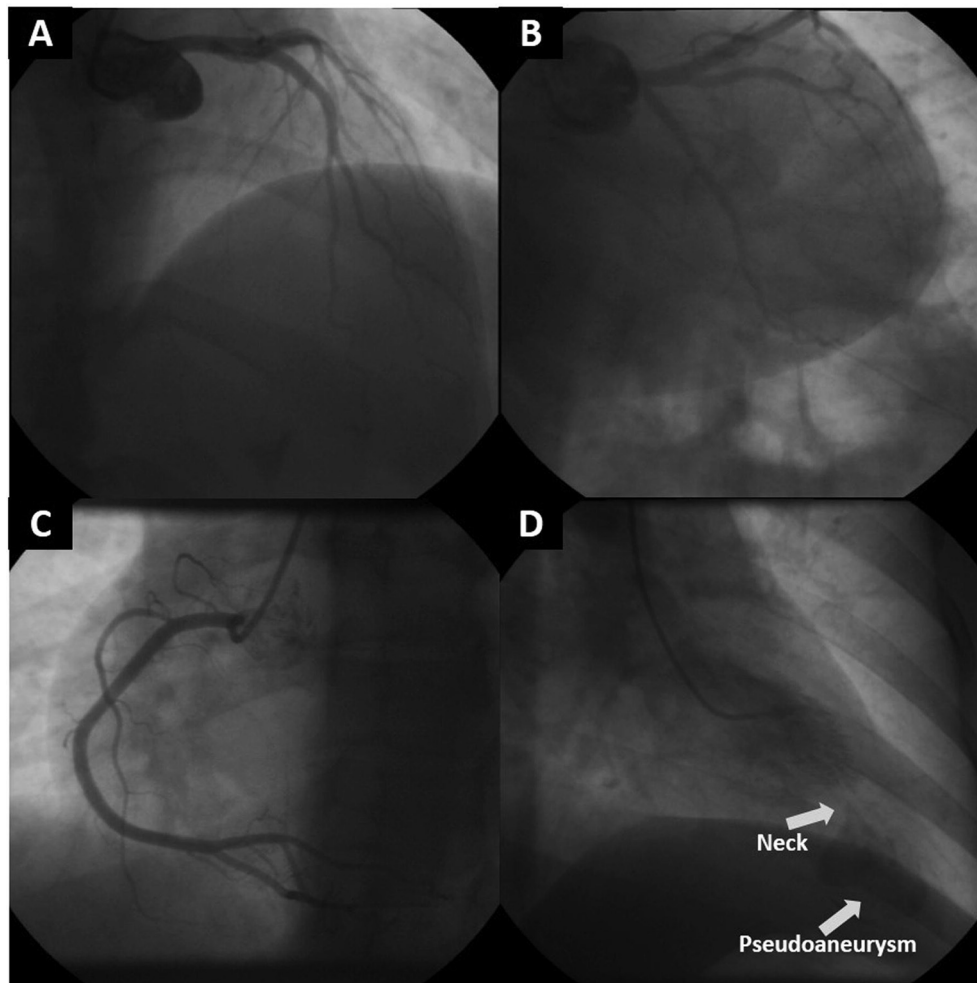


Fig. 2. (A–C) Images of normal coronary angiogram and (D) left ventriculogram showing neck and aneurysmal sack.

2.4. Outcome and follow-up

The patient was out of bed on postoperative Day 2. Drugs given postoperatively were beta blockers, aspirin, and antibiotics. Postoperative echocardiography showed normal LV size, cavity, and function (Fig. 1B). Holter monitoring was performed which indicated episodes of couplets and quadruplets of premature ventricular contraction of no significance.

The patient was discharged on postoperative Day 5. On follow-up after 1 month, 3 months, and 9 months, the patient was in functional Class I without any complication.

3. Discussion

A similar case report of an LV pseudoaneurysm of unknown etiology was presented by di Summa et al [3]. The patient was a 29-year-old woman compared with our patient who was 22 years old, with a similar

presentation of palpitations, chest pain, and dyspnea. The duration of history in our patient was 6–7 years compared with the case report which was 3 months. In the case of di Summa et al [3], the pseudoaneurysm ruptured after a duration of 3 months, while in our case of 6–7 years of prolonged illness, no complication occurred, probably because of heavy degeneration and fibrous tissue formation, followed by calcification.

LV aneurysms are either true aneurysms or pseudoaneurysms [4], with three pathology as dyskinetic and a thinned myocardium for true and rupture of free wall myocardium with overlying pericardium as pseudoaneurysm [5]. There are multiple etiologies of pseudoaneurysms that include myocardial infarction, cardiac surgery, infective endocarditis, chest trauma, tuberculosis, rheumatoid arthritis, Kawasaki's disease, and Behcet's syndrome [6].

The etiology of the pseudoaneurysm in our case was unknown. Isolating the transitional zone

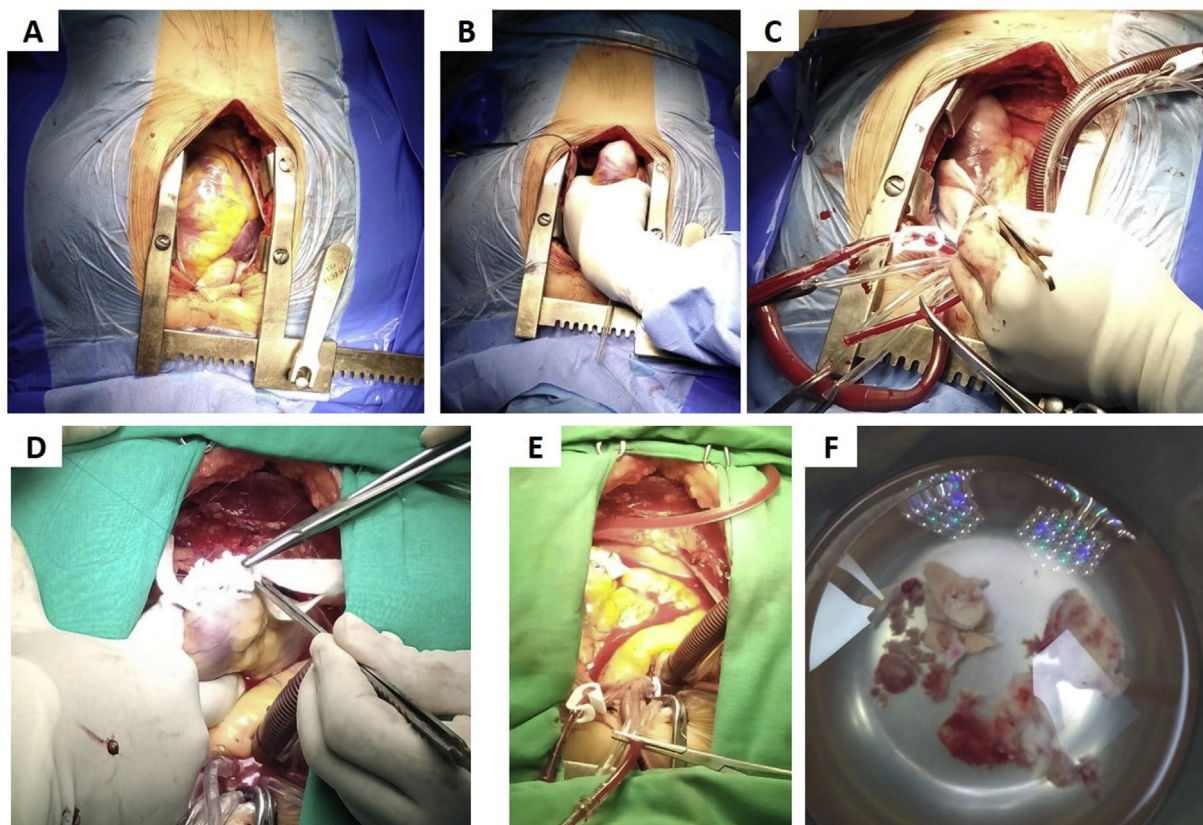


Fig. 3. Ventricular aneurysmectomy and repair: (A) median sternotomy and vertical pericardiectomy; (B) calcified left ventricular (LV) apical aneurysm; (C) standard cardiopulmonary bypass; (D, E) circular patch repair of apical ventriculectomy; and (F) surgical specimen of the aneurysm.

between aneurysmal tissue and the rest of the myocardium using monopolar radiofrequency ablation significantly reduces the occurrence of ventricular arrhythmia [7,8]. In addition to circumferential ablation and isolation of the aneurysmal cavity from the myocardium, isolating the margins of aneurysmectomy further reduces the number of potential arrhythmogenic foci.

Although a pseudoaneurysm has the complication of a life-threatening rupture and sudden death, the formation of a calcific shell in the aneurysm prevented the egg from bursting, in spite of increased intraventricular pressure.

This is a rare case of a young 22-year-old woman in whom the mechanism and etiology of a ventricular pseudoaneurysm formation could not be found. Considering the high risk of rupture of a ventricular pseudoaneurysm, surgical resection was mandatory, with no complications intraoperative or postoperative.

Conflict of interest

The authors declare no conflict of interest.

References

- [1] Bisoyi S, Dash AK, Nayak D, Sahoo S, Mohapatra R. Left ventricular pseudoaneurysm versus aneurysm a diagnosis dilemma. *Ann Card Anaesth* 2016;19:169.
- [2] Bechtel JM, Tölg R, Graf B, Richardt G, Noetzold A, Kraatz EG, et al. High incidence of sudden death late after anterior LV-aneurysm repair. *Eur J Cardiothorac Surg* 2004;25:807–11.
- [3] di Summa M, Iezzi F, Oburu G, Mehta N. Huge left ventricular pseudoaneurysm rupture in an African young adult patient. *Interact Cardiovasc Thorac Surg* 2014;19:160–1.
- [4] Frances C, Romero A, Grady D. Left ventricular pseudoaneurysm. *J Am Coll Cardiol* 1998;32:557–61.
- [5] Brown SL, Gropler RJ, Harris KM. Distinguishing left ventricular aneurysm from pseudoaneurysm: a review of the literature. *Chest* 1997;111:1403–9.
- [6] Mackenzie JW, Lemole GM. Pseudoaneurysm of the left ventricle. *Tex Heart Inst J* 1994;21:296.
- [7] Aliot EM, Stevenson WG, Almendral-Garrote JM, Bogun F, Calkins CH, Delacretaz E, et al. EHRA/HRS expert consensus on catheter ablation of ventricular arrhythmias: developed in a partnership with the European Heart Rhythm Association (EHRA), a registered branch of the European Society of Cardiology (ESC), and the Heart Rhythm Society (HRS); in collaboration with the American College of Cardiology (ACC) and the American Heart Association (AHA). *Europace* 2009;11:771–817.
- [8] Fernández-Armenta J, Penela D, Acosta J, Andreu D, Evertz R, Cabrera M, et al. Substrate modification or ventricular tachycardia induction, mapping, and ablation as the first step? A randomized study. *Heart Rhythm* 2016;13:1589–95.