

Three cases of neurosyphilis diagnosed in the 21st century: A case report

RAMONA ANDREEA CODREANU BALABAN¹, ANY AXELERAD^{1,2},
DANIELA MUSAT¹, ANABELLA CRISTIANA CIOABLA^{1,2}, ALINA ZORINA STUPARU^{1,2},
SILVIU DOCU AXELERAD³ and LAVINIA FLORENTA MUJA^{1,2}

¹Department of Neurology, 'Sf. Ap Andrei' Emergency County Clinical Hospital, 900591 Constanta;

²Department of Neurology, General Medicine Faculty, 'Ovidius' University, 900470 Constanta;

³Faculty of General Medicine, 'Vasile Goldis' University, 317046 Arad, Romania

Received September 29, 2022; Accepted February 20, 2023

DOI: 10.3892/etm.2023.11900

Abstract. In the last decades, it has been considered that syphilis and its complications, including neurological damage, are able to be kept under control with proper epidemiological management. However, socio-economic changes and the problem of antibiotic resistance have brought it back into the focus of clinicians. The present study reports on the cases of three male patients of different ages (28, 76 and 51 years) from different social backgrounds and occupations were provided (first patient, nurse; second patient, pensioner; third patient, navigator); they were confirmed to have neurosyphilis, clinically, paraclinically and by imaging. The complications that may occur in the evolution of the disease but also the beneficial effects of targeted, antisiphilic and symptomatic therapy were outlined. The purpose of the present study was to highlight issues of major importance regarding neurosyphilis, particularly for neurologists, for whom diagnosis may be challenging. It is key for the neurologist to understand the clinical manifestations and limitations of current diagnostic tests. It is important to consider that a positive rapid plasma reagin test result without confirmation of the presence of *Treponema pallidum* antibodies in the cerebrospinal fluid may represent a false-positive screening test.

Introduction

Syphilis is a sexually transmitted disease whose pathogen is *Treponema pallidum*, a gram-negative spirochete. The gateway is the tegument or mucous membranes at the level of minimal lesions (1). From a pathophysiological point of view,

the main process triggered by *Treponema pallidum* infection is an obliteration of terminal arterioles, with inflammatory changes and necrosis. In the central nervous system, infection causes chronic inflammation of the meninges and blood arteries, which over time may be complicated by parenchymal lesions (1).

Early invasion (not necessarily 'involvement') of the central nervous system, is thought to occur in numerous (if not most) patients infected with syphilis. Thus, it is not surprising that neurological manifestations of syphilis may occur at any stage of infection (2). While neurosyphilis itself is a complication of syphilis, untreated neurosyphilis may lead to devastating neurological sequelae, including permanent paralysis, dementia and death. Treatment should be initiated immediately, and certain complications may be reversible. The success of therapy has an inverse relationship with the duration of untreated infection (3). As there is no single highly sensitive and specific diagnostic test, it is based on clinical manifestations and cerebrospinal fluid (CSF) abnormalities (4).

The present article reviews the clinical manifestations, diagnostic process and first-line treatment of neurosyphilis, with a focus on the neurological symptoms, important to the clinician.

Case reports

Case 1. The first case was a 28-year-old male, with no personal pathological history, who presented at the Neurology Clinic of 'Sf. Ap Andrei' Emergency County Clinical Hospital (Constanta, Romania) in July 2022 due to Jacksonian epileptic episodes in the left arm, which had begun ~2 weeks previously, and the patient was under a treatment recommended by the neurologist with Levetiracetam (500 mg every 12 h). The patient was hospitalized at the Neurology Department of the Emergency Clinical Hospital (Constanta, Romania) for 5 days.

At the time of admission, an objective neurological examination revealed Jacksonian epileptic seizures in the left upper limb without any other neurological symptoms. A native brain MRI and magnetic resonance angiography with venous time were performed (which indicated a cortical, parietal, well-defined lesion that had not absorbed the gadolinium-based

Correspondence to: Dr Any Axelerad, Department of Neurology, 'Sf. Ap Andrei' Emergency County Clinical Hospital, 145 Tomis Bd, 900591 Constanta, Romania
E-mail: docuaxi@yahoo.com

Key words: neurosyphilis, *Treponema pallidum* antibodies, rapid plasma reagin, cerebrospinal fluid, prognosis, dementia

contrast substance; (Fig. 1) and an electroencephalogram was performed (which indicated a microvoltage pathway of 11.5 c/sec, modulated in spindles, without graphs suggestive of a lesional pathway). The blood test results are provided in Table I; the presence of *Treponema pallidum* antibodies in serum and cerebrospinal fluid was evident at high levels.

Following the investigations, without having a precise diagnosis, two days after admission, the neurologist decided to perform serological tests [Rapid Plasma Reagin (RPR), quantitative *Treponema pallidum* antibodies (3) and PCR HIV tests 1+2].

The results revealed positive RPR (1:34) and anti-*Treponema pallidum* antibody levels above the normal limit, which helped to differentiate between syphilis infection and a false-positive screening test. Considering previous information lumbar puncture was performed and the CSF was macroscopically opalescent, slightly hemorrhagic. In the complete CSF examination, the level of *Treponema pallidum* antibodies was 1/128, and in the serum, the value of *Treponema pallidum* antibodies was 1/2,560 units. The presence of *Treponema pallidum* antibodies in serum and CSF was evident at high levels; the values of specific or major parameters for the diagnosis of neurosyphilis, which were analyzed from CSF and serum, are listed in Table II.

On admission, the differential diagnosis included tests to exclude vitamin B12 deficiency, hypothyroidism or hyperthyroidism, and a test to identify mutations associated with cardiovascular disease-thrombophilia. As presented in Table II, the values for both vitamin B12 and thyroid tests were within normal limits.

The genetic test for thrombophilia identified the following genotypes: Heterozygous for the G1691A (Leiden) mutation of factor V and homozygous for the A1298C mutation of methylenetetrahydrofolate reductase (5). Based on the investigations performed and the results received during hospitalization, the diagnosis of neurosyphilis was confirmed.

From the patient's detailed history acquired by interview, the following information was obtained: Unmarried patient, currently living alone, affirmative with permanent protected sexual contact since the beginning of sexual activity, currently working as a nurse. At the dermatovenerological consultation, the doctor recommended treatment with Penicillin G crystalline 4,000,000 IU for 4 h for 14 days, followed by Benzathine Penicillin 240,000 IU intramuscularly in 3 doses at 5-day intervals.

During hospitalization, no improvement in the Jacksonian episodes was observed, and accordingly, antiepileptic medication was increased from 500 mg every 12 h to 1,000 mg every 12 h/day. Following the change in dose, the Jacksonian episodes completely disappeared. At five days after admission, the patient was released from the neurology clinic with a recommendation to continue antiepileptic treatment. The patient was followed in the private system by the attending doctor.

Case 2. The second case was a 76-year-old male patient, known to have arterial hypertension grade II with a high risk, who was admitted to the Neurology Department of the Emergency Clinical Hospital (Constanta, Romania) due to generalized tonic-clonic episodes, accompanied by urinary

sphincter relaxation and lingual traumatic mark, occurring at home during the day of presentation. The patient was admitted to 'Sf. Ap Andrei' Emergency County Clinical Hospital (Constanta, Romania) in February 2020 and was released after 25 days of hospitalization.

On admission, the neurological examination revealed that the patient was conscious, psychomotor agitated and had difficulty mobilizing the right limbs on paresis tests. The native brain computed tomography (CT) indicated a subacute ischemic lesion in the left middle cerebral artery territory, supratentorial sequelae and leukoaraiosis. Biological analysis blood tests indicated that hyperglycemia and inflammatory syndrome were present.

At two days after admission, the patient underwent brain MRI, which suggested progressive multifocal leukoencephalopathy (Fig. 2A and B) and inflammatory mastoid cell changes.

On day 3 after admission, the neurologist decided to perform RPR and HIV 1+2 serum testing, which revealed an intensely positive serum RPR test (Table III) and negativity for HIV 1+2.

After seven days following lumbar puncture, macroscopically, the CSF was transparent and clear and the presence of *Treponema pallidum* antibodies was identified (1/160), as well as slight glycochoria, slightly increased proteinuria and a positive RPR test.

Considering the above results, a dermatovenerological consultation was performed and the doctor initiated treatment with Penicillin G crystalline 4,000,000 IU at 4 h, for 14 days, followed by Benzathine Penicillin 240,000 IU intramuscularly in 3 doses at a 5-day interval.

As the patient's cognitive status was unsatisfactory during hospitalization, a psychological consultation was performed and the clinical psychologist performed the Mini-Mental State Examination (MMSE) (6), which had a score of 11 points and classified the patient in a stage of severe cognitive deterioration.

At 20 days after admission and after 14 days of treatment, the evolution was favorable, without the appearance of other acute events or tonic-clonic episodes. The dermatovenerologist advised the continuation of the intramuscular Benzathine Penicillin 240,000 IU, 3 doses at 5-day intervals.

An electroencephalogram was performed, which indicated a pathway of 67 c/sec in both the anterior and posterior derivatives. Temporal flattened pathway (lesional), Theta band pathway (lesional), slow alpha and no epileptiform elements were observed during recording. On the day of release, the patient had neurologically improved, was cooperative and temporo-spatially disoriented, without neck roll and without motor deficits. The patient was followed in the private system by the attending doctor.

Case 3. The third patient was a 51-year-old male, navigator, known to have recurrent transient aphasic episodes who presented to the 'Sf. Ap Andrei' Emergency County Clinical Hospital (Constanta, Romania) in April 2013 for sudden established speech difficulty without other signs of neurological impairment at the time of admission. After a native and contrast CT scan (the result of which was within age limits), an electroencephalogram (without epileptiform graphoelements)

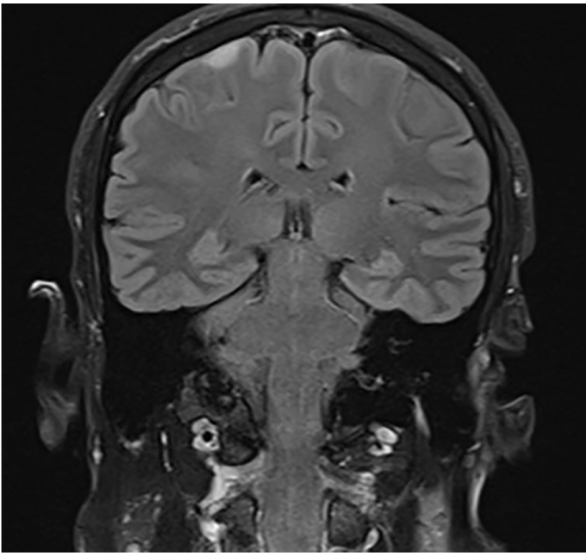


Figure 1. Brain MRI native axial fluid-attenuated inversion recovery on the second day of hospitalization of case no. 1 (male; age, 28 years) displayed a well-defined, hyperintense cortical and parietal lesion.

and cerebrovascular treatment, the speech disorder improved and the patient was discharged with recommendations of medication with antiplatelet (100 mg, 1 cp/day), anticonvulsant (200 mg, 1 cp/day) and antihypertensive (10 mg, 1 cp/day) drugs. The patient was admitted to 'Sf. Ap Andrei' Emergency County Clinical Hospital from Constanta, Romania on 19-04-2014 and discharged on 05-05-2014.

At six months after the initial presentation, the patient returned to the hospital due to left leg motor weakness. Neurological objective examination indicated that the patient was conscious, uncooperative, head and eyeballs deviated to the right and the patient exhibited left central facial paresis, left hemiplegia (left upper limb: 0/5; left lower limb, 0/5) and bilateral indifferent plantar cutaneous reflex; these symptoms completely remitted 24 h after admission. At the time of admission, a CT scan excluded acute diseases or sequelae. From a biological perspective, since the hemolucogram indicated significant leukocytosis, antibiotic therapy with Cephalosporin III, 1 g every 12 h for 7 days, was initiated.

During admission, examination of the neurological condition revealed tetraataxia, intermediate poorly reactive pupils and mild anisocoria more in the right eye than in the left. As the neurologist did not have a definite diagnosis after the investigations, the patient was serologically tested for HIV 1+2, hepatitis B surface antigen and anti-HCV, all with negative results, and syphilis (RPR positive). Later, a lumbar puncture was performed, and the following was detected: Clear, colorless fluid, increased proteinuria (950 mg/l); 52 elements/mmc (96% mononucleated, 4% polymorphonucleated) and positive CSF (RPR ++++).

A dermatovenerological consultation followed, based on which treatment with crystalline Penicillin G was initiated at 4,000,000 IU/4 h, for 14 days, followed by Benzathine Penicillin 240,000 IU intramuscular, 3 doses at 5-day intervals. At 16 days after admission, the patient was released. At the time of neurological re-examination, the clinical status had improved. Therapeutic management at discharge included

anticonvulsant drugs (200 mg; 1/2 cp in the morning, 1/2 cp at lunch and 1 cp in the evening), with the recommendation to prohibit the consumption of alcohol, coffee and cola, working at height and driving.

In the same year, six months after being diagnosed with neurosyphilis, the patient presented at the hospital with mild cognitive impairment. The clinical neurological examination revealed the following: Mild anisocoria (right eye > left eye), negative paresis tests, positive non-systematized Romberg, globally exacerbated osteotendinous reflexes, except for the Achilles reflexes, which were diminished bilaterally, bilateral flexion plantar cubitus reflex, mild dysmetria on the bilateral knee flexion test and painful distal tactile hypoesthesia.

The MMSE was also performed with a result of 22 points, representing mild cognitive impairment, which was the reason for the addition of Pramiracetam (600 mg, 1 cp every 12 h) to the treatment. In April 2016, May 2017 and May 2020, tests for RPR and *Treponema pallidum* antibodies were repeated, both with positive results. In Table IV, the evolution of the two infection indicators over the years is presented. The condition affected the patient's ability to continue performing his job and in 2018 he retired.

At the last neurological evaluation, in July 2021, the patient's general condition was unchanged from the previous examination, with no changes in the biological parameters examined. The recommended treatment was valproic acid 500 mg per day in a single dose, carbamazepine 200 mg per day in a single dose, to which lorazepam 1 mg and 1 cp per day was added, as the patient had experienced periods of anxiety, which started six years previously but had progressed recently prior to the presentation at the hospital. The patient was followed up in the private system by the attending doctor.

Discussion

As the clinical diagnosis of neurosyphilis remains far from optimal, the current study presented cases of patients diagnosed with neurosyphilis and briefly summarized the neurological manifestations that may occur during the course of the disease, which may help to diagnose the condition more rapidly. Neurosyphilis is one of the most complex manifestations to diagnose in patients without a known history of syphilis infection, due to its broad possible presentations. The most common manifestations of neurosyphilis include tabes dorsalis, generalized paralysis and meningo-vascular neurosyphilis (7,8).

Tabes dorsalis occurs 20-30 years after infection and consists of demyelination of the posterior medullary cords and posterior spinal nerve roots (1). Generalized paralysis (paralytic dementia) occurs 20-30 years after infection and consists of a chronic progressive meningo-encephalitis leading to the destruction of the cerebral cortex in the frontal and temporal lobes (1). Meningo-vascular syphilis usually occurs 5-12 years after infection and predominantly manifests as microangiopathy, with fibroblastic proliferation of the intima, thinning of the media and lymphocytic infiltration, with narrowing or obliteration of the vascular lumen. It manifests as ischemic strokes in the territory of the middle cerebral artery or branches of the basilar trunk (1).

Table I. Biological data of case no. 1 determined in July 2022.

Parameter	Value
RPR (NV: Negative)	1.34
<i>Treponema pallidum</i> antibody in CSF (NV: Negative)	1/128
<i>Treponema pallidum</i> antibody in serum (NV: Negative)	1/2560
<i>Treponema pallidum</i> antibody IgG in serum (NV: 2.5 units)	11.3
<i>Treponema pallidum</i> antibody IgG in CSF (NV: <40 units)	42.4
Q IgG (NV: <3 units)	4.4

NV, normal value; CSF, cerebrospinal fluid; RPR, rapid plasma reagin.

Table II. Biological data of case no. 1 determined in July 2022.

Parameter	Value
B12 vitamin, pg/ml (NV: 197-771)	282
Thyroid-stimulating hormone, μ UI/ml (NV: 0.27-4.2)	0.693
Free thyroxine, ng/dl (NV: 12-22)	13.2

NV, normal value.

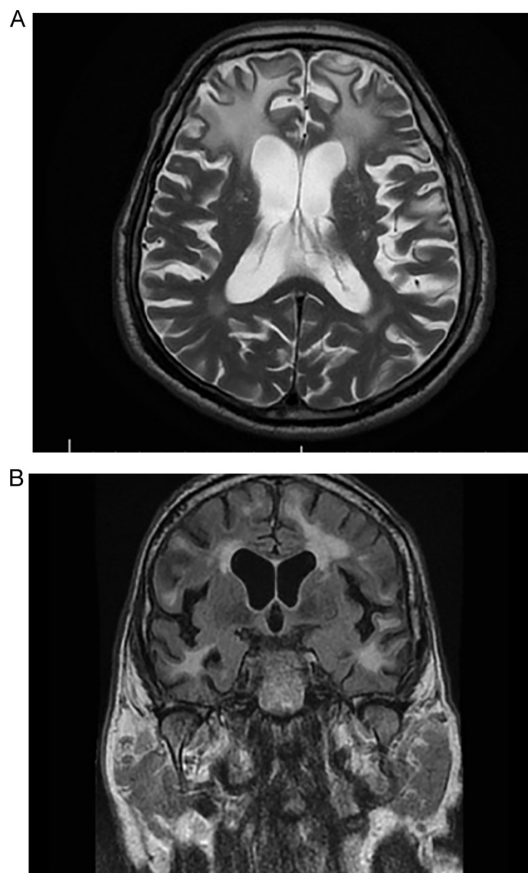


Figure 2. (A) Brain MRI on the second day of hospitalization of case no. 2 (male; age, 76 years) revealed native axial T2 hyperintense plaques without diffusion restriction and bilateral distribution in subcortical frontal and temporal white matter. (B) Brain MRI on the second day of hospitalization of case no. 2 revealed native axial fluid-attenuated inversion recovery hyperintense plaques without diffusion restriction and bilateral distribution in subcortical frontal and temporal white matter.

The topic of neurosyphilis, particularly in the geriatric population, has been widely neglected in the literature in recent years. This is also due to the widespread use of antibiotics, which may ultimately prevent the occurrence of syphilis (9). The first-line treatment has been Penicillin G since 1943, which is when it was first used to treat syphilis, and it is the only recommended antibacterial drug for neurosyphilis (10).

The first case described in the present study was a 28-year-old male patient. Neurological manifestations were limited to Jacksonian epileptic episodes, with sudden onset, without any other subjective complaint. Based on the clinical manifestations, for this particular case, it was recommended to perform both native brain MRI and brain MR angiography with venous time. Based on this, the diagnosis of superior sagittal sinus thrombosis was considered. As the patient's condition changed during treatment with antibiotics and levetiracetam for seizures, the patient's prognosis is good. The neurologist recommended clinical and serological monitoring at 3, 6, 9, 12, 18 and 24 months after treatment.

The second case presented was that of a 76-year-old male with a clinical neurological condition, including severe cognitive impairment, which had evolved rapidly at the time of discharge from the Neurology Department of the Clinical Hospital (Constanta, Romania), with a score of 11 points on the MMSE. Over time, one of the complications that patients with neurosyphilis may develop are psychiatric manifestations represented by manic episodes, depression or psychosis, in addition to the appearance or worsening of memory and judgment deficits, evolving towards severe dementia (3,6). Cases of syphilitic dementia are still reported in modern times.

The prognosis of the case remains uncertain because, considering the advanced cognitive impairment but also the conditions associated with neurosyphilis (type II diabetes mellitus newly discovered and under treatment with oral anti-diabetics, hypertension, superficial thrombophlebitis in the internal saphenous vein of the right leg), it is associated with a risk of developing significant complications that may lead to death. The third case of the present study was a 51-year-old patient whose diagnosis was challenging due to the non-specific clinical signs. From the first months after diagnosis, cognitive decline started to increase. In 2014, the cognitive impairment was mild (with an MMSE score of 22 points) and in 2016, two years after diagnosis, the cognitive impairment had progressed slightly, with an MMSE score of 19 points.

Table III. Biological data of case no. 2, determined in February 2020.

Parameter	Value
RPR (NV: Negative)	1:1 (+++/++++), 1:2 (+++), 1/4 (++)
<i>Treponema pallidum</i> antibody in CSF (NV: Negative)	1/160
HIV(1+2) (NV: Negative)	Negative

NV, normal value; CSF, cerebrospinal fluid.

Table IV. Biological data of case no. 3.

Parameter (NV)	April 2016	May 2017	May 2020
RPR (NV: Negative)	1:1(++++); 1:2(+++); 1:4(++); 1:8(+); 1:16(+/-)	1:1(++); 1:2(++); 1:4(+); 1:8(+/-)	1:1(++); 1:2(+); 1:4(+/-)
<i>Treponema pallidum</i> antibody in serum (NV: Negative)	1:80(++++); 1:160(+++); 1:320(++)	1:80(++++); 1:160(++++); 1:320(++++)	1:80(++++); 1:160(++++); 1:320(++++)

NV, normal value; RPR, Rapid Plasma Reagin.

All of the patients of the current study received standard treatment with antibiotics from the penicillin class. Neurosyphilis should be part of the differential diagnosis of every patient with impaired cognition and behavioral disorders. Neuropsychological assessments and CSF examinations are useful tools for measuring cognitive decline and response to treatment during follow-up (11). Regarding the third clinical case presented, who exhibited mild deterioration of cognition, considering the evolution of the patient from diagnosis to present, the prognosis is favorable, and the patient is in therapy (11).

An Estonian study by Liis *et al* (12) described the diagnosis of neurosyphilis. Given that syphilis is easy to diagnose and treat at this time, it should be considered and tested in patients with cognitive and movement disorders. A 42-year-old male presented to the Neurology clinic due to cognitive decline that had occurred ~1 year prior to presentation, hallucinations (rare), periods of confusion (transient), gait disturbances and involuntary movements. Focal slowing and epileptiform discharge in the right frontotemporal regions were described electroencephalographically (10). HIV 1 and 2 antibodies were negative, but the RPR test as well as the *T. pallidum* hemagglutination assay (TPHA) were positive in serum (RPR, 1:32; TPHA, 1:520) as well as in CSF (RPR, 1:8; TPHA, 1:640). Based on clinical imaging and laboratory data, neurosyphilis was diagnosed and penicillin treatment was initiated. At follow-up, 6 months later, the patient had mild dementia (MMSE, 25/30), but the myoclonus and extrapyramidal symptoms had disappeared. Both the RPR (1:2) and TPHA markers in the serum and CSF that were mentioned above had turned negative.

What makes the case reported by Liis *et al* (12) and the cases presented above similar is the cognitive impairment. In the case of the 76-year-old patient of the present study, cognitive decline was clearly progressive during hospitalization, with an MMSE score of 11 points at discharge. For the third patient, a 51-year-old male, the impairment was not as evident

at the time of the first admission to the neurology department, but later, 6 months after the diagnosis of neurosyphilis, it was possible to observe minimal cognitive decline, with slight progression in the following years.

In conclusion, neurosyphilis may occur at any time in the course of syphilis (13). The diagnosis is based on clinical manifestations but particularly on the paraclinical investigations that may be performed, including imaging and analysis of cerebrospinal fluid. Nowadays, it is important to remember that syphilis, and particularly neurosyphilis, in its early stages may be overlooked and left untreated; it may lead to changes in the neurological status of patients that are irreversible and have an unfavorable therapeutic response. As showcased by the three clinical cases, diagnosed at different time-points (case 1 in 2022, case 2 in 2020 and case 3 in 2014) and with non-specific clinical presentation, Penicillin G at high doses remains the first choice of therapy, to which symptomatic medication may be added.

Acknowledgements

Not applicable.

Funding

No funding was received.

Availability of data and materials

The datasets used and/or analyzed during the current study are available from the corresponding author on reasonable request.

Authors' contributions

AA, RACB and LFM conceived and designed the study. AZS performed the literature research. AA, RACB, LFM, AZS,

DM, ACC and SDA were involved in the interpretation of the results and in the writing of the manuscript. AA, RACB, AZS and LFM checked and confirm the authenticity of the raw data. All authors have read and approved the final manuscript.

Ethics approval and consent to participate

The current study was approved by the Ethics Committee of the Constanta Clinical Hospital (Constanta, Romania; approval no. 21/26.09.2022).

Patient consent for publication

All of the patients provided written informed consent for publication of their data and images.

Competing interests

The authors declare that they have no competing interests.

References

- Liao H, Zhang Y and Yue W: Case report: A case report of neurosyphilis mimicking limbic encephalitis. *Front Neurol* 13: 862175, 2022.
- US Department of Health Human Services and Centers for Disease Cont And Prevention: Sexually transmitted disease surveillance 2012. Createspace Independent Publishing Platform, North Charleston, SC, 2014.
- Ropper AH: Neurosyphilis. *N Engl J Med* 381: 1358-1363, 2019.
- Berger JR and Dean D: Neurosyphilis. *Handb Clin Neurol* 121: 1461-1472, 2014.
- Favaloro EJ: Genetic testing for thrombophilia-related genes: Observations of testing patterns for factor V Leiden (G1691A) and prothrombin gene 'mutation' (G20210A). *Semin Thromb Hemost* 45: 730-742, 2019.
- Trivedi D: Cochrane review summary: Mini-mental state examination (MMSE) for the detection of dementia in clinically unevaluated people aged 65 and over in community and primary care populations. *Prim Health Care Res Dev* 18: 527-528, 2017.
- Read PJ and Donovan B: Clinical aspects of adult syphilis. *Intern Med J* 42: 614-620, 2012.
- Shi M, Peng RR, Gao Z, Zhang S, Lu H, Guan Z, Gao Y, Wang C and Zhou P: Risk profiles of neurosyphilis in HIV-negative patients with primary, secondary and latent syphilis: Implications for clinical intervention. *J Eur Acad Dermatol Venereol* 30: 659-666, 2016.
- Zheng D, Zhou D, Zhao Z, Liu Z, Xiao S, Xing Y, Suo WZ and Liu J: The clinical presentation and imaging manifestation of psychosis and dementia in general paresis: A retrospective study of 116 cases. *J Neuropsychiatry Clin Neurosci* 23: 300-307, 2011.
- Buitrago-Garcia D, Marti-Carvajal AJ, Jimenez A, Conterno LO and Pardo R: Antibiotic therapy for adults with neurosyphilis. *Cochrane Libr* 5: CD011399, 2019.
- Mehrabian S, Raycheva MR, Petrova EP, Tsankov NK and Traykov LD: Neurosyphilis presenting with dementia, chronic chorioretinitis and adverse reactions to treatment: A case report. *Cases J* 2: 8334, 2009.
- Liis S, Mark B and Pille T: Neurosyphilis as a great imitator: A case report. *BMC Res Notes* 9: 372, 2016.
- Tiecco G, Degli Antoni M, Storti S, Marchese V, Focà E, Torti C, Castelli F and Quiros-Roldan E: A 2021 update on syphilis: Taking stock from pathogenesis to vaccines. *Pathogens* 10: 1364, 2021.



This work is licensed under a Creative Commons Attribution-NonCommercial-NoDerivatives 4.0 International (CC BY-NC-ND 4.0) License.