

Catheter-directed thrombolysis for *in situ* pulmonary artery thrombosis in children

Evyatar Hubara¹, Sharon Borik², Gili Kenet³, David Mishaly², Amir Vardi¹

¹Department of Pediatric Cardiac Critical Care Medicine, Sheba Medical Center, The Edmond and Lily Safra Children's Hospital, Tel Hashomer, Israel, ²The Edmond J. Safra International Congenital Heart Center, Sheba Medical Center, Tel Hashomer, Israel, ³The Israeli National Hemophilia Center and Thrombosis Unit with The Amalia Biron Research Institute of Thrombosis and Hemostasis, Sheba Medical Center, Tel Hashomer, Israel

ABSTRACT

In situ pulmonary artery thrombosis (ISPAT) is a unique form of pulmonary embolism characterized by local formation of thrombus in the pulmonary arteries. We present here a baby with hypoplastic left heart syndrome who developed ISPAT after Glenn surgery. The patient underwent catheter-directed thrombolysis, followed by systemic anticoagulation with excellent results.

Keywords: Cardiac surgery, catheter-directed thrombolysis, *in situ* pulmonary artery thrombosis, pulmonary embolism

INTRODUCTION

Even though considered rare in children, pulmonary embolus (PE) is increasingly recognized as a unique illness in terms of pathophysiology, presenting symptoms and treatment strategies.^[1,2] There are two different patterns of PE in children: classic thromboembolic PE (TE-PE) and *in situ* pulmonary artery thrombosis (ISPAT). While TE-PE has similar characteristics as adults, ISPAT has distinctive features including younger age at presentation and a local formation of thrombus in pulmonary arteries. ISPAT is not necessarily related to deep vein thrombosis (DVT) but rather a consequence of heart surgery, pulmonary artery anomalies, or lung transplantation.^[3] Catheter-directed thrombolysis (CDT) includes a placement of a catheter under radiologic imaging directly into the thrombus and delivering a thrombolytic agent. We describe the use of CDT for thrombus removal in a child with hypoplastic left heart syndrome (HLHS) who developed ISPAT after Glenn surgery.

CASE REPORT

An 8-month-old full-term baby boy with HLHS was electively admitted for bidirectional Glenn procedure. His past medical history included Sano-modified Stage I Norwood palliation in the neonatal period. He underwent the bidirectional Glenn procedure with pulmonary artery plasty, due to severe right pulmonary artery stenosis diagnosed on the pre-Glenn catheterization. Surgery was uneventful, and he was successfully extubated. On day 9 after surgery, nasal swab was positive for an RSV infection, and he was reintubated and started on inotropic support and nitric oxide for severe hypoxemia. Echocardiogram showed no flow in the left pulmonary artery (LPA). Catheterization demonstrated a complete occlusion of the LPA by a long segment thrombus [Figure 1]. Thrombectomy and LPA plasty using Gore-Tex membrane (0.6 mm) were performed followed by a computed tomographic angiography (CTA)

This is an open access journal, and articles are distributed under the terms of the Creative Commons Attribution-NonCommercial-ShareAlike 4.0 License, which allows others to remix, tweak, and build upon the work non-commercially, as long as appropriate credit is given and the new creations are licensed under the identical terms.

For reprints contact: WKHLRPMedknow_reprints@wolterskluwer.com

How to cite this article: Hubara E, Borik S, Kenet G, Mishaly D, Vardi A. Catheter-directed thrombolysis for *in situ* pulmonary artery thrombosis in children. *Ann Pediatr Card* 2021;14:211-4.

Access this article online

Quick Response Code:



Website:

www.annalspc.com

DOI:

10.4103/apc.APC_162_20

Address for correspondence: Dr. Evyatar Hubara, The Department of Pediatric Cardiac Critical Care Medicine, The Edmond and Lily Safra Children's Hospital, Sheba Medical Center, Tel Hashomer, Israel.

E-mail: evyatar.hubara@sheba.health.gov.il, evyatarhu@gmail.com

Submitted: 19-Jul-2020

Revised: 17-Sep-2020

Accepted: 28-Jan-2021

Published: 03-May-2021

that showed patent pulmonary arteries. Following the procedure, heparin therapy was resumed, yet a follow-up CTA 6 days later demonstrated re-occlusion of the LPA. Following multidisciplinary consultation, an urgent catheterization was performed during which the LPA was re-canalized using a glide catheter and 0.35” Terumo® glide wire with repeat manual suction of the thrombus. Surgical opinion was to avoid stenting the artery, so the catheter was left in situ in the thrombus for local administration of tissue plasminogen activator (TPA) to be given for 24 hours at a dose of 0.2 mg/kg/hr. The sheath inserted in the right internal jugular vein and the catheter left in place [Figure 2] were sewn securely in the neck for the duration of treatment and removed as soon as this was discontinued, with easy manual hemostasis achieved. Throughout treatment, the patient’s laboratory parameters including fibrinogen, plasminogen, platelet counts, and D-dimer levels were monitored. CDT was disconnected after 18 h due to mild bleeding at the sheath site and stabilization of D-dimer levels. No complications were noted. Following the procedure, bivalirudin infusion was started, as we suspected some heparin resistance and opted to apply a short-acting and potent anticoagulant. Repeat CT showed patency of the occluded vessel, and the patient was successfully extubated. Three weeks later, he underwent repeat catheterization for balloon dilation of the distal LPA [Figure 3] and has since undergone further dilation. Continued dilation is planned for rehabilitation of the pulmonary tree. In the meantime, the child has been discharged with long-term anticoagulation therapy with low-molecular weight heparin and is doing well with a room air oxygen saturation of 80%.

DISCUSSION

We present a young infant with a rare complication of local thrombus formation in a pulmonary artery following Glenn palliation for HLHS who underwent successful CDT.

Whereas the mainstay of treatment of acute pediatric thrombosis is systemic anticoagulation, the management of ISPAT is usually more aggressive.^[4] A rapid restoration of occluded vessels is necessary and therefore most patients undergo intervention.^[5-6] A systematic review found either surgical thrombectomy or stent placement, to be the preferred initial intervention in children who developed ISPAT.^[3] However, more recent studies have showed the efficacy and safety of CDT in children with PE in general and ISPAT in particular [Table 1].

The first successful CDT for acute pulmonary artery embolism was reported in 1996 by Beitzke *et al.*^[7] in a 3-year-old girl who presented with near lethal PE 3 weeks after Fontan operation. Nomura *et al.* described, in 2014, a case of 20-year-old woman with thromboembolism of

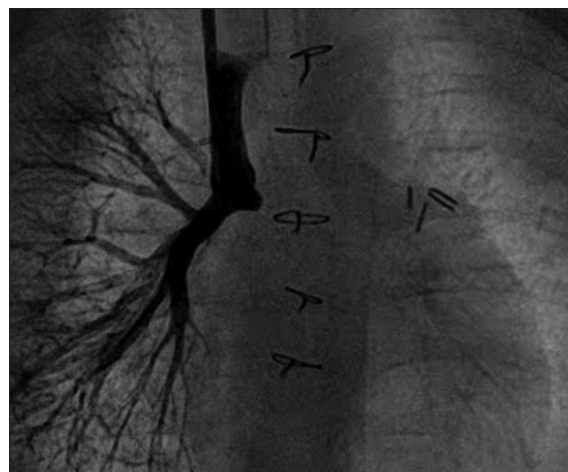

Figure 1: Angiogram in the superior vena cava demonstrating complete re-occlusion of the left pulmonary artery on repeat catheterization

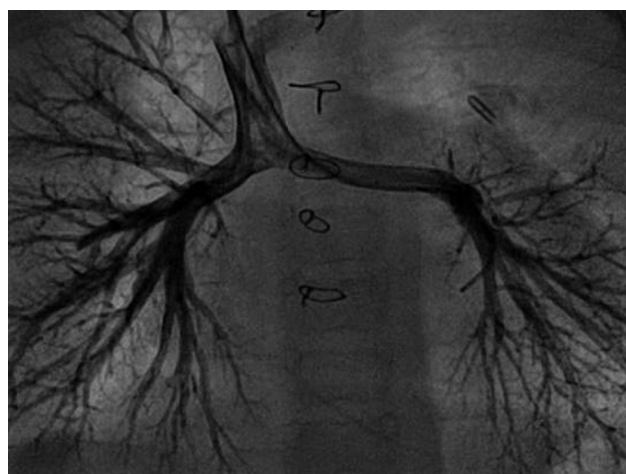


Figure 2: Angiogram in the left pulmonary artery after recanalization showing thrombus *in situ*. The catheter was left in this position for catheter-directed thrombolysis, as described in the text

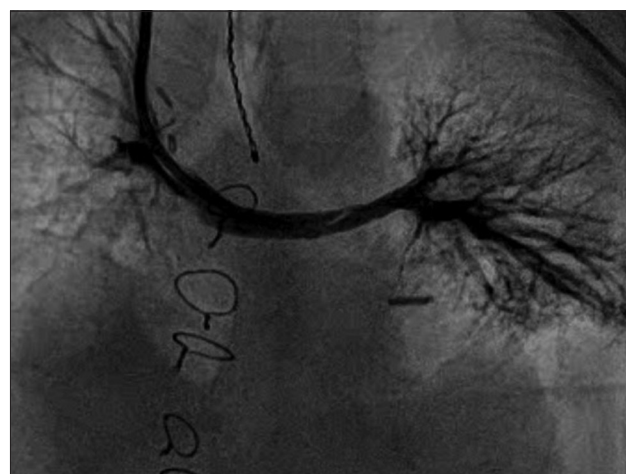

Figure 3: Angiogram after balloon dilation the left pulmonary artery and upper lobe branch three weeks after catheter directed thrombolysis. Note a widely patent central pulmonary artery with limited distal pulmonary tree

Table 1: Summary of data on catheter directed thrombolysis in patients with pulmonary emboli

Author, year	Number of patients, age	ISPAT rate	Location	Thrombolysis (tPA) dose and duration	Outcome
Dabin Ji, 2020	9, 6-19 year	None	5 B/L PA	0.5 mg/h 18-37 h	44% complete resolution 56% partial resolution No complications
Marvin K, 2019	1, 12 year	None	4 unilateral RPA	2.5 mg bolus followed by 1 mg/h 32 h (8 h and then 24 h)	Marked clinical and radiological improvement No complications
Belsky J, 2019	5, 3-21 year	None	4 B/L 1 RPA	0.03-2 mg/h 11.5-72.5 h	4 complete resolution 1 partial resolution No complications
Khan A, 2018	2 (children with PE out of 10 reported cases)	None	LPA	0.25-1 mg/h 16-25 h	Complete resolution No complications
Akam-Venkata J, 2018	9, 12-20 year	N/A	5 B/L 3 RPA 1 LPA	2 mg bolus followed by 1 mg/h 8-24 h	4 clinical improvement 7 survived 2 minor GI bleeding
Bavare AC, 2014	5, 11-17 year	None	3 B/L PA 2 RPA	0.75-2 mg/h 24 h	3 complete resolution 2 partial resolution No mortality No complications
Cannizzaro V, 2005	2, 10-13 year	None	1 B/L PA	Bolus 0.02-0.03 mg/kg Followed by 0.025 mg/kg/h 28-32 h	Hematoma at the access site Mild epistaxis
Ruud E, 2003	1 (out of 2 reported cases) 12 year	1	LPA	0.008-0.016 mg/kg/h	Complete resolution
Beitzke A, 1996	1, 3 year	1	N/A	N/A	N/A

PE: Pulmonary emboli, ISPAT: *In situ* pulmonary artery thrombus, tPA: Tissue plasminogen activator, RPA: Right pulmonary artery, LPA: Left pulmonary artery, B/L: Bilateral, PA: Pulmonary arteries, GI: Gastrointestinal, N/A: Not available

the subsegmental branches of the right pulmonary artery after a Glenn procedure with a successful CDT.^[8] Over the years, rare cases of pulmonary artery occlusion treated with CDT have been published. Most of the patients had a background of hypercoagulable states, and their clinical presentation was similar to that of adults with PE. Only two patients described had associated structural cardiac disease.

PE in adults is usually triggered by DVT, underlying thrombophilic risk factors or acquired conditions promoting hypercoagulability (e.g., cancer, immobility, hormonal therapy, and presence of antiphospholipid antibodies). The prevalence of postcardiac surgery PE in children is considered extremely rare even with concomitant respiratory infection, as in our case. In these cases, PE may be localized to MPA. Treatment duration of isolated pediatric PE (unlike adult PE) may be relatively short, especially when prothrombotic systemic risk factors cannot be established.

The distinction in choice preference between surgery and direct thrombectomy is still unclear. Given the long segment thrombus and surgical preference, we first performed surgical thrombectomy. However, due to re-occlusion propagated by high pulmonary resistance, pulmonary artery stenosis, and a concomitant viral infection, we decided to resolve the occlusion by direct thrombolysis. Factors which led our team to favor thrombolysis over stenting were mainly surgical preference due to a small distal pulmonary artery and young patient age. Indeed, the child may undergo

future stenting of the pulmonary artery; however, this management allowed gradual rehabilitation of the pulmonary tree and the ability to place a larger stent later which will be effective until adulthood. Endovascular catheter-directed therapy has the advantage of installation of lower doses of thrombolysis into or close to the thrombus, therefore reducing risk of bleeding. Strict monitoring during thrombolysis with tPA is critical. D-Dimer levels can particularly help to keep track of direct tPA therapy, as an elevated level reflects active fibrinolysis and stable or decreased levels indicate the absence of further thrombolysis and suggest thrombolysis may be discontinued.^[9] Bleeding remains a major concern, specifically in postsurgical cardiac patients, and is usually a primary end point for treatment.^[10]

Notably, bivalirudin therapy has been successful in young infants.^[11] The drug, usually indicated for the treatment of heparin-induced thrombocytopenia, is highly potent as it binds to the thrombin-bound clot and promotes thrombus recanalization. It may be easily monitored and has a very short half-life, the latter being extremely beneficial in postsurgical situations with increased bleeding risk. After treatment, the patient's condition markedly improved, and his recovery was fast and uneventful.

CONCLUSION

To the best of our knowledge, this is the youngest reported case of patient with ISPAT undergoing CDT. The infant

presented with severe hypoxemia after bidirectional Glenn procedure due to complete occlusion of the LPA. A direct catheter approach and local administration of thrombolysis allowed for successful re-canalization of his pulmonary artery and important clinical improvement.

Declaration of patient consent

The authors certify that they have obtained all appropriate patient consent forms. In the form the patient(s) has/have given his/her/their consent for his/her/their images and other clinical information to be reported in the journal. The patients understand that their names and initials will not be published and due efforts will be made to conceal their identity, but anonymity cannot be guaranteed.

Financial support and sponsorship

Nil.

Conflicts of interest

There are no conflicts of interest.

REFERENCES

1. Spentzouris G, Scriven RJ, Lee TK, Labropoulos N. Pediatric venous thromboembolism in relation to adults. *J Vasc Surg* 2012;55:1785-93.
2. Ramiz S, Rajpurkar M. Pulmonary embolism in children. *Pediatr Clin North Am* 2018;65:495-507.
3. Rajpurkar M, Biss T, Amankwah KE, Martinez D, William S, van Ommen HC, *et al.* Goldenberg. Pulmonary embolism and *in situ* pulmonary artery thrombosis in paediatrics. *Thromb Haemost* 2017;117:1199-207.
4. Law C, Raffini L. A guide to the use of anticoagulant drugs in children. *Paediatr Drugs* 2015;17:105-14.
5. Ino T, Benson LN, Freedom RM, Barker GA, Aipursky A, Rowe RD. Thrombolytic therapy for femoral artery thrombosis after pediatric cardiac catheterization. *Am Heart J* 1988;115:633-9.
6. Kennedy LA, Drummond WH, Knight ME, Millsaps MM, Williams JL. Successful treatment of neonatal aortic thrombosis with tissue plasminogen activator. *J Pediatr* 1990;116:798-801.
7. Beitzke A, Zobel G, Zenz W, Gamillscheg A, Stein JI. Catheter-directed thrombolysis with recombinant tissue plasminogen activator for acute pulmonary embolism after fontan operation. *Pediatr Cardiol* 1996;17:410-2.
8. Nomura K, Kurosawa H, Morita K, Tanaka K, Shimizu S. Pulmonary thromboembolism after one and a half ventricle repair. Successful catheter-directed thrombolysis. *Jpn J Thorac Cardiovasc Surg* 2001;49:138-40.
9. Tarango C, Manco-Johnson MJ. Pediatric thrombolysis: A practical approach. *Front Pediatr* 2017;5:260.
10. Ansah DA, Patel KN, Montegna L, Nicholson GT, Ehrlich AC, Petit CJ. Tissue plasminogen activator use in children: bleeding complications and thrombus resolution. *J Pediatr* 2016;171:67-720.
11. Buck ML. Bivalirudin as an alternative to heparin for anticoagulation in infants and children. *J Pediatr Pharmacol Ther* 2015;20:408-17.