



## Case Report

## Improvement of Erdheim-Chester disease-related renal failure after treatment with anakinra

Manuel Alfredo Podestà<sup>1</sup>, Giorgio Graziani<sup>1,\*</sup>, Francesco Reggiani<sup>1</sup>, Michele Buemi<sup>2</sup>, Salvatore Badalamenti<sup>1</sup>, Claudio Ponticelli<sup>1</sup><sup>1</sup> Nephrology and Dialysis Unit, Humanitas Clinical and Research Center, Milano, Italy<sup>2</sup> Department of Internal Medicine, University of Messina, Messina, Italy

## A B S T R A C T

## Article history:

Received 29 May 2014

Received in revised form

17 July 2014

Accepted 31 July 2014

Available online 10 September 2014

## Keywords:

Anakinra

Erdheim-Chester disease

Renal failure

Erdheim-Chester disease (ECD) is a rare non-Langerhans cell histiocytosis characterized by infiltrates of lipid-laden CD68<sup>+</sup>/CD1a<sup>-</sup> histiocytes, affecting heart, lungs, central nervous system, and bones. Kidney and adjacent structures can also be affected, leading to renal failure in about 30% of cases. The diagnosis is challenging, and treatment is generally based on administration of interferon-alpha (IFN $\alpha$ ), but preliminary results also showed the therapeutic efficacy of anakinra, an antagonist of the receptor of interleukin-1 (IL-1). We report the case of an elderly patient with ECD and severe involvement of the heart and kidneys who was successfully treated with anakinra.

© 2014. The Korean Society of Nephrology. Published by Elsevier. This is an open access article under the CC BY-NC-ND license (<http://creativecommons.org/licenses/by-nc-nd/4.0/>).

## Introduction

Erdheim-Chester disease (ECD) is a rare non-Langerhans cell histiocytosis that affects multiple organ and systems. Since the first description by Chester in 1930, approximately 450 cases have been reported in international literature. The disease is characterized by xanthogranulomatous infiltrates of foamy CD68<sup>+</sup>/CD1a<sup>-</sup> histiocytes usually surrounded by fibrosis. The etiology and pathogenesis of ECD remain poorly understood and its classification as a tumoral or inflammatory disease is controversial [1].

The clinical presentation is variable. A single patient may have a different combination of symptoms depending on the organs involved. Commonly involved sites are retro-orbital soft tissue, pituitary gland, lungs, and central nervous system, with manifestation ranging from diabetes insipidus to cerebellar or pyramidal syndromes, cognitive impairment and

cranial nerve paralysis. Infiltration of the liver, spleen, thyroid, skin, conjunctiva, and false vocal cord may also occur [1]. The involvement of flat and long bones is almost universal and causes juxta-articular pain, mainly in the knees and ankles. Cardiovascular symptoms may also occur: they are mainly related to pericardial effusion, which bears a high risk of cardiac tamponade. Less commonly, myocardial infiltration may cause a typical pattern of “pseudo-tumor”, usually localized in the right heart. Myocardial infarctions and valvular heart disease have also been reported [2]. Kidneys may be involved in up to 30% of cases [1]; renal disease may be caused by a direct invasion of the renal sinus and parenchyma or by a distal ureteral obstruction. In some cases, a periaortic infiltration extends to the renal vessels and spreads to the perirenal and hilar region of the kidneys, resulting in bilateral hydronephrosis or in renal artery compression, renovascular hypertension, and kidney ischemic injury, or in ureteral compression and bilateral hydronephrosis. Interestingly, both the vena cava and the pelvic ureters are usually unaffected, a feature that helps to distinguish ECD from retroperitoneal fibrosis. Kidney involvement is rarely symptomatic, but it may be progressive and lead to end-stage renal disease [3].

\* Corresponding author. Istituto Clinico Humanitas, Istituto di Ricovero e Cura a Carattere Scientifico (IRCCS), Via Manzoni 56, 20089 Rozzano – Milano, Italy.

E-mail address: [giorgio.graziani@humanitas.it](mailto:giorgio.graziani@humanitas.it) (G. Graziani).

Prior to the introduction of interferon-alpha (IFN $\alpha$ ), the mortality in patients with ECD was as high as 60% within 32 months from clinical diagnosis. Treatment with high-dose IFN $\alpha$  improved prognosis in about 67% of patients [4], but myocardial, renal, pulmonary, or central nervous system complications remain a frequent cause of death. Recently, encouraging results have been reported with anakinra, the recombinant form of interleukin-1 (IL-1) receptor antagonist [5–7]. We report here the beneficial results of anakinra in an elderly patient affected by ECD with kidney, heart, and bone involvement.

### Case report

A 76-year old man was admitted to our unit because of hypertension and renal function deterioration. His medical history was remarkable for chronic kidney disease with a baseline creatinine of 1.6 mg/dL, diabetes mellitus type 2, transient ischemic attacks, coronary artery disease, and recurrent episodes of colicky pain due to kidney stones.

At presentation, the patient complained of asthenia, permanent bone pain, dull chest pain, and dyspnea. Blood pressure was 150/80 mmHg. Physical examination of the lungs, heart, and abdomen was unremarkable. Laboratory investigations showed: serum creatinine 2.6 mg/dL, phosphate 5.2 mg/dL, and glycated hemoglobin 7.2%. All of the other tests, including complete blood count, electrolytes, and urinalysis, were normal.

Urinary tract ultrasonography showed bilateral hydronephrosis with a stone measuring 10 mm in diameter in the right kidney. Contrast-enhanced computed tomography also revealed the presence of an extrapelvic fibrous tissue which extended up to the ureteral origin, determining a significant bilateral constriction and stretching of the renal pelvis, with retrodilatation of the calyces. The ureters were not dilated. At magnetic resonance imaging (MRI), the extrapelvic tissue signal was compatible with the presence of fibrous tissue (Fig. 1). A laparotomy biopsy of the perirenal area showed a fibromuscular tissue diffusely infiltrated by foamy histiocytes, along with areas of steatonecrosis. On direct immunofluorescence, the histiocytes were CD68<sup>+</sup> and CD1a<sup>-</sup>.

A cardiac MRI showed pericardial effusion and a mass infiltrating the interatrial septum, which extended up to the

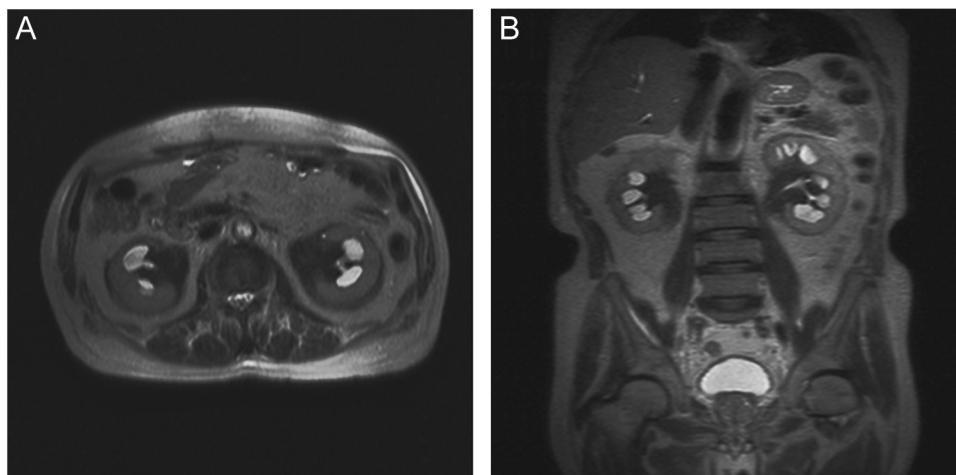
junction of the cava veins. The mass signal was not homogeneous, with punctiform nodulations, strongly suggesting a diagnosis of histiocytosis. A bone X-ray showed medullary osteosclerosis. Tests for lung and cerebral involvement were negative.

A diagnosis of ECD was made and treatment with subcutaneous pegylated IFN $\alpha$  was started at a dose of 180  $\mu$ g/wk, which was afterwards reduced to 135  $\mu$ g/wk. Heart MRI at 12 months showed reduction of the pericardial effusion and decrease of the right atrium wall thickening from 18 cm to 9 cm. However, treatment was poorly tolerated because of weakness, edema, and hypotension. Of more concern, serum creatinine progressively increased up to 3.9 mg/dL. IFN $\alpha$  was withdrawn, and subcutaneous anakinra (100 mg/d, according to the technical schedule) was started. After 1 year of therapy, the symptoms improved, serum creatinine decreased to 2.0 mg/dL, and a follow-up ultrasound showed the absence of hydronephrosis. After another year of follow-up, serum creatinine was still stable at around 2.0 mg/dL.

### Discussion

ECD is an exceptionally rare disease that eventually leads to a multifaceted clinical presentation. The diagnosis and treatment are difficult. When the histiocytic xanthogranulomatous infiltrates invade the perirenal and hilar tissues, a number of consequences may occur, ranging from progressive parenchymal ischemia and renal artery stenosis to ureteral obstruction and hydronephrosis. These lesions may eventually lead to chronic renal failure.

Attempts to treat ECD have been based on glucocorticoids associated with bisphosphonates and/or cytotoxic drugs, or high-dose chemotherapy followed by peripheral autologous hematopoietic stem cell transplantation. Braiteh et al [8] reported the first successful treatment with IFN $\alpha$  in three patients with advanced ECD. It has been suggested that IFN $\alpha$  may activate CD40-ligand, a member of the tumor necrosis factor (TNF) superfamily which binds to CD40 on dendritic cells. CD40-ligand accelerates the maturation of dendritic cells, and favors immune-mediated destruction of histiocytes. Moreover, IFN $\alpha$  has an immunomodulatory effect and antiinflammatory action by reducing lesional histiocyte recruitment.



**Figure 1.** Abdominal T2-weighted magnetic resonance imaging showing the extrapelvic fibrous tissue determining a bilateral constriction of the renal pelvis, with retrodilatation of the calyces (A: axial plane, B: coronal plane).

The efficacy of IFN $\alpha$  depends on individual response and on the organs involved [6]. In our patient, IFN $\alpha$  obtained an important reduction of myocardial pseudotumoral mass and pericardial effusion. However, renal function progressively deteriorated over time, with creatinine up to 3.9 mg/dL. Therapeutic dose is another open issue. Some authors reported that only high doses of IFN $\alpha$  could obtain a significant improvement of symptoms in about 66% of patients, but half of them complained of side effects [4]. Other investigators suggested that the initial dose of  $3.0\text{--}6.0 \times 10^6$  units, three times/wk, given subcutaneously, may be safely reduced to  $1.0 \times 10^6$  units in the long-term, to avoid side effects such as fatigue and flu-like syndrome [9]. However, in our patient, adverse events did not subside, even after dose adjustment.

Previous studies in ECD patients reported increased levels of proinflammatory cytokines, such as IL-1 and TNF $\alpha$ . More recently, Arnaud et al [10] found a significant increase in plasma levels of IL-6, a proinflammatory cytokine induced by T helper (Th)1 responses, along with an increase of IL-12, which favors the Th1 pathway [10]. These data suggest that ECD is associated with a systemic immune Th1-oriented disorder. In this setting, novel therapeutic approaches may be based on drugs that prevent the biologic activity of proinflammatory cytokines, particularly IL-1. Anakinra is a recombinant, non-glycosylated form of human IL-1 receptor antagonist (IL-1Ra), which binds to IL-1 membrane receptor and downregulates the biologic activities of IL-1, including inflammation. This effect is similar to that exerted by IFN $\alpha$ , which in fact increases the expression of IL-1Ra. Aouba et al [5] first reported a significant reduction of IL-1 $\alpha$  (a form expressed at the monocytes membrane surface after cell stimulation) following treatment with 100 mg/d of anakinra, a finding that, along with clinical improvement, supported the hypothesis of IL-1 as a primary actor in ECD systemic perturbation. Anakinra also showed important results in some ECD patients with skeletal [6] and cardiac involvement [7]. In all cases, a reduction of inflammatory markers, fever, and ECD symptoms was observed.

According to the technical schedule, anakinra should not be administered to patients with severe renal failure (creatinine clearance  $< 30$  mL/min/1.73m<sup>2</sup>) and should be used with caution in geriatric patients. Despite this, we decided to use anakinra as a rescue therapy in our patient, because of the poor tolerance of IFN $\alpha$  and the progressive deterioration of kidney function. We closely monitored possible side effects related to drug administration, such as infections and neutropenia. General conditions of the patient improved and plasma creatinine reduced from 3.9 mg/dL to 2.0 mg/dL. Neither renal artery nor ureteral stenting were necessary to obtain this result. Moreover, in contrast to IFN $\alpha$  therapy, which caused

severe side effects, anakinra was well tolerated with no side effects, even in the long-term. To the best of our knowledge, this is the first reported case of ECD with renal failure, unresponsive to IFN $\alpha$  therapy, successfully treated with anakinra.

### Conflict of interest

The authors have no conflict of interest or financial ties to disclose.

### References

- [1] Haroche J, Arnaud L, Cohen-Aubart F, Hervier B, Charlotte F, Emile JF, Amour Z: Erdheim-Chester disease. *Curr Rheumatol Rep* 16: 412, 2014
- [2] Haroche J, Cluzel P, Toledano D, Montalescot G, Touitou D, Grenier PA, Piette JC, Amour Z: Images in cardiovascular medicine. Cardiac involvement in Erdheim-Chester disease: magnetic resonance and computed tomographic scan imaging in a monocentric series of 37 patients. *Circulation* 119:e597–e598, 2009
- [3] Verdalles U, Goicoechea M, Garcia de Vinuesa S, Mosse A, Luño J: Erdheim-Chester disease: a rare cause of renal failure. *Nephrol Dial Transplant* 22:1776–1777, 2007
- [4] Hervier B, Arnaud L, Charlotte F, Wechsler B, Piette JC, Amour Z, Haroche J: Treatment of Erdheim-Chester disease with long-term high-dose interferon-alpha. *Semin Arthritis Rheum* 41:907–913, 2012
- [5] Aouba A, Georgin-Lavialle S, Pagnoux C, Martin Silva N, Renadn A, Galateau-Salle F, Le Toquin S, Bensadoun H, Larousserie F, Silvera S, Provost N, Candon S, Seror R, de Menthon M, Hermine O, Guillecin L, Bienvenu B: Rationale and efficacy of interleukin-1 targeting in Erdheim-Chester disease. *Blood* 116:4070–4076, 2010
- [6] Aubert O, Aouba A, Deshayes S, Georgin-Lavialle S, Rieu P, Hermine O: Favorable radiological outcome of skeletal Erdheim-Chester disease involvement with anakinra. *Joint Bone Spine* 80: 206–207, 2013
- [7] Killu AM, Liang JJ, Jaffe AS: Erdheim-Chester disease with cardiac involvement successfully treated with anakinra. *Int J Cardiol* 167: e115–e117, 2013
- [8] Braiteh F, Boxrud C, Esmaeli B, Esmaeli B, Kurzrock R: Successful treatment of Erdheim-Chester disease, a non-Langerhans-cell histiocytosis, with interferon-alpha. *Blood* 106:2992–2994, 2005
- [9] Suzuki HI, Hosoya N, Miyagawa K, Ota S, Nakashima H, Kurokawa M: Erdheim-Chester disease: multisystem involvement and management with interferon-alpha. *Leuk Res* 34:e21–e24, 2010
- [10] Arnaud L, Gorochoy G, Charlotte F, Lvovschi V, Parizot C, Larsen M, Ghillani-Dalbin P, Hervier B, Kahn JE, Deback C, Musset L, Amour Z, Heroche J: Systemic perturbation of cytokine and chemokine networks in Erdheim-Chester disease: a single-center series of 37 patients. *Blood* 117:2783–2790, 2011