

## Investigating the effects of carvacrol in rats using oxygen-induced retinopathy model

Abdulgani Kaymaz, Fatih Ulaş, Ayhan Çetinkaya<sup>1</sup>, Sevilay Erimşah<sup>2</sup>

**Purpose:** Investigating the effects of intraperitoneal carvacrol administration in rats using the oxygen-induced retinopathy (OIR) model. **Methods:** A total of 28 newborn Sprague Dawley rats were used and the OIR model was created using the 50/10% oxygen model. The study composed of four groups in total. While the OIR model was not used in Group I (control group), it was created for Groups II, III, and IV. About 0.01 mL carvacrol, bevacizumab, or 0.9% NaCl was administered intraperitoneal (IP) to the rats in all groups on postnatal day (PND) 14 as follows: Group I and Group II were administered 0.9% NaCl, Group III was administered bevacizumab, and Group IV was administered carvacrol. On PND 18, rats were sacrificed and their right eyes were enucleated. **Results:** Histopathological and immunohistochemical studies showed that the number of vascular endothelial cells (VECs), vascular endothelial growth factor (VEGF), and tumor necrosis factor- $\alpha$  (TNF- $\alpha$ ) decreased similarly in Group III and Group IV compared with Group II. VECs values for Group I, Group II, Group III, and Group IV were measured as  $0 \pm 0$ ,  $26.45 \pm 4.57$ ,  $7.75 \pm 1.98$ , and  $5.78 \pm 1.72$ , respectively, and it differed significantly between groups ( $P < 0.001$ ). Likewise, VEGF levels were observed as  $0.06 \pm 0.01$ ,  $3.31 \pm 0.53$ ,  $2.47 \pm 0.44$ , and  $2.49 \pm 0.52$ , respectively, and it differed significantly between groups ( $P < 0.001$ ). TNF- $\alpha$  levels were recorded as  $0.06 \pm 0.01$ ,  $3.58 \pm 0.38$ ,  $2.46 \pm 0.49$ , and  $2.29 \pm 0.25$ , respectively, and it differed significantly between groups ( $P < 0.001$ ). VECs, VEGF, and TNF- $\alpha$  were similar between Group III and IV (range of  $P$  values were 0.486–0.998). **Conclusion:** The study demonstrated that carvacrol significantly reduced retinal pathological angiogenesis, NV, VEC nuclei count, VEGF, and TNF- $\alpha$  levels. Moreover, the observed effects were comparable to those of bevacizumab.

**Key words:** Bevacizumab, carvacrol, neovascularization, oxygen-induced retinopathy, retinopathy of prematurity, tumor necrosis factor- $\alpha$ , vascular endothelial growth factor

Oxygen-induced retinopathy (OIR) is an effective model used to investigate and evaluate ischemia-associated pathological retinal neovascularization (NV). The OIR model simulates the pathological features of retinopathy of prematurity (ROP) with a coherent and reproducible angiogenic response. Therefore, this method has become an important way to investigate the mechanisms of proliferative vascular diseases and to develop potential therapies for these diseases.<sup>[1]</sup> Retinal NV, induced by ischemia and hypoxia, is an important pathological process in many vision-threatening diseases, including diabetic retinopathy (DRP), ROP, age-related macular degeneration (AMD), and retinal vein occlusion (RVO).<sup>[2-4]</sup> In addition, these proliferative vascular illnesses might cause irreversible damage to the patients' visual acuity.<sup>[5]</sup>

Vascular endothelial cells (VECs) have important roles in the process of angiogenesis. They activate the transcription of multiple genes during hypoxia as well as stimulate the release of growth factors, for instance, vascular endothelial growth factor (VEGF) and tumor necrosis factor- $\alpha$  (TNF- $\alpha$ ).<sup>[6]</sup> VEGF is a very important component in retinal NV development.<sup>[7,8]</sup> Similarly, TNF- $\alpha$  is a very strong angiogenic factor that is central to the arrangement of many genes, such as those encoding angiogenic mediators and adhesion molecules.<sup>[9]</sup>

Departments of Ophthalmology, <sup>1</sup>Physiology, <sup>2</sup>Histology and Embryology, Faculty of Medicine, Bolu Abant İzzet Baysal University, Bolu, Turkey

**Correspondence to:** Dr. Abdulgani Kaymaz, Department of Ophthalmology, Faculty of Medicine, Bolu Abant İzzet Baysal University, 14280 Bolu, Turkey. E-mail: kaymaz9@hotmail.com

Received: 12-Jun-2020

Revision: 17-Oct-2020

Accepted: 11-Dec-2020

Published: 30-Apr-2021

Access this article online

Website:

www.ijo.in

DOI:

10.4103/ijo.IJO\_1935\_20

Quick Response Code:



Bevacizumab (Avastin<sup>®</sup>), is a complete humanized murine monoclonal antibody that binds against all isoforms of VEGF, an angiogenic cytokine that promotes vascular leakage and growth.<sup>[10,11]</sup> As an off-label agent, bevacizumab is useful in the treatment of retinal disease with many intraocular vascular proliferation, including DRP, ROP, AMD, and RVO.<sup>[12-14]</sup> On the other hand, carvacrol, which is a monoterpene with a phenolic structure, has many biological properties, such as antiangiogenic, anti-inflammatory, and antioxidant actions. Due to its wide range of therapeutic effects, it has been largely used in traditional medicine.<sup>[15,16]</sup> In the existing literature, its therapeutic effects were reported in various diseases, for instance, diabetes mellitus, wound healing, colitis, lung, and kidney injury.<sup>[17-20]</sup> In such diseases, its effects were attributed to the mechanism of reducing VEGF, VEC, and TNF- $\alpha$ , suppressing NV and reversing inflammatory mechanisms. Besides VEGF carvacrol additionally suppresses inducible nitric oxide synthase (iNOS), cyclooxygenase (COX)-2, and nuclear factor- $\kappa$ B (NF- $\kappa$ B).<sup>[21]</sup> Moreover, carvacrol suppresses the fibrotic process by inhibiting transforming growth factor (TGF)- $\beta$ , Yes-associated protein (YAP), and transcriptional coactivator with PDZ-binding motif (TAZ).<sup>[22]</sup>

This is an open access journal, and articles are distributed under the terms of the Creative Commons Attribution-NonCommercial-ShareAlike 4.0 License, which allows others to remix, tweak, and build upon the work non-commercially, as long as appropriate credit is given and the new creations are licensed under the identical terms.

**For reprints contact:** WKHLRPMedknow\_reprints@wolterskluwer.com

**Cite this article as:** Kaymaz A, Ulaş F, Çetinkaya A, Erimşah S. Investigating the effects of carvacrol in rats using oxygen-induced retinopathy model. Indian J Ophthalmol 2021;69:1219-23.

Antiangiogenic, anti-inflammatory, and antioxidant effects of carvacrol have been extensively studied in many tissues and organs. However, less is known about the effects of carvacrol in retinal NV diseases. Therefore, in the present study, the efficacy of intraperitoneal (IP) bevacizumab and IPcarvacrol on retinal VEGF, TNF- $\alpha$ , and VECs were compared using an experimental OIR model in rats.

## Methods

The current study was conducted following the approval of study protocols by the Experimental Animal Studies Ethics Committee of Abant Izzet Baysal University (no: 2018/41). The study was conducted according to the guidelines of the Association for Research in Vision and Ophthalmology (ARVO) Statement for Use of Animals in Ophthalmic and Vision Research.

### Establishing the OIR Model

A total of 28 (70–120 g) Sprague Dawley newborn rats were used. All animals were maintained in a controlled environment with 22–24°C, 45–60% humidity, and a 12-h light: dark cycle. Food and water were provided *ad libitum*. To establish the 50/10 OIR model, 4 h following the birth, the pups were placed with their mothers in an oxygen-adjusted environment, in which the animals were encountered with 50% oxygen at first 24 h and then 10% oxygen for the following 24 h.<sup>[23]</sup> This cycle was repeated until postnatal day (PND) 14. The oxygen values of the environment were routinely followed each day and recalibrated if necessary. Moreover, carbon dioxide values of the environment were routinely followed each day, and carbon dioxide was eliminated from the environment by providing adequate gas-flow and adding soda lime. The animals were placed into the normal room air for 4 days after PND 14.

Four different groups, each consisting of seven pups were formed. In all groups, single IP injections were performed on PND 14.

Group I: The OIR model was not established. Animals were IP administered vehicle solution (0.01 mL 0.9% sodium chloride; control group).

Group II: The OIR model was established and the animals were IP administered 0.01 mL 0.9% sodium chloride (untreated OIR group).

Group III: The OIR model was created and the animals were IP administered 0.01 mL (2.5 mg/kg) bevacizumab (Altuzan, 100 mg/4 mL flacon, Roche, Switzerland).<sup>[24]</sup>

Group IV: OIR model was created and the animals were IP administered 0.01 mL (73 mg/kg) carvacrol (Sigma-Aldrich, St. Louis, USA).<sup>[25]</sup>

On PND 18, when OIR development is considered the most pronounced,<sup>[26]</sup> all animals were sacrificed by the intracardiac high-dose anesthesia. The right eyes of the rats were taken through enucleation, with a sufficient amount of optic nerve obtained.<sup>[26]</sup> Tissues were placed in fixation solutions for further histopathological and immunohistochemical examinations.

### Hematoxylin and Eosin (H&E) Staining

The eyes were fixed in a 10% neutral buffered formalin in phosphate-buffered saline (PBS) overnight at 4°C for 24 h and embedded in paraffin. The serial sections (4  $\mu$ m thick) of the whole eye were cut sagittally, which runs parallel to the optic nerve, and then stained with H and E. The nuclei of retinal VECs on the vitreal side of the retinal inner limiting membrane (ILM) was counted in ten sections of each eye at  $\times$  400 magnification by an independent observer blind to treatment, and the mean

number of the endothelial cell nuclei of each eye was calculated for each group [Fig. 1].

### Immunohistochemistry

Mouse and Rabbit Specific HRP Plus Detection Kit (ab93697; Abcam, Cambridge, UK) was used to perform immunohistochemistry. Paraffin-embedded tissues were cut into 4  $\mu$ m thick sections and deparaffinized in xylene. Then, the tissue samples were hydrated in graded ethanol. As antigen retrieval, tissues were treated with citrate buffer for 3–5 min at 600 W in a microwave oven. Further, 3% H<sub>2</sub>O<sub>2</sub> in methanol was used to block endogenous peroxidases for 15 min. To eliminate nonspecific binding, tissue samples were pretreated with blocking serum (Histostatin plus kit broad-spectrum; Invitrogen, California, USA). Later, the sections were incubated overnight with the following antibodies: anti-TNF alpha polyclonal antibody (1:250 dilution; ab183896; Abcam) and anti-VEGF monoclonal antibody (1:50 dilution; sc-7269; Santa, Santa Cruz, CA, USA) at 4°C. Subsequently, appropriate nonimmune immunoglobulin G was replaced with the primary antibody for negative control incubations. The sections were treated with the biotinylated secondary antibodies (Mouse and Rabbit Specific HRP Plus [ABC] Detection IHC kit [ab93697]) for 20 min at room temperature. The peroxide complex was visualized using 3,3-diaminobenzidine (DAB kit 88-2014, Invitrogen, California, USA). Then, Mayer's hematoxylin (Invitrogen, California, USA) was used to counterstain the tissue sections and they were mounted with Entellan (Merck, Darmstadt, Germany) on glass slides. The images were observed with a light microscope (Leica DM 1000, Germany) and the tissue section was photographed with Leica DMC 2900 (CH-9435 Heerbrugg, Germany). Each section was graded by two independent observers blind to treatment using the following scale: no expression (0), weak (1), moderate (2), strong (3), and very strong expression (4). The percentage of positive cells was defined as (0), <5%; (1), 6% to 15%; (2), 16% to 50%; (3), 51% to 80%; and (4), >80% positive cells.<sup>[27]</sup> This analysis was performed on three retinal sections of each rat and the mean value was determined.

### Statistical analyses

The data analyses were performed using the Statistical Package for the Social Sciences (SPSS) statistical software package, version 25.0 (SPSS Inc., Chicago, IL, USA). The data were presented as mean  $\pm$  standard deviations (SDs) for each data set. Statistical significance was considered as  $P < 0.05$ . The statistical analyses of the data were performed using one-way analysis of variance test and post hoc analyses following the confirmation of homogeneity and normality of the sample distribution.

## Results

### H&E staining and quantitative analysis of VECs

H&E staining on the retina in all groups is shown in Fig. 1. In Group II (untreated OIR Group), large amounts of abnormal microvessels in transverse and longitudinal lengths were recorded breaching ILM. The amount of NV was determined by counting the nuclei of the VECs [Table 1]. The number of VECs and vascular clusters that breached the ILM decreased while healing of the dilated vessels was observed in the groups treated with bevacizumab (Group III) and carvacrol (Group IV). VECs nuclei were not recognized on the vitreal side of the ILM in Group I (control group; Fig. 1). Although the numbers of retinal VECs nucleus were higher in Group II, it was significantly decreased in Group III and Group IV ( $P < 0.001$ ) [Fig. 1]. However, the number of VECs nuclei were similar between Group III and Group IV ( $P = 0.486$ ) [Table 2].

**Table 1: Quantitative analysis of VEC using hematoxylin and eosin and expression levels of VEGF and TNF- $\alpha$  using immunohistochemical staining in rat OIR model**

	Group I	Group II	Group III	Group IV	P*
VECs nuclei	0	26.45 $\pm$ 4.57	7.75 $\pm$ 1.98	5.78 $\pm$ 1.72	<0.001
VEGF	0.06 $\pm$ 0.01	3.31 $\pm$ 0.53	2.47 $\pm$ 0.44	2.49 $\pm$ 0.52	<0.001
TNF- $\alpha$	0.06 $\pm$ 0.01	3.58 $\pm$ 0.38	2.46 $\pm$ 0.49	2.29 $\pm$ 0.25	<0.001

\*One-way analysis of variance test. Group I: 0.01 mL IP vehicle solution (0.9% NaCl) was administered without establishing an OIR model (control group). Group II: 0.01 mL IP vehicle solution was administered following OIR development (untreated OIR group). Group III: 0.01 mL IP bevacizumab (2.5 mg/kg body weight) was administered following OIR development. Group IV: 0.01 mL IP carvacrol (73 mg/kg body weight) was administered following OIR development, TNF- $\alpha$ : tumor necrosis factor- $\alpha$ , VECs: vascular endothelial cells, VEGF: vascular endothelial growth factor

### Expressions of TNF- $\alpha$ and VEGF

The expression levels of VEGF and TNF- $\alpha$  in control and OIR groups were examined through immunohistochemistry [Table 1]. Positive staining of VEGF and TNF- $\alpha$  in the retinas of the OIR rats was quite remarkable in Group II [Figs. 2 and 3]. The staining intensity of VEGF and TNF- $\alpha$  was significantly reduced in Group III and Group IV compared to Group II ( $P$  values for VEGF were 0.004 and 0.006, respectively, and  $P$  values for TNF- $\alpha$  were <0.001) [Figs. 2 and 3]. The results demonstrated that carvacrol treatment reverses oxygen-dependent VEGF and TNF- $\alpha$  elevation.

In post hoc test results, VECs, VEGF, and TNF- $\alpha$  values of Group II were significantly higher than Group I ( $P < 0.001$  for each), Group III ( $P < 0.001$ ,  $P = 0.004$ , and  $P < 0.001$ , respectively) and Group IV ( $P < 0.001$ ,  $P = 0.006$ , and  $P < 0.001$ , respectively) [Table 2]. When Group I and Group III are compared, there was a significant decrease in VECs nucleus number, VEGF, and TNF- $\alpha$  values ( $P < 0.001$  for each). When comparing Group I and Group IV, VECs nucleus number, VEGF, and TNF- $\alpha$  values were significantly decreased ( $P = 0.003$ ,  $P < 0.001$ , and  $P < 0.001$ , respectively) [Table 2]. Although the agents used in Group III and IV provided an improvement in the parameters observed compared to Group II, it was not sufficient enough to bring them to the levels observed in Group I. However, unlike other findings, when Group III and Group IV were compared, VECs nucleus number, VEGF, and TNF- $\alpha$  values were similar to each other ( $P = 0.486$ ,  $P = 0.998$  and  $P = 0.772$ , respectively) [Table 2].

### Discussion

The results of the present study suggest that carvacrol administration significantly reduced retinal VECs, VEGF, and TNF- $\alpha$ , and reversed the process by suppressing the pathological NV developments. The observed effects were comparable to that of bevacizumab. To our knowledge, the current study is the first to investigate the effect of carvacrol on retinal NV.

Carvacrol, a component of thyme oil, is considered a new antitumor agent that could play a positive role in the treatment of various cancers, for example, lung, colon, and oral squamous cell cancers.<sup>[28-30]</sup> Moreover, many studies in the literature have reported the treatment of various diseases with carvacrol, including diabetes mellitus, liver toxicity, wound healing, and rheumatological diseases as well as damages in the lung, kidney, and intestine.<sup>[17-20,31,32]</sup> These studies reported the antiangiogenic, anti-inflammatory, and antioxidant effects of carvacrol.

TNF- $\alpha$  is a very powerful angiogenic agent and is also one of the most important inflammation markers.<sup>[9]</sup> Guimaraes *et al.* demonstrated that carvacrol decreased TNF- $\alpha$  concentrations in pleural lavage fluid in a mouse pleurisy model.<sup>[33]</sup> It has been previously shown that carvacrol significantly suppressed the inflammatory cytokines, especially TNF- $\alpha$ , in diabetic and hepatotoxicity rat models.<sup>[21,34]</sup> Studies have shown

**Table 2: Significance of multiple comparisons using post hoc test for the studied parameters**

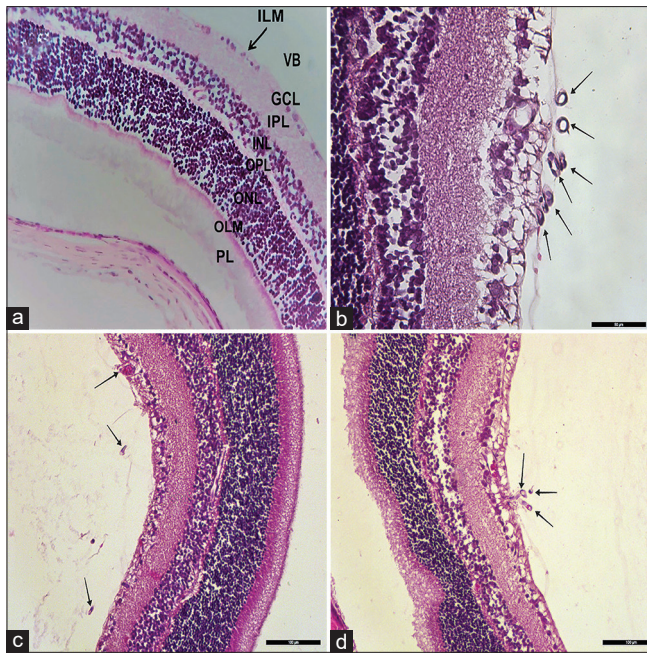
	VECs nuclei (P*)	VEGF (P*)	TNF- $\alpha$ (P*)
Group I - Group II	<0.001	<0.001	<0.001
Group I - Group III	<0.001	<0.001	<0.001
Group I - Group IV	0.003	<0.001	<0.001
Group II - Group III	<0.001	0.004	<0.001
Group II - Group IV	<0.001	0.006	<0.001
Group III - Group IV	0.486	0.998	0.772

\*Post hoc Tukey test. Group I: 0.01 mL IP vehicle solution (0.9% NaCl) was administered without establishing an OIR model (control group). Group II: 0.01 mL IP vehicle solution was administered following OIR development (untreated OIR group). Group III: 0.01 mL IP bevacizumab (2.5 mg/kg body weight) was administered following OIR development. Group IV: 0.01 mL IP carvacrol (73 mg/kg body weight) was administered following OIR development, TNF- $\alpha$ : tumor necrosis factor- $\alpha$ , VECs: vascular endothelial cells, VEGF: vascular endothelial growth factor

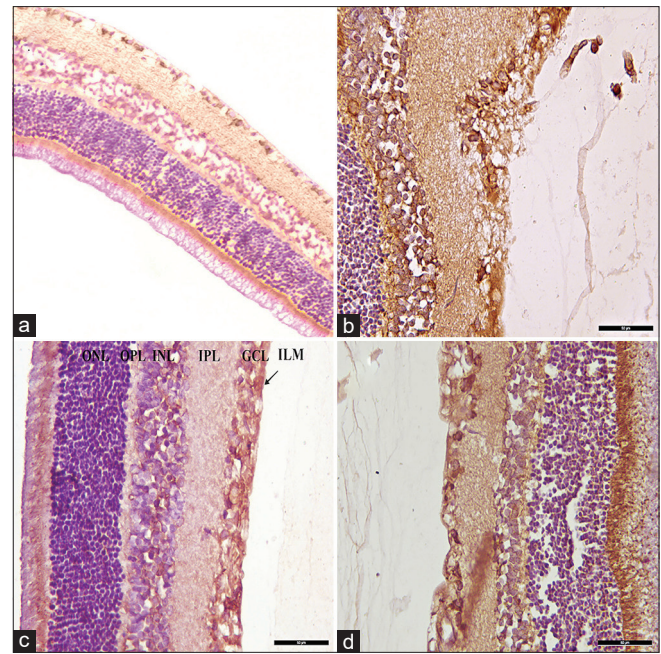
that carvacrol regulates the balance between pro and anti-inflammatory mediators, reduces lung toxicity, and suppresses the inflammatory response in patients with rheumatoid arthritis.<sup>[32,35,36]</sup> In the present study, it was observed that carvacrol significantly reduced the TNF- $\alpha$  level, and decreased inflammation and NV in the retina.

Carvacrol has been shown to suppress pathological NV by reducing VEGF in both cancer cells and VECs.<sup>[15]</sup> Likewise, Zeytun *et al.* found that carvacrol accelerates wound healing and suppresses VEGF in the esophageal burn model in rats.<sup>[37]</sup> In veterans, who were previously exposed to sulfur mustard and were treated with carvacrol, it was found that the serum levels of TNF- $\alpha$  and VEGF were decreased.<sup>[18]</sup> In the present study with the OIR model, similar results were obtained and carvacrol was found to reduce retinal VECs and VEGF and significantly suppressed NV.

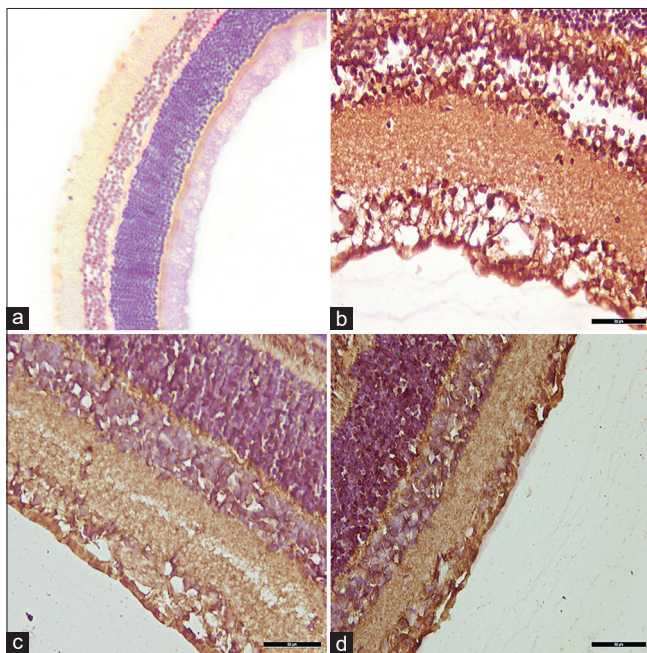
Ischemia and hypoxia in VECs in the retina increases VEGF production and causes retinal NV formation.<sup>[38]</sup> Strategies that modulate VEGF secretion in the retina have shown therapeutic efficacy.<sup>[38]</sup> In an OIR model study on mice, bevacizumab significantly suppressed VECs and VEGF.<sup>[39]</sup> It was shown in that study that treatment with bevacizumab decreased the number of blood vessel tufts and significantly changed the main vessel tortuosity. In mice with an ocular inflammation model, bevacizumab treatment reduced VEGF and TNF- $\alpha$  levels.<sup>[40]</sup> In addition, significant improvements were achieved in the treatment of ROP with intravitreal bevacizumab administration.<sup>[14]</sup> In the current study, it was observed that carvacrol significantly reduced retinal angiogenesis, NV, VEC nuclei count, VEGF, and TNF- $\alpha$  levels. Moreover, these results were comparable to that of bevacizumab, which is used in routine therapy.



**Figure 1:** H and E staining of retinal tissues. (a) Control; (b) Untreated OIR; (c) OIR + intraperitoneal bevacizumab; and (d) OIR + intraperitoneal carvacrol. GCL: ganglion cell layer, ILM: inner limiting membrane, INL: inner nuclear layer, IPL: inner plexiform layer, OLM: outer limiting membrane, ONL: outer nuclear layer, OPL: outer plexiform layer, PL: photoreceptor layer, VB: vitreous body. One way ANOVA test revealed numbers of retinal VECs nucleus were higher in Group II, it was significantly decreased in Group III and Group IV ( $P < 0.001$ ). However, the number of VECs nuclei were similar between Group III and Group IV ( $P = 0.486$ )



**Figure 2:** Expressions of VEGF. (a) Control (Grade 0); (b) Untreated OIR (Grade 3); (c) OIR + intraperitoneal bevacizumab (Grade 2); and (d) OIR + intraperitoneal carvacrol (Grade 2). GCL: ganglion cell layer, ILM: inner limiting membrane, INL: inner nuclear layer, IPL: inner plexiform layer, ONL: outer nuclear layer, OPL: outer plexiform layer. One way ANOVA test revealed retinal VEGF expression levels were higher in Group II, it was significantly decreased in Group III and Group IV ( $P < 0.001$ ). However, retinal VEGF expression levels were similar between Group III and Group IV ( $P = 0.998$ )



**Figure 3:** Expressions of TNF- $\alpha$ . (a) Control (Grade 0); (b) Untreated OIR (Grade 4); (c) OIR + intraperitoneal bevacizumab (Grade 2); and (d) OIR + intraperitoneal carvacrol (Grade 2). One way ANOVA test revealed retinal TNF- $\alpha$  expression levels were higher in Group II, it was significantly decreased in Group III and Group IV ( $P < 0.001$ ). However, retinal TNF- $\alpha$  expression levels were similar between Group III and Group IV ( $P = 0.772$ )

There were some limitations in the present study; injections were administered as an intraperitoneal single dose, the parameters examined were limited, and they were not supported by other advanced methods, such as Western blotting and real-time polymerase chain reaction (PCR). In addition, anti-inflammatory cytokine levels (like IL-10) and levels of cytokines that promote the fibrotic process (like TGF- $\beta$ ) in the rat OIR model were not evaluated to elucidate mechanisms of carvacrol action. Investigation of such cytokines can demonstrate the potential superiority of carvacrol over bevacizumab. Injections were administered intraperitoneally, as the effective dose of intravitreal carvacrol injection was unknown. Despite all these limitations, it was shown that the results obtained in retinal NV treatment were comparable to that of bevacizumab.

## Conclusion

In summary, the results of the current study demonstrated that carvacrol could potentially inhibit the retinal NV formation in the retina as well as decreased OIR-induced expression of VEGF and TNF- $\alpha$ . These data emphasized the potential benefit of carvacrol in the OIR model. These findings suggested that carvacrol could be used as a suitable therapeutic agent for the treatment of ROP, DRP, AMD, and RVO. Further, immunohistochemical and functional studies are needed to determine the effective dose and toxic effects of carvacrol that was administered intraperitoneally or intravitreally, and to determine the effects of repetitive injections.

## Acknowledgment

The authors thank Mr. İbrahim Ethem Torun for assistance with digital imaging.

## Financial support and sponsorship

Nil.

## Conflicts of interest

There are no conflicts of interest.

## References

- Smith LE, Wesolowski E, McLellan A, Kostyk SK, D'Amato R, Sullivan R, *et al.* Oxygen-induced retinopathy in the mouse. *Invest Ophthalmol Vis Sci* 1994;35:101-11.
- Ferris FL 3<sup>rd</sup>, Fine SL, Hyman L. Age-related macular degeneration and blindness due to neovascular maculopathy. *Arch Ophthalmol* 1984;102:1640-2.
- Green WR. Histopathology of age-related macular degeneration. *Mol Vis* 1999;5:27.
- Engerman RL. Pathogenesis of diabetic retinopathy. *Diabetes* 1989;38:1203-6.
- Tolentino MS, Tolentino AJ, Tolentino MJ. Current and investigational drugs for the treatment of diabetic retinopathy. *Expert Opin Investig Drugs* 2016;25:1011-22.
- Fraisl P, Mazzone M, Schmidt T, Carmeliet P. Regulation of angiogenesis by oxygen and metabolism. *Dev Cell* 2009;16:167-79.
- Eldweik L, Mantagos IS. Role of VEGF inhibition in the treatment of retinopathy of prematurity. *Semin Ophthalmol* 2016;31:163-8.
- Campochiaro PA. Molecular pathogenesis of retinal and choroidal vascular diseases. *Prog Retin Eye Res* 2015;49:67-81.
- Grilli M, Chiu JJ, Lenardo MJ. NF-kappa B and Rel: Participants in a multifactorial transcriptional regulatory system. *Int Rev Cytol* 1993;143:1-62.
- Comparison of Age-related Macular Degeneration Treatments Trials Research Group, Martin DF, Maguire MG, Fine SL, Ying GS, Jaffe GJ, *et al.* Ranibizumab and bevacizumab for treatment of neovascular age-related macular degeneration: Two-year results. *Ophthalmology* 2012;119:1388-98.
- Moja L, Lucenteforte E, Kwag KH, Bertele V, Campomori A, Chakravarthy U, *et al.* Systemic safety of bevacizumab versus ranibizumab for neovascular age-related macular degeneration. *Cochrane Database Syst Rev* 2014;9:CD011230.
- Mitchell P, Smith W, Wang JJ, Attebo K. Prevalence of diabetic retinopathy in an older community. The Blue Mountains Eye Study. *Ophthalmology* 1998;105:406-11.
- Arevalo JF, Sanchez JG, Fromow-Guerra J, Wu L, Berrocal MH, Farah ME, *et al.* Comparison of two doses of primary intravitreal bevacizumab (Avastin) for diffuse diabetic macular edema: Results from the Pan-American Collaborative Retina Study Group (PACORES) at 12-month follow-up. *Graefes Arch Clin Exp Ophthalmol* 2009;247:735-43.
- Mintz-Hittner HA, Kuffel RR Jr. Intravitreal injection of bevacizumab (avastin) for treatment of stage 3 retinopathy of prematurity in zone I or posterior zone II. *Retina* 2008;28:831-8.
- Khan I, Bhardwaj M, Shukla S, Lee H, Oh MH, Bajpai VK, *et al.* Carvacrol encapsulated nanocarrier/nanoemulsion abrogates angiogenesis by downregulating COX-2, VEGF and CD31 *in vitro* and *in vivo* in a lung adenocarcinoma model. *Colloids Surf B Biointerfaces* 2019;181:612-22.
- de Carvalho FO, Silva ER, Gomes IA, Santana HSR, do Nascimento Santos D, de Oliveira Souza GP, *et al.* Anti-inflammatory and antioxidant activity of carvacrol in the respiratory system: A systematic review and meta-analysis. *Phytother Res* 2020;34:2214-29.
- Bayramoglu G, Senturk H, Bayramoglu A, Uyanoglu M, Colak S, Ozmen A, *et al.* Carvacrol partially reverses symptoms of diabetes in STZ-induced diabetic rats. *Cytotechnology* 2014;66:251-7.
- Khazdair MR, Boskabady MH. The effect of carvacrol on inflammatory mediators and respiratory symptoms in veterans exposed to sulfur mustard, a randomized, placebo-controlled trial. *Respir Med* 2019;150:21-9.
- Costa MF, Durco AO, Rabelo TK, Barreto RSS, Guimaraes AG. Effects of carvacrol, thymol and essential oils containing such monoterpenes on wound healing: A systematic review. *J Pharm Pharmacol* 2019;71:141-55.
- Potocnjak I, Domitrovic R. Carvacrol attenuates acute kidney injury induced by cisplatin through suppression of ERK and PI3K/Akt activation. *Food Chem Toxicol* 2016;98:251-61.
- Aristatile B, Al-Assaf AH, Pugalendi KV. Carvacrol suppresses the expression of inflammatory marker genes in D-galactosamine-hepatotoxic rats. *Asian Pac J Trop Med* 2013;6:205-11.
- Mohseni R, Karimi J, Tavilani H, Khodadadi I, Hashemnia M. Carvacrol ameliorates the progression of liver fibrosis through targeting of Hippo and TGF- $\beta$  signaling pathways in carbon tetrachloride (CCl<sub>4</sub>)-induced liver fibrosis in rats. *Immunopharmacology and immunotoxicology* 2019;41:163-71.
- Penn JS, Henry MM, Tolman BL. Exposure to alternating hypoxia and hyperoxia causes severe proliferative retinopathy in the newborn rat. *Pediatr Res* 1994;36:724-31.
- Acun G, Ozdemir H, Sunamak O, Ozdemir ZU, Baskan E, Yazı M, *et al.* The effect of single-dose intraperitoneal bevacizumab on peritoneal adhesion formation. *Revista de Investigación Clínica* 2018;70:279-84.
- Selimoglu Sen H, Sen V, Bozkurt M, Turkcu G, Guzel A, Sezgi C, *et al.* Carvacrol and pomegranate extract in treating methotrexate-induced lung oxidative injury in rats. *Med Sci Monit* 2014;20:1983-90.
- Hartnett ME. The effects of oxygen stresses on the development of features of severe retinopathy of prematurity: Knowledge from the 50/10 OIR model. *Doc Ophthalmol* 2010;120:25-39.
- Gocmez SS, Yazir Y, Sahin D, Karadenizli S, Utkan T. The effect of a selective neuronal nitric oxide synthase inhibitor 3-bromo 7-nitroindazole on spatial learning and memory in rats. *Pharmacol Biochem Behav* 2015;131:19-25.
- Jung CY, Kim SY, Lee C. Carvacrol Targets AXL to inhibit cell proliferation and migration in non-small cell lung cancer cells. *Anticancer Res* 2018;38:279-86.
- Fan K, Li X, Cao Y, Qi H, Li L, Zhang Q, *et al.* Carvacrol inhibits proliferation and induces apoptosis in human colon cancer cells. *Anticancer Drugs* 2015;26:813-23.
- Dai W, Sun C, Huang S, Zhou Q. Carvacrol suppresses proliferation and invasion in human oral squamous cell carcinoma. *Onco Targets Ther* 2016;9:2297-304.
- Bozkurt M, Bodakci MN, Turkcu G, Kuyumcu M, Akkurt M, Sula B, *et al.* Protective effects of carvacrol against methotrexate-induced liver toxicity in rats. *Acta Chir Belg* 2014;114:404-9.
- Li Y, Xu JZ, Gu CX, Liu GL, Tian K. Carvacrol suppresses inflammatory responses in rheumatoid arthritis fibroblast-like synoviocytes. *J Cell Biochem* 2018. doi: 10.1002/jcb.28098.
- Guimaraes AG, Xavier MA, de Santana MT, Camargo EA, Santos CA, Brito FA, *et al.* Carvacrol attenuates mechanical hypernociception and inflammatory response. *Naunyn Schmiedeberg Arch Pharmacol* 2012;385:253-63.
- Ezhumalai M, Ashokkumar N, Pugalendi KV. Combination of carvacrol and rosiglitazone ameliorates high fat diet induced changes in lipids and inflammatory markers in C57BL/6J mice. *Biochimie* 2015;110:129-36.
- Mahmoodi M, Amiri H, Ayoobi F, Rahmani M, Taghipour Z, Ghavamabadi RT, *et al.* Carvacrol ameliorates experimental autoimmune encephalomyelitis through modulating pro- and anti-inflammatory cytokines. *Life Sci* 2019;219:257-63.
- Barnwal P, Vafa A, Afzal SM, Shahid A, Hasan SK, Alpashree, *et al.* Benzo (a) pyrene induces lung toxicity and inflammation in mice: Prevention by carvacrol. *Hum Exp Toxicol* 2018;37:752-61.
- Zeytun H, Ozkorkmaz EG. Effects of carvacrol in an experimentally induced esophageal burn model: Expression of VEGF and caspase-3 proteins. *J Invest Surg* 2019;1-9. doi: 10.1080/08941939.2019.1637484.
- Cornel S, Adriana ID, Mihaela TC, Speranta S, Algerino S, Mehdi B, *et al.* Anti-vascular endothelial growth factor indications in ocular disease. *Rom J Ophthalmol* 2015;59:235-42.
- Feng F, Cheng Y, Liu QH. Bevacizumab treatment reduces retinal neovascularization in a mouse model of retinopathy of prematurity. *Int J Ophthalmol* 2014;7:608-13.
- Lafreniere JD, Toguri JT, Gupta RR, Samad A, O'Brien DM, Dickinson J, *et al.* Effects of intravitreal bevacizumab in Gram-positive and Gram-negative models of ocular inflammation. *Clin Exp Ophthalmol* 2019;47:638-45.