

# Anatomical Characteristics and Variants of Prostatic Artery in Patients of Benign Hyperplasia Prostate by Digital Subtraction Angiography

Hien Nguyen Xuan<sup>1</sup>, Hoang Do Huy<sup>1</sup>, Ngoc Nguyen Thi Bich<sup>1\*</sup>, Giang Phan Hoang<sup>1</sup>, Khanh Le Van<sup>1</sup>, Trinh Nguyen Duy<sup>1</sup>, Tuan Anh Tran<sup>1</sup>, Vu Thi Nga<sup>2</sup>, Le Bui Minh<sup>3</sup>

<sup>1</sup>Bach Mai Radiology Center, Bach Mai Hospital, Hanoi Vietnam; <sup>2</sup>Institute for Research and Development, Duy Tan University, Danang, Vietnam; <sup>3</sup>NTT Hi-tech Institute, Nguyen Tat Thanh University, 300A Nguyen Tat Thanh St., Ward 13, District 4, Ho Chi Minh City, Vietnam

## Abstract

**Citation:** Nguyen Xuan H, Do Huy H, Nguyen Thi Bich N, Phan Hoang G, Le Van K, Nguyen Duy T, Anh Tran T, Thi Nga V, Bui Minh L. Anatomical Characteristics and Variants of Prostatic Artery in Patients of Benign Hyperplasia Prostate by Digital Subtraction Angiography. Open Access Maced J Med Sci. 2019 Dec 30; 7(24):4204-4208. <https://doi.org/10.3889/oamjms.2019.361>

**Keywords:** Prostatic artery; DSA; F. Carnevale classification

**\*Correspondence:** Hien Nguyen Xuan Bach, Mai Radiology Center, Bach Mai Hospital, Hanoi Vietnam, email: [ngochienduylocbm@gmail.com](mailto:ngochienduylocbm@gmail.com)

**Received:** 12-Apr-2019; **Revised:** 13-Jul-2019; **Accepted:** 14-Jul-2019; **Online first:** 13-Jul-2019

**Copyright:** © 2019 Hien Nguyen Xuan, Hoang Do Huy, Ngoc Nguyen Thi Bich, Giang Phan Hoang, Khanh Le Van, Trinh Nguyen Duy, Tuan Anh Tran, Vu Thi Nga, Le Bui Minh. This is an open-access article distributed under the terms of the Creative Commons Attribution-NonCommercial 4.0 International License (CC BY-NC 4.0)

**Funding:** This research did not receive any financial support

**Competing Interests:** The authors have declared that no competing interests exist

**List of abbreviations:** BPH: benign prostatic hyperplasia, CBCT: cone-beam computed tomography software, DSA: digital subtraction angiography, IIA: internal iliac artery, LUTS: lower urinary tract symptoms, PAE: prostatic artery embolisation, PA: prostatic artery, SVA: superior vesical artery

**AIM:** This work is aimed to describe anatomical features and variants of the prostatic artery (PA) using digital subtraction angiography (DSA).

**METHODS:** This is a descriptive statistic study. We reviewed the DSA of 348 patients, who had a PA embolisation to reduce the benign prostatic hyperplasia (BPH) symptoms at Radiology Department of Bach Mai Hospital from Oct – 2014 to Oct – 2018.

**RESULTS:** PA was found at 660 pelvic halves, of which 30 pelvic halves (4.5%) had two PAs, 630 pelvic halves had one PA. In terms of the origin of PA, in total 690 PAs, the percentage of type 1, 2, 3, 4 and 5 was successively 33.9%, 13.9%, 18.3%, 23.9% and 10.4%, respectively. Atherosclerosis of PA observed in 20.9%. The 'corkscrew' pattern was found in 30.4%. The average diameter of PA was  $1.5 \pm 0.34$ mm. The anastomosis of PA with surrounding arteries was common. PA may supply rectum (6.1%), seminal vesical (9.6%), bladder (5.2%), contralateral prostatic parenchyma (13.0%), surrounding soft-tissues (3.5%).

**CONCLUSION:** The common trunk with SVA superior vesical artery was the most common origin of PA. Anastomoses of PA with surrounding tissues were complex.

## Introduction

Benign prostatic hyperplasia (BPH) is a common disease in older men; it can cause lower urinary tract symptoms (LUTS). Prostatic artery embolisation (PAE) for BPH is a new mini-invasive treatment in Vietnam as well as in the world. It has demonstrated the therapeutic effect and safety in improving the symptoms of LUTS, reducing the prostatic volume [1], [2], [3], [4]. The key to the success of this method is to understand the anatomy of the prostatic artery. However, the anatomy of PA is very variable in number and the position of origin. In

male cadaveric studies, many researchers agreed that the origin of PA is very diverse and inconstant. Some authors also revealed cases of 2 or even 3 PAs in the same pelvic side [5-7]. Recent studies on the anatomy of PA on DSA had similar results. A single PA in each pelvic side was found in the majority of cases, a double vascularisation was rare [8], [9], [10]. The most common origin of PA is the branches of the anterior division of internal iliac artery (IIA) like an internal pudendal artery, common trunk with the superior vesical artery (SVA), obturator artery. The proportion of PA originating from the middle rectal artery, the accessory obturator artery, the gluteal artery, the accessory pudendal artery is rare. Carnevale was the first author to classify prostatic arteries by origin of

PA, which is relatively easy to apply [8]. According to this classification, the prostatic arteries divide into 5 different groups (Table 1).

**Table 1: Classification of PA by FC Carnevale et al., [8]**

Type	1	2	3	4	5
Origin of PA	Common trunk with SVA	The anterior division of IIA, inferior to SVA	Obturator artery	Internal pudendal artery	Less common origins

Also, PA has complex anastomosis with surrounding organs such as penis, rectum, seminal vesicle, and bladder [11]. Therefore, the risk of necrosis of surrounding organs during PAE is not negligible. Several researchers revealed the role of CBCT software in the PAE procedure [9], [12]. Currently, in Vietnam, Bach Mai hospital is the first place to apply this technique to treat BPH. However, to our knowledge, no study in Vietnam has been conducted to evaluate the anatomy of PA on the DSA. Therefore, the *purpose* of the present *study* is to (1) classify the prostatic arteries in Vietnamese by origin according to the classification of FC. Carnevale et al., and (2) describe other anatomical features of the prostatic artery, including anastomoses to adjacent arteries, number, shape, and diameter.

## Material and Methods

### Patient selection

This retrospective study was approved by the Department of Radiology, Bach Mai Hospital between 10/2014 and 10/2018.

### Inclusion criteria

1. Moderate to severe symptoms: IPSS index > 19 and the quality of life (QoL) > 3.
2. PSA index  $\leq 4$  ng/ml or PSA  $\leq 10$  ng/ml (the ratio free PSA/total PSA  $\geq 0.20$ , PSA density < 0.15).
3. No response to 6-month medical treatment.
4. The patient does not want surgery, accepting complications that may occur during the intervention.
5. Complete medical records
6. Successfully unilateral or bilateral PA catheterisation.

### Exclusion criteria

1. Prostatic cancer.
2. Urethral stenosis, narrowing of the bladder neck, large diverticula, and large stones.

3. General contraindications of angiography: serious infection, and liver failure, severe renal failure etc.

4. Active urinary infection.

5. Do not have enough medical records.

### Imaging modalities

We used Philips single-plane fluoroscopy (AluraHD) with Road-mapping and Cone-beam computed tomography software (CBCT). In this study, we only applied CBCT software in the following cases: suspect anastomosis of PA with surrounding organs, suspect whether or not the investigated artery supplies the prostate.

### Technical process

1. Put a bladder catheter with contrast product into a Foley balloon before performing the vascular procedure.

2. Angiogram of the internal iliac artery was performed with the ipsilateral oblique projection of 35-45 degrees and caudal-cranial angulation of 10 degrees.

3. Selective DSA of PA was used to measure the diameter of PA.

4. Injection of 1ml nitroglycerin 10% into PA was employed to evaluate better the anastomosis of PA.

5. Angiogram of PA was repeated to evaluate the anastomosis of PA.

6. In cases of suspected anastomosis of PA with surrounding organs, uncertain whether or not the investigated artery supplies the prostate, a CBCT was performed.

### Statistical analysis

All data are statistically processed and computerised under the SPSS program (version 16.0). Descriptive statistics with variables on anatomical characteristics of the prostate artery.

## Results

In the study period, 348 PAE procedures performed at Department of Radiology, Bach Mai hospital were included, the mean age of patients was 69.6 years, mean Qmax was 6.8 ml/s, and mean prostatic volume was 61.6 gram. In 348 these patients, 21 patients had an only unilateral selection of

prostatic artery due to occlusive atherosclerosis. Other 327 patients were treated with bilateral PAE. A total of 675 pelvic sides were studied.

In 675 pelvic sides, double vascularisation was found in 15 cases, a single PA in 660 pelvic sides. So, the number of PA in our study was 690, with the average diameter of PA was  $1.5 \pm 0.35$  mm (from 0.7 to 2.6 mm).

The most common origin of PA was the trunk with the SVA (33.9%), followed by internal pudendal artery (23.5%), and obturator artery (18.3%). The proportion of PA originating from the anterior division of IIA and other positions was 10.4% and 13.9%, respectively (Table 2).

**Table 2: Classification of PA**

Type	1	2	3	4	5	Total
N	234	72	126	162	96	690
Incidence (%)	33.9	10.4	18.3	23.5	13.9	100

An identifying feature of PA on DSA is the corkscrew pattern. However, in this study, the typical feature of PA was found in only 30.4% (Table 3).

**Table 3: Incidence of “corkscrew pattern” of PA**

Shape	Presence of the corkscrew pattern	Absence of the corkscrew pattern	Total
N	210	480	690
%	30.4	69.6	100

Atherosclerosis of PA can also be observed by DSA. Atherosclerosis is defined as a defect of contrast in the artery. In our study, atherosclerosis was seen in 20.9% of cases (Table 4).

**Table 4: Incidence of the atherosclerosis of PA**

Atherosclerosis	Presence	Absence	Total
N	144	546	690
%	20.9	79.1	100

The most common anastomosis was seen with the opposite PA (13%). The remaining types of anastomosis had lower rates like with seminal vesicle (9.6%), penis (8.7%), rectum (6.1%), bladder (4.3%), and soft tissue (3.5%) (Table 5).

**Table 5: Anastomosis between PA and surrounding arteries**

Anastomosis	Bladder	Seminal vesicle	Penis	Rectum	Soft tissue	Contralateral prostate tissue
N	30	66	60	42	24	90
%	4.3	9.6	8.7	6.1	3.5	13

## Discussion

Regarding the origin of prostatic arteries, based on the classification of FC. Carnevale, in this study, the most popular origin of the PA was the common trunk with SVA (33.9%), followed by internal pudendal artery (23.5%). This result is similar to the

study of FC. Carnevale and T. Bilhimet al., [8], [10]. According to a study by Wang et al., the most common origin of PA was also common trunk with SVA (37.1%) but followed by the anterior pelvic artery branch (31.1%), then the internal pudendal artery (24.2%) [9].

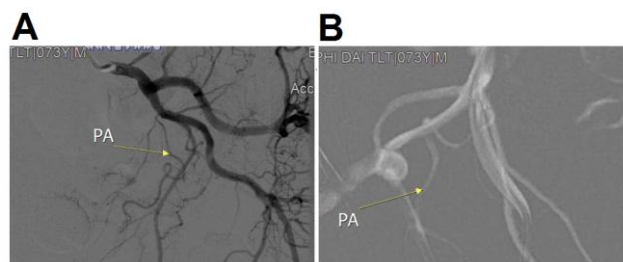


Figure 1: Prostatic arterial type 1 (A) and type 2 (B)

The less common origins of the PA were the middle rectal artery, the accessory obturator artery, the gluteal artery, and the accessory pudendal artery. However, in this study, the incidence of these PA types was relatively high (13.9%). There were 2 cases in which PA was originated from the accessory obturator artery—a branch of the external iliac artery (1.7%). According to T. Bilhim et al., the ratio of PA originated from the external iliac artery was 1.8% [13]. Thus, in the case of absence of PA on internal iliac artery angiogram, catheterisation of the external iliac artery is necessary to find PA from the accessory obturator artery.

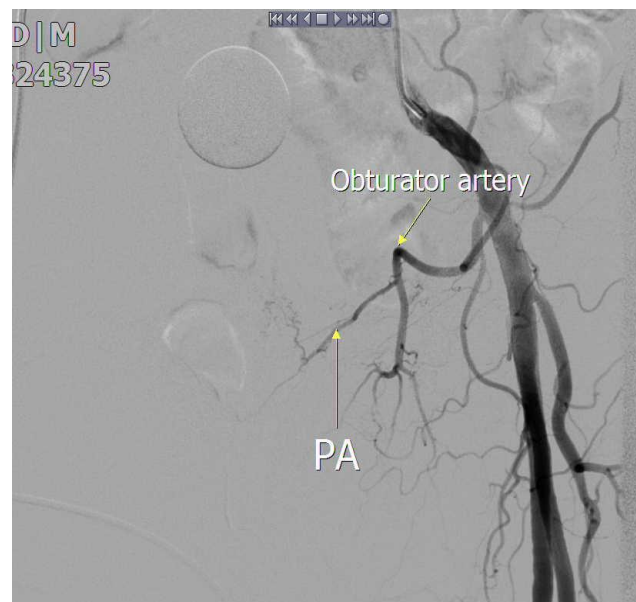


Figure 2: PA type 5, originating from the accessory obturator artery

Regarding the number of independent PA, there was one PA in 95.5% of pelvic sides and two independent PAs in the other 4.5%, for a total of 115 PA. This result was similar to the study done by Wang and FC Carnevale et al., [8], [9]. However, according to T. Bilhim, the incidence of two independent ipsilateral PA was very high (43%) [10]. Mean

diameter of PA was 1.5 mm. Therefore, the types of micro-catheters used must also be small in size. We always used microcatheter types with diameter  $\leq$  2F (equivalent to 0.67 mm).

The presence of the corkscrew pattern was found in 30.4%. It is unlike the uterine artery, which always has the corkscrew pattern on DSA imaging. This result was similar to the study of T. Bilhim [10]. Although less common, however, the presence of the corkscrew pattern can be considered as a suggestion of PA on DSA. Another difficulty in the embolisation of PA is atherosclerosis. Atherosclerosis was found in 20.9% of PA, most commonly in the proximal course of PA.

About anastomoses of PA, we saw them in 21% of cases. This result was similar to the study of Wang (22.6%). However, that rate was lower than those in studies done by T. Bilhim and JM. Pisco et al., (60%) [9], [10], [11].

In our study, the most common anastomosis was with contralateral PA (13%), followed by the penis (8.7%), bladder (4.3%), rectum (6.1%), seminal vesicle (9.6%), and soft tissue (3.5%). However, the presence of anastomosis of PA is not a contraindication to the embolisation. In the presence of small-sized anastomosis, a slow infusion under the control of fluoroscopy and usage of big embolisation particles ( $>$  200  $\mu$ m) may avoid the complication of non-target ischemia to the surrounding tissues (bladder, rectum, anus, or corpus cavernosum).

In cases with significant of PA anastomosis, before injecting particles for embolisation, maybe we need to cut off anastomosis by coils or other materials.

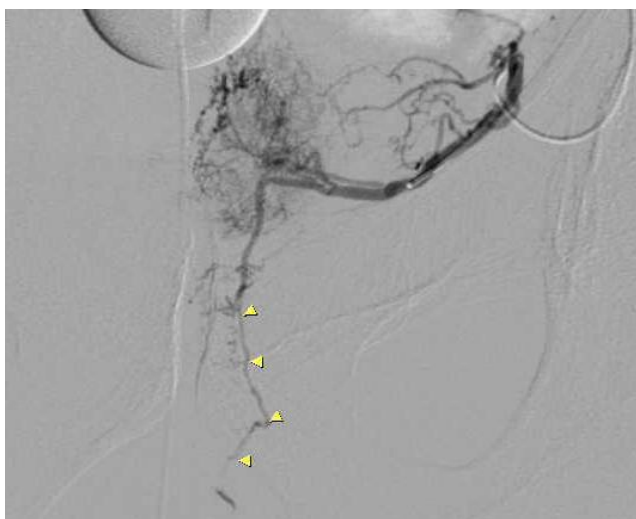


Figure 3: Anastomosis of PA with penis in AP views (arrowhead)

This study still has limitations. First, we acknowledge the retrospective nature of our patient group from a single centre. Second, we do not systematically use CBCT software to evaluate the anastomosis of PA, due to the risk of increasing the

irradiation dose and increasing the procedure times. This may affect the assessment of anastomosis of PA.

In conclusion, we found that the most popular origin of PA was the common trunk with SVA, followed by the interne pudendal artery and obturator artery. The anastomosis of PA was very diverse; it is possible to supply blood to bladder, rectum, seminal vesicles, and contralateral prostatic tissue. Therefore, perfect knowledge of PA is fundamental to assure the success of the procedure, avoid complications, and reduce procedure times and radiation exposure.

## Ethical Statement

This research was approved by the scientific ethics committee of Bach Mai hospital and allowed to be implemented at the Department of Radiology of Bach Mai hospital.

## Informed Consent

The patients were consulted and agreed to participate in the study. Informed consent was obtained from the patient included in the study.

## Acknowledgement

We would like to thank Ms Bui Nhat Le (Faculty of Clinical Pharmacy, University of Pharmacy, Hanoi, Vietnam) for checking and improving the English in the manuscript.

## References

1. Christidis DCE, Ly V, et al. Prostatic artery embolization for benign prostatic obstruction: assessment of safety and efficacy. *World J Urol.* 2018; 36: 575-584. <https://doi.org/10.1007/s00345-018-2220-z> PMID:29445846
2. DeMeritt JS, Elmasri FF, Esposito MP, Rosenberg GS. Relief of benign prostatic hyperplasia-related bladder outlet obstruction after transarterial polyvinyl alcohol prostate embolization. *Journal of Vascular and Interventional Radiology.* 2000; 11(6):767-70. [https://doi.org/10.1016/S1051-0443\(07\)61638-8](https://doi.org/10.1016/S1051-0443(07)61638-8)
3. Ray AF, Powell J, Speakman MJ, Longford NT, DasGupta R, Bryant T, Modi S, Dyer J, Harris M, Carolan-Rees G, Hacking N. Efficacy and safety of prostate artery embolization for benign prostatic hyperplasia: an observational study and propensity-matched comparison with transurethral resection of the

- prostate (the UK-ROPE study). *BJU international*. 2018; 122(2):270-82. <https://doi.org/10.1111/bju.14249> PMID:29645352
4. Bagla S, Smirniotopoulos J, Orlando J, van Breda A. Safety and Efficacy of Prostate Artery Embolization in Small-Volume Benign Prostatic Hyperplasia. *Journal of Vascular and Interventional Radiology*. 2015; 26(1):148-9. <https://doi.org/10.1016/j.jvir.2014.10.032>
5. Ambrósio JD, De Almeida JS, De Souza A. Origin of prostatic arteries in man. *Rev Paul Med*. 1980; 96(3-4):52.
6. Bouissou H, Talazac A. Arterial vascularization of the normal and the pathological prostate. In *Annales d'anatomie pathologique*. 1959; 4(1):63-79.
7. Garcia-Monaco R, Garategui L, Kizilevsky N, Peralta O, Rodríguez P, Palacios-Jaraquemada J. Human cadaveric specimen study of the prostatic arterial anatomy: implications for arterial embolization. *Journal of Vascular and Interventional Radiology*. 2014; 25(2):315-22. <https://doi.org/10.1016/j.jvir.2013.10.026> PMID:24325930
8. de Assis AM, Moreira AM, de Paula Rodrigues VC, Harward SH, Antunes AA, Srougi M, Carnevale FC. Pelvic arterial anatomy relevant to prostatic artery embolisation and proposal for angiographic classification. *Cardiovascular and interventional radiology*. 2015; 38(4):855-61. <https://doi.org/10.1007/s00270-015-1114-3> PMID:25962991
9. Wang MQ, Duan F, Yuan K, Zhang GD, Yan J, Wang Y. Benign prostatic hyperplasia: cone-beam CT in conjunction with DSA for identifying prostatic arterial anatomy. *Radiology*. 2017:282. <https://doi.org/10.1148/radiol.2016152415> PMID:27467466
10. Bilhim T, Pisco JM, Tinto HR, Fernandes L, Pinheiro LC, Furtado A, Casal D, Duarte M, Pereira J, Oliveira AG, O'Neill JE. Prostatic arterial supply: anatomic and imaging findings relevant for selective arterial embolization. *Journal of Vascular and Interventional Radiology*. 2012; 23(11):1403-15. <https://doi.org/10.1016/j.jvir.2012.07.028> PMID:23101913
11. Bilhim T, Tinto HR, Fernandes L, Pisco JM. Radiological anatomy of prostatic arteries. *Techniques in vascular and interventional radiology*. 2012; 15(4):276-85. <https://doi.org/10.1053/j.tvir.2012.09.006> PMID:23244724
12. Bagla S, Rholl KS, Sterling KM, van Breda A, Papadouris D, Cooper JM, van Breda A. Utility of cone-beam CT imaging in prostatic artery embolization. *Journal of Vascular and Interventional Radiology*. 2013; 24(11):1603-7. <https://doi.org/10.1016/j.jvir.2013.06.024> PMID:23978461
13. Bilhim T, Pisco J, Pinheiro LC, Tinto HR, Fernandes L, Pereira JA. The role of accessory obturator arteries in prostatic arterial embolization. *Journal of Vascular and Interventional Radiology*. 2014; 25(6):875-9. <https://doi.org/10.1016/j.jvir.2014.03.005> PMID:24857944