

## BRIEF COMMUNICATION

**Cervical dystonia caused by focal putaminal ischemia**Lars Dinkelbach<sup>1,2</sup>, Christian Johannes Hartmann<sup>1</sup>, Christian Mathys<sup>3</sup>, Lars Wojtecki<sup>1,2</sup>, Daniel Hänggi<sup>4</sup> & Martin Südmeyer<sup>1,2</sup><sup>1</sup>Department of Neurology, Medical Faculty, University Düsseldorf, Düsseldorf, Germany<sup>2</sup>Institute of Clinical Neuroscience and Medical Psychology, Heinrich Heine University, Düsseldorf, Germany<sup>3</sup>Department of Diagnostic and Interventional Radiology, Medical Faculty, University Düsseldorf, Düsseldorf, Germany<sup>4</sup>Department of Neurosurgery, Medical Faculty, University Düsseldorf, Düsseldorf, Germany**Correspondence**

Martin Südmeyer, Department of Neurology and Institute of Clinical Neuroscience and Medical Psychology, Heinrich Heine University, Moorenstrasse 5, D-40225 Düsseldorf, Germany. Tel: +49-211/81-16756; Fax: +49-211/81-16525; E-mail: martin.suedmeyer@uni-duesseldorf.de

**Funding Information**

No funding information provided.

Received: 24 June 2015; Revised: 18 August 2015; Accepted: 18 August 2015

*Annals of Clinical and Translational Neurology* 2015; 2(11): 1029–1031

doi: 10.1002/acn3.250

**Abstract**

We describe a 48-year-old woman with putaminal gliosis and a sphenoid wing meningioma at the left, who developed dystonia restricted to cervical regions. We propose the following causal chain: the meningioma led to an occlusion of a lenticulo-striatal branch of the middle cerebral artery that caused ventral putaminal ischemia and finally resulting in symptomatic dystonia. The previously reported relevance of the infarcted regions to the pathophysiology of dystonia supports this assumption. Implications for the diagnostic procedure of dystonia will be discussed.

**Introduction**

Dystonia is a group of movement disorders characterized by involuntary, repetitive movements, or abnormal postures.<sup>1</sup> A recently published consensus suggests a bi-axial classification with clinical characteristics (focal, segmental, hemidystonia, generalized) on the first and the etiology (primary, secondary) on the second axis.<sup>2</sup>

The current pathophysiological concept of dystonia assumes that abnormal alterations in the sensorimotor integration accompanied by an increase in motor cortex excitability finally leads to sustained muscle contractions. The abnormalities were charged to be secondary to a shortage of inhibitory control in the basal ganglia.<sup>3</sup> This approach is in line with the lesion analyses which emphasize the particular, albeit not exclusive, relevance of striatal or thalamic regions for the etiology of dystonia.<sup>4,5</sup>

In 25<sup>6</sup>–40%<sup>7</sup> of all patients, a secondary dystonia is assumed. Causes differ widely from tardive dystonia secondary to neuroleptic treatment<sup>7</sup> to vascular etiologies as stroke<sup>8,9</sup> or subdural hematoma.<sup>10</sup> Neoplasms are a

known source of secondary dystonia as well: reported cases focused on tumors in children,<sup>4,11–15</sup> whereas only four cases in adults have been described yet<sup>4,12,14,16</sup> (for a complete overview of all identified causes for secondary dystonia see [17]).

Here, we report a case of secondary cervical dystonia caused by ventral putaminal ischemia after vascular occlusion due to a sphenoid wing meningioma.

**Case Report**

In 2007, a 48-year-old woman presented at an outpatient medical center after developing an antero- and laterocollis with a tilt of 45° to the right, a hypertonic right sternocleidomastoid and a dystonic lifted shoulder, resulting in a Tsui Score of 8 (solely considering cervical symptoms, range from 0 to 25). The patient reported a slight relief under usage of a sensory trick maneuver, cervical symptoms seemed to improve by touching the right shoulder. There was no relevant medical history and family history was negative for movement disorders. Except arterial

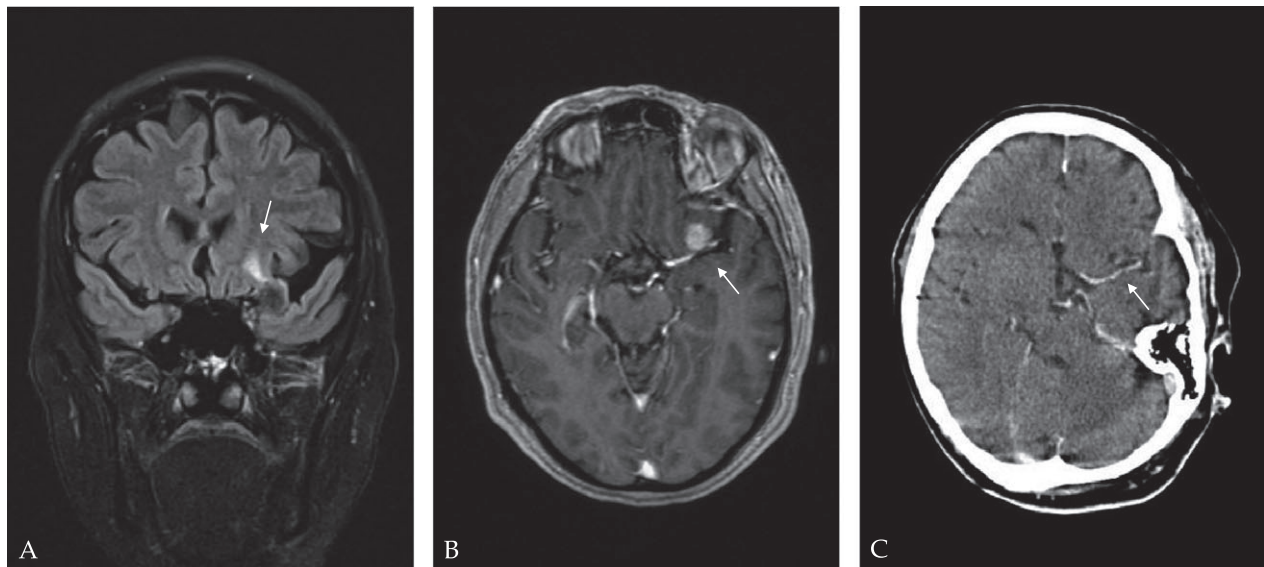
hypertension, no other comorbidities were reported. Cervical dystonia was diagnosed and regular injections with abobotulinum toxin type A (Dysport<sup>®</sup>, Ipsen Ltd, Paris, France, 800 MU) were conducted at intervals of 3 months, resulting in a good but dropping response. However, a cranial magnetic resonance imaging (MRI) was not performed. Within 3 years, an outspread of dystonic symptoms to the right dorsal trunk became manifest. Therefore, the patient was admitted to our medical care center to consider a treatment with deep brain stimulation (DBS).

Extensive laboratory diagnostics of the patients' blood and cerebrospinal fluid revealed no indications for inflammatory or neurodegenerative processes. Doppler sonography of intra and extracranial vessels and electroencephalography were unremarkable. Cranial MRI revealed a circumscribed gliosis of the left ventral putamen, adjacent to the left capsula externa (see Fig. 1A) that corresponds to the supply area of a lenticulo-striatal branch of the middle cerebral artery. Further, a 13 × 15 mm sized extra-axial mass was observed at the left sphenoid wing with homogeneous contrast enhancement (see Fig. 1B) and direct spatial relation to the lenticulo-striatal branches of the middle cerebral artery. We decided to fully resect the mass next to the infarct via a pterional approach. Histological examination led to the pathological diagnosis of a meningeothelial psammomatous meningioma (WHO-I).

Postoperatively, the patient noticed no more progression of truncal dystonic symptoms. During a 3-year clinical follow-up, the cervical component of dystonia (Tsui Score of 8) remained stable. After an attempt with anticholinergic medication (trihexyphenidyl) proved ineffective, the treatment with abobotulinum toxin type A was resumed, leading to a moderate benefit (see Video S1).

## Discussion

The typical clinical characteristics and the absence of additional neurologic symptoms initially led to the diagnosis of primary dystonia. The presence of sensory tricks seems to be rare in patients with secondary dystonia,<sup>6</sup> supporting the initial assumption. However, the lesions found upon structural brain imaging clearly suggest a secondary dystonia due to a meningioma-induced ventral putaminal ischemia. The ischemic region presumably affected sensorimotor pathways in the striatum which were accounted for being a pathophysiological substrate of dystonia.<sup>3</sup> This conclusion is in line with a case of left segmental dystonia affecting the face and hand after embolic occlusion of the middle cerebral artery.<sup>5</sup> A direct genesis of dystonia by the meningioma as previously reported in a case by Soland and coworkers<sup>16</sup> seems to be implausible as the meningioma described here was distinctly smaller, just slightly infiltrated the adjacent



**Figure 1.** (A) Preoperative coronal magnetic resonance imaging (FLAIR, TR: 9000 msec, TE: 118 msec) showing a circumscribed gliosis of the ventral putamen, corresponding to the area of a lenticulo-striatal branch. (B) Axial MRI (contrast-enhanced T1-MPRAGE, TR: 1900 msec, TE: 3.37 msec) reveals a homogeneously enhancing meningioma located at the left sphenoid wing comprising the left middle cerebral artery in the height of lenticulo-striatal branches. (C) Axial CT showing the middle cerebral artery after successful tumor resection.

cortex, and was not accompanied by a perifocal edema which could affect the basal ganglia. However, a coincidental occurrence of primary dystonia cannot fully be excluded.

The diagnostic criteria of the European Federation of Neurological Societies stated the need of structural brain imaging as MRI in the diagnosis of primary dystonia for the screening of secondary forms.<sup>18</sup> Geyer and Bressman suggest to perform brain imaging as an obligatory part of the diagnosis if the patient is older than 26 or, if younger, after a hereditary genesis can be ruled out.<sup>17</sup> Our case emphasizes the necessity of structural brain imaging in the diagnosis of dystonia – particularly with regard to a potentially treatable underlying cause as described here.

Due to the fact that several studies indicate a weaker effect of DBS for the treatment of secondary dystonia in comparison to primary forms,<sup>18,19</sup> conventional treatment regimen with botulinum toxin was preferred.

In summary, our case provides a new facet for the pathophysiological substrate of dystonia consisting of a putaminal lesion induced by a neoplasm–vascular cascade which underlines the need for a cranial MRI in the diagnosis of dystonia.

## Acknowledgments

L. D. authored this case report in partial fulfillment of the requirements for an M.D. thesis.

## Conflict of Interest

None declared.

## References

1. Tarsy D, Simon DK. Dystonia. *N Engl J Med* 2006;355:818–829.
2. Albanese A, Bhatia K, Bressman SB, et al. Phenomenology and classification of dystonia: a consensus update. *Mov Disord* 2013;28:863–873.
3. Breakefield XO, Blood AJ, Li Y, et al. The pathophysiological basis of dystonias. *Nat Rev Neurosci* 2008;9:222–234.
4. Marsden C, Obeso J, Zarranz J, Lang A. The anatomical basis of symptomatic hemidystonia. *Brain* 1985;108:463–483.
5. Pettigrew LC, Jankovic J. Hemidystonia: a report of 22 patients and a review of the literature. *J Neurol Neurosurg Psychiatry* 1985;48:650–657.
6. Svetel M, Ivanović N, Marinković J, et al. Characteristics of dystonic movements in primary and symptomatic dystonias. *J Neurol Neurosurg Psychiatry* 2004;75:329–330.
7. Andrade LA, Ferraz HB. Idiopathic dystonia clinical, profile of 76 Brazilian patients. *Arq Neuropsiquiatr* 1992;50:426–432.
8. Molho ES, Factor SA. Basal ganglia infarction as a possible cause of cervical dystonia. *Mov Disord* 1993;8:213–216.
9. Russo LS. Focal dystonia and lacunar infarction of the basal ganglia: a case report. *Arch Neurol* 1983;40:61–62.
10. Nobbe FA, Krauss JK. Subdural hematoma as a cause of contralateral dystonia. *Clin Neurol Neurosurg* 1997;99:37–39.
11. Caress JB, Nohria V, Fuchs H, Boustany R-M. Torticollis acquired in late infancy due to a cerebellar gangliocytoma. *Int J Pediatr Otorhinolaryngol* 1996;36:39–44.
12. Krauss JK, Seeger W, Jankovic J. Cervical dystonia associated with tumors of the posterior fossa. *Mov Disord* 1997;12:443–447.
13. Kumandaş S, Per H, Gümüş H, et al. Torticollis secondary to posterior fossa and cervical spinal cord tumors: report of five cases and literature review. *Neurosurg Rev* 2006;29:333–338.
14. LeDoux MS, Brady KA. Secondary cervical dystonia associated with structural lesions of the central nervous system. *Mov Disord* 2003;18:60–69.
15. Narbona J, Obeso J, Tunon T, et al. Hemi-dystonia secondary to localised basal ganglia tumour. *J Neurol Neurosurg Psychiatry* 1984;47:704–709.
16. Soland V, Evoy F, Rivest J. Cervical dystonia due to a frontal meningioma. *Mov Disord* 1996;11:336–337.
17. Geyer HL, Bressman SB. The diagnosis of dystonia. *Lancet Neurol* 2006;5:780–790.
18. Albanese A, Asmus F, Bhatia K, et al. EFNS guidelines on diagnosis and treatment of primary dystonias. *Eur J Neurol* 2011;18:5–18.
19. Andrews C, Aviles-Olmos I, Hariz M, Foltynie T. Which patients with dystonia benefit from deep brain stimulation? A metaregression of individual patient outcomes. *J Neurol Neurosurg Psychiatry* 2010;81:1383–1389.

## Supporting Information

Additional Supporting Information may be found in the online version of this article:

**Video S1.** The described cervical dystonia with an antero- and laterocollis to the right, before and 3 years after tumor resection.