

The current management of alveolar soft part sarcomas

Xiaojing Chang, MD^{a,*}, Yuehong Li, MD^b, Xiaoying Xue, MD^a, Huandi Zhou, MS^a, Liubing Hou, MS^a

Abstract

Objective: Alveolar soft part sarcomas (ASPS) which has high potential ability of metastasis, is a rare and slowly growing malignant tumor, and mainly primary localized in limbs. To date, little is known about the best treatment of ASPS. This study aims to review the current management and advance of ASPS.

Methods: WANFANG MED ONLINE, CNKI, and NCBI PUBMED were used to search literature spanning from 1963 to 2020, and all cases of ASPS about “ASPS, diagnosis, treatment, surgery, radiotherapy, chemotherapy, target therapy or immune therapy” with detailed data were included.

Results: Complete surgical resection remained the standard management strategy, radiotherapy was reported to be used for the patients of micro- or macroscopical incomplete residue or the surgical margin was questionable. Chemotherapy was controversial. Some target drugs and immune checkpoint inhibitors had produced antitumor activity.

Conclusion: Complete surgical resection is the cure treatment for ASPS, and adjuvant chemotherapy is not recommended excepted clinical trials. For the patients with micro- or macroscopical incomplete residue, radiotherapy should be appreciated. Furthermore, for recurrence, distant metastasis, and refractory of ASPS, combination therapy, especially combination with multiple target agents and/or immune checkpoint inhibitors may prolong survival time.

Abbreviations: CR = complete response, OS = overall survival, PD = progress disease, PFS = progression-free survival, PR = partial response, SD = stable disease.

Keywords: ASPS, chemotherapy, immune therapy, radiotherapy, target therapy

1. Introduction

Alveolar soft part sarcoma (ASPS) is a very rare soft tissue sarcoma, accounting for <1% of the all soft tissue tumor, and the 5-year overall survival (OS) is 56%.^[1] It mainly occurs in children and young adults, a few cases also present in elderly patients and pregnant women.^[2,3] Female patients are more than male patients, and the proportion is about 2:1.^[4] In children, the most common site of origin is the tongue and orbit of head-and-neck region, very few occurs in the penis.^[5] While, in adults patients,

majority occur in deep areas of lower extremities and trunk, especially in thigh, but a few are also present in orbital, flexure tendon, breasts, lingual and gastrointestinal tract, and even in head.^[2,6-9] Since ASPS has no related symptoms in early time, most patients complain with a painless mass as a chief complaint, few patients also complain pain and discomfort accompanied the growing mass.^[4] ASPS has high potential ability of metastasis, lung, brain and bone metastases are common. Noteworthy, its brain metastasis ability is higher compared with other soft tissue sarcomas.

To date, due to its rarity, most reports of ASPS are case reports or small series. This narrative review was based on WANFANG MED ONLINE, CNKI, and NCBI PUBMED search spanning from 1963 to 2020, and all cases of ASPS about “ASPS, diagnosis, treatment, surgery, radiotherapy, chemotherapy, target therapy or immune therapy” with detailed data were included. Cases were excluded if they were duplicated or their information was too generalized.

2. Diagnosis

2.1. Imageological examination

ASPS which grows slowly is usually diagnosed as benign tumor at the first medical examination. CT (Computed tomography) imaging shows an enhancing mass lesion with edge rule, and tortuous prominent blood vessels. On MRI imaging, ASPS usually typically shows high signal intensity in T1- and T2-weighted scan, and features internal and external multilobulated signal change. In contrast-enhanced MRI imaging, the mass shows intense enhancement and multiple peritumoral and

Editor: Shalini Tanwar.

The authors have no funding and conflicts of interests to disclose.

Data sharing not applicable to this article as no datasets were generated or analyzed during the current study.

^aDepartment of Radiotherapy, the Second Hospital of Hebei Medical University, Shijiazhuang, China, ^bDepartment of Pathology, the Second Hospital of Hebei Medical University, Shijiazhuang, China.

* Correspondence: Xiaoying Xue, Department of Radiotherapy, the second Hospital of Hebei Medical University, 050000, Shijiazhuang, China (e-mail: xxy6412@163.com).

Copyright © 2021 the Author(s). Published by Wolters Kluwer Health, Inc. This is an open access article distributed under the terms of the Creative Commons Attribution-Non Commercial License 4.0 (CCBY-NC), where it is permissible to download, share, remix, transform, and buildup the work provided it is properly cited. The work cannot be used commercially without permission from the journal.

How to cite this article: Chang X, Li Y, Xue X, Zhou H, Hou L. The current management of alveolar soft part sarcomas. *Medicine* 2021;100:31(e26805).

Received: 23 March 2021 / Received in final form: 24 May 2021 / Accepted: 12 July 2021

<http://dx.doi.org/10.1097/MD.00000000000026805>

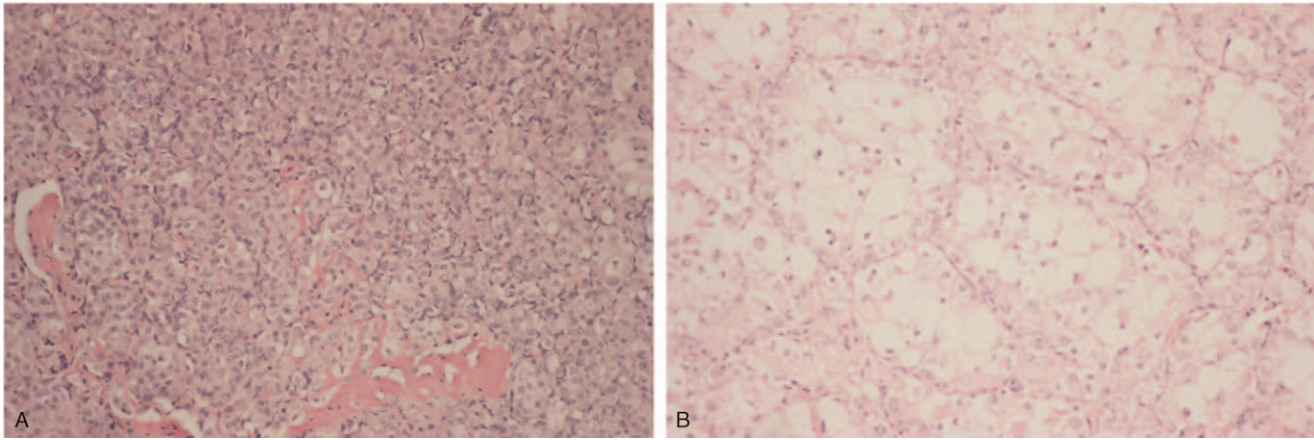


Figure 1. Photomicrograph of a 18-year old female patient with the primary tumor of the right thigh in our institution, which was approved by the institutional review board of Hebei Medical University and patient consent forms was obtained. The neoplasm showed the characteristic features of ASPS. A. $\times 100$; B. $\times 400$.

intratumoral tortuous signal voids. The part with a high signal in T1-weighted MRI has low blood flow rate, and the part with multilobulated signal change in T1-weighted and T2-weighted MRI shows high blood flow rate, relatively.^[10–12]

2.2. Molecular pathology

Pathological photomicrograph shows that tumor cells which are arranged in alveolar or organoid pattern containing oval vesicular nuclei and abundant eosinophilic cytoplasm (Fig. 1, a photomicrograph of a 18-year old female patient with the primary tumor of the right thigh in our institution, which was approved by the institutional review board of Hebei Medical University and patient consent forms was obtained). In almost all cases, ASPS is characterized with rearrangement of TFE3 and der (17)t (X;17)(p11;q25), leads to ASPSCR1-TFE3 fusion gene.^[13,14]

ASPS is easy to be misdiagnosed as arteriovenous malformation and benign angioma, early biopsy is essential to differentiate it. Furthermore, perivascular epithelioid cell tumors (PEComas) which are a distinct set of mesenchymal tumors also with strong TFE3 expression and nested pattern morphologically mimicked ASPS in partly, and oncologist should avoid misdiagnosis.^[15]

3. Therapeutic methods

To date, complete surgical resection remains the standard management strategy, whereas, radiotherapy and chemotherapy are controversial, target drugs and immune checkpoint inhibitors have produced antitumor activity.

3.1. Surgery

Surgery is considered the first-line treatment in localized ASPS, complete surgical excision is the mainstay and the most effective therapeutic option, especially for primary intracranial and spinal ASPS.^[9,16] Surgical resection margin influences the prognosis, and wide resection for ASPS is strongly recommended. The 5-year OS rate of wide tumor resection could reached 67.5%.^[17] For R0 resection, the 3- and 5-year survival was 100% and 80% respectively, which were both higher than those of R1 or R2. It

has to be noted, tumor size is also a prognosis factor. For patients with tumor size smaller than 50 mm, the survival was better than those with tumors size more than 50 mm (70% vs 42.9%) at final follow up.^[4] For patients with tumor size less than 50 mm, the 5-year, 10-year, 15-year survival rate were 72%, 65%, and 65%, respectively, which was better than those with tumor size larger than 50 mm (46%, 9%, and 0%, respectively).^[18] In a retrospective review of 26 consecutive ASPS patients, 20 patients underwent surgical excision (R0 18, R1 plus radiotherapy 2), no local recurrence was seen in these patients during a mean follow-up period of 81 months.^[19] Thus, extensive resection of the mass, especially R0 resection, is considered as the most effective treatment of ASPS.

3.2. Radiotherapy

Early studies reported no significant benefit from radiotherapy, more recent studies showed radiotherapy could prevent or reduce local recurrence (Table 1). Preoperative radiotherapy which is recommended for the treatment of STS in NCCN guideline could improve R0 resection rate and prolong OS for patients with extremity and retroperitoneal soft tissue sarcoma (STS) undergoing surgical resection.^[19,20] To date, radiotherapy was reported to be mainly used for the patients of micro- or macroscopical incomplete residue or the surgical margin with questionable. Hei et al^[7] reported 8 cases of orbital ASPS, 6 of those received postoperative radiotherapy, among them 5 cases demonstrated well prognosis with no evidence of local recurrence or metastasis during the follow-up period (range:3–61 months). For primary intracranial ASPS or brain metastasis of ASPS, gamma knife radiotherapy or SBRT could achieve satisfactory local control, the median progression-free survival (PFS) achieved 12 months after gamma knife radiotherapy.^[21]

For radiation doses, researchers recommended 50Gy following by boost to the tumor area with 10 to 16 Gy for negative margins, 16 to 18 Gy boost for microscopically positive margins and 20 to 26 Gy for gross residual disease of soft tissue sarcoma of trunk after operation,^[22–24] which had been recommend in NCCN guide (National comprehensive Cancer Network, <https://www.nccn.org>). For multiple brain metastases, some researchers administered palliative whole-brain radiotherapy with 30 Gy in

Table 1
Radiotherapy dose in ASPS.

Year	Author	Location	Dose	Effect
2016	Chen Z et al	Multiple brain metastases	Whole-brain radiotherapy with 30 Gy	Prognosis was poor
2014	Emmez H	Primary intracerebral ASPS	54 Gy (RT+ chemotherapy after gross total excision)	PFS achieved 45 mo
2014	Mullins BT	Larynx	Total dose of 59.4 Gy	DFS for 4 mo
2014	Mullins BT	Parotid gland	Total dose of 63.4 Gy	DFS for 168 mo
2014	Meng N	Recurrent ASPS of the tongue	Iodine-125	achieved CR +recurrent-free survival >30 mo
2013	Nakao K	The upper third of the vagina	carbon-ion RT with 67.2 Gy in 16 fractions	without recurrence for 20 mo
2010	Hanzer M	Single lung metastasis of ASPS	Hyperfractionated local RT with total dose of 44.8 Gy	
2008	Sidi et al	The left thigh	50.4 Gy followed by a boost to the tumour area with 9 Gy (after chemotherapy + surgery)	Not well (bilateral pulmonary metastases immediately appeared)

10 fractions, but prognosis was poor because of the widespread metastases in advanced cases.^[25] For single lung metastasis of ASPS, hyperfractionated local radiotherapy could be considered with total dose of 44.8 Gy.^[26]

Carbon-ion radiotherapy also showed satisfactory effects. There was a case report that a 9-year old girl who was diagnosed as ASPS with the tumor locating in the upper third of the vagina, received carbon-ion radiotherapy with 67.2 Gy in 16 fractions at the part of the tumor adhered to the posterior pubis which was residual after resection, the tumor decreased gradually without recurrence for 20 months, the patient had not any adverse effects.^[27] In addition, iodine-125 may be beneficial for some recurrent ASPS patients. A report showed a 4-year-old boy with recurrent ASPS of the tongue who received iodine-125 seed brachytherapy under ultrasound guidance, achieved complete response (CR) and had a recurrent-free survival of >30 months.^[28] Thus, for some local lesions of ASPS, iodine-125 could be considered.

3.3. Chemotherapy

To date, the efficacy of chemotherapy on ASPS was reported ineffective.^[8,21,29–32] Reichardt et al^[29] retrospectively analyzed the response on first-line chemotherapy in 68 patients of ASPS, results showed 51% was progress disease (PD), 41% was stable disease (SD), only 4% of patients was CR. It means that chemotherapeutic regimens lack efficacy in ASPS. They suggested ASPS patients should not be treated with chemotherapy outside of controlled clinical trials. Flores et al^[30] analyzed the clinical data of 69 children and young adults less than 30 years old with ASPS, they found ASPS was resistant to cytotoxic chemotherapy. In the EpSSG NRSTS 2005 study, 4 of 22 patients with ASPS received chemotherapy of ifosfamide and doxorubicin, there were no responses.^[31]

Whereas, few case reports demonstrated the well clinical efficacy of chemotherapy. Asokan et al^[33] reported an 18-year-old female of ASPS combined pulmonary metastasis received 6 cycles of chemotherapy with adriamycin, cyclophosphamide and vincristine. No locoregional recurrence or metastasis elsewhere was found during the 11 months follow-up. Qiu et al^[5] reported an unusual case of ASPS involving the penis of a 3-year-old boy who just received a partial penectomy, received 6 months of chemotherapy with ifosfamide, epirubicin, mesna and dacarbazine. PFS was 28 months. These were similar to Lin YK's study^[17] who performed a retrospective study enrolling 13 ASPS patients, 7 of those patients received chemotherapy with an alkylating agent (ifosfamide) and doxorubicin, the 5-year survival rate was

66.7%. Emmez et al^[22] reported a primary intracerebral alveolar soft part sarcoma in an 11-Year-Old Girl who received whole brain radiotherapy and 9 cycles of chemotherapy using the regimen of ifosfamide, vincristine, actinomycin after gross total excision, 45 months after the initial treatment, MRI showed recurrence, then she received re-operation and 6 cycles of ifosfamide, carboplatin, and etoposide chemotherapy regimen, no recurrence was found during 9 months follow-up. These results mean that chemotherapy may play a beneficial role in long-term survival of ASPS. But many published studies are case reports or small series encompassing diverse treatment paradigms. Thus, more data from systematic analyses and clinical trials of chemotherapy are needed. So adjuvant chemotherapy is not recommended excepted clinical trials.

3.4. Targeted therapy

An increasing number studies of targeted therapy in ASPS have been published which report multi-targeted tyrosine kinase inhibitors are effective for ASPS, especially for patients with evidence of metastasis, but most are case report or small series^[32,34–43] (Table 2). To date, sunitinib, pazopanib have been recommended for the treatment of ASPS in NCCN and Chinese society of clinical oncology (CSCO) guidelines. Anlotinib, a novel tyrosine kinase inhibitor targeting VEGF/VEGFR signaling involving VEGFR-2,-3 and FGFR-1,-2,-3,-4, as the first agent to be approved for clinical use, was approved by China Food and Drug administration (CFDA) and recommended for the first-line therapy of ASPS in CSCO guidelines of STS. The recommendation of Anlotinib was based on a phase II study which was a multicenter study from 15 institutions across China.^[35] In this study, 166 patients who received oral anlotinib 12 mg, once daily for 2 weeks, 3 weeks as a cycle, were included, and 13 cases was ASPS patients. The primary endpoint was PFR at 12 weeks (PFR12 weeks). Results showed PFR12 weeks was 68%, and the median PFS and OS was 5.6 and 12 months respectively. For ASPS group, it was 77% and 21 months respectively, median OS had not been reached. No treatment-related death occurred. It suggests that anlotinib has significant benefit and the toxicity is manageable and acceptable. A double-blind, placebo-controlled, phase III trial of anlotinib in ASPS is ongoing (NCT03016819, Table 3).

Pazopanib, another small molecule and multitargeted tyrosine kinase inhibitor to against VEGFR was also reported to be effective for ASPS.^[8,36–38] In a phase II trial, 6 enrolled patients with metastatic ASPS received pazopanib 800 mg once daily, One patient achieved partial response (PR) (objective response rate

Table 2
Clinical trials evaluating target drug in ASPS.

Year	Author	Phase and clinical number	Drug	Effect
2019	Judson I et al	II (NCT01337401)	Cediranib 30 mg qd Cediranib VS placebo group	median PFS: 10.1 VS 4.9 ($P=.28$) 12-mo PFS: 38.7% VS 34.4% median OS: 27.8 Vs 47.3 ($P=.48$) 12-mo OS: 90 3% VS 68.8%
2019	Cohen JW et al	II (NCT00942877)	Cediranib (AZD2171)	ORR 35% at 24wks, DCR 84% at 24wks
2019	Kim M et al	II (NCT02113826)	Pazopanib 800 mg qd	median PFS 5.5 mo, 6-month PFS 50%
2018	Chi Y et al	II (NCT01878448)	Anlotinib 12 mg, qd	median PFS 5.6 mo, PFS 12wks was 77% median OS 12 mo
2018	Schöffski et al	II (EORTC 90101) (NCT01524926)	Crizotinib 250 mg	1-year OS was 97.4% and 75.0% for MET ⁺ and MET ⁻ patients
2018	Stacchiotti et al	Retrospective study	Pazopanib	median PFS for 13.6 months
2017	Schuetze et al	II (NCT00464620)	Dasatinib	PFS rate at 6 mo with 62% for ASPS
2017	Jagodzińska-Mucha P et al	Retrospective study (15 patients with metastatic ASPS)	Sunitinib 37.5 mg qd	median PFS reached 19 mo, median OS for 56 mo
2016	Li T et al	Retrospective study (14 patients with unresectable or metastatic ASPS)	Sunitinib 37.5 mg qd	median PFS for 41.0 mo, median OS not reached
2016	Kuo DJ	Case report (2 patients with widespread metastases)	Pazopanib, sorafenib, cediranib and sunitinib	survived over 5 y
	Kuo DJ	(multiple target agents)	Sorafenib, cediranib, pazopanib, sunitinib, axitinib, cabozantinib	survived over 5 y
2012	Wagner AJ et al	phase II trial (NCT00557609)	Tivantinib (ARQ 197) ASPS (n=27)	median PFS was 5.5 mo for ASPS
2011	Stacchiotti et al	9 metastatic ASPS patients	Sunitinib 37.5 mg qd	the median PFS reached 17 months

16.7%) and the others showed SD.^[37] The tumors of patients with SD remained stable for at least 4 months. The median PFS was 5.5 months, and the 6-month PFS rate was 50%. There was no severe toxicities except 1 patient with grade 3 diarrhea. A retrospective study reported 30 patients received pazopanib, 1 case achieved CR, 7 reached PR, 17 with SD, the median PFS was 13.6 months.^[38] Whereas, 1 case report showed pazopanib could efficiently prolong survival time over 3 years after chemotherapy failure on a 37-year-old female presented with multiple lung mass and a large abdominal tumor, but seemed ineffective for brain metastasis because of it might not pass through the blood-brain barrier.^[31]

Sunitinib was reported to be promising efficacy for ASPS.^[39–41] In a retrospective study, sunitinib was administered to metastatic ASPS patients, and the median PFS reached 17 months.^[39] Jagodzińska-Mucha et al^[40] reported 15 metastatic ASPS patients, and the median PFS and OS reached 19 months and 56 months respectively. The 5-year OS was 49%. In another retrospective study of 14 Chinese patients with locally unresectable or metastatic ASPS, treated with 37.5 mg of sunitinib once daily, the median PFS was 41.0 months, and median OS was not reached. The 1- and 4-year OS were 90.0% and 60.0% respectively. Furthermore, neoadjuvant treatment with sunitinib could improve the chance of resection for patients with locally advanced ASPS.^[41]

To date, other target drugs, such as crizotinib,^[42] cediranib,^[43–46] bevacizumab^[47,48] sorafenib,^[49] cabozantinib,^[49] apatinib,^[50] dasatinib^[51,52] and Tivantinib,^[53] have also shown therapeutic

advantages and great potential for ASPS patients. The famous clinical trial is EORTC (European Organization for Research and Treatment of Cancer) 90101 study which is a multicentre, biomarker-driven, single agent, nonrandomized, two-stage phase II trial to evaluate the efficacy and safety of crizotinib (a MET tyrosine kinase inhibitor) in advanced and/or metastatic ASPS patients with rearrangement of TFE3.^[42] In this study, 48 patients who were attributed to MET⁺ (43/48 patients), or MET⁻ (4/4 patients) sub-cohorts (1 MET[?] Patient) on the basis of the presence or absence of a TFE3 gene rearrangement, received the treatment with oral crizotinib with starting dose as 250 mg bid, 21 days was defined as 1 treatment cycle. Results showed the objective response rate in MET⁺ and MET⁻ patients was 2.5% and 25.0%, respectively. The SD in MET⁺ and MET⁻ patients was 87.5% and 75.0%, respectively. The disease control rate was 90% and 100%, respectively. The 1-year overall survival rate was 97.4% and 75.0%, respectively. There were no deaths on treatment or within 4 weeks of treatment discontinuation. This study demonstrated that crizotinib had safety and activity in TFE3 rearranged ASPS patients.

Cediranib (AZD2171), another oral, small-molecule anti-angiogenic agents, could inhibited all 3 vascular endothelial growth factor receptor (VEGFR-1, -2 and -3). In a phase II trial, the OR rate of cediranib reached 35% and disease control rate reached 84% at 24 weeks.^[43–45] In another phase II trial, which recruited 48 advanced ASPS patients, PFS was 10.1 months in Cediranib group which was longer than that in placebo group (4.9 months), and the adverse sides were tolerated.^[46]

Table 3
Ongoing clinical trials with target therapy in ASPS.

Trial number	Phase	Drug	Disease	Primary endpoint	Status completion date
NCT02867592	II	XL184 (Cabozantinib)	Refractory Sarcomas (ASPS)	OR Active, not recruiting	September, 2021
NCT01391962	II	Sunitinib or Cediranib	Metastatic ASPS	ORR Active, not recruiting	December, 2021
NCT03016819	III	Anlotinib (AL3818) or Dacarbazine	Metastatic or Advanced ASPS	ORR Recruiting	August, 2021

Table 4**Ongoing clinical trials with PD-1/PD-L1 inhibitors in ASPS.**

Trial number	Phase	Drug	Disease	Primary	Status endpoint	Completion date
NCT03141684	II	Atezolizumab (Anti-PD-L1)	Advanced ASPS (initial treatment)	ORR	Recruiting	October, 2021
NCT02936102	I	FAZ053 (Anti-PD-L1) or +PDR001 (Anti-PD1)	Advanced ASPS	Adverse	Active Events (AEs), not recruiting	April, 2022
NCT03623581	II	GB226 (Anti-PD-1)	Relapsed/metastatic/ unresectable ASPS	ORR	Recruiting	December, 2022

Table 5**Ongoing clinical trials of combination therapy in ASPS.**

Trial number	Phase	Drug	Disease	Primary endpoint	Status completion date
NCT03880123	I	Selinexor and Ixazomib	Advanced Sarcoma (ASPS)	MTD	Withdrawn November 2020
NCT01532687	II	Gemcitabine Alone or in Combination With Pazopanib	Refractory STS (ASPS)	PFS	Completed October, 2019
NCT02636725	II	Concurrent Axitinib and Pembrolizumab	Advanced ASPS	PFS	Active, December, 2022 not recruiting
NCT03989596	II	Hypofractionated RT (10x 3.25 Gy) and Deep hyperthermia	Unresectable STS (ASPS)	Rate of grade 3	Active, December, 2022 not recruiting
NCT03277924	I/II	Sunitinib Plus Nivolumab	Advanced STS (ASPS)	PFSR at 6 months	Recruiting September, 2022
NCT04332874	II	Pembrolizumab + infusion of melphalan and dactinomycin	Advanced ASPS	PFS	Recruiting April, 2023

All of the above suggest that targeted therapy is effective for the long survival of ASPS patients, especially for patients with evidence of metastasis. Unfortunately, most target drugs have not yet been approved for use in ASPS. Some phase II and III clinical trials are ongoing (Table 3), and results are expected in the near future.

3.5. Immune therapy

Immune checkpoint inhibitors (ICIs), such as anti-PD-1 (programmed death-1) anti-PD-L1, and anti-cytotoxic T lymphocyte antigen 4 (CTLA-4), are increasingly used in late-stage malignant tumor patients who have failed to respond to multiple treatments, such as melanoma, non-small-cell lung cancer (NSCLC), and renal cell carcinoma, and have produced higher antitumor response.^[54–56] In ASPS patients, there are just some case reports for ICIs. Kuo et al^[49] reported 2 ASPS cases, 1 patient received nivolumab (PD-1 inhibitor) after failed treatment with multiple target drugs, the SD achieved for 7 months. Lewin et al^[57] reported 2 ASPS patients who received immune checkpoint inhibitor, durvalumab (anti-PD-L1) alone or in combination with tremelimumab (anti-CTLA-4) achieved sustained partial responses. Another case report showed a 29-year-old man who was commenced an ipilimumab (anti-CTLA-4) plus nivolumab (anti-PD-1) combination therapy after failed treatment with surgical extirpation and multiple target drugs, results revealed the patient achieved a partial response after 4 cycles of this combination therapy, and the tumor continued with a 69% decrease from baseline imaging after 3 cycles of maintenance nivolumab.^[58] Atezolizumab, a monoclonal anti-PD-L1 antibody, was also reported to be effective for ASPS with multiple brain metastases, but researchers found that RECIST criteria may be not fit for evaluating the curative effect after treatment with ICIs.^[59] These results suggest that immune checkpoint blockade may be a useful therapeutic strategy for advanced ASPS with widespread metastases. Up to now, just pembrolizumab was recommended for the treatment of

ASPS in NCCN and CSCO guidelines. The recommendation of pembrolizumab was based on a retrospective review, which reviewed the charts of 50 sequential patients with metastatic or unresectable advanced sarcoma, and all 4 ASPS patients had clinical benefit with checkpoint inhibitors.^[60] Now Some clinical trials are ongoing (Table 4), and we expect exciting results.

3.6. Combination therapy

To date, little is known about the combination therapy, such as chemotherapy combined with radiotherapy and/or target therapy or immune therapy. Palliative radiotherapy combined with chemotherapy is considered appropriate for ASPS patients with multiple brain or lung metastasis.^[61] Multiple target agents are also reported to be effective for ASPS. Kuo et al^[49] reported 2 ASPS patients with widespread metastases, who were both administered multiple target agents (1 case was treated with pazopanib, sorafenib, cediranib and sunitinib. another was treated with sorafenib, cediranib, pazopanib, sunitinib, axitinib, cabozantinib), they both survived over 5 years. Furthermore, ICIs combination therapy, such as anti-PD-L1 combined with anti-CTLA-4 has shown promising activity and efficacy.^[58] Clinical trials of combination therapy are ongoing, it maybe a promising treatment in ASPS (Table 5). More systematic studies are needed to validate that findings and examine the efficacies of other new single and combination therapy regimens.

4. Conclusion

Because of the low incidence of ASPS, there are inherent limitations of systematically studying such a rare malignant tumor. Many published studies are case reports or small series encompassing diverse treatment paradigms. Additionally, no meta-analysis has yet to analyze the benefit of adjuvant therapy treatment, and of how it should be coordinated with radiation therapy. Thus, more data from systematic analyses and clinical trials are needed.

In summary, ASPS is a rare malignant tumor, complete surgical resection is the mainstay of treatment for localized ASPS, and adjuvant chemotherapy is not recommended excepted clinical trials. For the patients with micro- or macroscopical incomplete residue or the surgical margin was questionable, radiotherapy should be appreciated to prevent or reduce local recurrence, targeted therapy shows significant benefit for ASPS. Furthermore, for recurrence, distant metastasis, and refractory of ASPS, combination therapy, especially combination with multiple target agents and/or immune checkpoint inhibitors may prolong the mean survival time.

Author contributions

Data curation: Yuehong Li.

Resources: Liubing Hou.

Software: Huandi Zhou, Liubing Hou.

Writing – original draft: Xiaojing Chang.

Writing – review & editing: Xiaojing Chang, Xiaoying Xue.

References

- Wang H, Jacobson A, Harmon DC, et al. Prognostic factors in alveolar soft part sarcoma: a SEER analysis. *J Surg Oncol* 2016;113:581–6.
- Pruksapong C, Satayasontorn K. Alveolar soft part sarcoma of flexure tendon. *J Surg Case Rep* 2017;12:rjx240.
- Wang Y, Cui J, Yan X, et al. Alveolar soft part sarcoma with multiple brain and lung metastases in pregnancy: a case report and literature review. *Medicine (Baltimore)* 2017;96:e8790.
- Cho YJ, Kim JY. Alveolar soft part sarcoma: clinical presentation, treatment and outcome in a series of 19 patients. *Clin Orthop Surg* 2014;6:80–6.
- Qiu L, Li Y, Ali SI, et al. Alveolar soft part sarcoma occurring in the penis of a 3-year-old boy: a rare case report. *Medicine (Baltimore)* 2017;96:e8383.
- Asano Y, Kashiwagi S, Takada K, et al. Alveolar soft part sarcoma metastatic to the breast: a case report. *BMC Surg* 2019;19:30.
- Hei Y, Kang L, Yang X, et al. Orbital alveolar soft part sarcoma: a report of 8 cases and review of the literature. *Oncol Lett* 2018;15:304–14.
- Yoshihiro T, Tsuchihashi K, Nio K, et al. Lingual alveolar soft part sarcoma responsive to pazopanib: a case report. *Medicine (Baltimore)* 2017;96:e8470.
- Tao X, Tian R, Hao S, et al. Primary intracranial alveolar soft-part sarcoma: report of two cases and a review of the literature. *World Neurosurg* 2016;90:699e1–6.
- McCarville MB, Muzzafar S, Kao SC, et al. Imaging features of alveolar soft-part sarcoma: a report from Children's Oncology Group Study ARST0332. *AJR Am J Roentgenol* 2014;203:1345–52.
- Li Xubin, Ye Zhaoxiang. Magnetic resonance imaging features of alveolar soft part sarcoma: report of 14 cases. *World J Surg Oncol* 2014;12:36.
- Cui JF, Chen HS, Hao DP, et al. Magnetic resonance features and characteristic vascular pattern of alveolar soft-part sarcoma. *Oncol Res Treat* 2017;40:580–5.
- Ladanyi M, Lui MY, Antonescu CR, et al. "The der (17)t (X;17) (p11;q25) of human alveolar soft part sarcoma fuses the TFE3 transcription factor gene to ASPL, a novel gene at 17q25". *Oncogene* 2001;20:48–57.
- Covell DG, Wallqvist A, Kenney S, et al. Bioinformatic analysis of patient-derived ASPS gene expressions and ASPL-TFE3 fusion transcript levels identify potential therapeutic targets. *PLoS One* 2012;7:e48023.
- Saluja K, Thomas J, Zhang S, et al. Malignant perivascular epithelioid cell tumor of the oropharynx with strong TFE3 expression mimicking alveolar soft part sarcoma: a case report and review of the literature. *Hum Pathol* 2018;76:149–55.
- Zhao C, Gao X, Yang J, et al. Surgical management and outcome of spinal alveolar soft part sarcoma (ASPA): a case series of five patients and literature review. *World J Surg Oncol* 2017;15:39.
- Lin YK, Wu PK, Chen CF, et al. Alveolar soft part sarcoma: clinical presentation, treatment, and outcome in a series of 13 patients. *J Chin Med Assoc* 2018;81:735–41.
- Ogose A, Yazawa Y, Ueda T, et al. Alveolar soft part sarcoma in Japan: multi-institutional study of 57 patients from the Japanese Musculoskeletal Oncology Group. *Oncology* 2003;65:7–13.
- Gingrich AA, Bateni SB, Monjzab AM, et al. Neoadjuvant Radiotherapy is associated with r0 resection and improved survival for patients with extremity soft tissue sarcoma undergoing surgery: a national cancer database analysis. *Ann Surg Oncol* 2017;24:3252–63.
- Diamantis A, Baloyiannis I, Magouliotis DE, et al. Perioperative radiotherapy versus surgery alone for retroperitoneal sarcomas: a systematic review and meta-analysis. *Radiol Oncol* 2020;54:14–21.
- Ogura K, Beppu Y, Chuman H, et al. Alveolar soft part sarcoma: a single-center 26-patient case series and review of the literature. *Sarcoma* 2012;2012:907179.
- Emmez H, Kale A, Sevinç Ç, et al. Primary intracerebral alveolar soft part sarcoma in an 11-year-old girl: case report and review of the literature. *NMC Case Rep J* 2014;2:31–5.
- Mullins BT, Hackman T. Adult alveolar soft part sarcoma of the head and neck: a report of two cases and literature review. *Case Rep Oncol Med* 2014;2014:597291.
- Sidi V, Fragandrea I, Hatzipantelis E, et al. Alveolar soft-part sarcoma of the extremity: a case report. *Hippokratia* 2008;12:251–3.
- Chen Z, Sun C, Sheng W, et al. Alveolar soft-part sarcoma in the left forearm with cardiac metastasis: a case report and literature review. *Oncol Lett* 2016;11:81–4.
- Hanzer M, Nebl A, Spindel S, et al. Necrosis of a skin autograft after short-term treatment with sunitinib in a 14-year-old girl with metastatic alveolar soft part sarcoma of the thigh. *Klin Padiatr* 2010;222:184–6.
- Nakao K, Nakamura K, Kiyohara H, et al. Ovarian function preserved by carbon-ion radiotherapy for alveolar soft-part sarcoma. *Int J Gynaecol Obstet* 2013;123:165–6.
- Meng N, Zhang X, Liao A, et al. Management of recurrent alveolar soft-part sarcoma of the tongue after external beam radiotherapy with iodine-125 seed brachytherapy. *Head Neck* 2014;36:E125–128.
- Reichardt P, Lindner T, Pink D, Thuss-Patience PC, et al. Chemotherapy in alveolar soft part sarcomas. What do we know? *Eur J Cancer* 2003;39:1511–6.
- Flores RJ, Harrison DJ, Federman NC, et al. Alveolar soft part sarcoma in children and young adults: a report of 69 cases. *Pediatr Blood Cancer* 2018;65:e26953.
- Brennan B, Zanetti I, Orbach D, et al. Alveolar soft part sarcoma in children and adolescents: the European paediatric soft tissue sarcoma study group prospective trial (EpSSG NRSTS 2005). *Pediatr Blood Cancer* 2018;65:4.
- Shido Y, Matsuyama Y. Advanced alveolar soft part sarcoma treated with pazopanib over three years. *Case Rep Oncol Med* 2017;2017:3738562.
- Asokan B, Ramanan P, Sundararaj M, et al. Alveolar soft part sarcoma of the forearm. *Indian J Plast Surg* 2017;50:310–3.
- Soheilifar MH, Taheri RA, Zolfaghari Emameh R, et al. Molecular landscape in alveolar soft part sarcoma: implications for molecular targeted therapy. *Biomed Pharmacother* 2018;103:889–96.
- Chi Y, Fang Z, Hong X, et al. Safety and efficacy of anlotinib, a multikinase angiogenesis inhibitor, in patients with refractory metastatic soft-tissue sarcoma. *Clin Cancer Res* 2018;24:5233–8.
- Kobayashi E, Kawai A, Chuman H. Pazopanib treatment in alveolar soft part sarcomas. *Ann Oncol* 2015;26:108–10.
- Kim M, Kim TM, Keam B, Kim YJ, et al. A Phase II trial of pazopanib in patients with metastatic alveolar soft part sarcoma. *Oncologist* 2019;24:20–e29.
- Stacchiotti S, Mir O, Le Cesne A, et al. Activity of pazopanib and trabectedin in advanced alveolar soft part sarcoma. *Oncologist* 2018;23:62–70.
- Stacchiotti S, Negri T, Zaffaroni N, et al. Sunitinib in advanced alveolar soft part sarcoma: evidence of a direct antitumor effect. *Ann Oncol* 2011;22:1682–90.
- Jagodzinska-Mucha P, Switaj T, Kozak K, et al. Long-term results of therapy with sunitinib in metastatic alveolar soft part sarcoma. *Tumori* 2017;103:231–5.
- Li T, Wang L, Wang H, et al. A retrospective analysis of 14 consecutive Chinese patients with unresectable or metastatic alveolar soft part sarcoma treated with sunitinib. *Invest New Drugs* 2016;34:701–6.
- Schöffski P, Wozniak A, Kasper B, et al. Activity and safety of crizotinib in patients with alveolar soft part sarcoma with rearrangement of TFE3: European Organization for Research and Treatment of Cancer (EORTC) phase II trial 90101 'CREATE'. *Ann Oncol* 2018;29:758–65.

- [43] Kummar S, Allen D, Monks A, et al. Cediranib for metastatic alveolar soft part sarcoma. *J Clin Oncol* 2013;31:2296–302.
- [44] Cohen JW, Widemann BC, Derdak J, et al. Cediranib phase-II study in children with metastatic alveolar soft-part sarcoma (ASPS). *Pediatr Blood Cancer* 2019;66:e27987.
- [45] Powles T, Brown J, Larkin J, et al. A randomized, double-blind phase II study evaluating cediranib versus cediranib and saracatinib in patients with relapsed metastatic clear-cell renal cancer (COSAK). *Ann Oncol* 2016;27:880–6.
- [46] Judson I, Morden JP, Kilburn L, et al. Cediranib in patients with alveolar soft-part sarcoma (CASPS): a double-blind, placebo-controlled, randomised, phase 2 trial. *Lancet Oncol* 2019;20:1023–34.
- [47] Azizi AA, Haberler C, Czech T, et al. Vascular-endothelial-growth-factor (VEGF) expression and possible response to angiogenesis inhibitor bevacizumab in metastatic alveolar soft part sarcoma. *Lancet Oncol* 2006;7:521–3.
- [48] Read WL, Williams F. Metastatic alveolar soft part sarcoma responsive to pazopanib after progression through sunitinib and bevacizumab: two cases. *Case Rep Oncol* 2016;9:639–43.
- [49] Kuo DJ, Menell JS, Glade Bender JL. Treatment of metastatic, refractory alveolar soft part sarcoma: case reports and literaturereview of treatment options in the era of targeted therapy. *J Pediatr Hematol Oncol* 2016;38:e169–172.
- [50] Zhou Y, Tang F, Wang Y, et al. Advanced alveolar soft part sarcoma responds to apatinib. *Oncotarget* 2017;8:50314–22.
- [51] Mukaihara K, Tanabe Y, Kubota D, et al. Cabozantinib and dastinib exert anti-tumor activity in alveolar soft part sarcoma. *PLoS One* 2017;12:e0185321.
- [52] Schuetze SM, Bolejack V, Choy E, et al. Phase 2 study of dasatinib in patients with alveolar soft part sarcoma, chondrosarcoma, chordoma, epithelioid sarcoma, or solitary fibrous tumor. *Cancer* 2017;123:90–7.
- [53] Wagner AJ, Goldberg JM, Dubois SG, et al. Tivantinib (ARQ 197), a selective inhibitor of MET, in patients with microphthalmia transcription factor-associated tumors: results of a multicenter phase 2 trial. *Cancer* 2012;118:5894–902.
- [54] Hao C, Tian J, Liu H, et al. Efficacy and safety of anti-PD-1 and anti-PD-1 combined with anti-CTLA-4 immunotherapy to advanced melanoma: A systematic review and meta-analysis of randomized controlled trials. *Medicine (Baltimore)* 2017;96:e7325.
- [55] Gettinger S, Horn L, Jackman D, et al. Five-year follow-up of nivolumab in previously treated advanced non-small-cell lung cancer: results from the CA209-003 study. *J Clin Oncol* 2018;36:1675–84.
- [56] Flippot R, Escudier B, Albiges L. Immune checkpoint inhibitors: toward new paradigms in renal cell carcinoma. *Drugs* 2018;78:1443–57.
- [57] Lewin J, Davidson S, Anderson ND, et al. Response to immune checkpoint inhibition in two patients with alveolar soft-part sarcoma. *Cancer Immunol Res* 2018;6:1001–7.
- [58] Conley AP, Trinh VA, Zobniw CM, et al. Positive tumor response to combined checkpoint inhibitors in a patient with refractory alveolar soft part sarcoma: a case report. *J Glob Oncol* 2018;4:1–6.
- [59] Vander Jagt TA, Davis LE, Thakur MD, et al. Pseudoprogression of CNS metastatic disease of alveolar soft part sarcoma during anti-PDL1 treatment. *Radiol Case Rep* 2018;13:882–5.
- [60] Roman Groisberg, David S, Hong , Amini Behrang, et al. Characteristics and outcomes of patients with advanced sarcoma enrolled in early phase immunotherapy trials. *J Immunother Cancer* 2017;5:100.
- [61] Kaushal-Deep SM, Raswan US, Kirmani AR, et al. Alveolar soft part sarcoma metastasizing to the brain: a rare entity revisited with review of recent literature. *J Pediatr Neurosci* 2019;14:158–61.