

Available online at www.sciencedirect.com

ScienceDirect

journal homepage: www.elsevier.com/locate/radcr

Case Report

Multiple superficial femoral artery pseudoaneurysms following sub intimal application of paclitaxel coated technology ☆,☆☆,★,★★

Krystal Dinh, BMed, M Trauma*, Animesh Singla, MBBS, FRACS (Vasc), Hiro Masuda, MD, Daniel Nguyen, MBBS, FRACS (Gen), FRACS (Vasc)

Department of Vascular Surgery, Royal North Shore Hospital, St Leonards, NSW, Australia

ARTICLE INFO

Article history:

Received 23 August 2021

Accepted 30 August 2021

Keywords:

Vascular

Diagnostic imaging

Interventional radiology

Pseudo aneurysm

Superficial femoral artery

ABSTRACT

Drug coated balloons (DCB) are a commonly used endovascular option for treating patients presenting with symptomatic peripheral vascular disease. DCB have illustrated to increase primary patency and thus have been a popular choice in addressing restenosis caused by neointimal hyperplasia. Pseudoaneurysms (PSA) are a common vascular pathology, the causes of which include iatrogenic, trauma, stent fractures and angioplasty balloon overuse. Herein, we describe the case where a patient developed multiple superficial femoral artery (SFA) PSA potentially secondary to the subintimal application of paclitaxel.

Crown Copyright © 2021 Published by Elsevier Inc. on behalf of University of Washington.

This is an open access article under the CC BY-NC-ND license

(<http://creativecommons.org/licenses/by-nc-nd/4.0/>)

Clinical summary

A 61-year-old male presented to hospital with an incidental finding of SFA PSA during work up for solitary lung lesions. A positron emission tomography (PET) scan illustrated FDG-avidity uptake (Fig. 1) in the soft tissue surrounding his left SFA suggestive of either infection or inflammation. Subsequent imaging with computed tomography angiography (CTA) illustrated multiple left leg SFA partially thrombosed PSA (Fig. 2).

The primary provisional diagnosis at this stage was infected mycotic aneurysms.

The patient was a heavy tobacco and Marijuana smoker, an ex-intravenous drug user and had a background of ischaemic heart disease, hypertension, mild intellectual impairment and liver cirrhosis from past hepatitis B (treated). Furthermore, he had previously underwent a left femoral to right popliteal bypass with ring enforced Gortex graft for an acutely ischaemic right leg and multiple elective peripheral interventions for claudication including right common femoral artery (CFA) en-

☆ Competing Interests: Nil conflicts of interest or financial support was obtained for this case report.

☆☆ All authors agree with the content of this case report.

★ Consent has been gained from the patient described.

★★ This publication has not been submitted to any other journal and has not been previously published.

* Corresponding author.

E-mail address: dinhkrystal9@gmail.com (K. Dinh).

<https://doi.org/10.1016/j.radcr.2021.08.073>

1930-0433/Crown Copyright © 2021 Published by Elsevier Inc. on behalf of University of Washington. This is an open access article under the CC BY-NC-ND license (<http://creativecommons.org/licenses/by-nc-nd/4.0/>)

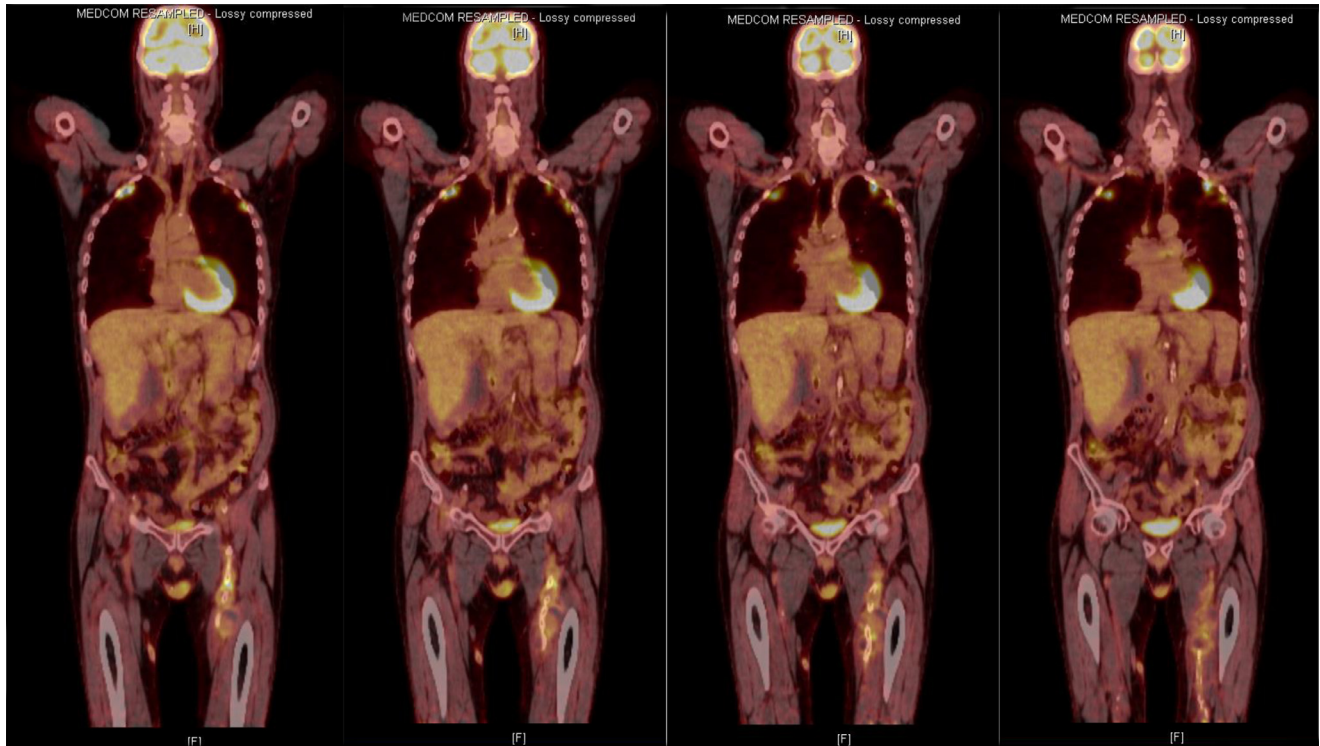


Fig. 1 – FDG PET scan illustrating uptake in the soft tissue surrounding the left superficial femoral artery indicating either infection or inflammation

arterectomy and left common iliac artery stent. In regards to the area of FDG PET uptake, three years prior to his presentation, he had a SFA occlusion treated with a subintimal paclitaxel coated balloon angioplasty (iVascular, luminor 18) with subsequent stenting (6 × 200mm iVascular, ivolution self-expanding nitinol stent).

Due to the high suspicion for SFA stent infection and after consultation with both the infectious disease and radiology teams, a gallium scan was completed. The gallium scan illustrated a small degree of uptake at the left SFA stent that likely reflected inflammation around the partially thrombosed PSA. The patient remained asymptomatic, afebrile and haemodynamically stable throughout the duration of his admission. Further, multiple blood culture samples returned a negative result and his white cell count and c-reactive protein remained normal. Subsequent to these findings, a mycotic PSA were excluded. The patient was followed up in the vascular outpatient clinic three months post his initial admission with subsequent CTA and ultrasound imaging which illustrated a SFA 50-75% stenosis, and a mild progression of his left leg SFA PSA for which he was booked for an elective repair.

Diagnostic subtracted imaging (DSA) of the SFA prior to elective repair illustrated four PSA of the SFA (Fig. 3) and fractured proximal SFA stent. The SFA stents were realigned with two overlapping covered stents (6 × 20mm proximally, and 6 × 15mm distally GORE, Viabahn) and post dilated with a plain endovascular balloon (6 × 15mm Abbott, Amarda plain balloon). The tight distal SFA stenosis was also treated (6 × 15mm Abbott, Amarda plain balloon). Final DSA illus-

trated exclusion of the SFA PSA and improved flow with the distal SFA stenosis.

The respiratory team were involved with management of his lung lesions, he had a bronchoscopy and biopsy of his lung lesions which illustrating a chronic inflammatory state. However, because there were no changes to the lesions, the patient was followed up as an outpatient.

Discussion

DCBs are a commonly used endovascular option for treating patients presenting with symptomatic PVD. DCBs increase target lesion primary patency rates and thus have been a popular choice in addressing restenosis caused by neointimal hyperplasia. PSA are a common vascular pathology, the causes of which include iatrogenic, trauma, stent fractures and angioplasty balloon oversize/overuse. Herein, we describe the rare and interesting case of a patient presenting with SFA PSA. The cause of the SFA PSA may have arose secondary to a combination of multiple contributing factors including 1. subintimal treatment of the lesion (potentially with localized perforations), 2. physical stresses caused by localized stent fracture may also have predisposed and 3. the use of drug coated paclitaxel technology. Mechanism of action of paclitaxel is to cause cell death by arrest cell division on mitosis stage, thus inhibiting the healing process of neointimal hyperplasia. Combined, these may have contributed to the localized development of SFA PSA.

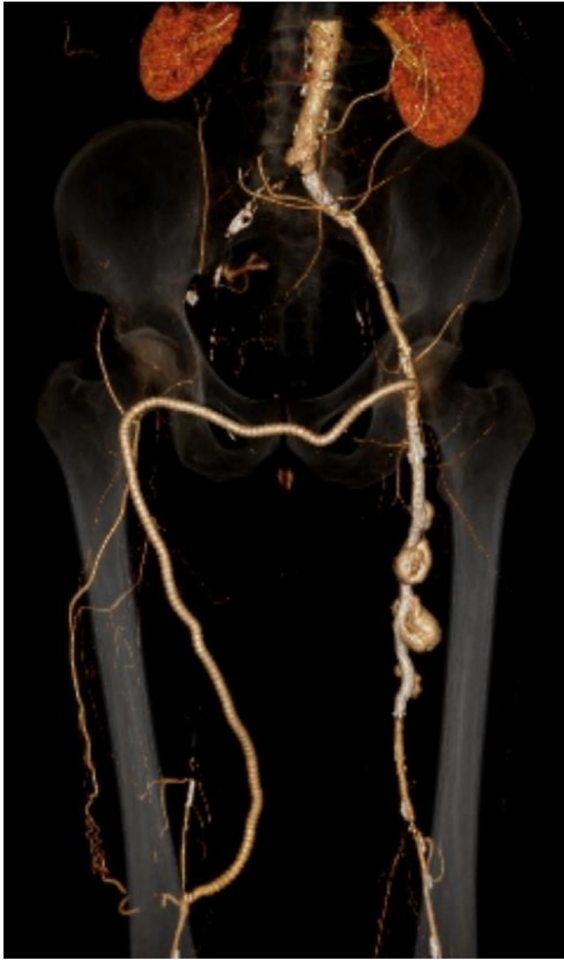

Fig. 2 – Computed Tomography Angiography reconstruction of the left femoral to right popliteal bypass, left iliac artery stent, and left superficial femoral artery pseudoaneurysms

There is scarce literature on aneurysm degeneration following the application of paclitaxel coated devices, with only two case reports published, both used paclitaxel on their devices [1,2]. Golouh *et al.* presented a case where a SFA PSA developed after the use of paclitaxel. Whilst a second study by Chen *et al.* described the development of a vein bypass graft PSA post the application of paclitaxel however it is important to note that balloon overinflation may have also contributed to this phenomenon as illustrated by contrast extravasation during initial treatment. Thus, the true etiology of these PSAs is known however, with recent discussions regarding mortality risk associated with paclitaxel endovascular techniques, it is prudent to continue surveillance for patients undergoing subintimal drug coated treatment for lower limb recanalization.

REFERENCES

- [1] Golouh V, Kobilica N, Breznik S. Superficial femoral artery pseudoaneurysm and arterial wall destruction after drug-coated balloon treatment. *Cureus* 2020;12:9.
- [2] Chen W, Dyniewski B, Bobka T, Kraemer C, Tan T, Zhou W. Aneurysmal degeneration after paclitaxel-eluting balloon angioplasty. *Vasc Endovasc Surg* 2021;55:410–14.

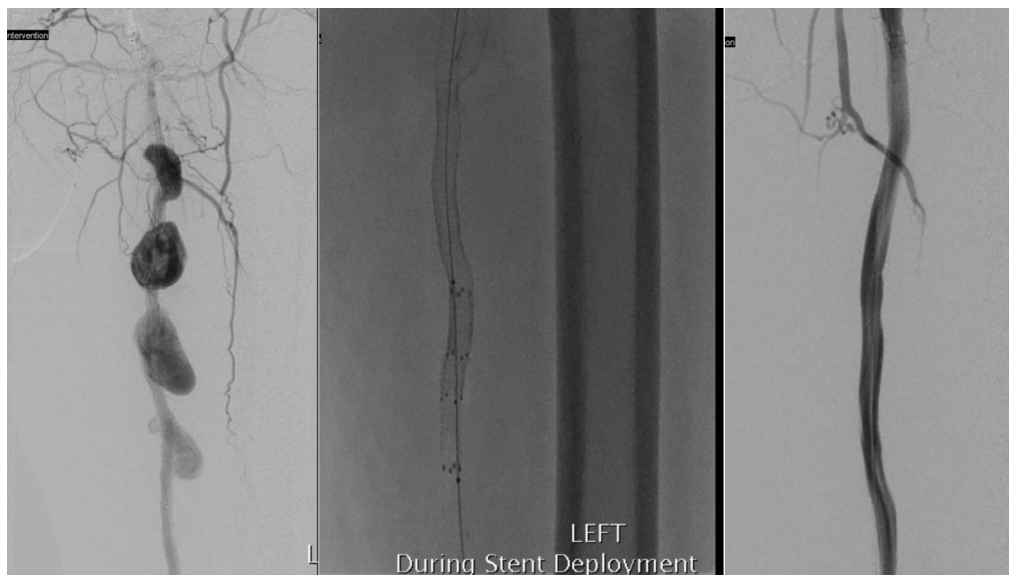


Fig. 3 – Intra operative images of the superficial femoral artery before and after treatment