



# Percutaneous Drainage for Giant Pulmonary Interstitial Emphysema in a Tiny Infant with a Birth Weight of 327 g

Yuta Hoshina, MD<sup>1</sup> Ryo Ogawa, MD, PhD<sup>1,2</sup>  Arata Oda, MD<sup>1,2</sup> Yoshiya Kamei, MD<sup>1</sup>  
Tomohiko Nakamura, MD, PhD<sup>1,2</sup>

<sup>1</sup> Division of Neonatology, Nagano Children's Hospital, Azumino, Nagano, Japan

<sup>2</sup> Life Science Research Center, Nagano Children's Hospital, Azumino, Nagano, Japan

**Address for correspondence** Ryo Ogawa, MD, PhD, Division of Neonatology, Nagano Children's Hospital, 3100 Toyoshina, Azumino-shi, Nagano 399-8288, Japan (e-mail: drryo0411@gmail.com).

AJP Rep 2024;14:e133–e135.

## Abstract

Giant pulmonary cyst in extremely low birth weight (ELBW) infants has been described as one of severe pulmonary diseases. Any definitive therapy for refractory cases, where conservative methods of treatments are not effective, has not been established as a standard. Herein, we report an ELBW infant with a giant pulmonary cyst cured by percutaneous drainage without any adverse events. A female infant was born with a birth weight of 327 g. Surfactant was administered on days 1 and 2 of life to treat respiratory distress syndrome. Tracheal intubation was performed and synchronized intermittent mandatory ventilation was promptly initiated following birth. On the course, right giant pulmonary cyst developed on day 9 after birth. Although we started conservative therapy, including right lateral decubitus positioning, high-frequency oscillatory ventilation, and systemic corticosteroid administration, the diameter of the cyst had reached 34 mm, and mediastinal displacement was observed on day 28 after birth when she weighed 393 g. She recovered by percutaneous drainage followed by suction with a pressure of  $-10$  cm H<sub>2</sub>O under mild sedation for 3 days. We believe that percutaneous drainage can be one of the available options for unilateral pulmonary interstitial emphysema.

## Keywords

- ▶ drainage
- ▶ extremely low birth weight infant
- ▶ pulmonary interstitial emphysema
- ▶ respiratory

Giant pulmonary cysts can be fatal in extremely low birth weight (ELBW) infant. New bubbly cystic or linear lucency within a lung is an important indicator for physicians.<sup>1</sup> Conservative treatment, such as positioning, suctioning, respiratory physical therapy, gentle conventional ventilation, and high-frequency oscillatory ventilation (HFOV), are effective in most cases,<sup>2</sup> whereas more invasive modes are not established as standard therapy. We present the case of an ELBW infant of 393 g with a giant pulmonary cyst treated

with percutaneous drainage without any adverse events. This study was approved by the ethics committee of Nagano Children's Hospital, and written informed consent was obtained from the patient's parents for publication.

## Case Presentation

A female infant with a birth weight of 327 g was delivered in the 23rd gestational week by emergency cesarean section

received  
January 2, 2024  
accepted after revision  
April 9, 2024

DOI <https://doi.org/10.1055/s-0044-1786713>.  
ISSN 2157-6998.

© 2024. The Author(s).

This is an open access article published by Thieme under the terms of the Creative Commons Attribution-NonDerivative-NonCommercial-License, permitting copying and reproduction so long as the original work is given appropriate credit. Contents may not be used for commercial purposes, or adapted, remixed, transformed or built upon. (<https://creativecommons.org/licenses/by-nc-nd/4.0/>)

Thieme Medical Publishers, Inc., 333 Seventh Avenue, 18th Floor, New York, NY 10001, USA

owing to exacerbation of preeclampsia, so that antenatal steroids were not administered. Her mother, gravida 2, para 1, without premature rupture of membranes was treated for hypertension during pregnancy, and restricted fetal growth had been diagnosed. Apgar scores were 1 at 1 minute and 2 at 5 minutes. No abnormalities were observed during general examination, and there were no evidence of meconium staining nor chorioamnionitis. Placental inflammation was not diagnosed pathologically. Tracheal intubation was performed, and synchronized intermittent mandatory ventilation (SIMV) was promptly initiated following birth. Surfactant was administered on days 1 and 2 of life to treat respiratory distress syndrome. A pulmonary cyst emerged in right lung on day 9 (►Fig. 1A), accompanied by poor oxygenation and ventilation (fraction of inspired oxygen [FiO<sub>2</sub>] 0.4 to keep oxygen saturation [SpO<sub>2</sub>] > 94% on SIMV at positive end-expiratory pressure 7 cm H<sub>2</sub>O and peak inspiratory pressure [PIP] 18 cm H<sub>2</sub>O). Conservative therapy was started, including right lateral decubitus positioning, HFOV at an inspiratory to expiratory ratio of 1:2 to reduce gas leak (from day 14 after birth to avoid high pressure ventilation), and systemic corticosteroid administration: hydrocortisone 5 mg/kg/d for 2 days, tapered to 1 mg/kg/d every 2 days. However, the cyst continued to enlarge. We again changed the ventilation mode from HFOV to SIMV at PIP 22 on day 21 after birth to deal with frequent desaturation.

On day 28 after birth, the infant weighed 393 g. On the course, the setting of PIP was required to be 25 mm Hg, and diameter of the cyst had reached 34 mm and mediastinal displacement was observed, indicating pulmonary interstitial emphysema (PIE).

After informed consent of the parents of the infant was obtained on day 29, we punctured the cyst guided by X-ray under local anesthesia, with xylocaine 1% in addition to midazolam and fentanyl injection. Considering the physique of the infant and suction efficiency, we placed a 20-gauge venous catheter with needle (Terumo Corp., Tokyo, Japan) via the fifth intercostal space on medial axillary line in a dorsal direction (►Fig. 1B). After confirming the successful discharge of air by manual suctioning, we started suction drainage with a pressure of -10 cm H<sub>2</sub>O under mild sedation with the injection of phenobarbital, as needed. On the course

of continuous drainage, the cyst gradually diminished to a negligible size, and blood SpO<sub>2</sub> improved (FiO<sub>2</sub> 0.3 on HFOV at mean airway pressure [MAP] 14 cm H<sub>2</sub>O) at day 3 after the procedures. Consequently, we removed the catheter on the same day (►Figs. 1C and 2). The pulmonary cyst did not recur, and no adverse event was observed. This infant was discharged to home without oxygen on 201 days.

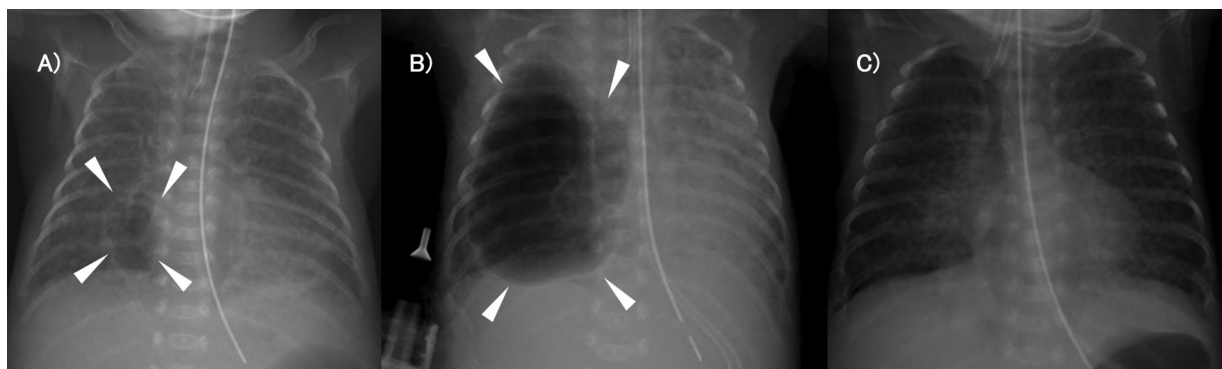
## Discussion

We reported the possibility of percutaneous drainage for PIE in an infant who weighed 393 g when the procedure was performed. The pulmonary cyst of the infant did not recur, and no adverse event was observed.

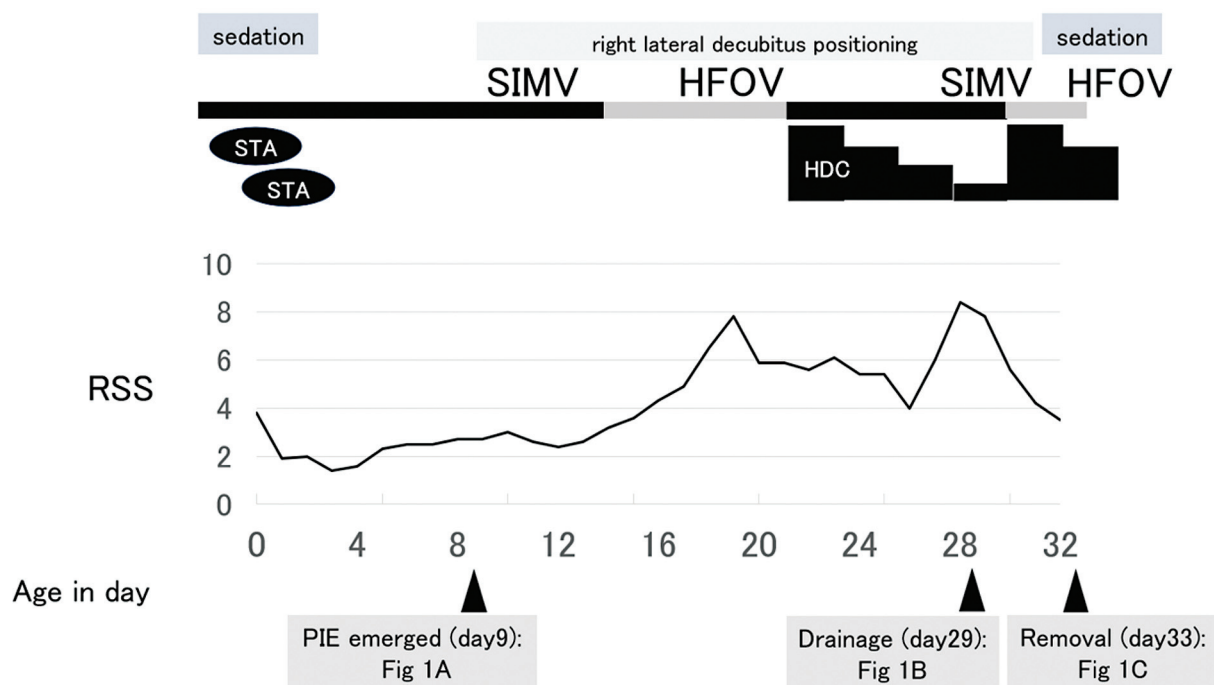
When physicians treat PIE, conservative therapy is generally considered at first. For example, positioning the infant with the affected side down determined to collapse lung, minimal chest physiotherapy, and endotracheal suctioning, and if possible, decreasing ventilator pressure and inspiratory times.<sup>3-5</sup> Additionally, HFOV may be effective to avoid higher MAP.<sup>6</sup> If PIE is resistant to conservative therapy, more invasive regimens, such as selective intubation, lobectomy, or pneumonectomy, are reported.<sup>2,7-12</sup> Conversely, there are a few case reports on percutaneous drainage for PIE.<sup>13,14</sup>

The cause of PIE is leaked gas trapped in the interstitium from alveoli.<sup>5</sup> Especially, preterm infants have a higher risk of PIE as their perivascular connective tissues are abundant and relatively more compliant.<sup>15,16</sup> Additionally, atelectasis in respiratory distress syndrome and plugged small airways in meconium aspiration syndrome can increase the risk of air leak because the ventilation in lung can be uneven.<sup>3</sup> We hypothesized that percutaneous drainage would be also effective for PIE based on its mechanism exhibited by trapped air in thorax like in pneumothorax.<sup>5</sup> Especially, our case was advantageous owing to sufficient size of the cyst enabling drainage and its proximity to thoracic wall on X-ray. In a previously reported case,<sup>13</sup> the cyst was multilobulated, so that physicians languished to perform drainage. As for the device, we could not clarify but 24-gauge peripheral intravenous catheter might have been used.<sup>14</sup>

The infant in our case had considerably smaller weight compared with those previously reported cases of drainage.



**Fig. 1** X-rays of the patient's giant pulmonary cyst. (A) Day 9 at the time of emergence of PIE. (B) Day 29 at the time of cyst puncture. (C) Day 32 at the time of catheter removal.



**Fig. 2** Course of RSS (consisting of mean airway pressure multiplied by FiO<sub>2</sub>). FiO<sub>2</sub>, fraction of inspired oxygen; HFOV, high-frequency oscillatory ventilation; PIE, Pulmonary interstitial emphysema; RSS, respiratory severity score; SIMV, synchronized intermittent mandatory ventilation.

Further research is required to determine the optimum approach for this procedure in terms of adequate patient's condition, concrete device, and appropriate suction pressure.

### Conclusion

We believe that percutaneous drainage is a potentially effective treatment for ELBW infants when refractory PIE leading to breathing and circulation failure is diagnosed.

**Conflict of Interest**  
None declared.

**Acknowledgments**  
We thank Dr. Shigeru Takamizawa for the corporation with placing the catheter and Dr. Yoshiaki Kondo for professional assistance in radiologic interpretations.

### References

- 1 Merrow AC, Hariharan S. Pulmonary interstitial emphysema. In: Merrow AC, Hariharan S, eds. *Imaging in Pediatrics*. Amsterdam: Elsevier; 2017:53
- 2 Rastogi S, Gupta A, Wung JT, Berdon WE. Treatment of giant pulmonary interstitial emphysema by ipsilateral bronchial occlusion with a Swan-Ganz catheter. *Pediatr Radiol* 2007;37(11):1130–1134
- 3 Jeng MJ, Lee YS, Tsao PC, Soong WJ. Neonatal air leak syndrome and the role of high-frequency ventilation in its prevention. *J Chin Med Assoc* 2012;75(11):551–559
- 4 Ahlfeld SK. Respiratory tract disorders. In: Kliegman RM, Geme JWSt, Blum NJ, et al, eds. *Nelson Textbook of Pediatrics*. 21st ed. Amsterdam: Elsevier; 2020:929–949
- 5 Crowley MA. Neonatal respiratory disorders. In: Martin RJ, Fanaroff AA, Walsh MC, eds. *Fanaroff and Martin's Neonatal-Perinatal Medicine*. 11th ed. Amsterdam: Elsevier; 1203–1230
- 6 Squires KAG, De Paoli AG, Williams C, Dargaville PA. High-frequency oscillatory ventilation with low oscillatory frequency in pulmonary interstitial emphysema. *Neonatology* 2013;104(04):243–249
- 7 Shankar R, Ahmed H, Farhan A, Corbally M. Ventilator-induced pulmonary interstitial emphysema treated with lobectomy in a preterm infant. *J Pediatr Surg Case Rep* 2020;60:101566
- 8 Joseph LJ, Bromiker R, Toker O, Schimmel MS, Goldberg S, Picard E. Unilateral lung intubation for pulmonary air leak syndrome in neonates: a case series and a review of the literature. *Am J Perinatol* 2011;28(02):151–156
- 9 Swingle HM, Eggert LD, Bucciarelli RL. New approach to management of unilateral tension pulmonary interstitial emphysema in premature infants. *Pediatrics* 1984;74(03):354–357
- 10 Sica M, Molinaro F, Angotti R, Mazzei O, Messina M. A case of diffuse persistent pulmonary emphysema: when is difficult the diagnosis? *J Pediatr Surg Case Rep* 2016;12:11–15
- 11 Matta R, Matta J, Hage P, Nassif Y, Mansour N, Diab N. Diffuse persistent interstitial pulmonary emphysema treated by lobectomy. *Ann Thorac Surg* 2011;92(04):e73–e75
- 12 Belcher E, Abbasi MA, Hansell DM, Ffolkes L, Nicholson AG, Goldstraw P. Persistent interstitial pulmonary emphysema requiring pneumonectomy. *J Thorac Cardiovasc Surg* 2009;138(01):237–239
- 13 Kim C, Shin JE, Lee SM, et al. A case of pulmonary interstitial emphysema treated by percutaneous catheter insertion in extremely low birth weight infant. *Yonsei Med J* 2016;57(06):1523–1526
- 14 Watanabe M, Momoi N, Sato M, et al. Percutaneous evacuation of diffuse pulmonary interstitial emphysema by lung puncture in a baby with extremely low birth weight: a case report. *J Med Case Rep* 2012;6:325
- 15 Greenough A, Bhojnarwala B. Causes and management of pulmonary air leaks. *Paediatr Child Health* 2012;22:523–527
- 16 Makker K, Day-Richardson CL, Hudak ML. Respiratory distress syndrome. In: Maheshwari A, ed. *Principles of Neonatology*. 1st ed. Amsterdam: Elsevier; 2024:66–77