

Spectrophotometric Evaluation of Color Change in Tooth Enamel Defects Using Resin Infiltrate: An *In Vivo* Study

Shikha Dogra¹, Virinder Goyal², Anil Gupta³, Sakshi Joshi⁴, Vimanyu Kataria⁵, Jyotika Saini⁶, Monika Nagpal⁷, Payal Narula⁸

ABSTRACT

Aim: To analyze the comparative change in pretreatment and posttreatment $L^*a^*b^*$ values of color in initial nonpitted white spot lesions of fluorosed teeth after resin infiltration with DMG-Icon spectrophotometrically with VITA easy shade.

Materials and methods: A total of 30 maxillary and mandibular permanent anterior teeth with mild, nonpitted white spot lesions (atleast one) of fluorosis [till grade IV of Thylstrup and Fejerskov (TF) index] in patients between 6 years and 14 years of age were included in the present study. Shade of selected tooth and its white spot lesion area was recorded using VITA 3D shade guide, both pre and postoperatively, i.e., after application of DMG Icon. This was followed by recording the change in corresponding $L^*a^*b^*$ values of tooth shade and white spot lesion spectrophotometrically using VITA Easy Shade. Results obtained were analyzed statistically.

Results: ΔE value of color change was found to be less than 3.7 in most of samples after resin infiltration and esthetically color change to naked eye was statistically significant (p value < 0.00001) postoperatively.

Conclusion: Resin infiltration with DMG Icon can improve the color of non-cavitated white spot lesions. The esthetic effect of this treatment was evident immediately after treatment. Moreover, no cavitation occurred after etching, even when the surface layer had been eroded completely.

Clinical significance: Achievement of esthetic results without loss of tooth structure and postoperative sensitivity.

Keywords: DMG-Icon, Mild fluorosis, Resin infiltration, Spectrophotometer, Tooth discoloration, White spot lesions.

International Journal of Clinical Pediatric Dentistry (2020): 10.5005/jp-journals-10005-1727

INTRODUCTION

The most important esthetic factor for smile is tooth discoloration as it is perceived more rapidly than other esthetic abnormalities.¹ Tooth discoloration can occur due to extrinsic and intrinsic stains. The extrinsic stains are results of tobacco, plaque, betel chewing and medications such as chlorhexidine, cetylpyridinium chloride whereas the cause of intrinsic stains is dental fluorosis, dental trauma from external injury, defects in formation of tooth enamel such as hypomineralization, hypomaturation or hypoplasia, intrauterine consumption of tetracycline medicaments.²

Discoloration as white spot lesions appears as a result of subsurface demineralization, seen in cases of mild dental fluorosis, post traumatic injury, post orthodontic decalcification. Hence white spot lesions are early sign of demineralization under intact enamel, which is considered to be a reversible stage that may or may not progress into cavitated carious lesion. Kim et al. had reported prevalence of white spot lesions due to developmental defects of enamel ranging from 3.6% to 25% and that of post-orthodontic decalcification varies from 2% to 96%.²

One of the etiologies for white spot lesion is dental fluorosis, which occurs during tooth development due to chronic ingestion of excessive amounts of fluoride. Clinically, fluorosed enamel is characterized by white opacities that vary from minor striations to extensive areas of lusterless enamel to loss of surface layer of enamel. Histologically, increased amounts of fluoride will cause hypomineralization or porosity, in the enamel.³ With increasing severity, the porosity and depth of involvement are increased. In severe cases, post-eruptive breakdown of the tooth surface can result in pitting, which can predispose the underlying porous enamel to rapid staining and discoloration.⁴

Conventional techniques for treatment of white spot lesion of fluorosis include remineralization techniques with topical fluorides

^{1,3,4,6-8}Department of Pedodontics and Preventive Dentistry, SGT University, Gurugram, Haryana, India

²Department of Pediatric and Preventive Dentistry, Surendera Dental College and Research Institute, Sri Ganganagar, Rajasthan, India

⁵Department of Oral and Maxillofacial Surgery, Sudha Rustagi College of Dental Sciences and Research, Faridabad, Haryana, India

Corresponding Author: Shikha Dogra, Department of Pedodontics and Preventive Dentistry, SGT University, Gurugram, Haryana, India, Phone: +91 9205716200, e-mail: shikha.dogra87@gmail.com

How to cite this article: Dogra S, Goyal V, Gupta A, et al. Spectrophotometric Evaluation of Color Change in Tooth Enamel Defects Using Resin Infiltrate: An *In Vivo* Study. *Int J Clin Pediatr Dent* 2020;13(2):150–154.

Source of support: Nil

Conflict of interest: None

and CPP-ACP (casein phosphopeptide-amorphous calcium phosphate) application, bleaching therapy, microabrasion, veneers. Remineralization techniques are effective but esthetic effect may be less because remineralization is often restricted to the lesion surface. Moreover, it requires time and needs to be implemented at the very early stages of the lesion development.² Further bleaching techniques can lead to postoperative sensitivity and esthetic results may not be achieved. Microabrasion and veneers requires reduction of surface layer of enamel therefore, due to loss of sound tooth structure it can result in postoperative sensitivity. Also achievement of esthetic results may be questionable. Drawbacks of previous approaches in the treatment of fluorosed enamel led to the invention of resin infiltration concept via DMG Icon, i.e. a new minimally invasive technique through low-viscosity light-

cure resins that have been optimized for rapid penetration into the porous enamel.

DMG Icon consists of three components: (i) icon-etch containing 15% hydrochloric acid, pyrogenic silicic acid, water and additives; (ii) icon-dry: 99% ethanol; (iii) icon-infiltrant containing methacrylate-based resin matrix, initiators, additives. Kim et al. had reported that DMG Icon is designed to bridge the gap between prevention and restoration by filling and reinforcing the pore system of non-cavitated developmental defects of enamel with a light curable agent.⁵ The resin completely fills the pores within the tooth, replacing lost tooth structure and stopping the lesion progression by blocking further introduction of any nutrients into the pore system. With resin infiltration, lesions are stabilized while the anatomical shape and color of the non-cavitated smooth surface white spot defects of fluorosed enamel are masked.⁶

Keeping in mind the above said advantages of resin infiltration, this study was performed to analyze the comparative change in pre and posttreatment $L^*a^*b^*$ values of color (where L , lightness/darkness; a^* , red/green shade; b^* , yellow or blue shade) in initial non-pitted white spot lesions of fluorosed teeth after resin infiltration with DMG-Icon spectrophotometrically using VITA Easy Shade.

MATERIALS AND METHODS

This study was conducted in Department of Pediatric and Preventive Dentistry, in SGT Dental College and Hospital, Gurugram, after obtaining ethical clearance.

Materials Used

Rubber Dam Kit, Resin Infiltrate (DMG Icon).

Armamentarium

VITA 3D shade guide, spectrophotometer (VITA Easy Shade), light curing unit.

Methods

A total of 30 maxillary and mandibular permanent anterior teeth with mild, nonpitted white spot lesions (at least one) of fluorosis [till grade IV of Thylstrup and Fejerskov (TF) index of dental fluorosis] in patients between 6 years to 14 years of age were enrolled in the present study. The CIELAB space (usually abbreviated CIE for its French name, Commission Internationale de l'Éclairage to explain $L^*a^*b^*$ values of tooth color, where L , lightness/darkness; a^* , red/green shade; b^* , yellow or blue shade) was applied in this study, which is an international system for color measurement. Using CIELAB space, ΔE value of color change of teeth after application of DMG Icon was evaluated using formula $\Delta E = (\Delta L^2 + \Delta a^2 + \Delta b^2)^{1/2}$ from pretreatment and posttreatment $L^*a^*b^*$ values of tooth and white spot lesion area.⁷

Pretreatment shade of the selected 30 tooth samples and their white spot lesion area of fluorosis were recorded using VITA 3D shade guide and corresponding pretreatment $L^*a^*b^*$ values for the recorded tooth shade and white spot lesion area of fluorosis were noticed spectrophotometrically using VITA Easy Shade (Fig. 1).

The affected tooth was cleaned and isolated using rubber dam. Sufficient amount of icon-etch was applied on to the lesion site and was kept for 2 minutes. Icon-etch was rinsed with water for at least 30 seconds and dried with oil-free and water-free air. Then icon dry was applied onto the lesion site for 30 seconds and dried with oil-free and water free air. This was followed by application of icon-infiltrant onto the etched surface for 3 minutes and light-cured

for 40 seconds. After one minute a second layer of icon-infiltrant for 3 minutes was applied and light-cured^{8,9} (Fig. 2). The rubber dam was removed and posttreatment change in the shade of white spot lesion area of 30 study samples were noticed on VITA 3D shade guide and corresponding postoperative $L^*a^*b^*$ values of white spot lesion were noticed spectrophotometrically with VITA Easy Shade (Figs 1 and 2).

Patient satisfaction was evaluated and analyzed on the basis of 5-point Likert scale postoperatively after resin infiltration with DMG-Icon as very satisfied, satisfied, neutral, dissatisfied, very dissatisfied.¹⁰

RESULTS

After analyzing pre and posttreatment $L^*a^*b^*$ values of tooth color using spectrophotometer, i.e., VITA Easy Shade (from corresponding tooth shade and white spot lesion area shade from VITA 3D shade guide) in 30 study samples, pretreatment $\Delta E1$ values ranged from 3.16 to 13.15 with mean \pm SD (7.34 \pm 2.59) and posttreatment $\Delta E2$ values ranged from 3.00 to 11.66 with mean \pm SD (4.89 \pm 2.25). Net ΔE value was found to be in range of 0.09–8.91 with mean \pm SD (2.45 \pm 1.89). On statistical analysis, Wilcoxon signed ranks test was applied which showed p value $<$ 0.00001, i.e., highly significant (Table 1).

In this study, 26 tooth samples showed net ΔE values of color change lower than 3.7 and six samples had net ΔE values of color change greater than 3.7 (Fig. 3).

On 5-point Likert scale, 19 patients were found to be very satisfied, 8 patients were found to be satisfied, 3 patients were neutral and none of the patient was dissatisfied or very dissatisfied (Fig. 4).

DISCUSSION

Developmental defects of enamel are the visual deviation from its normal translucent appearance occurring due to defect in enamel organ formation and are described as hypoplastic, hypomaturative, hypomineralized enamel. Dental fluorosis is a chronic, fluoride-induced condition, in which enamel development is disrupted and the enamel is hypomineralized.¹¹

Maxillary central incisors are esthetically most important teeth are prone to the development of dental fluorosis in children who are exposed to excessive doses of fluoride between 20 months and 30 months of age. Critical period to fluoride overexposure is between 1 year and 4 years and the children above 8 years of age are considered not to be at risk. The safe level for daily fluoride intake is 0.05–0.07 mg F/kg/day. Above this level, due to chronic fluoride consumption there is a the risk of developing fluorosis.¹²

Extent of severity of dental fluorosis may vary from change in translucency of tooth enamel (white opaque lines) to loss of outer layer of enamel which changes anatomical shape and size of tooth. Clinically, most commonly employed measures for the determination of extent dental fluorosis are dean index (1942) and Thylstrup and Fejerskov (TF) index (1978). Adelário et al. had reported simplified Thylstrup and Fejerskov (TF) index as most suitable for determining the prevalence of dental fluorosis in regions with endemic fluorosis.¹³ Hence, in the present study, white spot lesions of fluorosis on maxillary and mandibular permanent anterior teeth till grade IV of Thylstrup and Fejerskov (TF) index of dental fluorosis were included.

Usually, nonpitted white spot lesions (WSPs) are managed by performing tooth bleaching, microabrasion, remineralization with




Fig. 1: Spectrometric evaluation of color change using VITA easy shade

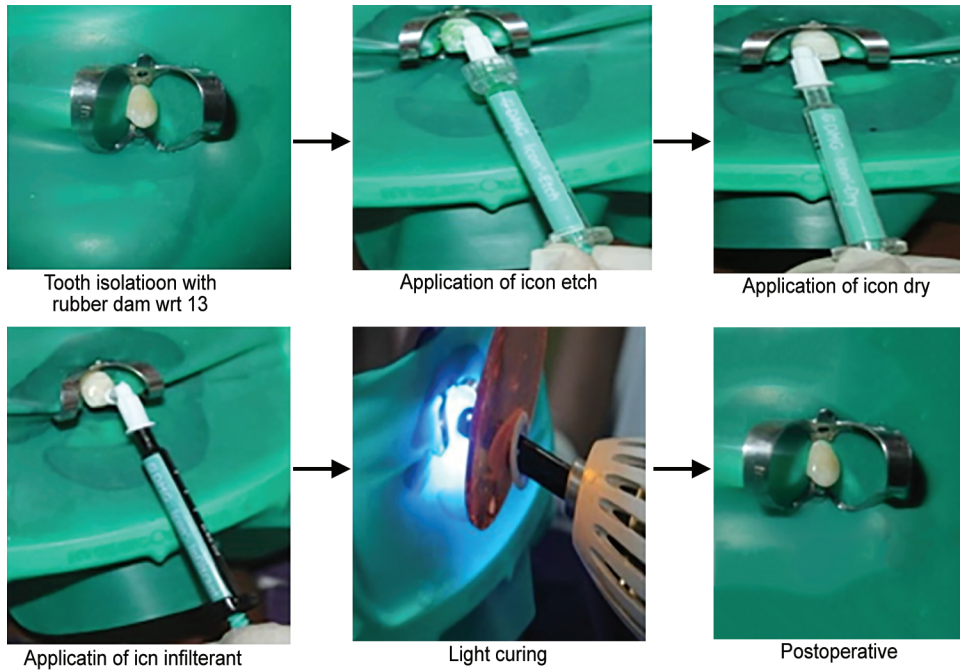


Fig. 2: Procedure of resin infiltration by DMG icon on tooth no. 23

Table 1: Wilcoxon signed rank test

Color change	n	Range	Mean ± SD	Std. error	Z value	p value
Pre- $\Delta E1$	30	3.16–13.15	7.34 ± 2.59	0.480	-4.7821	<0.00001
Post- $\Delta E2$	30	3.00–11.66	4.89 ± 2.25	0.417		
Net change ΔE	30	0.09–8.91	2.45 ± 1.89	0.350		

Pretreatment vs posttreatment color change showing p value < 0.00001, i.e., highly significant

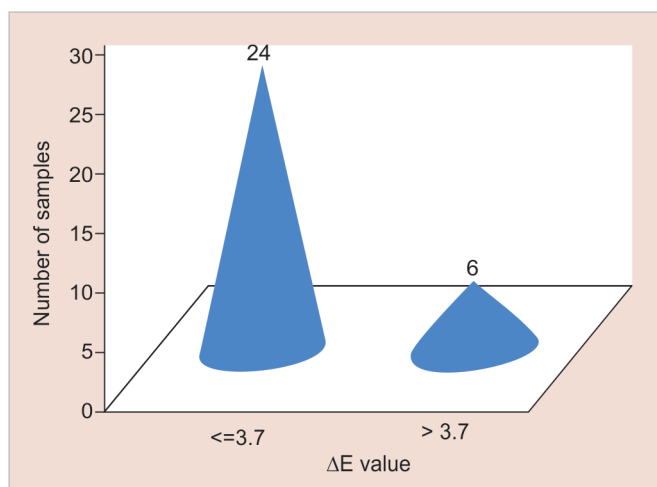


Fig. 3: Twenty four samples with net color change (ΔE) ≤ 3.7 and 6 samples with net color change (ΔE) > 3.7

casein phosphopeptide–amorphous calcium phosphate (CPP–ACP) or placement of veneers.¹⁴ Bleaching techniques employ oxidizing agents such as hydrogen peroxide or peroxide releasing agents to brighten teeth. Gugnani et al. had reported the gingival irritation, tooth sensitivity, and sometimes even reversible pulpitis as limitations with these agents.⁸

Owing to above described disadvantages of conventional approaches for management of nonpitted white spot lesions of fluorosis, a new resin infiltrate named ICON was introduced by DMG company (Hamburg, Germany) in year 2009. Initially this technique was proposed for infiltration of incipient carious lesions, allowing masking of white spots by modifying the optic properties of the enamel. The objective of this approach was to infiltrate microspaces and microporosities of the subsurface lesion (up to a 450 μm depth). Paris et al. in 2009 evaluated the masking of labial enamel white spot lesions of enamel by resin infiltration and reported that infiltrated lesions lose their whitish appearance and look similar to sound enamel.¹⁵

Further use of resin infiltration technique with DMG Icon in masking white spot lesions due to developmental defects of enamel and postorthodontic decalcifications was reported by Kim et al. in 2011.²

Also, Muñoz et al.¹⁶ had reported esthetic management of fluorosis and hypoplasia stains with this technique. They found that fluorosis stains showed visually marked improvement after resin infiltration (DMG Icon) than microabrasion.

In 2017 improvement in esthetics by this material was further reported by Knösel in developmental defects, i.e., molar incisor hypoplasia and enamel fluorosis.¹⁷ Hence, the present study was conducted to evaluate effect of resin infiltration technique [DMG-Icon] for masking non cavitated white spot lesions of fluorosis.

The ΔE value of color change of teeth after application of esthetic materials had been measured *in vivo* and *in vitro* using several techniques including spectrophotometers, colorimeters and image analyzing softwares.¹⁸ In the present study spectrophotometer (VITA Easy Shade) was used for analyzing ΔE value, which quantifies the discrepancy between the two colors.

Concerning color stability, a color change is said to be clinically visible in any site with ΔE data higher than 3.7 units. Ideally, ΔE value should be lower than 3.7 units after treatment with respective

esthetic restorative technique, indicating that a color difference between the two sites could not be seen by the naked eye.^{2,19}

In this study, 26 subjects showed net ΔE values of color change lower than 3.7 and six samples had net ΔE values of color change greater than 3.7 (Fig. 3), results were found to be statistically highly significant (as p value < 0.00001) (Table 1). This is due to the fact that infiltrant resin has very low viscosity, high surface tension, and low contact angle with the enamel. These properties are important for penetration of resin into the layer of lesion body.²

Further, esthetically masking white spot lesions by resin infiltration with DMG-Icon occur by modification in optical properties of enamel. These lesions are more obvious when the teeth are dry as enamel, water, and air have different refractive indices. Sound enamel has a refractive index of 1.62. Enamel becomes porous when demineralized. If the pores within the lesion are filled with water (refractive index: 1.33), the lesions will appear opaque as compared to the sound enamel. If dried, the water in the pores is replaced with air (refractive index 1.0), and the lesion becomes more apparent. On the other hand, when the microporosities are filled with infiltrant resin, the refractive index increase to 1.52. Hence the difference in refractive index between the infiltrated lesion and enamel is negligible therefore the lesions appear similar to the surrounding sound enamel.² In present study complete masking of non cavitated white spot lesions of dental fluorosis was found in 26 samples as net ΔE values of color change was less than 3.7 in these samples.

Resin infiltrant can be applied twice because of shrinkage of materials after first application resulting in the generation of space that can be occluded by a second application.² In this study, six samples had net ΔE values of color change greater than 3.7, i.e., lesions were partially masked. This might be due to error in tooth isolation or application technique of DMG Icon. In accordance to this, Son et al. compared the effectiveness of resin infiltration technique (Icon, DMG) with microabrasion (Opalustre, Ultradent Products, Inc.) in management of white spot lesions. They found neither microabrasion nor resin infiltration technique can remove white spot lesions completely, but resin infiltration technique seems to be more effective than microabrasion.²⁰

Hence most of our results were similar to those reported by Gugnani et al.⁸ who had evaluated esthetic improvement of white spot lesions and nonpitted fluorosis using resin infiltration technique in four clinical cases and reported that resin infiltration was a micro invasive, single sitting, painless procedure that remarkably improves the esthetics in nonpitted fluorosis and white spot lesion.

CONCLUSION

Resin infiltration with DMG Icon can improve the color of non-cavitated white spot lesions and the effect appears immediately after treatment. Moreover, no cavitation occurred after etching, even when the surface layer had been eroded completely. Hence it is much less invasive than conventional approaches and can be successfully used for treatment of tooth enamel defects.

CLINICAL SIGNIFICANCE

Noninvasive, painless achievement of esthetic results without loss of tooth structure. No postoperative sensitivity occurred in this procedure and esthetic results were achieved in single visit.

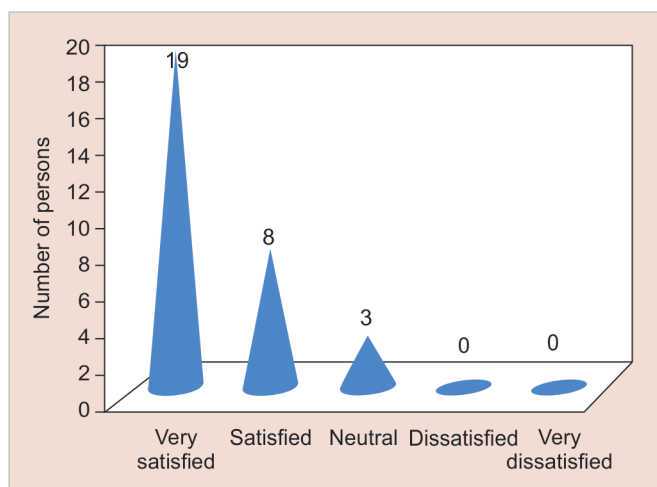


Fig. 4: Satisfaction level of patients posttreatment using 5-point Likert scale

ACKNOWLEDGMENTS

We would like to acknowledge Dr Vijay Prakash Mathur (Prof and Head, Department of Pedodontics and Preventive Dentistry, AIIMS, New Delhi, India), Prof Dr Neeraj Gugrani (Professor, Department of Pedodontics and Preventive Dentistry, DAV Dental College, Yamuna Nagar, Haryana, India) and Dr Deepali Sharma (Visiting Researcher at Wilfrid Laurier University, Canada) for providing help in completing this study.

REFERENCES

- dos Santos Medeiros MC, de Lima KC. Effectiveness of nightguard vital bleaching with 10% carbamide peroxide—a clinical study. *J Can Dent Assoc* 2008;74(2):163–163e.
- Kim S, Kim EY, Jeong TS, et al. The evaluation of resin infiltration for masking labial enamel white spot lesions. *Int J Paediatr Dent* 2011;21(4):241–248. DOI: 10.1111/j.1365-263X.2011.01126.x.
- Cavalheiro JP, Giroto-Bussaneli D, Restrepo M, et al. Clinical aspects of dental fluorosis according to histological features: a Thylstrup Fejerskov index review. *Rev CES Odont* 2017;30(1):41–50. DOI: 10.21615/cesodon.30.1.4.
- Train TE, McWhorter AG, Seale NS, et al. Examination of esthetic improvement and surface alteration following microabrasion in fluorotic human incisors *in vivo*. *Pediatr Dent* 1996;18(5):353–362.
- Kim JH, Son HH, Chang J. Color and hardness changes in artificial white spot lesions after resin infiltration. *Restor Dent Endod* 2012;37(2):90–95. DOI: 10.5395/rde.2012.37.2.90.
- Gugnani N, Pandit IK, Gupta M, et al. Caries infiltration of noncavitated white spot lesions: a novel approach for immediate esthetic improvement. *Contemp Clin Dent* 2012;3(Suppl 2):S199–S202. DOI: 10.4103/0976-237X.101092.
- Joiner A, Hopkinson I, Deng Y, et al. A review of tooth colour and whiteness. *J Dent* 2008;36(Suppl 1):S2–S7. DOI: 10.1016/j.jdent.2008.02.001.
- Gugnani N, Pandit IK, Goyal V, et al. Esthetic improvement of white spot lesions and non-pitted fluorosis using resin infiltration technique: series of four clinical cases. *J Indian Soc Pedod Prev Dent* 2014;32(2):176–180. DOI: 10.4103/0970-4388.130996.
- Subramaniam P, Girish Babu KL, Lakhotia D. Evaluation of penetration depth of a commercially available resin infiltrate into artificially created enamel lesions: an *in vitro* study. *J Conserv Dent* 2014;17(2):146–149. DOI: 10.4103/0972-0707.128054.
- Matsuda DK, Khatod M, Antounian F, et al. Multicenter outcomes of arthroscopic surgery for femoroacetabular impingement in the community hospital setting. *J Hip Preserv Surg* 2016;3(4):318–324. DOI: 10.1093/jhps/hnw024.
- Mascarenhas AK. Risk factors for dental fluorosis: a review of the recent literature. *Pediatr Dent* 2000;22(4):269–277.
- Abanto Alvarez J, Rezende KM, Marocho SM, et al. Dental fluorosis: exposure, prevention and management. *Med Oral Patol Oral Cir Bucal* 2009;14(2):E103–E107.
- Adelário AK, Vilas-Novas LF, Castilho LS, et al. Accuracy of simplified Thylstrup & Fejerskov index in rural communities with endemic fluorosis. *Int J Environ Res Public Health* 2010;7(3):927–937. DOI: 10.3390/ijerph7030927.
- Ng F, Manton DJ. Aesthetic management of severely fluorosed incisors in an adolescent female. *Aust Dent J* 2007;52(3):243–248. DOI: 10.1111/j.1834-7819.2007.tb00495.x.
- Paris S, Meyer-Lueckel H. Masking of labial enamel white spot lesions by resin infiltration—a clinical report. *Quintessence Int* 2009;40(9):713–718.
- Muñoz MA, Arana-Gordillo LA, Gomes GM, et al. Alternative esthetic management of fluorosis and hypoplasia stains: blending effect obtained with resin infiltration techniques. *J Esthet Restor Dent* 2013;25(1):32–39. DOI: 10.1111/j.1708-8240.2012.00527.x.
- Knösel M, Vogel R, Sandoval P. Infiltration of white-spot-lesions and developmental enamel defects. *Rev Clin Periodontol Implantol Rehabil Oral* 2017;10(2):101–106. DOI: 10.4067/S0719-01072017000200101.
- Chu SJ, Trushkowsky RD, Paravina RD. Dental color matching instruments and systems. Review of clinical and research aspects. *J Dent* 2010;38(Suppl 2):e2–e16. DOI: 10.1016/j.jdent.2010.07.001.
- Knösel M, Attin R, Becker K, et al. External bleaching effect on the color and luminosity of inactive white spot lesions after fixed orthodontic appliances. *Angle Orthod* 2007;77(4):646–652. DOI: 10.2319/060106-224.
- Son J-H, Hur B, Kim H-C, et al. Management of white spots: resin infiltration technique and microabrasion. *J Korean Acad Cons Dent* 2011;36(1):66–71. DOI: 10.5395/JKACD.2011.36.1.66.