

# Budd-Chiari syndrome in urology: Impact on nephrectomy for advanced renal cell carcinoma

Samir P. Shirodkar, Mark S. Soloway, Gaetano Ciancio<sup>1</sup>

Departments of Urology and <sup>1</sup>Surgery, Division of Transplantation, University of Miami Miller School of Medicine, Miami, USA

## ABSTRACT

**Objectives:** Budd-Chiari syndrome (BCS) is a poorly understood entity in urology. It results from obstruction of the hepatic veins and the subsequent complications. It has been infrequently reported to be secondary to hepatic venous obstruction from invasion by an inferior vena cava (IVC) tumor thrombus in renal cell carcinoma (RCC). We report the largest known series of patients with RCC and BCS.

**Patients and Methods:** Ten patients presented to a tertiary hospital with locally advanced RCC with IVC tumor thrombus. All were evaluated and had clinical or radiographic evidence of BCS. All underwent nephrectomy, IVC thrombectomy or ligation, and tumor removal from the hepatic veins. The perioperative and pathological factors were measured. These included estimated blood loss (EBL) and transfusions. Inpatient factors including duration of intubation, length of intensive care unit (ICU) stay, and overall length of stay (LOS) were recorded. The tumor-free status was evaluated.

**Results:** The average age was 59 years. No intraoperative deaths occurred. Two intraoperative complications were noted. The mean EBL was 4244 cc; mean surgery length was 8 hours 12 minutes; and the mean ICU stay was nine days. The overall LOS averaged 13.25 days. One patient died postoperatively of sepsis and multisystem organ failure. One patient required reoperation for an abdominal wall hematoma caused by subcutaneous enoxaparin administration. Average follow-up was 28 months. Five patients are alive with no evidence of disease.

**Conclusions:** Budd-Chiari syndrome is a rare entity in urology, with a potential for significant morbidity and mortality. Surgical excision of the primary tumor along with thrombectomy results in alleviation of BCS and improvement in the patient.

**Key words:** Budd-Chiari syndrome, hepatic vein thrombus, inferior vena cava thrombus, renal cell carcinoma

## INTRODUCTION

Budd-Chiari syndrome (BCS) is an infrequently encountered disease entity in urologic oncology. Defined as hepatic venous obstruction resulting in a spectrum of clinical manifestations, from asymptomatic to fulminant liver failure, it is most often caused by

a hypercoagulable state.<sup>[1]</sup> In urologic oncology, rare case reports have described the Budd-Chiari syndrome resulting from renal cell carcinoma (RCC) with an inferior vena cava (IVC) tumor thrombus that has invaded into the hepatic veins. Previously, a series with four patients has been reported.<sup>[2]</sup> We have reported a series of four patients and our management experience earlier.<sup>[3]</sup> The surgical approach to patients with BCS is complex and must encompass oncological efficacy, including full removal of the primary tumor and tumor thrombus, along with safe maneuvers, to ensure that there are no complications related to BCS and hepatic congestion. Finally, the underlying cause of BCS must be addressed and corrected.

**For correspondence:** Dr. Gaetano Ciancio, University of Miami Miller School of Medicine, Department of Surgery, Division of Transplantation, Post Office Box 012440, Miami, FL 33101, USA. E-mail: gciancio@med.miami.edu

Access this article online	
Quick Response Code:	Website: www.indianjurol.com
	DOI: 10.4103/0970-1591.85439

## PATIENTS AND METHODS

With the Institutional Review Board approval, ten patients with clinical and radiographic evidence of advanced renal cell carcinoma with Budd-Chiari syndrome were identified, within the period April 1998 to January 2008. The patients were evaluated preoperatively via computed

tomography (CT) and/or magnetic resonance imaging (MRI) scanning to delineate the extent of the tumor vascular thrombus [Figure 1a and b]. Clinically, four patients showed evidence of advanced BCS, including abdominal ascites, coagulopathy, and hepatomegaly. All were counseled on treatment options and elected to undergo surgery. This included nephrectomy and IVC thrombectomy, along with removal of tumor from the hepatic veins. When complete thrombectomy was not possible in cases of densely adherent thrombus to the caval wall, the IVC was ligated via vascular stapling.

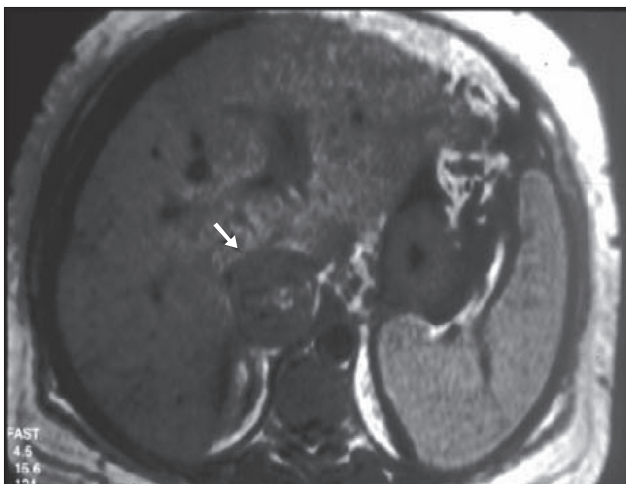
All patients were optimized medically including cardiac, pulmonary, and hepatology evaluation as necessary. Preoperative preparation included maintaining euvolemia and avoiding or treating any signs of extravascular fluid overload, including pulmonary edema and ascites. Any anticoagulation was held prior to surgery.

Surgical management was based on previously reported techniques applied from liver transplant surgery.<sup>[4,5]</sup> Initially, a subcostal incision was made on the side of the tumor. This was sometimes extended, if needed, to create a formal Chevron incision with a small xiphisternal extension. Ascitic fluid, if present in the abdomen, was drained as completely as possible. A Rochard retractor was then placed to elevate the diaphragm and allow for improved perihepatic or perisplenic visualization.

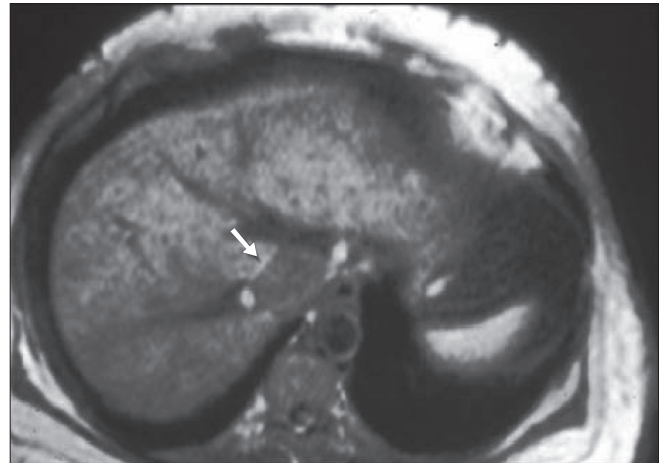
On the right side, the falciform ligament was taken down, as was the triangular ligament. The liver was then mobilized off the kidney. There was often significant collateralization, which had to be very carefully ligated and divided. The dissection then proceeded in the orthodox method for radical nephrectomy. We adhered to the early posterior ligation of the renal artery where possible, as we had found that this significantly decreased the collaterals and allowed for some decrease in the volume of the kidney.<sup>[6]</sup>

On the left side, the dissection proceeded similarly. The splenorenal attachments were taken down and the mobilization of the spleen and tail of the pancreas, with or without the stomach was done.<sup>[7]</sup> Splenodiaphragmatic ligaments were also meticulously ligated during the splenic mobilization steps. Mobilization of the kidney was continued posteriorly, along with early ligation of the artery, and completely circumferentially.

Subsequently, the IVC was mobilized to the level of the iliac veins. At the level of the liver and intrahepatic IVC there were often a great number of collaterals, which had to be meticulously ligated, to avoid hemorrhage. At this time, palpation of the tumor thrombus along with confirmation using transesophageal echocardiography (TEE) allowed the surgeon to accurately identify the level of the tumor thrombus. All the patients, except one, had intra-atrial tumor thrombus extension. Patient one had supradiaphragmatic infra-atrial tumor thrombus. Once the cranial extension of the thrombus had been noted, the next step was to perform the Pringle's maneuver, to temporarily occlude the vascular inflow to the liver. We recommend waiting for some time to allow the liver to decompress prior to proceeding with the case. At that time, further vascular clamps were placed to isolate the tumor. They should be placed in the following order: the infrarenal vena cava and left or right renal vein primarily, followed by the placement of a Satinsky clamp above the level of the tumor or at the right atrium, performed under TEE monitoring. In left-sided tumors, the adrenal vein was also clamped. If the patient was able to tolerate this without hypotension from the significant lower extremity venous collateralization, the cava was then opened. In all cases, except in one patient who was placed on cardiopulmonary bypass (CPB), the tumor thrombus, supradiaphragmatic IVC, and right atrium could be drawn down into the abdominal cavity via a transdiaphragmatic approach, using gentle caudal traction on the IVC and right atrium. In one patient, in anticipation of extensive



**Figure 1a:** Radiographic image of IVC tumor thrombus obstructing the hepatic veins (white arrow)



**Figure 1b:** Renal cell carcinoma tumor thrombus with invasion of the hepatic vein. The mosaic pattern of the liver after gadolinium enhancement is consistent with hepatic obstruction caused by tumor thrombus (white arrow)

blood and for fluid management, CPB and hypothermia were initiated. This was planned preoperatively based on the patient's known coagulopathy. Such planning allowed avoidance of CPB in 90% of the cases, with no additional morbidity to the patient.

The tumor thrombus was removed from the IVC and a thorough examination was performed, to ensure no residual tumor was left behind. At the ostium of the hepatic veins into the IVC, any visible tumor mass was grasped and removed. In two cases, the IVC could not be cleared due to the densely adherent tumor. In these situations the IVC was ligated using a vascular stapler. In one case, a segment of the IVC was resected due to adherent thrombus and this was patched using a Gore-Tex graft to re-establish patency of the vessel. Once the IVC was closed, all the clamps were removed and the closure proceeded in the normal fashion.

All patients were admitted to the intensive care unit (ICU) postoperatively. A nasogastric tube was placed in each patient and removed with return of the bowel function. Intraoperative variables including operative length, estimated blood loss (EBL), autologous (CellSaver) and heterologous blood transfusions, complications, and bypass procedure usage were recorded. Postoperative variables including length of ICU stay, overall length of stay, inpatient complications, and the need for reoperation were noted. Finally, the pathological findings were retrieved for each patient, including size, stage, grade, and histology. Long-term follow-up was recorded, along with the patient's disease status at the date of the latest follow-up. If the patient had died, the cause of death, along with relation of the disease status and surgical recovery were ascertained whenever possible.

## RESULTS

Of the ten patients, six were female. Six of the renal units were right-sided. The average age was 59 years (range 43-72 years). Average preoperative creatinine, when available, was 1.3 ng/dl. Mean EBL was 4,244 cc (range 100-9,000 cc). Mean length of surgery was 8 hours 12 minutes. Average heterologous blood transfusion rate was 12.2 units (range 0-30 units). Mean CellSaver replacement was 4,275 cc (range 1500-9,000 cc) in the four patients who received CellSaver. There were two intraoperative complications reported. Patient five had multiple episodes of intraoperative ventricular fibrillation along with asystole. He underwent cardioversion into sinus rhythm, but required sternotomy for cardiac exposure, and placement of a catheter into the right atrium because of fluid management and the need for extensive fluid and blood return. Patient four had significant blood loss during the Pringle Maneuver as a replaced hepatic artery was not included in the clamp. This was promptly corrected with no sequelae. Patient two required cardiopulmonary bypass (CPB) with deep hypothermic

circulatory arrest (DHCA), to gain adequate control of the most cranial portion of the tumor thrombus and also for her multiple comorbidities including coagulopathy, end-stage renal disease, and coronary artery disease. CPB was performed to ensure the patient's safety.

Postoperatively all patients were admitted to the ICU. The average ICU length of stay was nine days (range 2-15 days). Overall LOS was 13.25 days (range 6-18 days). Average discharge creatinine was 1.55 ng/dl (range 0.5-3.1 ng/dl). Patient eight died on postoperative day 22 after multiple episodes of sepsis and resultant multisystem organ failure. Patient three required prolonged intubation for respiratory failure, but was extubated on postoperative day 10. Patient four had a history of COPD and required re-intubation on postoperative day one with eventual extubation on postoperative day seven. Patient six had an abdominal wall hematoma noted postoperatively, for which she was taken to the operating room to evaluate for potential intra-abdominal hemorrhage. Her exploration was negative and it was felt that the hematoma was related to the injection of low molecular weight heparin (LMWH) in the abdominal subcutaneous tissue.

The mean tumor size was 8.65 cm (range 3-13 cm). All patients had clear cell, renal cell carcinoma. The mean Fuhrman grade of the tumor was 3.1 (range 2-4).

Average follow-up was 28 months (range 1-81 months). At the latest follow-up, five patients were alive. Patient one died 81 months postoperatively, with questionable recurrence. No extensive workup was undertaken for evaluation. Patient two died 17 months postoperatively with pulmonary metastases. Patient three had new lung metastases diagnosed 10 months postoperatively and was referred to Oncology. He had a favorable response to adjuvant therapies, but died after 22 months. Patient four was disease-free at 34 months. Patient five had retroperitoneal recurrence at 29 months and enrolled in an adjuvant trial, and currently alive. Patient six was disease-free at 32 months. Patient seven died seven months postoperatively from questionable metastases. Patient eight died in the postoperative period. Patients nine and ten were disease-free 12 months and one month postoperatively. Details of the operative variables, patient characteristics, and tumor pathologies are presented in Tables 1 and 2.

## DISCUSSION

Budd-Chiari syndrome is defined as obstruction of the hepatic veins resulting in congestive hepatopathy with eventual centrilobular fibrosis.<sup>[8]</sup> The clinical presentation can vary from asymptomatic radiographic findings to severe fulminant hepatic failure. The classic triad of presentation is abdominal pain, ascites, and hepatomegaly; however, a number of presenting symptoms may be detected.

**Table 1: Operative and postoperative variables**

Pt no	EBL (cc)	Transfusions (units)	Cell saver (cc)	Bypass used?	Intraoperative complications	Postoperative complications	IVC management
1	500	0	0	No	None	None	Open thrombectomy
2	NR	30	0	Yes, CPB with DHCA	None	None	Open thrombectomy, repair with Gore-Tex
3	7000	22	0	No	None	Prolonged Intubation	Oversewn IVC at hepatic vein
4	10000	7	5000	No	Unclamped artery in Pringle maneuver	None	Open thrombectomy
5	9000	30	9000	No, sternotomy, RA catheter for fluids	Vfib/asystole, cardioversion	None	Staple ligation
6	2000	7	0	No	None	Abdominal wall hematoma d/t LMWH	Open thrombectomy
7	2000	4	1500	No	None	None	Open thrombectomy
8	1600	8	0	No	Spleen injury	Prolonged Intubation, death	Open thrombectomy
9	6000	11	1600	No	None	None	Staple ligation
10	100	3	0	No	None	None	Open thrombectomy

EBL = Estimated blood loss, IVC = Inferior vena cava, NR = Not reported, CPB = Cardiopulmonary bypass, DHCA = Deep hypothermic circulatory arrest, RA = Right atrium, Vfib = Ventricular fibrillation, LMWH = Low molecular weight heparin, Liver tsp = Liver transplant

**Table 2: Pathological results**

Pt no	Age (years)	Sex	Tumor side	Tumor pathology	Fuhrman grade	Tumor size (cm)	Tumor stage	IVC thrombus level	Budd-Chiari sx
1	71	F	R	Clear cell	II	3.2	T3bNxMx	III d	Abd pain
2	43	F	L	n/a	III	5	T3cNxMx	IV	A, HML
3	50	M	R	Clear cell	III	9	T3cN0Mx	IV	Yes
4	42	M	L	Granular	III	8	T3cNxMx	IV	Yes
5	70	M	R	Clear cell	IV	12	T3cN1Mx	IV	Yes
6	52	F	R	Clear cell	III	8	T4NoMx	IV	Yes
7	71	M	R	n/a	III	4	T3bNxMx	IV	Yes
8	72	F	L	Clear cell	III	9	T3bNxMx	IV	HF
9	51	F	R	Clear cell	III	7	T3cNoMx	IV	Yes
10	67	F	L	Clear cell	IV	13	T3cNoMx	IV	Yes

A = Ascites, HML = Hepatomegaly, HF = Hepatic failure

The etiology can be divided into primary and secondary causes.<sup>[9]</sup> Primary BCS results from the direct occlusion of hepatic veins from an intraluminal source of the thrombus. Secondary BCS is caused by an extrinsic compression of either the IVC or the hepatic veins. The primary form of BCS is the most common, with an underlying hypercoagulable state present in most patients. This can include mutations in Factor V Leiden, Protein C and S deficiencies, and the presence of antithrombin. A number of other primary causes of BCS have been identified and covered in a number of excellent articles.<sup>[10,11]</sup> Secondary BCS can be related to hepatic cystic disease or some other external compression of the local vasculature, most commonly malignant disease of various abdominal organs.<sup>[12]</sup>

Treatment of BCS is initially anticoagulation, to prevent further propagation of the thrombus in the hepatic veins. Subsequently, a graded approach is taken by the treating physician teams — beginning with percutaneous angioplasty with stenting or thrombolysis, to recanalize the obstructed vasculature. If these maneuvers do not work, shunting may be performed. In the most difficult cases, liver transplantation is often the only remaining treatment option.

The Budd-Chiari syndrome that results from extensive RCC with IVC tumor thrombus invading the hepatic vessels has a number of similarities and differences from the BCS that results from the above-mentioned and cited inherited and acquired causes. It is a primary form of BCS, with



direct occlusion of the hepatic veins occurring by tumor thrombus propagation and not bland (vascular) thrombus. The diagnosis may be made in the same way as that of the other cases of BCS — by utilizing history, physical examination findings, laboratory data, and radiographic imaging. Patients may complain of right upper quadrant pain or abdominal distention. Chronic liver disease may be present, and rarely, patients may present with hepatic failure. On physical examination, the presence of ascites with hepatomegaly is the classical presentation of BCS. In our cohort, two patients had significant acute onset of abdominal distention and were found to have extensive ascites. On physical examination, they were noted to have marked hepatomegaly with mild tenderness on palpation of the liver edge. Each patient received radiographic imaging with CT and/or MRI scanning. In some cases, invasion of the hepatic veins was visualized on imaging studies [Figure 1], however, in other cases this was difficult to ascertain.

The most significant difference is the approach to treatment. In the case of primary BCS from RCC with IVC tumor thrombus invasion of the hepatic veins, the only appropriate treatment modality is surgical excision with removal of the tumor thrombus from the hepatic veins. Other reported treatments for BCS, including anticoagulation and percutaneous angioplasty with stenting will not be effective. Moreover, they may be very harmful, with the potential of dislodging a fragment of tumor during the percutaneous procedure, which results in pulmonary embolus. The surgical approach should not compromise the oncologic goals of the operation — it has been shown that even in the case of tumor thrombus, full surgical excision of RCC and the thrombus results in acceptable long-term survival, even when compared with patients without IVC tumor thrombus.<sup>[13,14]</sup> However, the presence of BCS sharply increases the complexity of the surgery. Primarily, some patients may have a coagulopathy related to a diminished hepatic function that interferes with appropriate clotting, increasing the risk of intra- and postoperative bleeding.

In our series, one patient had significant coagulopathy needing extensive intraoperative blood return. In her case, it was felt preoperatively that it would be safest to perform the surgery under cardiopulmonary bypass with deep hypothermic circulatory arrest, in order to minimize bleeding risks. Had other situations arisen, including intraoperative pulmonary thromboembolus or cranial extent of the tumor, much above what was anticipated by the surgical team, CPB was available and could be initiated. Fortunately, there were no other reasons for CPB in our experience with BCS and renal carcinoma. Additionally, hepatomegaly related to venous congestion in the liver posed another challenge during surgery. All patients had supradiaphragmatic tumor thrombi, and as a result, extensive liver mobilization needed to be performed. The large size of the liver and extensive vascular collateralization required a great deal of hepatic

manipulation including the Piggyback maneuver.<sup>[15]</sup> During these portions of the operation, given the size and vascularity of the liver, the risk of hepatic injury was extremely high. Adherence to strict surgical principles previously described, with minimal manipulation, allowed our series to have minimal complications during this portion of the surgery.

Our surgical approach followed the techniques that have been reported in the past for efficacious and safe treatment of extensive RCC with IVC thrombus.<sup>[16]</sup> Certain technical points are meticulously adhered to, including maintaining a plane outside of the Gerota's fascia, early ligation of the renal artery in the posterior plane,<sup>[6]</sup> en-bloc mobilization of the spleen and pancreas where appropriate,<sup>[7]</sup> and transdiaphragmatic excision of the supradiaphragmatic or intra-atrial tumor thrombus that avoids sternotomy and cardiopulmonary bypass whenever possible.<sup>[17]</sup> The curative management of BCS occurs when the IVC has been opened after gaining full control and isolation. When the ostium of the major and minor hepatic veins is identified, any tumor thrombus seen invading the veins is manually removed. Given the dense and vascular nature of the tumor, in most cases it is able to be removed intact from the ostium of the hepatic veins. Visual inspection is used to confirm all tumor thrombus removal, and then the remainder of the intracaval tumor thrombus is removed. In cases where the thrombus cannot be separated from the caval wall due to dense adherence, the IVC is either ligated with a vascular stapling or partially excised and patched with a Gore-Tex graft.<sup>[18]</sup>

The surgical outcomes resulting from these techniques and other pearls gleaned from our experience have been positive. We have had no intraoperative tumor emboli. Use of transesophageal echocardiography, preoperative planning, intraoperative palpation of the cranial extent of the tumor thrombus, minimal manipulation of the IVC, and proximal vascular control when possible, have allowed us to avoid this complication, which has been reported with high morbidity and mortality when it does occur.<sup>[19]</sup> Other surgical variables including blood loss and blood return are reported in Table 2.

One patient died in the immediate postoperative period. This patient had multiple episodes of sepsis eventually resulting in multisystem organ failure. She remained ventilator-dependent, had a tracheostomy tube placed, and was on continuous venovenous hemodialysis. During her last episode of sepsis, the family elected to withdraw care from the patient. Patients three and four had prolonged intubation due to respiratory failure. Patient four had a long history of chronic obstructive pulmonary disease, which probably contributed to this. Patient six had a large abdominal wall hematoma some days postoperatively. Concern for intra-abdominal bleeding along with a decrease in hematocrit prompted a re-exploration of the abdomen. There was no bleeding source found and it was felt that the hematoma was due to the subcutaneous injection

of low molecular weight heparin for anticoagulation. The patient's remaining course was uncomplicated. No other postoperative complications were reported.

At the last follow-up five patients were alive. Of the four patients who died after discharge, two were related to recurrent disease in the lung and retroperitoneum. In two patients, the cause of death was uncertain, but probably related to recurrence. The remaining five patients were disease-free at follow-up intervals ranging from one to 34 months. No patients alive at the last follow-up had exhibited any clinical or radiographic symptoms of BCS. Hepatic function was either normal at the time of discharge or returning to the normal range.

## CONCLUSIONS

Budd-Chiari syndrome is a rarely encountered state in urology. It is seen in renal cell carcinoma with an IVC tumor thrombus, with invasion of the hepatic veins, resulting in obstructive changes to the liver. The only effective treatment for BCS is removal of the tumor from the hepatic veins, and this should not compromise the remainder of the operation. Also the presence of BCS itself can complicate the surgery, including difficulties related to hepatomegaly, bleeding from coagulopathy, and extensive collateralization. All these should be planned for, and full excision performed, to ensure curative management of BCS and the most favorable outcomes from the standpoint of renal cell cancer. Long-term outcomes are positive in patients, with improvement in hepatic function and survival, postoperatively.

## REFERENCES

1. Aydinli M, Bayraktar Y. Budd-Chiari syndrome: Etiology, pathogenesis and diagnosis. *World J Gastroenterol* 2007;13:2693-6.
2. Kume H, Kameyama S, Kasuya Y, Tajima A, Kawabe K. Surgical treatment of renal cell carcinoma associated with Budd-Chiari syndrome: Report of four cases and review of the literature. *Eur J Surg Oncol* 1999;25:71-5.
3. Ciancio G, Soloway M. Renal cell carcinoma invading the hepatic veins. *Cancer* 2001;92:1836-42.
4. Ciancio G, Livingstone AS, Soloway M. Surgical management of renal cell carcinoma with tumor thrombus in the renal and inferior vena cava: The University of Miami experience in using liver transplantation techniques. *Eur Urol* 2007;51:988-94.
5. Ciancio G, Soloway M, Livingstone AS. The increasing use of liver transplantation surgical techniques in the management of renal and nonrenal cancer with or without inferior vena cava tumor thrombus. *World J Surg* 2009;33:1328-9.
6. Ciancio G, Vaidya A, Soloway M. Early ligation of the renal artery using the posterior approach: A basic surgical concept reinforced during resection of large hypervascular renal cell carcinoma with or without inferior vena cava thrombus. *BJU Int* 2003;92:488-9.
7. Ciancio G, Vaidya A, Shirodkar S, Manoharan M, Hakky T, Soloway M. En bloc mobilization of the pancreas and spleen to facilitate resection of large tumors, primarily renal and adrenal, in the left upper quadrant of the abdomen: Techniques derived from multivisceral transplantation. *Eur Urol* 2009;55:1106-11.
8. Valla DC. Hepatic vein thrombosis (Budd-Chiari syndrome). *Semin Liver Dis* 2002;22:5-14.
9. Hoekstra J, Janssen HL. Vascular liver disorders (I): Diagnosis, treatment and prognosis of Budd-Chiari syndrome. *Neth J Med* 2008;66:334-9.
10. Janssen HL, Meinardi JR, Vleggaar FP, van Uum SH, Haagsma EB, van Der Meer FJ, *et al.* Factor V Leiden mutation, prothrombin gene mutation, and deficiencies in coagulation inhibitors associated with Budd-Chiari syndrome and portal vein thrombosis: Results of a case-control study. *Blood* 2000;96:2364-8.
11. Deltre P, Denninger MH, Hillaire S, Guillin MC, Casadevall N, Briere J, *et al.* Factor V Leiden related Budd-Chiari syndrome. *Gut* 2001;48:264-8.
12. Janssen HL, Garcia-Pagan JC, Elias E, Mentha G, Hadengue A, Valla DC; European Group for the Study of Vascular Disorders of the Liver. Budd-Chiari syndrome: A review by an expert panel. *J Hepatol* 2003;38:364-71.
13. Glazer AA, Novick AC. Long-term follow-up after surgical treatment for renal cell carcinoma extending into the right atrium. *J Urol* 1996;155:448-50.
14. Lubahn JG, Sagalowsky AI, Rosenbaum DH, Dikmen E, Bhojani RA, Paul MC, *et al.* Contemporary techniques and safety of cardiovascular procedures in the surgical management of renal cell carcinoma with tumor thrombus. *J Thorac Cardiovasc Surg* 2006;131:1289-95.
15. Ciancio G, Hawke C, Soloway M. The use of liver transplant techniques to aid in the surgical management of urological tumors. *J Urol* 2000;164:665-72.
16. Cerwinka WH, Manoharan M, Soloway MS, Ciancio G. The role of liver transplantation techniques in the surgical management of advanced renal urothelial carcinoma with or without inferior vena cava thrombus. *Int Braz J Urol* 2009;35:19-23.
17. Ciancio G, Soloway MS. Renal cell carcinoma with tumor thrombus extending above diaphragm: Avoiding cardiopulmonary bypass. *Urology* 2005;66:266-70.
18. Hemming AW, Reed AI, Langham MR Jr, Fujita S, Howard RJ. Combined resection of the liver and inferior vena cava for hepatic malignancy. *Ann Surg* 2004;239:712-9.
19. Shuch B, Larochele JC, Onyia T, Vallera C, Margulis D, Pantuck AJ, *et al.* Intraoperative thrombus embolization during nephrectomy and tumor thrombectomy: Critical analysis of the University of California-Los Angeles experience. *J Urol* 2009;181:492-8.

**How to cite this article:** Shirodkar SP, Soloway MS, Ciancio G. Budd-Chiari syndrome in urology: Impact on nephrectomy for advanced renal cell carcinoma. *Indian J Urol* 2011;27:351-6.  
**Source of Support:** Nil, **Conflict of Interest:** None declared.