



Case Report

Subdural fluid accumulation caused by ventriculoperitoneal shunt underdrainage: A rare and paradoxical complication

Ruth Prieto¹, Matias Cea Soriano², Celia Ortega¹, Teresa Kalantari¹, Alberto Pueyo Rabanal²

Departments of ¹Neurosurgery, ²Surgery, Puerta de Hierro University Hospital, Madrid, Spain.

E-mail: *Ruth Prieto - rprieto29@hotmail.com; Matias Cea Soriano - matiascea8@gmail.com; Celia Ortega - celia.ortega92@gmail.com; Teresa Kalantari - teresa.kalantari@hotmail.com; Alberto Pueyo Rabanal - albertopueyo@gmail.com



***Corresponding author:**

Ruth Prieto, MD, PhD,
Department of Neurosurgery,
Puerta de Hierro University
Hospital, Madrid, Spain.

rprieto29@hotmail.com

Received : 08 September 2020

Accepted : 02 December 2020

Published : 22 December 2020

DOI

10.25259/SNI_620_2020

Quick Response Code:



ABSTRACT

Background: Subdural fluid collection in patients with internal cerebrospinal fluid (CSF) shunts has generally been linked to overdrainage and more rarely to pus accumulation. The authors present a previously unrecognized condition leading to extra-axial CSF accumulation: shunt underdrainage. Treatment of coexisting subdural fluid collection and hydrocephalus, disorders that have previously only been reported concurrently following head trauma or subarachnoid hemorrhage, is controversial. In addition, we intend to provide insight into the pathophysiology of abnormal CSF accumulation within both the subdural space and ventricles simultaneously.

Case Description: A 42-year-old female with a history of hypothalamic glioma and obstructive hydrocephalus during childhood presented with headache, vomiting, and gait disturbance. Following the insertion of her first ventriculoperitoneal shunt (VPS) by the age of 8, she underwent several surgeries due to shunt failure, all of them associating ventriculomegaly. Ventricles remained notably enlarged following insertion of her most recent VPS, and the computed tomography scan performed 2 months later at her admission showed a large subdural collection. Afterward, a malpositioned distal catheter causing shunt blockage was confirmed. Both, the subdural accumulation and hydrocephalus, were resolved following adequate placement of the peritoneal catheter.

Conclusion: This case demonstrates that subdural fluid accumulations may occur following VPS underdrainage with hydrocephalus. Development of such extra-axial collection was probably caused by pressure related to CSF spillage from the ventricles into the subdural space. Our case also supports that a mass-effect subdural accumulation with hydrocephalus can be satisfactorily treated with adequate VPS alone, without directly treating the subdural collection.

Keywords: Cerebrospinal fluid, External hydrocephalus, Shunt malfunction, Subdural accumulation, Ventriculoperitoneal shunt

INTRODUCTION

Subdural fluid accumulation in patients carrying artificial diversion systems generally corresponds to the abnormal collection of cerebrospinal fluid (CSF) in the subdural space secondary to shunt overdrainage and exceptionally to subdural empyema.^[2,5] To the best of our knowledge, abnormal CSF accumulation in the subdural space has not been previously reported in the context of distal shunt underdrainage with hydrocephalus. A thorough literature review found that concurrent subdural CSF collection and ventriculomegaly have been only reported in head injured patients

This is an open-access article distributed under the terms of the Creative Commons Attribution-Non Commercial-Share Alike 4.0 License, which allows others to remix, tweak, and build upon the work non-commercially, as long as the author is credited and the new creations are licensed under the identical terms.

©2020 Published by Scientific Scholar on behalf of Surgical Neurology International

or following subarachnoid hemorrhage (SAH) related to aneurysm rupture.^[1,3,4,6,7,10,11,13-15] Their management is controversial as most neurosurgeons consider that hydrocephalus cannot be treated until the subdural collection has no mass effect, and thus, patients are usually subjected to a tedious treatment including several surgeries.^[13] Nevertheless, in recent years, several cases with coexisting subdural CSF accumulation and hydrocephalus (either following SAH or head trauma) have satisfactorily been treated by placing a ventriculoperitoneal shunt (VPS) alone.^[3,7,11,14]

We present the first case report of VPS malfunction secondary to malposition of the distal catheter in a patient presenting with concomitant hydrocephalus and a large subdural accumulation. The underlying physiopathology and surgical strategy implemented are also discussed.

CASE DESCRIPTION

We present a 42-year-old female with a history of hypothalamic glioma and resultant obstructive

hydrocephalus that had been subjected to multiple surgeries since her childhood due to CSF shunt malfunction. Following her last VPS implantation, symptoms of high intracranial pressure (ICP) notably improved but ventricle enlargement remained almost unchanged on computed tomography (CT) [Figures 1a-c]. In addition, a coiled distal catheter was found on the abdominal X-ray, which was misinterpreted, probably due to patient obesity, as being in the correct position inside the peritoneal cavity [Figure 1d].

In the present admission, 2 months after the latest VPS placement, the patient complained of severe headache, vomiting, and gait disturbance. An urgent cranial CT demonstrated hydrocephalus in addition to a large low-density subdural collection over the right hemisphere with a minor right interhemispheric component [Figures 1e-g]. Macroscopic integrity of the whole shunt system was checked on plain radiographs, but because of a suspected dislocation of the peritoneal tip, a CT scan of the abdomen was performed. This revealed multiple loops of the distal catheter

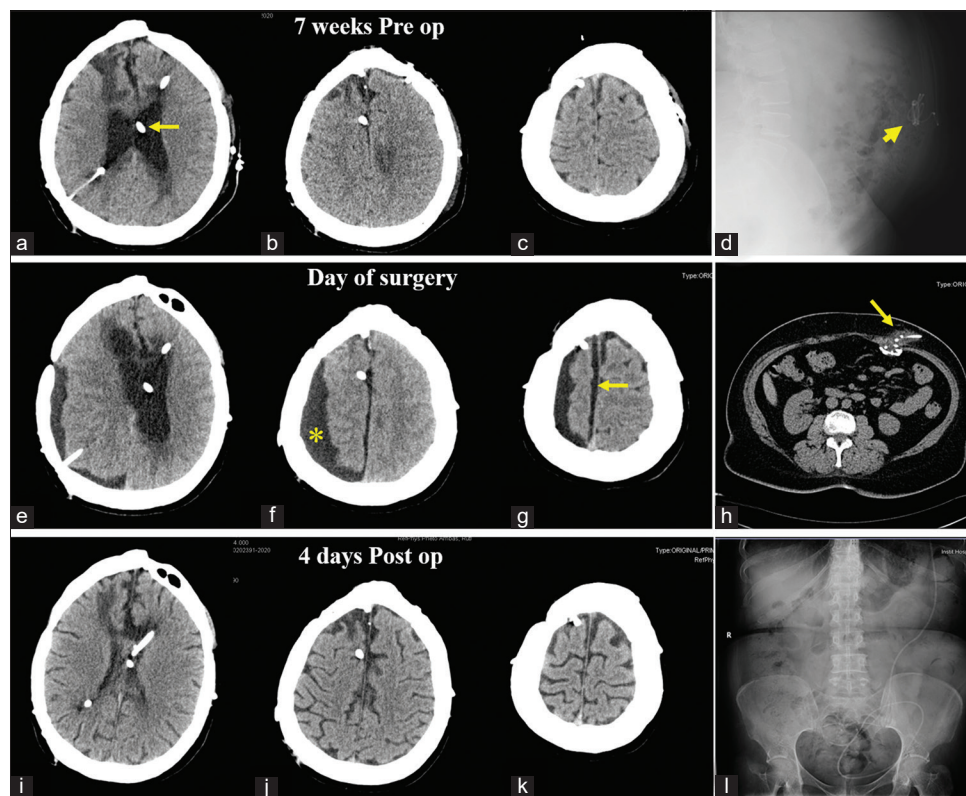


Figure 1: Preoperative and postoperative radiological studies. (a-c) Axial head computed tomography (CT) images obtained 7 weeks before current admission, that is, 1 week after placement of the latest ventriculoperitoneal shunt (VPS) (arrow), show persistence of hydrocephalus. (d) Lateral abdominal X-ray showing a coiled distal catheter (head arrow). (e-g) Head scan performed at admission demonstrating enlargement of the ventricular system in addition to a large extra-axial low-density collection over the right hemisphere (asterisk) with underlying effaced sulci and a minor subdural interhemispheric component (arrow). (h) Abdominal CT scan displaying multiple loops of the distal end of the VPS at the abdominal wall (arrow). (i-k) Postoperative CT scan performed after 4 days after intraperitoneal repositioning of the distal catheter demonstrates complete resolution of both hydrocephalus and the subdural collection. (l) Postoperative X-ray confirms correct intra-abdominal position of the VPS.

and CSF fluid accumulation at the subcutaneous space [Figure 1h]. Valve reservoir pumping demonstrated rapid reexpansion and the CSF was easily tapped. CSF Gram stain and culture revealed no microorganisms. Blood count and chemistries were also normal.

The paradox of finding a subdural accumulation (typically associated with VPS overdrainage) and hydrocephalus in a patient with distal VPS malposition generated perplexity and uncertainty for us regarding the most appropriate surgical strategy. Draining the subdural accumulation was considered in addition to repositioning the peritoneal catheter. Nevertheless, the delayed development of the subdural collection following several weeks of hydrocephalus in a patient with shunt malfunction led us to consider that both abnormal fluid accumulations might be related to the blocked CSF flow. Thus, we finally recommended VPS revision alone. We first performed a minilaparotomy, which revealed a pseudocyst encompassing the distal end of the catheter. Once adequate CSF outflow was verified, the fibrous capsule was partially resected, and the catheter repositioned intraperitoneally. Following surgery, all symptoms resolved, and postoperative CT performed on day 4 showed resolution of both hydrocephalus and subdural CSF accumulation [Figures 1i-k]. Moreover, postoperative abdominal X-ray confirmed correct placement of the distal peritoneal catheter

[Figure 1l]. After the 2-month follow-up, the clinical and radiological courses remain satisfactory [Figure 2].

We wish to highlight both the time frame of the development and resolution of the subdural accumulation, as well as the successful surgical strategy chosen. CSF accumulation occurred in a delayed fashion following several weeks of ventriculomegaly, and it was completely resolved by the 4th postoperative day after only VPS revision, which points to a shift of excessive CSF from the ventricles to the subdural compartment as the underlying mechanism for subdural fluid accumulation in our patient.

DISCUSSION

Malfunction of CSF shunting devices is still a common and challenging problem in neurosurgery.^[2] The case that we report had a subdural CSF accumulation associated with hydrocephalus, the first finding considered by most neurosurgeons as a sign of VPS overdrainage, whereas the latter related to shunt underdrainage. This paradoxical conjunction has not previously been reported in patients with shunt malfunction and thus gave rise to considerable diagnostic and therapeutic uncertainty. An accurate understanding of the pathophysiological mechanisms underlying subdural collections associated with hydrocephalus is essential to choose a safe and effective treatment. Such a circumstance (coexisting subdural accumulation and hydrocephalus) has only been reported in adults suffering from aneurysmal SAH and/or head trauma, whether or not surgery was performed for aneurysm clipping or decompressive craniectomy.^[1,3,4,6,7,10,11,13-15] Several terms have been used to refer to the simultaneous presence of hydrocephalus and subdural CSF accumulation, the most widespread being “subdural effusion with hydrocephalus” and “external hydrocephalus in adults.”^[3,10,11,14,15] Regardless of terminology, it is of paramount importance to be aware of this condition's severity, causing high ICP and thus requiring prompt surgical treatment, in contrast to the benign course of external hydrocephalus in infants and subdural hygromas. Accordingly, a recent study proved that subdural pressure was significantly higher (>15 cm H₂O) in subdural collections associated with hydrocephalus than in simple hygromas related to brain atrophy.^[6]

Treatment strategy of concomitant hydrocephalus and subdural CSF accumulations

The preferred treatment strategy for mass effect subdural collections associated with hydrocephalus has been through two different surgical stages, each one directed at each type of abnormal CSF accumulation. Initial surgical procedures are usually focused on subdural surgical drainage, either through subdural-peritoneal shunts or single burr holes. In

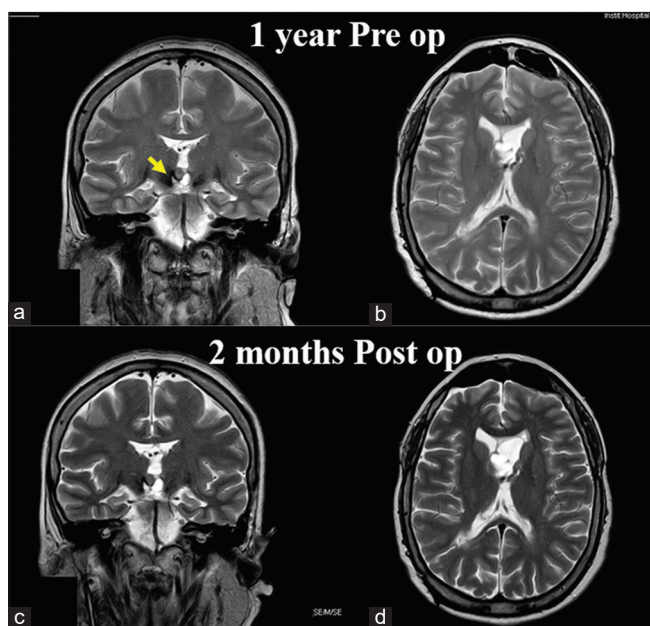


Figure 2: Preoperative and postoperative magnetic resonance imaging studies. (a and b) T2-weighted MR images obtained 1 year before current admission (at a time with adequate functioning of her internal cerebrospinal fluid diversion system). Note the tumor occupying the third ventricle (arrow). (c and d) Images obtained 2 months after correct placement of the distal catheter demonstrates recovery of previous ventricular size and lack of subdural accumulation.

a later stage, after the mass effect of the extra-axial collection has been solved, treatment is focused on ventricular dilatation, usually with VPS placement.^[13] This classic two-step strategy is based on the fact that diversion of CSF is known to be perilous for the vast majority of subdural collections, including chronic subdural hematomas or subdural hygromas, as it usually leads to their enlargement or replacement by air.^[9,14] Nevertheless, this multiple stage treatment has recently been questioned as it usually forces patients to undergo repeated surgical procedures because the primary cause (hydrocephalus) remains untreated until the final stage. Moreover, drainage of subdural collections may lead to infections of the central nervous system, which will delay definitive treatment of hydrocephalus.

An increasing number of neurosurgeons advocate VPS as a sole surgical procedure in patients with concomitant hydrocephalus and subdural CSF accumulation. Some reports demonstrating successful resolution of hydrocephalus and subdural collections, either related to SAH,^[3,14] ruptured intracranial aneurysmal clipping,^[1,7] or head injury,^[10,11] following VPS insertion have been published in the past two decades. Likewise, subdural accumulation in our patient disappeared when her hydrocephalus related to VPS distal blockage was solved following correct placement of the peritoneal catheter.

Physiopathology underlying abnormal CSF accumulation within the ventricular and subdural cavities

Development of subdural fluid collections in patients with concomitant hydrocephalus following SAH or head trauma has been related to a communication between the ventricles and the subdural space, either through traumatic arachnoid tearing or surgical violation of parachiasmatic/Liliequist membranes.^[7,8,10,11,14] In many of these cases, subdural CSF accumulation came before ventricle enlargement, a fact that has been related to a lower resistance in the subdural compartment than at the ependymal layer at the onset of hydrocephalus.^[3,7]

Nonetheless, in the case that we report, enlargement of the ventricles preceded the development of the subdural collection. Extra-axial CSF accumulation was probably related to a low resistance transparenchymal path between the ventricles (where CSF was accumulated at a high pressure due to VPS blockage) and the subdural space (a low-pressure compartment). Such a path could be either the surgical transfrontal route used to approach the tumor or along the old parietal ventricular catheter, both of which associate surgical violation of the arachnoid membranes. Moreover, recent studies have described a new mechanism involved in physiological CSF drainage along Virchow-Robin perivascular spaces toward meningeal and cervical lymphatic vessels. This glymphatic CSF drainage seems to predominate

in patients with hydrocephalus.^[1,12] Dependency on vessel pulsation for adequate lymphatic drainage raises the possibility that the high ICP in our patient with obstructive hydrocephalus might have also impaired normal pulsatile CSF flow along perivascular spaces and thus contributed to fluid accumulation in the subdural compartment.^[1]

Complete resolution of the subdural collection once the VPS in our patient recovered normal functioning supports that communication between the ventricles and the subdural space is two way and unobstructed. Finally, its rapid disappearance within only 4 days of VPS revision is probably related to the elasticity of a young brain.

CONCLUSION

To the best of our knowledge, this is the first case report documenting a subdural fluid collection coexisting with hydrocephalus secondary to CSF shunt underdrainage. Satisfactory clinical course with complete resolution of both subdural CSF accumulation and hydrocephalus following a single surgery aimed at fixing shunt malposition supports that such an extra-axial collection was secondary to pressure-related CSF spillage from the ventricles into the subdural space. Awareness of this rare and paradoxical type of VPS malfunction is essential to expedite accuracy in diagnosis and provide adequate treatment.

Acknowledgments

We wish to express our gratitude to Ana Puerto and Cristina Escudero, librarians of Puerta de Hierro University Hospital (Madrid, Spain) for their kind assistance during the process of retrieving some of the original articles used in this study. We are also grateful to George Hamilton for his critical review of the language and style of the manuscript.

Declaration of patient consent

The authors certify that they have obtained all appropriate patient consent.

Financial support and sponsorship

Nil.

Conflicts of interest

There are no conflicts of interest.

REFERENCES

1. Akins PT, Guppy KH. Are hygromas and hydrocephalus after decompressive craniectomy caused by impaired brain pulsatility, cerebrospinal fluid hydrodynamics, and glymphatic drainage? Literature overview and illustrative cases. *World*

- Neurosurg 2019;130:e941-52.
2. Broggi M, Zattra CM, Schiariti M, Acerbi F, Tringali G, Falco J, *et al.* Diagnosis of ventriculoperitoneal shunt malfunction: A practical algorithm. *World Neurosurg* 2020;137:e478-86.
 3. Cardoso ER, Shubert R. External hydrocephalus in adults. Report of three cases. *J Neurosurg* 1996;85:1143-7.
 4. Escosa-Bagé M, Sola RG. Physiopathology of adult onset external hydrocephalus. *Rev Neurol* 2002;35:141-4.
 5. Feletti A, d'Avella D, Wikkelso C, Klinge P, Hellström P, Tans J, *et al.* Ventriculoperitoneal shunt complications in the European idiopathic normal pressure hydrocephalus multicenter study. *Oper Neurosurg (Hagerstown)* 2019;17:97-102.
 6. Huh PW, Yoo DS, Cho KS, Park CK, Kang SG, Park YS, *et al.* Diagnostic method for differentiating external hydrocephalus from simple subdural hygroma. *J Neurosurg* 2006;105:65-70.
 7. Kawaguchi T, Fujita S, Hosoda K, Shibata Y, Komatsu H, Tamaki N. Treatment of subdural effusion with hydrocephalus after ruptured intracranial aneurysm clipping. *Neurosurgery* 1998;43:1033-8.
 8. Naffziger HC. Subdural fluid accumulation following head injury. *J Am Med Assoc* 1924;82:1751-2.
 9. Samuelson S, Long DM, Chou SN. Subdural hematoma as a complication of shunting procedures for normal pressure hydrocephalus. *J Neurosurg* 1972;37:548-51.
 10. Tsuang FY, Huang AP, Tsai HY, Chen JY, Lee JE, Lu YK, *et al.* Treatment of patients with traumatic subdural effusion and concomitant hydrocephalus. *J Neurosurg* 2012;116:558-65.
 11. Tzerakis N, Orphanides G, Antoniou E, Sioutos PJ, Lafazanos S, Seretis A. Subdural effusion with hydrocephalus after severe head injury: Successful treatment with ventriculoperitoneal shunt placement: Report of 3 adult cases. *Case Rep Med* 2010;2010:743784.
 12. Weller RO, Djuanda E, You HY, Carare RO. Lymphatic drainage of the brain and the pathophysiology of neurological disease. *Acta Neuropathol* 2009;117:1-14.
 13. Wu R, Ye Y, Ma T, Jia G, Qin H. Management of subdural effusion and hydrocephalus following decompressive craniectomy for posttraumatic cerebral infarction in a patient with traumatic brain injury: A case report. *BMC Surg* 2019;19:26.
 14. Yoshimoto Y, Wakai S, Hamano M. External hydrocephalus after aneurysm surgery: Paradoxical response to ventricular shunting. *J Neurosurg* 1998;88:485-9.
 15. Zanini MA, de Lima Resende LA, de Souza FA, Gabarra RC. Traumatic subdural hygromas: Proposed pathogenesis based classification. *J Trauma* 2008;64:705-13.

How to cite this article: Prieto R, Cea Soriano M Ortega C, Kalantari T, Pueyo Rabanal A. Subdural fluid accumulation caused by ventriculoperitoneal shunt underdrainage: A rare and paradoxical complication. *Surg Neurol Int* 2020;11:451.