

Applications of Computer Technology in Complex Craniofacial Reconstruction

Kristopher M. Day, MD*†
 Kyle S. Gabrick, MD†
 Larry A. Sargent, MD, FACS,
 FAAP*†

Background: To demonstrate our use of advanced 3-dimensional (3D) computer technology in the analysis, virtual surgical planning (VSP), 3D modeling (3DM), and treatment of complex congenital and acquired craniofacial deformities.

Methods: We present a series of craniofacial defects treated at a tertiary craniofacial referral center utilizing state-of-the-art 3D computer technology. All patients treated at our center using computer-assisted VSP, prefabricated custom-designed 3DMs, and/or 3D printed custom implants (3DPCI) in the reconstruction of craniofacial defects were included in this analysis.

Results: We describe the use of 3D computer technology to precisely analyze, plan, and reconstruct 31 craniofacial deformities/syndromes caused by: Pierre-Robin (7), Treacher Collins (5), Apert's (2), Pfeiffer (2), Crouzon (1) Syndromes, craniosynostosis (6), hemifacial microsomia (2), micrognathia (2), multiple facial clefts (1), and trauma (3). In select cases where the available bone was insufficient for skeletal reconstruction, 3DPCIs were fabricated using 3D printing. We used VSP in 30, 3DMs in all 31, distraction osteogenesis in 16, and 3DPCIs in 13 cases. Utilizing these technologies, the above complex craniofacial defects were corrected without significant complications and with excellent aesthetic results.

Conclusion: Modern 3D technology allows the surgeon to better analyze complex craniofacial deformities, precisely plan surgical correction with computer simulation of results, customize osteotomies, plan distractions, and print 3DPCI, as needed. The use of advanced 3D computer technology can be applied safely and potentially improve aesthetic and functional outcomes after complex craniofacial reconstruction. These techniques warrant further study and may be reproducible in various centers of care. (*Plast Reconstr Surg Glob Open* 2018;6:e1655; doi: 10.1097/GOX.0000000000001655; Published online 6 March 2018.)

INTRODUCTION

Since its advent in the 1980s,¹ advanced 3-dimensional (3D) computer technologies have transformed many health care fields and enabled many new treatment paradigms.² Virtual surgical planning (VSP)³ and 3D modeling

(3DM)⁴ are 2 tools used in craniofacial surgery due to advances in imaging resolution⁵ and rigid biomaterial production⁶ in recent decades. Some centers use these techniques routinely in complex reconstruction, such as free flap mandible reconstruction.⁷⁻¹¹ The concept of patient-specific custom implants (PCI) for craniofacial reconstruction predates such advanced 3D technical developments by nearly a decade,¹² though the fabrication of craniofacial PCIs by 3D printing (3DPCI) has occurred only recently.¹³⁻¹⁷ A systematic review in 2016 by Bauermeister et al.¹⁸ identified 226 articles on the biologic application of 3D printing. Kamali et al.¹⁹ suggests that 3D printing in medicine will grow into a multibillion-dollar industry within the next 10 years. Gerstle et al.²⁰ suggests that "plastic surgeons may likely find this technology indispensable ... in the near future." As advanced 3D technologies continue to proliferate, it becomes imperative to assess their impact on the treatment of complex craniofacial deformities and become familiar with the use of VSP, 3DM, and 3DPCI.

From the *Department of Plastic Surgery, University of Tennessee Chattanooga College of Medicine, Chattanooga, Tenn.; †University of Tennessee Chattanooga College of Medicine, Chattanooga, Tenn.; and ‡Department of Neurosurgery, University of Tennessee Chattanooga College of Medicine, Chattanooga, Tenn.

Received for publication April 17, 2017; accepted December 8, 2017.

Presented at the 59th Annual Scientific Meeting of the Southeastern Society of Plastic and Reconstructive Surgery, June 12, 2016, Lake Buena Vista, Fla.

Copyright © 2018 The Authors. Published by Wolters Kluwer Health, Inc. on behalf of The American Society of Plastic Surgeons. This is an open-access article distributed under the terms of the Creative Commons Attribution-Non Commercial-No Derivatives License 4.0 (CCBY-NC-ND), where it is permissible to download and share the work provided it is properly cited. The work cannot be changed in any way or used commercially without permission from the journal.

DOI: 10.1097/GOX.0000000000001655

Disclosure: The authors have no financial interest to declare in relation to the content of this article. The Article Processing Charge was paid for by the authors.

The use of 3DPCIs is a burgeoning area within craniofacial surgery, but craniofacial surgery may be particularly suited to employ these 3D reconstructive modalities, since craniofacial deformities treated so often involve complex geometric shapes with rigid composition. Modern computer-aided VSP and 3D modeling (3DM) are now employed to enhance the diagnostic analysis, anatomic orientation, individualized surgical planning, patient consent, virtual and physical simulation of results, and educational yield in craniofacial surgery.^{18–21} Specific applications of 3D technologies in craniofacial surgery include cranioplasty, orthognathics, traumatic maxillofacial reconstruction, facial skeletal augmentation for congenital deficiencies, distraction osteogenesis vector analysis, and facial contouring procedures.^{22–36}

In this report, we review our experience with the correction of syndromic and nonsyndromic congenital and acquired craniofacial deformities using advanced 3D technology. We describe the process of VSP, 3DM, and 3DPCI production as well as indications for employing these techniques.

MATERIALS AND METHODS

In accordance with all ethical standards of clinical research, this study was performed with Institutional Review Board approval from the University of Tennessee (#15–128). We present a series of craniofacial defects treated at a tertiary craniofacial referral center utilizing state-of-the-art 3D computer technology.

We identified all patients from our center's database who received VSP, 3DM, or a 3DPCI. The VSP planning sessions were conducted online based on images obtained at our center. Patients' images from craniofacial "thin-cut" protocol computerized tomography (CT) scans with 3D reconstruction were transferred via secure cloud computing in the form of a Digital Imaging and Communications in Medicine Image Files (.dcm). Virtual manipulation of these images during a computer-aided VSP session was then conducted online with the surgeon and a biomedical computer engineering specialist.

A 3DM was constructed in cases that featured significant complexity to refine the operative plan in the physical environment, aid the surgeon's assessment of complex anatomy, augment clinical teaching opportunities, and enable the simulation of portions of the operation. For select cases demonstrating deficient bone, a 3DPCI was fabricated using 3D printing and an established industrial processing system ("Patient Specific Implants," KLS Martin, Inc.; Jacksonville, Fla.).³⁷ Our material of choice for the majority of custom implants is polyether ether ketone (PEEK; ISO 10993 specifications), which is generated using an additive manufacturing method.³⁷ Other materials include polyethylene, which allows for tissue ingrowth.

The 3DPCI was designed by segmental mirroring of the contralateral, unaffected anatomy to approximate a normal anatomic state in cases involving unilateral pathologies.³⁸ In cases involving bilateral deformities, age and gender were used to generate a baseline structure, which was then refined under the direction of the operative sur-

geon on a case-by-case basis. Implants were often designed in combination with other alloplastic components, such as titanium orbital floor reconstructive mesh. Physical simulation of the operative plan was frequently conducted on the 3DM, to which 3DPCI's fit could be confirmed preoperatively. The 3DM and 3DPCI were then sterilized and used to refine and prepare for surgical execution immediately before in situ placement in the operating room.

RESULTS

Patients and Demographics

We describe the use of 3D computer technology to precisely analyze, plan, and reconstruct 31 craniofacial deformities caused by: Pierre-Robin Sequence (7), Treacher Collins (5), Apert's (2), Pfeiffer (2), Crouzon (1) Syndromes, craniosynostosis (6), hemifacial microsomia (2), micrognathia (2), multiple facial clefts (1), and trauma (3). The majority of patients' defects were due to congenital causes ($n = 28$, 32.1% male) and had an average age of 3.4 ± 5.4 years. Of these, 21 were syndromic in nature and 7 were nonsyndromic. Acquired cases were due to trauma and represented the smallest subgroup ($n = 3$, 100% male) with an average age of 36.5 ± 13.2 years.

Technologies Utilized

We utilized VSP in 30 cases included in this analysis, including 16 cases employing distraction osteogenesis. Models were generated for all 31 cases, and 3DPCIs were used in 13 cases overall. All 3 acquired cases employed VSP and 3DM. Two of these exhibited deficient native bone stock, requiring a 3DPCI. For congenital patients, VSP was used in 96.4% (27/28), distraction osteogenesis was conducted in 57.1% (16/28), and 3DPCI's were implanted in 39.3% (11/28). The most common 3DPCI material used for congenital and acquired defects was PEEK. Table 1 lists each technology employed per patient, and Table 2 summarizes the use of the 3D technologies by type of defect. Utilizing these technologies, the above complex craniofacial defects were corrected with excellent aesthetic results, as demonstrated in the following case examples. All surgical procedures were performed by the senior author (L.A.S.).

Case Examples 1 and 2: VSP and Distraction Osteogenesis

Figures 1, 2 display 2 patients who were treated after VSP of distraction osteogenesis. The first case displays a case of nonsyndromic unilateral coronal craniosynostosis (Fig. 1). This patient was born nearly 9 weeks premature and presented for consultation at 8 weeks of age, weighing approximately 7 pounds. Her preoperative photographs demonstrate a right harlequin deformity of the supraorbital region with a flattened and retruded right forehead and brow with a slight rightward deviation of the nasal pyramid. As can be seen in the 3D reconstruction of her CT scan, the entire right coronal suture is fused. During the VSP session, the strip craniectomy and extent of distraction were planned with virtual manipulation of the 3D reconstructed image. Distractors were removed 13 weeks later following a distraction phase with 0.5 mm twice daily

Table 1. Patients Treated with 3D Computer Technology

Sample Size (Male, Female)	Age (y)	Etiology/Syndrome	Defects Addressed with 3D Technology	Procedures Conducted Using 3D Technology	Technology Utilized
Syndromic congenital 7 (3, 4)	0.23	Pierre-Robin	Micrognathia	Bilateral mandibular osteotomies, internal mandibular distraction	VSP, 3DM, DO
5 (2, 3)	12.1	Treacher-Collins	Zygomatic hypoplasia, micrognathia, mid-face eyelid deformities	Bilateral orbitozygomatic custom implants, titanium mesh orbital floor reconstruction, orbicularis muscle flaps, lateral canthopexy	VSP, 3DM, 3DPCI
2 (0, 2)	0.75	Apert's	Craniosynostosis	Anterior and posterior craniotomies, distraction, forehead advancement, brow bone graft, skull remodeling, suboccipital decompression	VSP, 3DM, DO
2 (0, 2)	0.4	Pfeiffer	Craniosynostosis	Bifrontal craniotomies and anterior distraction	VSP, 3DM, DO
1 (1, 0)	0.4	Crouzon	Craniosynostosis	Craniotomies and distraction	VSP, 3DM, DO
1 (0, 1)	0.4	Micrognathia	Micrognathia	Bilateral sagittal split osteotomies followed by custom mandibular implants	VSP, 3DM, 3DPCI
2 (1, 1)	5.2	Hemifacial Microsomia	Unilateral micrognathia	Unilateral mandibular distraction	VSP, 3DM, DO
1 (0, 1)	14.2	Facial clefts	Unilateral complex facial clefting, anophthalmia	Multistage reconstruction with soft-tissue mobilization, bony reconstruction, and osteointegrated implant	3DM, 3DPCI
Nonsyndromic congenital 6 (1, 5)	0.7	Craniosynostosis	Pan-craniosynostosis	Craniotomy, distraction, skull reconstruction, suboccipital decompression	VSP, 3DM, 3DPCI, DO
1 (1, 0)	0.4	Micrognathia	Micrognathia	Bilateral custom mandibular implants, sagittal split osteotomies	VSP, 3DM, 3DPCI
Acquired 3 (3, 0)	36.5	Trauma	Enophthalmos, vertical orbital dystopia, zygomatic and frontal bone defects	Custom osteotomies, frontal cranio-plasty, orbital and zygomatic reconstruction with custom implants and titanium mesh, canthopexy, levator plication	VSP, 3DM, 3DPCI

Table 2. Summary of 3D Technology Utilized by Patient Type

Patients	Sample Size	Technology			
		VSP	3DM	DO	3DPCI
Congenital					
Syndromic	21	20	21	13	7
Nonsyndromic	7	7	7	3	4
Acquired	3	3	3	0	2
Total	31	30	31	16	13

advancement with slight overcorrection of the forehead/brow position. The patient experienced complete correction of her upper facial asymmetry and required no revision procedures 4 years postoperatively.

The second case displays a Pierre-Robin Sequence patient who exhibited airway obstruction secondary to mandibular hypoplasia. She was treated using VSP to plan the precise location and vector of bilateral mandibular osteotomies and symmetric placement of bilateral internal mandibular distractors (Fig. 2). The accuracy of the internal distractor placement was aided by VSP sessions that approximated the mandibular length after distraction, and a cutting guide was generated for in situ placement during the procedure. Preoperative fabrication of a ClearView³⁴ model further assured safe placement of screw holes that did not involve either tooth roots or the mental nerve canal. This patient had distractors placed at 5 weeks of

age, a similar distraction schedule to the above case, and has suffered no complications. Her retrognathia was fully corrected to a position that is expected to optimize her chance for a normal occlusion. Her airway obstruction was completely resolved after 10 mm of distraction, and an additional 8–10 mm of distraction was performed to a slightly overcorrected position.

Case Examples 2 and 3: 3D Modeling in Complex Craniofacial Reconstruction

Figures 3, 4 display 2 cases of complex reconstruction, which was aided by multiple 3D technologies, including 3DM. The first case shows a patient with multiple complex facial clefts, which resulted in near hemifacial agenesis with the absence of the right orbit and globe (Fig. 3). This patient's preoperative planning included the production of both skeletal and soft-tissue models, which were used to develop a detailed multistage operative plan that was executed over approximately 6 months time. The first stage included bony reconstruction of the lower jaw, chin, upper jaw, right cheek, and orbit using multiple bone grafts, LeFort I osteotomy with plate stabilization, and an advancement genioplasty. Her second stage followed with extensive soft-tissue reconstruction of the cheek and lips with removal of redundant or scarred tissue. This was followed by further release of contracted soft tissues of the cheek and right lateral and upper lip with reconstruction.

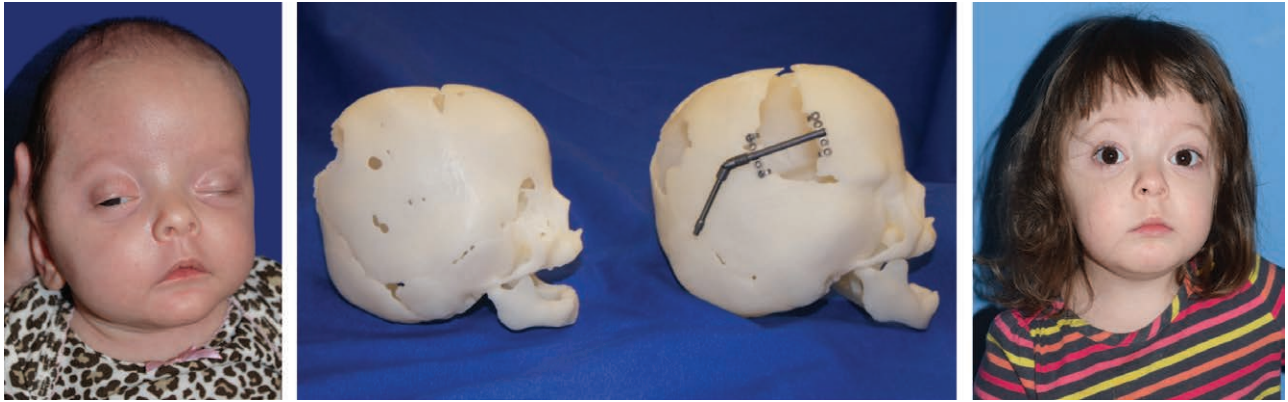


Fig. 1. Computer-assisted VSP and 3D models were used to plan placement of distractors and vector in this case of right unilateral coronal craniosynostosis. Notice almost complete normalization of the right forehead, orbit, and nose after distraction.

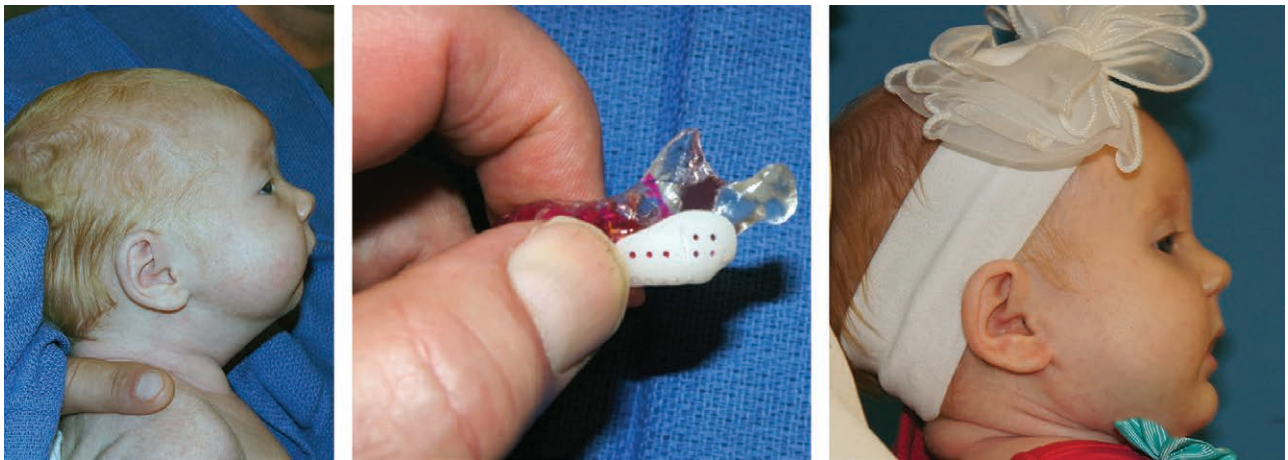


Fig. 2. Accuracy and symmetry can be achieved with the aid of a customized cutting guide, vector analysis, and virtual planning of screw hole placement in a case of mandibular distraction for severe Pierre Robin Sequence with severe airway obstruction.

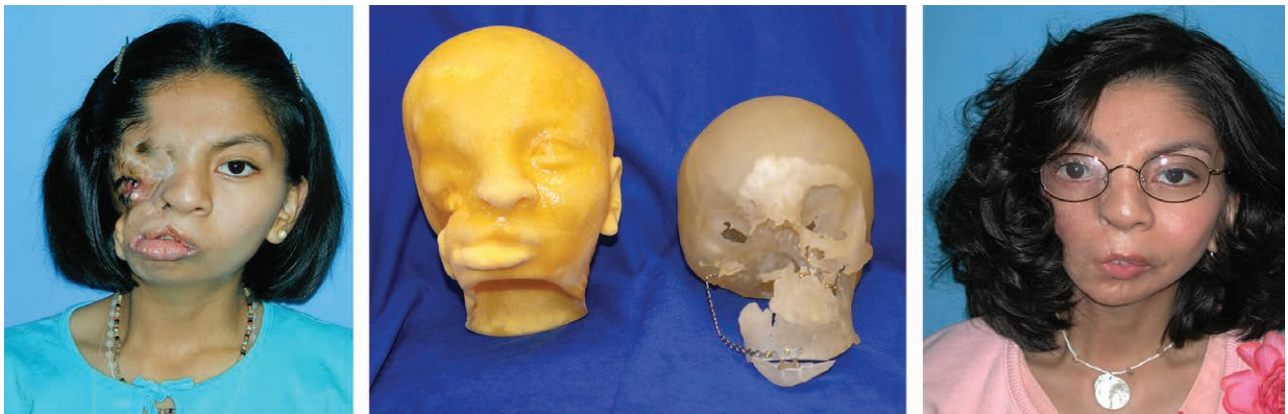

Fig. 3. 3D modeling was indispensable in these complex congenital craniofacial disorders. Seen here is a complex facial cleft that required 4-stage surgical repair in which both bony and soft-tissue 3D models were fabricated to simulate the surgical approach.

Finally, osteointegrated implants were placed, and a custom periorbital prosthesis was fabricated to mirror her contralateral orbital aesthetics. This patient underwent all steps of reconstruction without any complications.

The second patient shows a severe case of Apert syndrome with a cloverleaf skull (kleeblattschädel; Fig. 4).³⁵

She was first stabilized in the intensive care unit and had a ventricular shunt for hydrocephalus. A semiurgent craniotomy was planned at 1 month of age due to severe cranial restriction from multiple suture synostosis, persistent intracranial hypertension with papilledema, and proptosis. The entire anterior two-thirds of the skull and supraorbit-

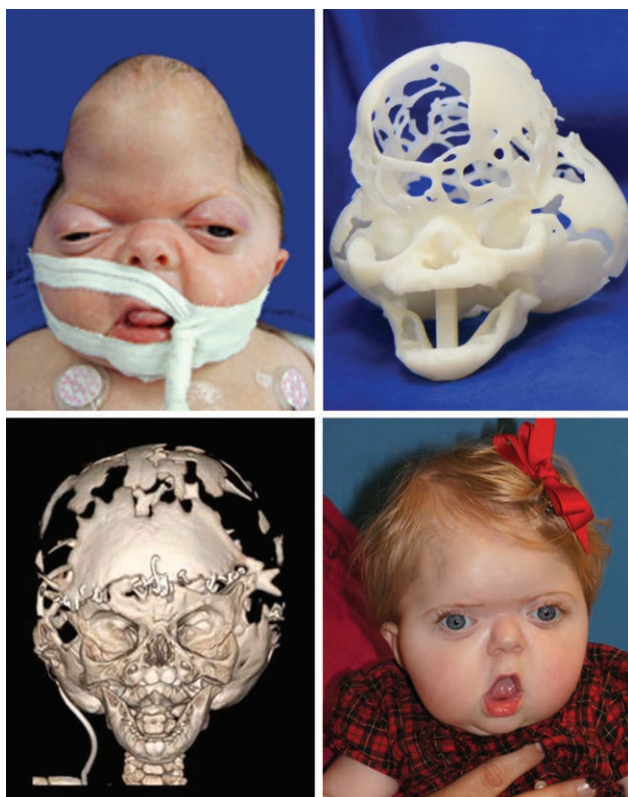

Fig. 4. This is a severe case of Apert syndrome (kleeblattschädel) that used 3D models to plan anterior reconstruction and distraction.

al rims were removed, allowing extensive decompression of the brain and release of the superior and lateral orbits down to the inferior orbital floor. Bone grafts were harvested from the parietal area to reconstruct the defects in the supraorbital bone. Two large pieces of bone were recontoured to reconstruct the forehead. The reconstructed supraorbital bar and forehead were secured together and advanced 2.0 cm. Bilateral distractors were then used to secure the lateral supraorbital bone to the temporal area of bone to provide additional forehead/brow advancement via distraction osteogenesis. VSP and 3DM were used for planning and approximation of results. Flexible arms were attached to each distractor, which exited through the temporal scalp. After a 5-day latency period, distraction was initiated twice a day at 1 mm/d. Bilateral distraction was successfully performed for 25 days for an additional 2.5 cm of forehead/brow advancement. This was followed by staged 2.5 cm distraction of her posterior cranial vault following multiple additional osteotomies for release of craniostylosis and extensive posterior remodeling at approximately 3 months old. This patient is now 5 years old and doing well.

Case Examples 5 and 6: 3D Patient-Specific Custom Implants

Figures 5, 6 demonstrate 2 examples of cases in which 3DPCIs were used to augment existing native bone structure. The first patient suffered displaced left zygomaticomaxillary complex, orbital, and frontal bone fractures

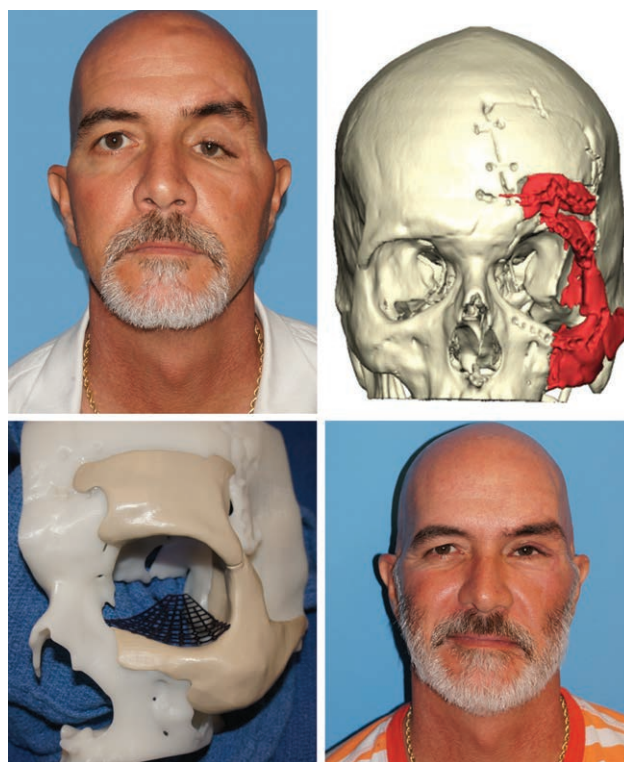


Fig. 5. Shown is a complex posttraumatic facial deformity with enophthalmos and vertical orbital dystopia. Virtual surgical simulation and 3D models were used in the reconstructive planning. Custom printed implants that were used are shown.

that underwent attempted open reduction and internal fixation at an outside facility before referral to our center. This patient suffered from debilitating diplopia and recurrent nausea. He was dependent on an eye patch. A left enophthalmos and vertical orbital dystopia were present. As seen in the preoperative 3D reconstructed CT scan, his native bone was highly comminuted and deficient following several surgical procedures. Therefore, due to deficient comminuted bone, we considered osteotomies and autogenous grafts versus a custom printed implant and decided to use the latter. We therefore used VSP with the creation of a 3DM for reconstruction of the left periorbital region with a PEEK 3DPCI to which a titanium mesh was fitted to reconstruct the orbital floor.³⁶

The patient's underwent reopening of the previous bicoronal and lower eyelid incisions to provide sufficient exposure, which included complete takedown of the temporalis muscle, removal of multiple previous reduction plates, micro screws, and comminuted bone fragments. Due to severe comminution with missing bone, portions of the left supraorbital frontal bone and body of the left zygoma were removed via osteotomy and debridement. The 3DPCIs were designed in 2 pieces that were inserted and rigidly secured to the patient's native bone using a lag screw and miniplate fixation. A contoured titanium mesh was then inserted to reconstruct the orbital floor and secured to the 3DPCI's infraorbital rim with micro screws. The orbital plate was positioned on the 3D model with

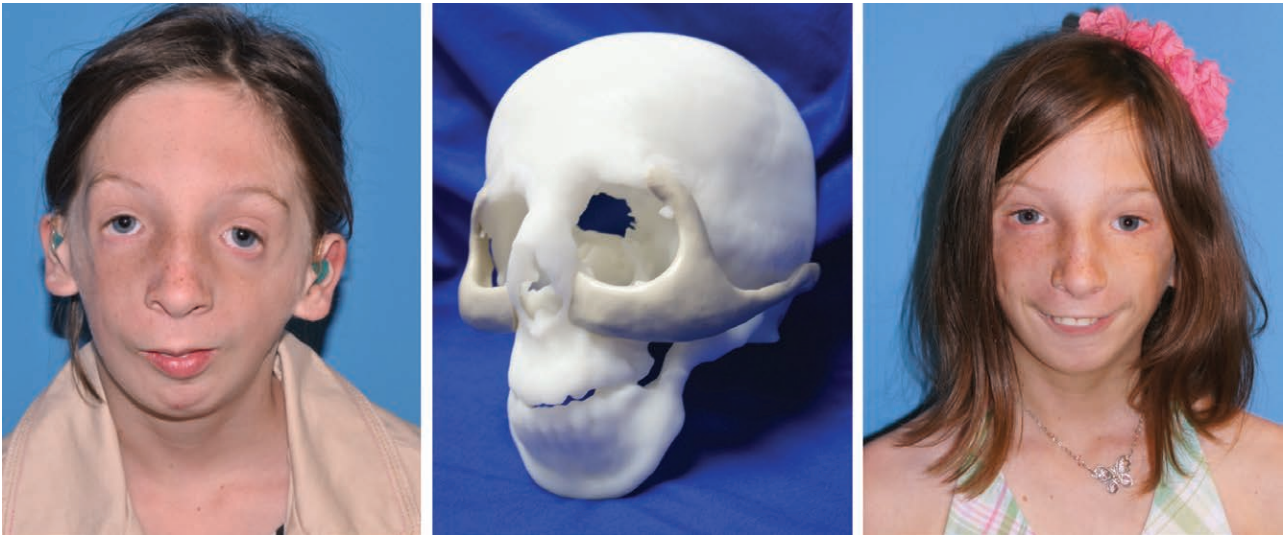

Fig. 6. This patient with Treacher Collins syndrome exhibits characteristic malar deficiency. VSP with custom designed and printed implants played a big role in this zygomatic-orbital reconstruction.

predrilled holes. Lastly, the soft tissue was resuspended, secured, and a lateral canthopexy was performed before closure. The patient tolerated the procedure well. He was admitted to the hospital postoperatively and was discharged the following day. He subsequently underwent correction of his traumatic left upper eyelid ptosis with plication of the levator tendon 3 months after 3DPCI insertion. This patient experienced complete resolution of diplopia and worked as a machinist without an eye patch.

The second patient demonstrates the use of a 3DPCI in a case of Treacher-Collins Syndrome (Fig. 6). This patient exhibited marked midface hypoplasia with deficient malar projection due to underdevelopment of the left zygoma and near aplasia of the right zygoma. She also had micrognathia, negative canthal tilt, and a drooping appearance to her midface from insufficient underlying bony support. Due to the congenital absence of a large segment of the zygoma, this patient's reconstruction was planned with VSP, the creation of a 3DM, and fabrication of PEEK 3DPCI. The bilateral orbital and zygomatic regions were thereby reconstructed by placement and rigid fixation of the 3DPCI to which contoured titanium mesh orbital floor reconstruction inserts were fashioned. She also received bilateral lateral canthopexy and cheek advancement with resuspension of the soft-tissue envelop over the 3DPCI. This procedure resulted in correction of the eyelid deformities by extensive mobilization of the cheek and eyelid with suspension of the orbicularis muscle to the superior lateral orbit. No rotation flaps or grafts were used in the lower eyelids. She tolerated the procedure well with no complications.

Complications, Secondary Procedures, and Follow-up

There were no extruded 3DPCIs, implant-associated abscesses, seromas, or hematomas, and no implants required removal. One patient (#14, case example 4 above) whose care included VSP, a 3DM, and distraction osteogenesis manifested a posterior scalp wound that required

debridement and local advancement flap closure. Another patient (#29, case example 5 above) underwent levator plication for ptosis after implant placement. This was a staged procedure that was anticipated and discussed preoperatively, and this resulted in lid symmetry. Two patients (#14 and #26) underwent revisions of ventriculoperitoneal shunts by neurosurgery, though these were unrelated to 3D planning or custom implants. The overall average follow-up interval was 2.8 years.

DISCUSSION

We describe multiple examples of the use of VSP, 3DMs, and 3DPCIs for the reconstruction of syndromic and nonsyndromic congenital and acquired craniofacial deformities. The use of these techniques demonstrates an array of complex craniofacial conditions with excellent outcomes. As evident in Figures 1–6, the fundamental indication to employ advanced 3D techniques are deformities that require detailed analysis and precise reconstruction of complex deformities. The nature of this complexity may be due to deficiency of native bone, recurrent surgical intervention, smaller pediatric anatomy requiring fine precision, or severe deformities that benefit from detailed VSP or simulation of the operative in the physical environment with a 3DM. In clinical scenarios in which 3DPCIs were not needed or the patient's condition featured linear alteration of existing native bone, such as in distraction osteogenesis (Fig. 1), VSP could be employed without a 3DM. Models were generated by 3D printing, typically for cases involving complicated anatomic structures whose visualization in a tactile physical environment helped refine the surgical plan. This also enabled physical simulation of the procedure, which may allow for preoperative confirmation of optimal shape and fit when using a 3DPCI (Fig. 5).

Previous authors support PEEK as well suited to craniofacial reconstruction, given it approximates the physical

properties of human cortical bone.^{6,13,14,17} Although long-term studies are still needed, this literature reports relatively low complication rates associated with PEEK implants.^{6,13,14,17} We have not experienced complications attributed to the 3DPCI thus far, including no implant infections or extrusions, although other materials like polyethylene are also available.

There are inherent drawbacks to the use of advanced 3D computer technology, including potentially increased cost, the risk of infection or extrusion of alloplastic biomaterials, and unexpected discrepancies between simulated and actual operative results.^{18–21,24,30} Employing 3D technologies also does not absolve the surgeon from the responsibility of sound clinical judgment, planning, and execution. The educational role of 3D technology in craniofacial reconstruction also continues to be defined. Nevertheless, advanced 3D tools allow the surgeon to take advantage of virtual and physical environment planning and simulation of results in addition to adding material to areas with severe deficiency.

Computer-aided 3D reconstruction is a burgeoning field in craniofacial surgery characterized by advanced technology for the optimal correction of a wide array of deformities. Craniofacial surgeons currently face the challenge of producing high-quality evidence to define: criteria that warrant the use of advanced 3D technologies, a viable balance between in-house production and outsourcing of resources to industry, a timeline for the production and delivery of 3DPCIs, standards for ethical interaction with commercial providers of 3D reconstructive services to plastic surgeons, the value of 3D reconstructive technologies in medical education, the optimal biomaterials for use in 3DPCIs, and long-term outcomes of this approach.^{4,18–21,27,44}

CONCLUSIONS

Modern 3D technology allows the surgeon to better analyze complex craniofacial deformities, precisely plan surgical correction with computer simulation of results, customize osteotomies, plan distractions, and print custom implants as needed. The use of advanced 3D computer technology can be applied safely and potentially improve aesthetic and functional outcomes after complex craniofacial reconstruction. These techniques warrant further study and may be reproducible in various centers of care.

Kristopher M. Day, MD

5840 Lake Resort Terrace, Apartment N104
Chattanooga, TN 37415

E-mail: KristopherMDay@Gmail.com

REFERENCES

- Hull C, inventor. Apparatus for production of three-dimensional objects by stereolithography. *US Patent 4,575,330*. March 11, 1986.
- Schubert C, van Langeveld MC, Donoso LA. Innovations in 3D printing: a 3D overview from optics to organs. *Br J Ophthalmol*. 2014;98:159–161.
- Chim H, Wetjen N, Mardini S. Virtual surgical planning in craniofacial surgery. *Semin Plast Surg*. 2014;28:150–158.
- Parthasarathy J. 3D modeling, custom implants and its future perspectives in craniofacial surgery. *Ann Maxillofac Surg*. 2014;4:9–18.
- Doi K. Diagnostic imaging over the last 50 years: research and development in medical imaging science and technology. *Phys Med Biol*. 2006;51:R5–27.
- Tan KH, Chua CK, Leong KF, et al. Scaffold development using selective laser sintering of polyetheretherketone-hydroxyapatite biocomposite blends. *Biomaterials*. 2003;24:3115–3123.
- Avraham T, Franco P, Brecht LE, et al. Functional outcomes of virtually planned free fibula flap reconstruction of the mandible. *Plast Reconstr Surg*. 2014;134:628e–634e.
- Deek NF, Wei FC. Computer-assisted surgery for segmental mandibular reconstruction with the osteoseptocutaneous fibula flap: can we instigate ideological and technological reforms? *Plast Reconstr Surg*. 2016;137:963–970.
- Jacobs JM, Dec W, Levine JP, et al. Best face forward: virtual modeling and custom device fabrication to optimize craniofacial vascularized composite allotransplantation. *Plast Reconstr Surg*. 2013;131:64–70.
- Levine JP, Bae JS, Soares M, et al. Jaw in a day: total maxillofacial reconstruction using digital technology. *Plast Reconstr Surg*. 2013;131:1386–1391.
- Seruya M, Fisher M, Rodriguez ED. Computer-assisted versus conventional free fibula flap technique for craniofacial reconstruction: an outcomes comparison. *Plast Reconstr Surg*. 2013;132:1219–1228.
- D'Urso PS, Earwaker WJ, Barker TM, et al. Custom cranioplasty using stereolithography and acrylic. *Br J Plast Surg*. 2000;53:200–204.
- Alonso-Rodriguez E, Cebrián JL, Nieto MJ, et al. Polyetheretherketone custom-made implants for craniofacial defects: report of 14 cases and review of the literature. *J Craniomaxillofac Surg*. 2015;43:1232–1238.
- Guevara-Rojas G, Figl M, Schicho K, et al. Patient-specific polyetheretherketone facial implants in a computer-aided planning workflow. *J Oral Maxillofac Surg*. 2014;72:1801–1812.
- Mohler LR, Porterfield HW, Ferraro JW. Custom implants for reconstruction of craniofacial defects. *Arch Surg*. 1976;111:452–455.
- Nickels L. World's first patient-specific jaw implant. *Metal Powder Rep*. 2012;67:12–14.
- Ramos CK, Cayci C, Castro-Garcia JA, et al. Patient-specific polyetheretherketone implants for repair of craniofacial defects. *J Craniofac Surg*. 2015;26:631–633.
- Bauermeister AJ, Zuriarrain A, Newman MI. Three-dimensional printing in plastic and reconstructive surgery: a systematic review. *Ann Plast Surg*. 2015. [Epub ahead of print].
- Kamali P, Dean D, Skoracki R, et al. The current role of three-dimensional printing in plastic surgery. *Plast Reconstr Surg*. 2016;137:1045–1055.
- Gerstle TL, Ibrahim AM, Kim PS, et al. A plastic surgery application in evolution: three-dimensional printing. *Plast Reconstr Surg*. 2014;133:446–451.
- Pfaff MJ, Steinbacher DM. Plastic surgery applications using three-dimensional planning and computer-assisted design and manufacturing. *Plast Reconstr Surg*. 2016;137:603e–616e.
- Darwood A, Collier J, Joshi N, et al. Re-thinking 3D printing: a novel approach to guided facial contouring. *J Craniomaxillofac Surg*. 2015;43:1256–1260.
- Farré-Guasch E, Wolff J, Helder MN, et al. Application of additive manufacturing in oral and maxillofacial surgery. *J Oral Maxillofac Surg*. 2015;73:2408–2418.
- Fisher M, Medina M 3rd, Bojovic B, et al. Indications for computer-aided design and manufacturing in congenital craniofacial reconstruction. *Craniomaxillofac Trauma Reconstr*. 2016;9:235–241.

25. Hyung WY, Nguyen A, Yong KK. Facial contouring surgery with custom silicone implants based on a 3D prototype model and CT-scan: a preliminary study. *Aesth Plast Surg*. 2015;39:418–424.
26. Joffe J, Harris M, Kahugu F, et al. A prospective study of computer-aided design and manufacture of titanium plate for cranioplasty and its clinical outcome. *Br J Neurosurg*. 1999;13:576–580.
27. Levine JP, Patel A, Saadeh PB, et al. Computer-aided design and manufacturing in craniomaxillofacial surgery: the new state of the art. *J Craniofac Surg*. 2012;23:288–293.
28. Müller A, Krishnan KG, Uhl E, et al. The application of rapid prototyping techniques in cranial reconstruction and preoperative planning in neurosurgery. *J Craniofac Surg*. 2003;14:899–914.
29. Poukens J, Haex J, Riediger D. The use of rapid prototyping in the preoperative planning of distraction osteogenesis of the cranio-maxillofacial skeleton. *Comput Aided Surg*. 2003;8:146–154.
30. Rustemeyer J, Melenberg A, Sari-Rieger A. Costs incurred by applying computer-aided design/computer-aided manufacturing techniques for the reconstruction of maxillofacial defects. *J Craniomaxillofac Surg*. 2014;42:2049–2055.
31. Rotaru H, Băciuț G, Stan H, et al. Abstract: reconstruction of craniofacial bone defects with three-dimensional custom-made implants. A five year experience. *Intl J Oral Maxillof Surg*. 2009;38:500.
32. Tang W, Guo L, Long J, et al. Individual design and rapid prototyping in reconstruction of orbital wall defects. *J Oral Maxillofac Surg*. 2010;68:562–570.
33. Tepper OM, Sorice S, Hershman GN, et al. Use of virtual 3-dimensional surgery in post-traumatic craniomaxillofacial reconstruction. *J Oral Maxillofac Surg*. 2011;69:733–741.
34. Tsuji M, Noguchi N, Ihara K, et al. Fabrication of a maxillofacial prosthesis using a computer-aided design and manufacturing system. *J Prosthodont*. 2004;13:179–183.
35. Yan A, Yaremchuk M. Abstract P60: facial skeletal augmentation with custom implants using computer-assisted design (CAD) and computer-assisted manufacturing (CAM) technology. *Plast Recon Surg*. 2015;135:1239.
36. Zopf DA, Mitsak AG, Flanagan CL, et al. Computer aided-designed, 3-dimensionally printed porous tissue bioscaffolds for craniofacial soft tissue reconstruction. *Otolaryngol Head Neck Surg*. 2015;152:57–62.
37. KLS Martin®. “Patient specific implants: additive manufacturing.” Available at <http://www.klsmartin.com/products/implants-and-implant-systems/cmfi/patient-specific-implants/additive-manufacturing/?L=2>. Accessed February 7, 2017.
38. Park SW, Choi JW, Koh KS, et al. Mirror-imaged rapid prototype skull model and pre-molded synthetic scaffold to achieve optimal orbital cavity reconstruction. *J Oral Maxillofac Surg*. 2015;73:1540–1553.
39. KLS Martin®. “ClearView Patient Models.” Available at <http://www.klsmartinnorthamerica.com/products/ct-based-surgical-planning/clearview-patient-models/>. Accessed September 2, 2016.
40. Sargent LA, Griner D. Use of osteogenesis distractors in cloverleaf skull reconstruction. *Ann Plast Surg*. 2013;70:546–548.
41. Day KM, Phillips P, Sargent LA. Correction of a post-traumatic orbital deformity using three dimensional modeling, virtual surgical planning with computer assisted design, and three dimensional printing of custom implants. *Craniofacial Trauma Recon*. Accepted, pending publication.
42. National Institutes of Health. NIH 3D print exchange. Available at <http://3dprint.nih.gov>. Accessed June 5, 2016.
43. U.S. Food and Drug Administration. Public workshop: additive manufacturing of medical devices: an interactive discussion on the technical considerations of 3-D printing. Available at <http://www.fda.gov/MedicalDevices/NewsEvents/WorkshopsConferences/ucm397324.htm>. Accessed June 5, 2016.
44. Ozbolat IT, Yu Y. Bioprinting toward organ fabrication: challenges and future trends. *IEEE Trans Biomed Eng*. 2013;60:691–699.