



Efficacy and safety of embolization for arteriovenous malformations of the basal ganglia and thalamus via the transarterial approach

Wei Zhang[#], Heng Wei[#], Qi Tian, Shoumeng Han, Wenrui Han, Yujia Guo, Guijun Wang, Shenqi Zhang, Gang Deng, Junming Wang, Qianxue Chen, Mingchang Li

Department of Neurosurgery, Renmin Hospital of Wuhan University, Wuhan, China

Contributions: (I) Conception and design: W Zhang, H Wei; (II) Administrative support: Y Guo, Q Chen; (III) Provision of study materials or patients: Q Tian, G Wang, J Wang; (IV) Collection and assembly of data: W Han, S Zhang, G Deng; (V) Data analysis and interpretation: S Han, M Li; (VI) Manuscript writing: All authors; (VII) Final approval of manuscript: All authors.

[#]These authors contributed equally to this study.

Correspondence to: Mingchang Li. Department of Neurosurgery, Renmin Hospital of Wuhan University, 99 Ziyang Road, Wuhan 430060, China. Email: mingcli@whu.edu.cn.

Background: To evaluate the effectiveness and safety profile of transarterial embolization in the treatment of brain arteriovenous malformations (bAVMs) within the basal ganglia and thalamus.

Methods: A retrospective clinical study was performed on 22 patients with bAVMs localized within the basal ganglia and thalamus who were treated with transarterial embolization (December 2012 and January 2019) in our center. The bAVMs were embolized via the transarterial approach with Onyx or Glubran according to the anatomical structure. A detachable or undetachable microcatheter was used in the procedure according to the length of the feeding artery. The data of these patients were retrospectively analyzed.

Results: Among the 22 patients, 9 bAVMs were located in the basal ganglia and 13 were located in the thalamus. Twenty patients presented with hemorrhage (90.9%), leaving 2 patients (9.1%) who had no symptoms. According to the Spetzler-Martin grading classification, 13 bAVMs (59.1%) were grade 3, 7 (31.8%) were grade 4, and 2 (9.1%) were grade 5. Procedure-related complications occurred in only 1 patient (4.5%). No deaths related to the operation occurred. All patients achieved anatomic stabilization and no bleeding was observed in the follow-up.

Conclusions: Selective embolization via the transarterial approach is safe and effective for bAVMs originating within the basal ganglia and thalamus. Our results demonstrate a low rate of complications and an elevated degree of anatomical disruption in the endovascular treatment of bAVMs stemming from the basal ganglia and thalamus.

Keywords: Arteriovenous malformation; basal ganglia; thalamus; transarterial approach embolization

Submitted Dec 29, 2021. Accepted for publication Mar 18, 2022.

doi: 10.21037/atm-22-384

View this article at: <https://dx.doi.org/10.21037/atm-22-384>

Introduction

Brain arteriovenous malformations (bAVMs) consist of aberrant fistulas presenting across arteries and veins which lack any interconnecting capillary beds, leading to various symptoms including intracranial hemorrhage and seizure (1). Deep bAVMs often involve important structures

such as the thalamus and basal ganglia and have a higher annual bleeding rate, disability rate, and mortality rate than bAVMs in superficial parts (2). The treatment strategies for bAVMs involving important structures are challenging and variable due to their unknown pathogenesis and complicated internal structure (3).

For neurosurgeons, the treatment of deep bAVMs is difficult and risky. Arteriovenous malformations carry a significant cumulative risk of bleeding. Treatment options include microsurgery, stereotaxic radiosurgery (SRS), embolization. Treatment selection is based on bAVMs characteristics, including size, location, venous drainage, surgical access, rupture status, and previous treatment. The Spetzler-Martin classification is the most commonly used classification system in selecting treatment. Microsurgery can achieve high cure rates with low morbidity and mortality, especially for I–II grade bAVMs (4). SRS is suitable for small or medium-sized bAVMs, unruptured bAVMs and residual bAVMs after operation or endovascular treatment. However, the effect is slow, and it takes 1 to 3 years for the brain AVM to completely disappear (5). Embolization was considered an adjunct to the treatment of bAVMs in the past and was used to assist microsurgery and SRS. With the development of embolic agents, catheter guide wires, etc, embolization as an independent treatment method is increasingly used in bAVMs. For deep bAVMs, microsurgery is difficult to locate accurately and may cause greater trauma. Radiation-related complications and rebleeding rates are relatively high with radiation therapy for deep bAVMs, while occlusion rates are lower. In such patients, embolization is suitable if there is a feeding artery or a draining vein that can reach the nidus (6). Compared to microsurgical resection, endovascular embolization is less invasive and results in less sequelae, and is becoming the first treatment option for more and more intracranial cerebrovascular diseases (7). However, at present, the efficacy and safety of transarterial and intravenous, or radiotherapy in the treatment of this kind of bAVM are still controversial (8,9).

There have been many studies on bAVMs, but they are not applicable to deep bAVMs such as those located in the basal ganglia and thalamus (10,11). Regardless of the choice of microsurgery, stereotactic radiation therapy or embolization, the treatment of deep bAVMs faces more risks. This study aimed to evaluate the efficacy and safety of single-center transarterial endovascular treatment of bAVM deep within the basal ganglia and thalamus. This investigation aimed at evaluating the effectiveness and safety profile of transarterial endovascular treatment of deep bAVMs within the basal ganglia and thalamus at a single center. We present the following article in accordance with the STROBE reporting checklist (available at <https://atm.amegroups.com/article/view/10.21037/atm-22-384/rc>).

Methods

This investigation retrospectively collected the data of patients with basal ganglia and thalamus bAVMs treated with embolization via the transarterial approach from August 2013 to January 2019. The study was conducted in accordance with the Declaration of Helsinki (as revised in 2013). The study was approved by the Ethics Committee of Renmin Hospital of Wuhan University (No. WDRY2021-K070) and informed consent was taken from all the patients or their guardians. Patient demographic data, medical history, medical manifestation/s, analytical scans, surgical procedure outcomes, post-surgery analyses, and medical monitoring data were collected. The bAVMs were categorized depending on dimensions, localization (basal ganglia or thalamus), and type of drainage (superficial-/deep-/deep- and superficial-venous), and were consequently classified according to the Spetzler-Martin grading classification. Clinical cases with pial arteriovenous fistulas, as well as those a previous history of treatment for this condition, were all excluded from this investigation. All study participants were preoperatively evaluated through head computed tomography (CT) and digital subtraction angiography (DSA) and were examined by the in-house multidisciplinary cerebrovascular team prior to and post intervention.

Clinical data and follow-up data were documented for each patient. Follow-up and evaluation of postoperative neurological function were performed at 12 months after embolization. All patients were followed up with head DSA after embolization. Major adverse events after embolization were assessed, such as novel ischemic stroke, intracranial bleeding, and death. Novel ischemic stroke was defined as a novel, symptomatic, thromboembolic incidence confirmed through magnetic resonance imaging (MRI). Intracranial bleeding was linked to embolization, encompassing intrasurgical vascular perforation, venous occlusion, and bleeding. The modified Rankin scale (mRS) was used to assess neurological recovery.

The purpose of the treatment was to correct the abnormal fistulas between arteries and veins that resulted in the obliteration of venous endothelial walls and consequently led to profuse internal bleeding of bAVMs. During the procedure, we prioritized the undetachable microcatheter (Marathon, EV3, Irvine, CA, USA) advanced with microwire guidance (Mirage™, EV3, USA) via the transarterial approach within the nidus for cases without a sufficiently long reflex feeding artery. For bAVMs with long feeders, a

Table 1 Investigational bAVM features and results

Patient	Age (years), sex	Initial mRS	Location	bAVM size (cm)	Presentation	Feeding artery	Spetzler-Martin grade	Venous drainage	Final mRS	Angiographic results	Embolitic agents
1	16, M	1	Right basal ganglia	4	Ruptured	2	4	Deep	1	65%	Glubran
2	22, F	2	Left basal ganglia	4	Ruptured	3	4	Deep	1	100%	Onyx
3	24, F	2	Right thalamus	3	Ruptured	4	4	Deep	1	80%	Onyx
4	16, M	3	Right basal ganglia	1.5	Ruptured	1	3	Deep	1	100%	Onyx
5	40, M	1	Left basal ganglia	3	Ruptured	1	4	Deep	1	100%	Onyx
6	26, F	4	Right basal ganglia	2	Ruptured	2	3	Deep	1	100%	Onyx
7	64, M	3	Left thalamus	3.5	Ruptured	1	4	Deep	1	60%	Onyx
8	19, F	3	Left thalamus	2	Ruptured	2	3	Deep	1	100%	Onyx
9	38, M	1	Left thalamus	2.5	Ruptured	2	3	Deep	1	100%	Onyx
10	51, F	1	Left thalamus	2	Ruptured	1	3	Deep	0	100%	Glubran
11	35, F	1	Right thalamus	3.5	Ruptured	2	4	Deep	0	100%	Onyx
12	30, M	1	Right thalamus	3	Ruptured	2	4	Deep	0	90%	Glubran
13	42, F	3	Right thalamus	4	Ruptured	2	4	Deep	1	50%	Onyx
14	38, F	1	Right thalamus	4	Ruptured	2	4	Deep	1	40%	Onyx
15	29, F	1	Right thalamus	3.5	Ruptured	4	4	Deep	0	90%	Onyx
16	21, M	4	Right thalamus	2	Ruptured	2	3	Deep	1	100%	Glubran
17	38, F	1	Right basal ganglia	6	Ruptured	2	5	Deep	1	80%	Onyx
18	66, M	1	Left thalamus	2.5	Ruptured	1	3	Deep	0	100%	Onyx
19	16, M	3	Right basal ganglia	2	Ruptured	1	3	Deep	0	100%	Onyx
20	62, M	1	Right basal ganglia	6	Unruptured	1	5	Deep	0	40%	Onyx
21	67, M	1	Left basal ganglia	3	Unruptured	1	4	Deep	1	100%	Onyx
22	9, M	1	Right thalamus	6	Ruptured	2	5	Deep	1	80%	Onyx

bAVM, brain arteriovenous malformation; mRS, modified Rankin scale.

removable-tip microcatheter (ApolloTM, EV3, USA) was used from the transarterial approach to achieve curative results. Onyx was used to penetrate adequately into the nidus if the tip of the microcatheter could be advanced into the nidus, otherwise Glubran with a concentration between 15% to 20% would be used to embolize the nidus in cases of feeders with excessive tortuosity. The treatment was stopped when the arterial approach was no longer feasible or bAVMs could not be reached by total vascular area (TVA).

Statistical analysis

SPSS20.0 software was used for statistical

analysis, and the mean \pm standard deviation expresses the measurement data ($\bar{x} \pm s$).

Results

Patient profiles and outcomes are listed in *Table 1*. A total of 22 bAVM clinical cases, with symptoms stemming from the basal ganglia (n=9) and thalamus (n=13), underwent embolization. The clinical case group was 45% female (mean age 35 ± 18 years). The majority of clinical cases manifested bleeding (91%; n=20), while 7 (32%) patients had worsening neurological condition (mRS >2) at admission. The mean size of bAVMs was 3.77 ± 0.69 cm.

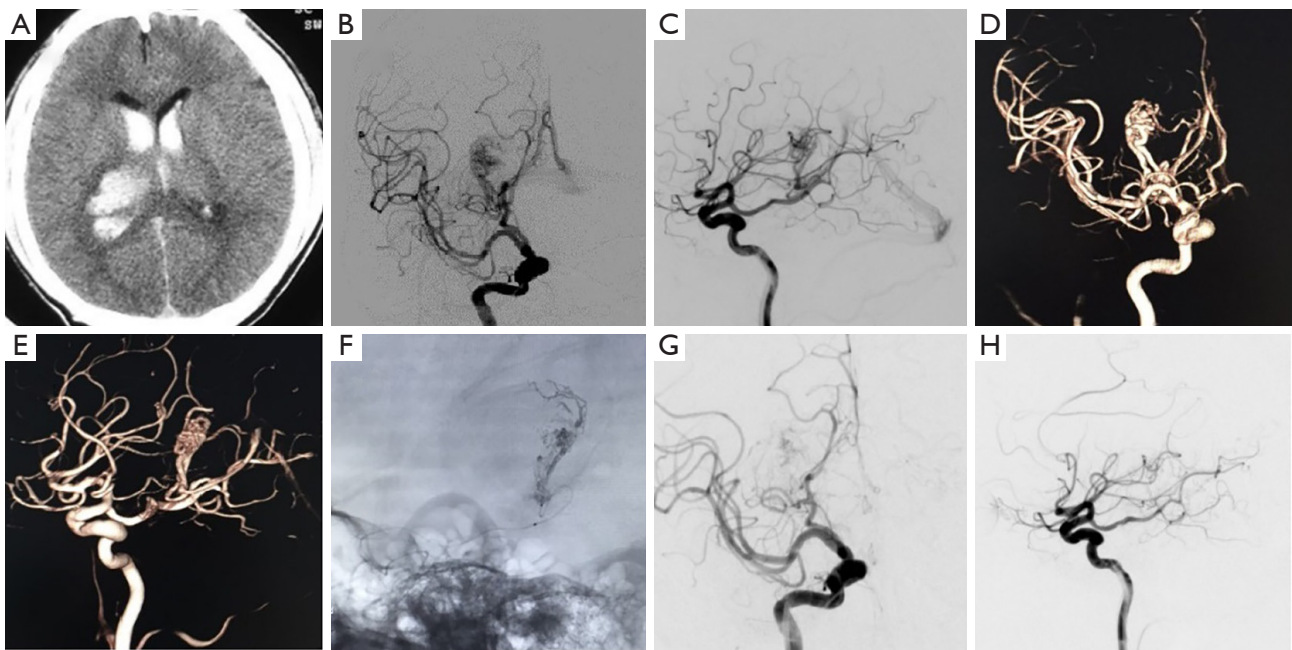


Figure 1 A 30-year-old clinical case manifested severe headache and left hemiparesis. (A) Nonenhanced CT imaging (axial view) demonstrated high density within the right caudate-capsular area with ventricular extravasation. Selective right ICA DSA from the AP (B) and lateral (C) views highlighted the AVM supply through the posteromedial choroidal arteries, with a nidus of 3.5 cm. Deep drainage was conducted through the Galen vein. (D,E) Three-dimensional DSA better delineated the angioarchitecture. (F) Intraoperative single-shot imaging from the lateral view exhibited the cast of Glubran (GEM Srl, Viareggio, Italy). (G,H) Twelve-month control DSA in the AP (G) and lateral (H) views demonstrated anatomical exclusion of nidus. CT, computed tomography; ICA, internal carotid artery; DSA, digital subtraction angiography; AP, anteroposterior; AVM, arteriovenous malformation.

Eight cases were grade 3, 11 cases were grade 4, and 2 cases were grade 5 according to the Spetzler-Martin grading classification. The total embolization rate was 40–100%, with an average rate of 86.19% in this series. Onyx was used in 18 (82%) cases and Glubran was used in 4 (18%) cases. *Figures 1,2* are individual clinical cases.

All patients achieved a positive clinical outcome (mRS 0–2) after 12 months follow-up. Only 1 (5%) patient presented visual field defects related to embolization. No bleeding or recurrence occurred during the follow-up.

Discussion

It is well known that bAVMs can occur in any part of the brain, with affected regions accounting for more than 60% of the cerebral hemisphere. The first symptoms include headache, epilepsy, and cerebral hemorrhage. bAVMs that occur in deep structures of the brain, such as the basal ganglia or thalamus, account for about 1% to 3% of the total incidence (12). The incidence of hemorrhage in basal

ganglia and thalamus bAVMs was shown to be significantly higher compared to superficial bAVMs (13). Within this investigation, 20 basal ganglia and thalamus bAVM cases were admitted with intraventricular hemorrhage, and 2 patients had asthenia as the first symptom.

Rebleeding basal ganglia and thalamus bAVMs are the greatest threat in such patients. The strategies for bAVM treatment in the basal ganglia and thalamus include endovascular embolization, radiosurgery, and microsurgery, as well as the combination of each of them. Microsurgery can clear hematomas and relieve the space-occupying effect, remove the lesions completely, and eliminate the risk of bleeding. In this way, this approach may still be beneficial for bAVMs of the basal ganglia and thalamus (4). Several approaches such as transsylvian fissure and the transcalsal and transcortical approach are usually used to achieve total resection of bAVMs in the basal ganglia and thalamus, especially for patients with hemorrhagic presentation and young age (14). For compact and small size bAVMs of the basal ganglia, microsurgical total resection can be achieved

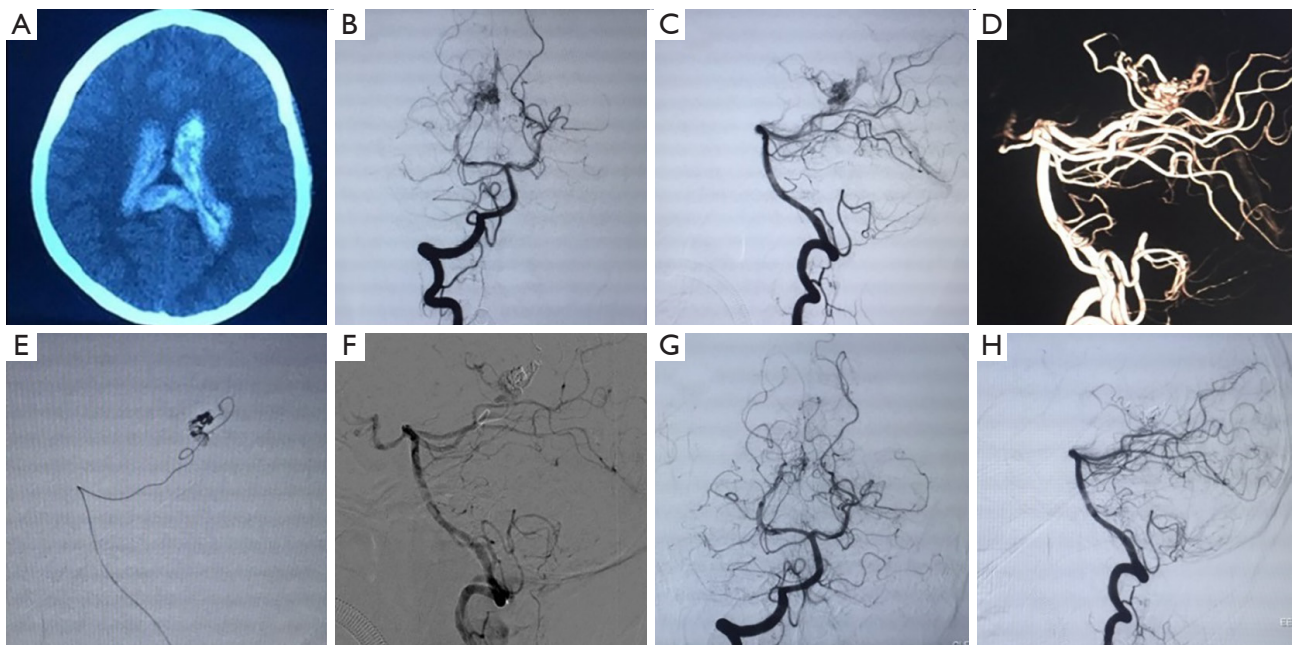


Figure 2 A 35-year-old clinical case manifested severe headache. (A) Nonenhanced CT imaging (axial) demonstrated ventricular hemorrhage. Selective right vertebral DSA in the AP (B) and lateral (C) views highlighted the AVM supply through the posterior choroidal artery, with a nidus of 3.5 cm. Deep drainage was conducted through the Galen vein. (D) Three-dimensional DSA better delineated the angioarchitecture. Intraoperative single-shot imaging from the lateral (E) view highlights arterial methodology via a microcatheter (Marathon, EV3, Irvine, CA, USA) within the posterior choroidal arteries. Non-subtracted single-shot imaging from the lateral (F) view revealing the cast for Onyx (EV3, Neurovascular, Irvine, CA, USA). Twelve-month control DSA within the AP (G) and lateral (H) views highlighted anatomical exclusion of nidus. CT, computed tomography; DSA, digital subtraction angiography; AP, anteroposterior; AVM, arteriovenous malformation.

because the bAVMs are supplied by the middle cerebral artery (MCA) branch, which provides early accessibility to the neurosurgeon to seal supplying artery mass (15). However, bAVMs of the thalamus are also supplied by the anterior choroidal artery, thalamoperforating arteries (from P1 posterior-cerebral/posterior-communicating arteries), and posterior choroidal arteries (lateral > medial), which block accessibility to supplying arteries until late dissection phase. As a result, when dealing with bAVMs of the basal ganglia and thalamus, it is hard to avoid damaging surrounding tissues and nerves, and may even lead to massive hemorrhage. Potts reported that although 71% to 94% of insular cortex and basal ganglia bAVMs could achieve total resection, total resection could only be achieved in 46% of thalamus bAVMs. The incidence of complications was 29% (14/48), and the complications were mainly epilepsy, hydrocephalus, and infection (16). Thus, basal ganglia and thalamus bAVMs require multi-strategy treatment compared to other bAVMs.

Radiosurgery comprises part of this treatment, and is recommended for patients with deep or functional area bAVMs or bAVMs that cannot be resected completely. A total of 23% to 44% of bAVMs in the basal ganglia and thalamus were treated with stereotactic radiosurgery (SRS) because of its non-invasiveness. To date, it is well recognized that SRS is suitable for small or medium-sized bAVMs, unruptured bAVMs, and residual bAVMs after surgery or endovascular treatment. It was reported that the disruption rate was 43% to 81% for deep bAVMs which were treated by SRS. However, the disruption is achieved 6 months later, which has a hemorrhagic rate of 8% to 15% during the latency period and is not recommended for ruptured bAVMs (17).

Endovascular embolization is suitable for basal ganglia and thalamus bAVMs as this treatment prevents trauma to the parenchyma caused by microsurgery and SRS. Previously, embolic agents including solid particles such as polyvinyl alcohol (PVA) and sutures, as well as liquid agents

such as N-butyl-2-cyanoacrylate (NBCA), had low rates of curative outcome due to their high level of complications. Therefore, endovascular embolization can resolve the condition in a minority of patients and is also a corollary to surgical procedures/SRS (18). With advancements in microcatheter technologies and new embolism-related drugs over the past decade, interventional therapy has become safer and more efficient for bAVMs and is becoming the first choice for nonbleeding cerebrovascular diseases (19). NBCA was the most commonly used agent before Onyx was introduced in clinical practice. The most serious disadvantage of NBCA is the risk of adhesion to the microcatheter after injection, which requires rapid removal of the microcatheter as soon as the glue retrograde, even if the bAVM has not been embolized completely. Onyx, a nonadhesive liquid agent, has a lower risk of catheter entrapment, allowing it to be injected slowly. Moreover, its good perfusion characteristics mean it can penetrate into the nidus adequately, which improves the rate of total embolization and decreases recurrence (20).

Transarterial bAVM embolization is a standalone treatment, with the advantages of reaching the nidus easily, less risk of adhesion to the microcatheter, and staging of embolization (21). The transvenous route is deemed as a rescue treatment. Relative indications for transvenous embolization include small nidus (<3 cm maximum diameter), single draining vein, absence of a navigable arterial feeder, and nil access to the nidal remnant. However, the transvenous approach may cause premature occlusion of the drainage vein and perforation (22). In this series, the microcatheter could reach all of the niduses by the feeding artery, so the transarterial approach was chosen in all cases for safety.

For basal ganglia and thalamus bAVMs, the main feeding arteries usually include perforations within the anterior cerebral artery (ACA), MCA, and posterior cerebral artery (PCA). Thus, embolic agents without good penetration characteristics cannot penetrate into the nidus well. Combined with a detachable microcatheter such as the Apollo or Sonic, Onyx can be injected very slowly and diffuse into the nidus fully without fear of Onyx reflux and microcatheter entrapment. In our series, Onyx was used when the microcatheter could be introduced into the nidus, otherwise different concentrations of NBCA were used to embolize the feeding artery and nidus. In one bAVM with 3 feeding arteries, total embolization was achieved with the combination of Onyx and the Apollo detachable microcatheter. For 2 bAVMs with 4 feeding arteries, to

avoid occluding the drainage vein and the perforating arteries, we partially embolized the nidus. The follow-up results showed that there was no rebleeding. To avoid complications, the microcatheter tip should be introduced within the nearest proximity to the nidus and without letting the microwire come out when the microcatheter is near the nidus, otherwise there is a risk of puncturing the bAVM.

Because most of the feeding arteries are from the anterior choroidal artery perpendicular to the internal carotid artery (ICA), it is difficult to introduce the microcatheter because of the acute angle between the parent artery and feeding artery. Thus, a balloon can be used to assist the microcatheter as it goes into the nidus. In this way, embolization from the venous approach is an alternative method for patients with bAVMs in the basal ganglia and thalamus which cannot be occluded from arterial approach, although there was no such case in our series (23).

Conclusions

This is a retrospective clinical study of endovascular treatment for bAVMs of the basal ganglia and thalamus. Embolization treatment appears to have a good safety profile for basal ganglia and thalamus bAVMs. Our results demonstrate a low rate of complications. Under the appropriate treatment strategy, intravascular treatment is safe and reliable as a single treatment approach for basal ganglia and thalamus bAVMs.

Acknowledgments

Funding: This research was funded in part by the National Natural Science Foundation of China (No. 81971870 and No. 82172173).

Footnote

Reporting Checklist: The authors have completed the STROBE reporting checklist. Available at <https://atm.amegroups.com/article/view/10.21037/atm-22-384/rc>

Data Sharing Statement: Available at <https://atm.amegroups.com/article/view/10.21037/atm-22-384/dss>

Conflicts of Interest: All authors have completed the ICMJE uniform disclosure form (available at <https://atm.amegroups.com/article/view/10.21037/atm-22-384/coif>).

The authors have no conflicts of interest to declare.

Ethical Statement: The authors are accountable for all aspects of the work in ensuring that questions related to the accuracy or integrity of any part of the work are appropriately investigated and resolved. The study was conducted in accordance with the Declaration of Helsinki (as revised in 2013). The study was approved by the Ethics Committee of Renmin Hospital of Wuhan University (No. WDRY2021-K070) and informed consent was taken from all the patients or their guardians.

Open Access Statement: This is an Open Access article distributed in accordance with the Creative Commons Attribution-NonCommercial-NoDerivs 4.0 International License (CC BY-NC-ND 4.0), which permits the non-commercial replication and distribution of the article with the strict proviso that no changes or edits are made and the original work is properly cited (including links to both the formal publication through the relevant DOI and the license). See: <https://creativecommons.org/licenses/by-nc-nd/4.0/>.

References

- Chen CJ, Ding D, Derdeyn CP, et al. Brain arteriovenous malformations: A review of natural history, pathobiology, and interventions. *Neurology* 2020;95:917-27.
- Mendes GA, Silveira EP, Caire F, et al. Endovascular Management of Deep Arteriovenous Malformations: Single Institution Experience in 22 Consecutive Patients. *Neurosurgery* 2016;78:34-41.
- Schimmel K, Ali MK, Tan SY, et al. Arteriovenous Malformations-Current Understanding of the Pathogenesis with Implications for Treatment. *Int J Mol Sci* 2021;22:9037.
- Schramm J, Schaller K, Esche J, et al. Microsurgery for cerebral arteriovenous malformations: subgroup outcomes in a consecutive series of 288 cases. *J Neurosurg* 2017;126:1056-63.
- Daou BJ, Palmateer G, Thompson BG, et al. Stereotactic Radiosurgery for Brain Arteriovenous Malformations: Evaluation of Obliteration and Review of Associated Predictors. *J Stroke Cerebrovasc Dis* 2020;29:104863.
- Wu EM, El Ahmadieh TY, McDougall CM, et al. Embolization of brain arteriovenous malformations with intent to cure: a systematic review. *J Neurosurg* 2019;132:388-99.
- Elsenousi A, Aletich VA, Alaraj A. Neurological outcomes and cure rates of embolization of brain arteriovenous malformations with n-butyl cyanoacrylate or Onyx: a meta-analysis. *J Neurointerv Surg* 2016;8:265-72.
- Kawashima M, Hasegawa H, Shin M, et al. Outcomes of stereotactic radiosurgery for hemorrhagic arteriovenous malformations with or without prior resection or embolization. *J Neurosurg* 2020. [Epub ahead of print]. doi: 10.3171/2020.7.JNS201502.
- Kim MJ, Park SH, Park KY, et al. Gamma Knife Radiosurgery Followed by Flow-Reductive Embolization for Ruptured Arteriovenous Malformation. *J Clin Med* 2020;9:1318.
- Wang A, Mandigo GK, Feldstein NA, et al. Curative treatment for low-grade arteriovenous malformations. *J Neurointerv Surg* 2020;12:48-54.
- Flores BC, See AP, Weiner GM, et al. Use of the Apollo detachable-tip microcatheter for endovascular embolization of arteriovenous malformations and arteriovenous fistulas. *J Neurosurg* 2018;130:963-71.
- Can A, Gross BA, Du R. The natural history of cerebral arteriovenous malformations. *Handb Clin Neurol* 2017;143:15-24.
- Madhugiri VS, Teo MKC, Westbroek EM, et al. Multimodal management of arteriovenous malformations of the basal ganglia and thalamus: factors affecting obliteration and outcome. *J Neurosurg* 2018;131:410-9.
- Lawton MT, Lang MJ. The future of open vascular neurosurgery: perspectives on cavernous malformations, AVMs, and bypasses for complex aneurysms. *J Neurosurg* 2019;130:1409-25.
- Gao C, Xu B. Surgical technique and nuances in ruptured versus unruptured arteriovenous malformation surgery. *J Neurosurg Sci* 2018;62:478-83.
- Potts MB, Young WL, Lawton MT, et al. Deep arteriovenous malformations in the Basal Ganglia, thalamus, and insula: microsurgical management, techniques, and results. *Neurosurgery* 2013;73:417-29.
- Kano H, Kondziolka D, Flickinger JC, et al. Stereotactic radiosurgery for arteriovenous malformations, Part 4: management of basal ganglia and thalamus arteriovenous malformations. *J Neurosurg* 2012;116:33-43.
- Iyer A, D'souza M, Steinberg GK. Embolization before stereotactic radiosurgery for the treatment of brain arteriovenous malformations. *J Neurosurg Sci* 2018;62:514-8.
- Triano MJ, Lara-Reyna J, Schupper AJ, et al. Embolic Agents and Microcatheters for Endovascular Treatment of Cerebral Arteriovenous Malformations. *World Neurosurg*

- 2020;141:383-8.
20. Sheen JJ, Jiang YY, Kim YE, et al. Increase in fluoroscopic radiation dose in successive sessions of multistage Onyx embolization of brain arteriovenous malformations compared with the first session. *J Neurointerv Surg* 2018;10:e36.
 21. Zaki Ghali MG, Kan P, Britz GW. Curative Embolization of Arteriovenous Malformations. *World Neurosurg* 2019;129:467-86.
 22. Chen CJ, Norat P, Ding D, et al. Transvenous embolization of brain arteriovenous malformations: a review of techniques, indications, and outcomes. *Neurosurg Focus* 2018;45:E13.
 23. De Sousa JMB, Iosif C, Sganzerla LZ, et al. Selection of Patients for Treatment of Brain Arteriovenous Malformations by the Transvenous Approach: Relationship with Venous Anatomy and Risk of Hemorrhagic Complications. *AJNR Am J Neuroradiol* 2020;41:2311-6.
- (English Language Editor: C. Betlazar-Maseh)

Cite this article as: Zhang W, Wei H, Tian Q, Han S, Han W, Guo Y, Wang G, Zhang S, Deng G, Wang J, Chen Q, Li M. Efficacy and safety of embolization for arteriovenous malformations of the basal ganglia and thalamus via the transarterial approach. *Ann Transl Med* 2022;10(6):306. doi: 10.21037/atm-22-384