



## Case of unilateral pellucid marginal corneal degeneration progressing to corneal perforation with keratoconus in contralateral eye

Natsuki Ueji<sup>a</sup>, Kumiko Kato<sup>a,\*</sup>, Yuka Yonekawa<sup>a</sup>, Maki Takeuchi<sup>a</sup>, Yuko Takashima<sup>a</sup>, Koji Hirano<sup>b</sup>, Mineo Kondo<sup>a</sup>

<sup>a</sup> Department of Ophthalmology, Mie University Graduate School of Medicine, Tsu, Japan

<sup>b</sup> Department of Ophthalmology, Fujita Health University Bantane Hospital, Nagoya, Japan

### ARTICLE INFO

#### Keywords:

Pellucid marginal corneal degeneration  
Perforation  
Conservative treatment  
Atopic predisposition

### ABSTRACT

**Purpose:** To report our findings in a case of pellucid marginal corneal degeneration (PMCD) in the left eye and keratoconus (KC) in the right eye, and to review earlier cases of PMCD and KC.

**Observations:** A 45-year-old woman visited our hospital with a complaint of reduced vision in her right eye. She was predisposed to allergies since childhood and had a habit of rubbing her eyes. Based on the results of the corneal topographic study, we diagnosed her with KC in the right eye and PMCD in the left eye. We prescribed a rigid, gas permeable contact lens and treated her allergic conjunctivitis with ocular medications. Three years after her initial visit, she developed a corneal perforation in the left eye. The perforation was closed by conservative treatment consisting of therapeutic soft contact lens wear. One year after the cornea healed, the corneal astigmatism in the left eye was about one-half of what it was before the corneal perforation. Her corrected visual acuity improved to 1.0 with conventional spectacles.

**Conclusion and Importance:** We found a difference in the progression of KC and PMCD even when they occurred in same individual. We suggest that the atopic predisposition, which is considered a risk factor for acute hydrops in KC, to be a risk factor for acute hydrops and corneal perforation in eyes with PMCD.

### 1. Introduction

Pellucid marginal corneal degeneration (PMCD), first described by Schlaeppli in 1957, is a relatively rare disorder that is associated with non-inflammatory thinning of the lower periphery of the cornea.<sup>1</sup> Patients often visit ophthalmologists in their 30s or later with a main complaint of vision decrease. In these patients, slit-lamp microscopy shows a noninflammatory band of thinning in the periphery of the inferior cornea and an adjacent anterior protrusion of the upper region. This appearance has been described as a “beer belly” cornea. Corneal analysis shows a “crab claw” pattern.<sup>2</sup>

PMCD is more common in men than in women and is more often bilateral.<sup>3</sup> The etiology of PMCD has not been definitively determined, but it is believed to be a disorder related to keratoconus (KC) because it is often seen in the same family. In addition, KC is often present in the contralateral eye of patients with PMCD.<sup>4</sup> The difference between the two disorders is that KC often occurs at a younger age, 10–20 years, while PMCD occurs after the age of 30 years. The common denominator

of both is that acute hydrops, a condition characterized by stromal edema due to leakage of aqueous into the stroma through a tear in Descemet’s membrane, can develop when the corneal thinning is advanced causing the tears in Descemet’s membrane. The risk factor for acute hydrops in KC has been reported to be an atopic predisposition of the patient,<sup>5</sup> but there have been no reports describing the risk factors for acute hydrops in PMCD. This may be because PMCD is much rarer than KC.

We have examined a case of unilateral PMCD that progressed to a corneal perforation in a patient whose contralateral eye had KC. We report our findings in this case and compare them with the findings of previous cases of PMCD and KC.

### 2. Case report

The patient had been aware of the vision decrease in her right eye since she was about 20-years-old. When she could no longer be corrected by conventional spectacles, she visited the eye clinic around the age of

\* Corresponding author. Department of Ophthalmology, Mie University Graduate School of Medicine, 2-174 Edobashi, Tsu, Mie, 514-8507, Japan.

E-mail address: [k-kato@clin.medic.mie-u.ac.jp](mailto:k-kato@clin.medic.mie-u.ac.jp) (K. Kato).

<https://doi.org/10.1016/j.ajoc.2022.101293>

Received 9 December 2020; Received in revised form 15 July 2021; Accepted 17 January 2022

Available online 25 January 2022

2451-9936/© 2022 The Authors.

Published by Elsevier Inc.

This is an open access article under the CC BY-NC-ND license

(<http://creativecommons.org/licenses/by-nc-nd/4.0/>).

30 years. She was prescribed soft contact lenses. After the age of 40 years, she had a decrease in her visual acuity in the right eye in spite of wearing the soft contact lenses, and she was referred to our hospital.

At the initial examination, the patient had no specific complaints about the left eye. However, she reported that she had a history of atopic predisposition since her early childhood and had a habit of rubbing her eyes. There were no other relevant family histories. Her corrected decimal BCVA was 0.1 with a correction of  $-8.00\text{ DS} = -10.00\text{ DC Ax }53^\circ$  in the right eye and 1.0 with  $-0.50\text{ DS} = -7.00\text{ DC Ax }103^\circ$  in the left eye. We noted the very high astigmatism in both eyes. The intraocular pressure was 8 mmHg in the right eye and 17 mmHg in the left. Slit-lamp microscopy showed an anterior protrusion of both corneas (Fig. 1A and B). In addition, there were allergic changes in both conjunctivas with hyperemia and follicular formation in the upper eyelid. She was aware of her unpleasant pruritus sensation that provoked her desire to rub her eyes. There were no obvious abnormalities in the lens, vitreous cavity, and retina that could have caused the reduction of vision. Examination of the corneal topography showed a marked protrusion of the paracentric inferior cornea in the right eye and a band-shaped, highly refractive area in the most peripheral part of the inferior cornea of the left eye (Fig. 1C and D). Corneal pachymetry maps showed mild thinning in the inferior part of the cornea of both eyes (Fig. 1E and F).

We diagnosed her with KC in the right eye based on the age of onset and corneal topography. We diagnosed her left eye with PMCD based on the area of corneal thinning and band-shaped protrusion.

Rigid gas permeable hard contact lenses were prescribed for both eyes to treat the astigmatism due to the abnormal corneal shapes. The decimal visual acuity with the contact lenses was 1.0 for the right eye and 1.5 for the left eye.

The corneal topography obtained 2.5 years after the initial examination showed that there was almost no progression of the corneal topography in the right eye, but the inferior part of the cornea in the left eye was approximately 100  $\mu\text{m}$  thinner than that at the initial visit. The axial power map showed a typical crab claw pattern (Fig. 2A–D). She complained of a foreign body sensation in both eyes, and our examination of the upper eyelid conjunctiva showed an increase in the degree of conjunctival follicles and edema. She was prescribed topical epinas-tine, an antihistamine, ophthalmic solution.

Three years after the initial visit, the patient visited our hospital with a complaint of pain, ocular discharge, and tearing in the left eye. Slit-lamp biomicroscopy showed corneal edema and a corneal perforation in the inferior part of cornea of the left eye, and the anterior chamber was completely collapsed (Fig. 3A). The patient was treated with a bandage contact lens, systemic carbonic acid dehydrogenase inhibitor, and topical atropine. One week later, the bandage contact lens was

removed after we confirmed that the anterior chamber was fully formed, and the leakage of the aqueous humor had stopped.

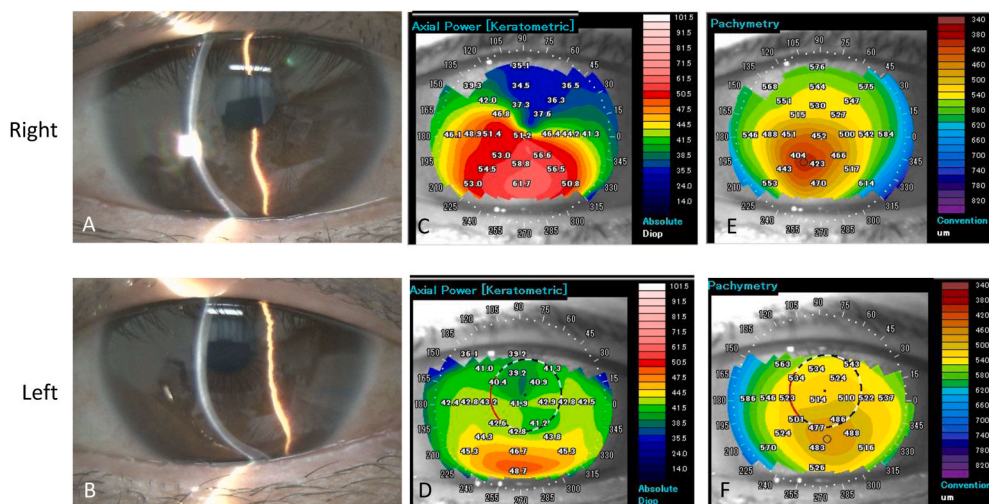
One year after the healing, a corneal opacity was present (Fig. 3B and D), but the corneal astigmatism has been reduced compared to that before the perforation (Fig. 3C). In addition, the corneal thickness around the corneal perforated area was preserved (Fig. 3D). Her corrected decimal BCVA at the final visit was 1.0 with a correction of  $-2.25\text{ DS} = -4.00\text{ DC Ax }20^\circ$  in the left eye.

### 3. Discussion

Our results showed that there was a progressive thinning of the cornea in the left eye with PMCD over a three-year period. This led to a corneal perforation. Marked corneal edema around the perforated area suggested that the corneal perforation occurred secondary to acute hydrops. On the other hand, the right eye diagnosed with KC showed little change in its corneal topography.

Eyes with PMCD and KC can develop acute hydrops but the frequency in PMCD is not known because PMCD is very rare.<sup>2</sup> Cases leading to corneal perforation in PMCD are even rarer, and according to previous reports, 20 eyes with a corneal perforation were identified in 16 PMCD patients (Table 1). The mean age at the time of the corneal perforation was  $50.1 \pm 14.6$  years. We examined the published findings in 18 eyes with KC leading to corneal perforation that were reported after 1987, and the mean age at the time of corneal perforation was  $36.9 \pm 16.3$  years (Table 1).<sup>20–34</sup> We believe that the progression of corneal degeneration in eyes with PMCD has a later age of occurrence than KC. This then resulted in a later age of corneal perforation in eyes with PMCD than eyes with KC.

The question then arises on whether the age of the onset of these corneal disorders differ even when they occur in the same individual. Earlier studies in Japan reported that 9 of 108 (8.3%) patients diagnosed with PMCD had KC or suspected KC in the contralateral eye.<sup>3</sup> However, there have been no reports on whether the timing of progression of these two disorders coincided when they occurred in the same individual. Furthermore, in our current case, the axial power map of the right eye at 3 years after the initial examination showed crab claw-like changes. This suggested that the patient may have developed both KC and PMCD in the right eye. According to Barraquer et al., 30% of patients with PMCD have atypical corneal topographic findings, and they reported that they found KC and PMCD in the same eye in those cases.<sup>6</sup> In our case, the degree of progression of the corneal degeneration was different between the right eye, which may have had both KC and PMCD, and the left eye, which had only PMCD. However, there have been no report that reported the detailed clinical course of eye that developed KC and PMCD

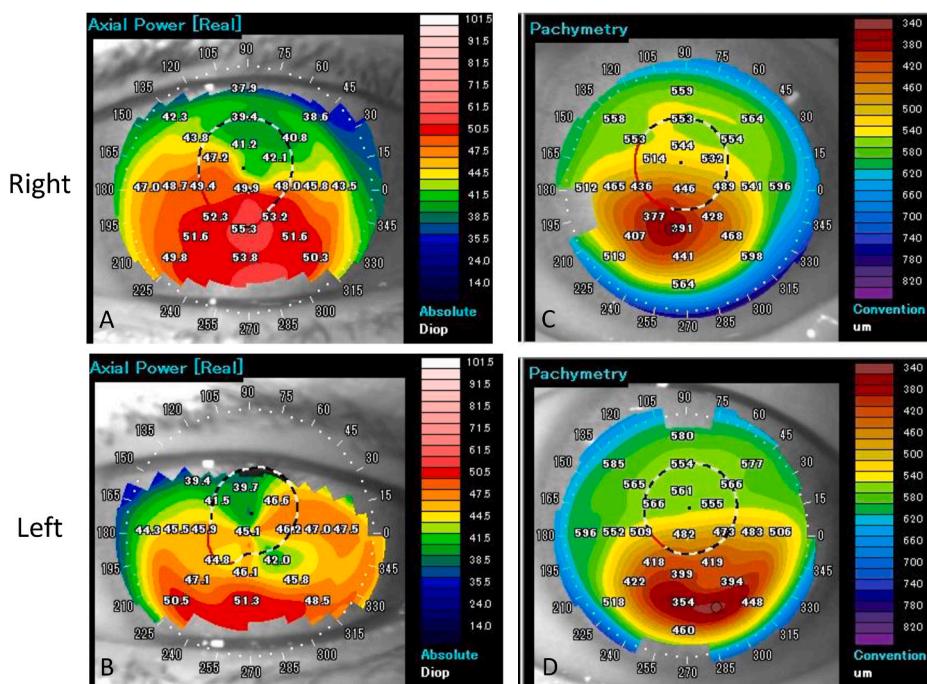


**Fig. 1.** Findings of slit-lamp microscopy and corneal topography at the initial visit in a patient with keratoconus (KC) in the right eye and pellucid marginal corneal degeneration (PMCD) in the left eye.

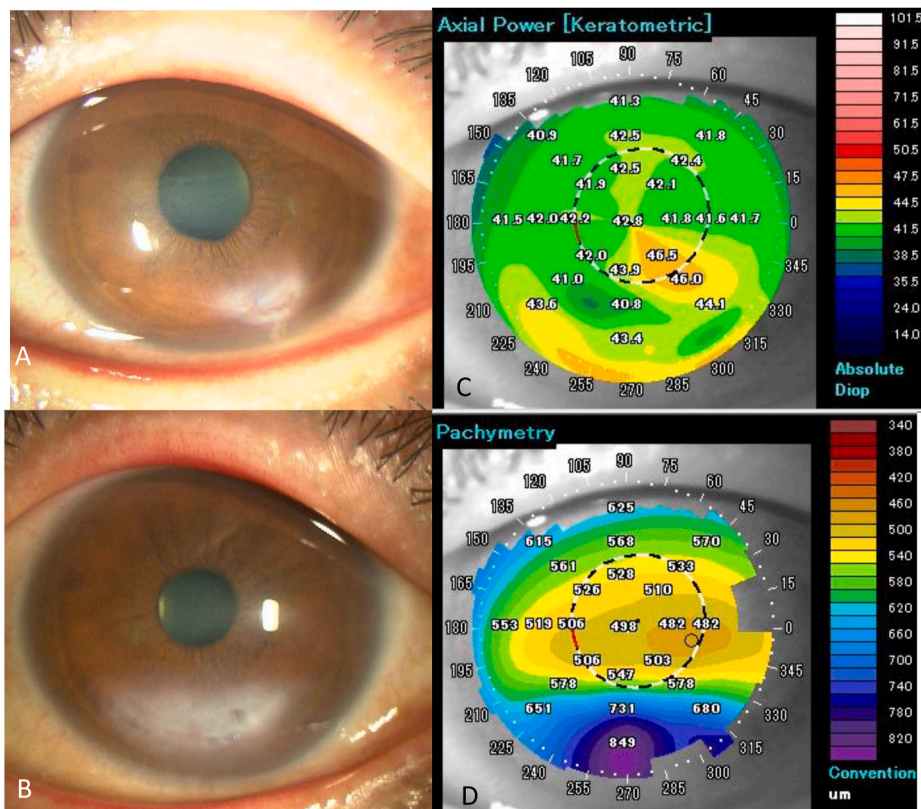
A: and B: Anterior protrusion of the inferior cornea can be seen in the photographs taken through a slit-lamp (A: Right eye, B: Left eye).

C: and D: Axial power maps showing high refractive power in the inferior half of the cornea of the right eye and in the most peripheral part of the cornea of the left eye (C, Right eye; D, Left eye).

E: and F: Pachymetry maps showing mild thinning in the paracentral region of the cornea of both eyes (E, Right eye; F, Left eye).



**Fig. 2.** Corneal topographic findings at 2.5 years after the initial visit. A: and B: Axial power maps show a high refractive power at the inferior half of the cornea in both eyes. Crab claw-like changes can be seen in the left eye (A, Right eye; B, Left eye). C: and D: Corneal thickness maps show almost no progression of corneal thinning in the right eye, but a significant progression of thinning in the inferior periphery of the cornea in the left eye (C, Right eye; D, Left eye).



**Fig. 3.** Slit-lamp photographs at the time of corneal perforation and slit-lamp photograph and corneal topography map after healing. A: Slit-lamp image shows acute hydrops at 5 o'clock of the cornea and the collapse of the anterior chamber. B: Slit-lamp photograph at 8 months after the healing. Corneal opacity is present but the anterior chamber has reformed. C: and D: Corneal topographic maps at 8 months after the healing. Corneal astigmatism is markedly reduced. Corneal thickness around the corneal perforated area is preserved.

in the same eye. We will continue to monitor the patient to follow the changes in the corneal topography and if there is any difference in the speed of corneal degeneration between the left eye and the right eye.

We examined earlier publications on whether there were acute hydrops in 21 eyes with PMCD that developed corneal perforation including our case and found that there were 15 eyes with acute hydrops

and 6 eyes without acute hydrops. Cases without acute hydrops were characterized by a relatively wide areas of corneal thinning even before the perforation and a large corneal perforation.<sup>7-10</sup> In addition, there was one case of a corneal perforation that occurred during a fundus examination with scleral indentation.<sup>10</sup> Conservative treatments failed in these cases, and it required corneal suturing or corneal

**Table 1**  
Characteristics of patients who developed corneal perforation in PMCD and KC.

PMCD						KC					
Case No.	Age	Sex	Eyes	Allergic predisposition	Reference	Case No.	Age	Sex	Eyes	allergic predisposition	Reference
1	33	F	R	NR	10	1	27	M	L	Rubbing eye	20
2	56	F	L	None	17	2	34	F	L	None	21
3	61	F	B	Eczema	7	3	30	M	L	None	22
4	62	M	B	None	7	4	53	M	L	None	23
5	35	F	R	Asthma, Eczema	7	5	21	M	L	None	24
6	41	F	B	None	9	6	59	F	L	Rubbing eye	25
7	74	M	L	None	12	7	24	F	R	None	26
8	29	M	R	None	13	8	63	M	B	None	27
9	55	M	L	None	13	9	19	F	R	NR	28
10	66	M	L	None	14	10	23	M	L	NR	28
11	54	F	L	Atopic keratoconjunctivitis	14	11	55	F	R	NR	29
12	55	M	L	Atopic dermatitis	8	12	58	F	L	None	29
13	56	M	L	None	18	13	26	F	L	Asthma	30
14	20	M	L	NR	19	14	21	M	L	Atopic dermatitis	31
15	38	M	B	None	15	15	47	F	R	Atopic dermatitis	32
16	44	M	L	Atopic dermatitis	16	16	35	M	R	Rubbing eye	33
17	48	F	L	Allergic conjunctivitis, rubbing eye	our case	17	14	M	R	Rubbing eye	34

KC: keratoconus, PMCD: Pellucid marginal corneal degeneration, NR:Not reported, R: Right eye, L: Left eye, B: Both eyes.

transplantation. In cases of extensive corneal thinning, the patient may need to be informed of the risk of corneal perforation and to avoid any degree of pressure on the eye.

Allergic predispositions to vernal conjunctivitis, asthma, and other allergic disorders are risk factors for acute hydrops in eyes with KC.<sup>5</sup> Although there are no reports on the risk factors for acute hydrops in eyes with PMCD, a study of 108 patients with PMCD in Japan reported that 22.2% of patients had an allergic predisposition.<sup>3</sup> Allergic predispositions, such as atopic dermatitis, were found in 6 of the 17 cases of KC that developed a corneal perforation, and 6 of 18 patients with PMCD who developed a corneal perforation had allergic predisposition and/or habit of rubbing the eyes (Table 1). Furthermore, an analysis of the risk factors for acute hydrops in 22 cases of corneal ectatic disorders showed that 95% of the patients had seasonal allergic disease and 91% had allergy associated with an eye-rubbing behavior.<sup>11</sup> These reports and the present case suggest that allergic predisposition is most likely a risk factor for acute hydrops and corneal perforation in eyes with PMCD.

Currently, there is no effective treatment to prevent the progression of PMCD, and we should consider aggressive treatment for cases with allergy associated eye-rubbing behavior to reduce the risk the development of acute hydrops and corneal perforation. In our case, epinastine eye drops were administered to reduce the eye-rubbing behavior, but the disease had already progressed to corneal perforation. If we had started the anti-allergic treatment earlier, we may have avoided the acute hydrops and corneal perforation.

We reviewed the cases that had undergone treatment of a corneal perforation associated with PMCD and found that conservative treatments with tissue adhesive and/or therapeutic contact lenses were performed in 13 of 20 eyes.<sup>7,9,10,12–16</sup> The conservative treatment was successful in 4 eyes, 4 eyes required corneal sutures, and 12 eyes required corneal transplantation.<sup>7–10,12–14,17–19</sup> Three eyes that had been treated by therapeutic contact lenses alone were healed,<sup>15,16</sup> and one eye was successfully treated by a combination of tissue adhesive and therapeutic contact lenses.<sup>13</sup> Although corneal transplants have been the most performed treatment, we need to be aware of the possibility of corneal astigmatism induced by the surgery. Therefore, we should attempt conservative treatments with therapeutic contact lenses especially in cases of relatively small perforations.

#### 4. Conclusions

We examined a case with PMCD in one eye and keratoconus in the contralateral eye. Our findings showed that the degree of progression differed between the eyes, and an allergic predisposition was likely the risk factor for acute hydrops and corneal perforation in this eye with

PMCD. Thus, clinicians should be aware of allergic predisposition and eye-rubbing behavior when following these corneal disorders.

#### 5. Patient consent

Written informed consent was obtained from the patient for publication of this Case report and any accompanying images. A copy of the written consent is available for review by the Editor of this journal.

#### Funding

Grant-in-Aid for Scientific Research C (MK, 18H02954 and 17K19721) from Ministry of Education, Culture, Sports, Science and Technology, Japan.

#### Author contributions

KK, NU, KH and MK wrote the main manuscript. NU, YY, YT and MT collected the data. All authors reviewed the manuscript.

#### Declaration of competing interest

N. Ueji, None; K. Kato, None; Y. Yonekawa, None; M. Takeuchi, None; K Hirano, None; M. Kondo, Novartis (F).

#### Acknowledgements

We thank Professor Emeritus Duco I. Hamasaki of the Bascom Palmer Eye Institute of the University of Miami (Miami, FL, USA) for critical discussion and final manuscript revisions.

#### References

- Schlaeppli V. La dystrophie marginale inférieure pellucide de la cornée. *Bibl Ophthalmol.* 1957;12:672–677.
- Feder R. In: Krachmer JH, Mannis M, Holland E, eds. *Pellucid Marginal Degeneration.* Missouri: Mosby; 2011:878–881. Cornea. 3 ed.
- Shimazaki J, Maeda N, Hieda O, et al. National survey of pellucid marginal corneal degeneration in Japan. *Jpn J Ophthalmol.* 2016;60:341–348.
- Kayazawa F, Nishimura K, Kodama Y, Tsuji T, Itoi M. Keratoconus with pellucid marginal corneal degeneration. *Arch Ophthalmol.* 1984;102:895–896.
- Barsam A, Brennan N, Petrushkin H, et al. Case-control study of risk factors for acute corneal hydrops in keratoconus. *Br J Ophthalmol.* 2017;101:499–502.
- Barraquer F. Results of the crescent resection in keratotorus. *Dev Ophthalmol.* 1981; 5:49–51.
- Chan E, Snibson GR, Poon A. Direct surgical repair of corneal perforation in pellucid marginal degeneration: a case series. *Cornea.* 2013;32:1058–1062.
- Millar MJ, Maloof A. Deep lamellar keratoplasty for pellucid marginal degeneration: review of management options for corneal perforation. *Cornea.* 2008;27:953–956.

9. Lee WB, O'Halloran HS, Grossniklaus HE. Pellucid marginal degeneration and bilateral corneal perforation: case report and review of the literature. *Eye Contact Lens*. 2008;34:229–233.
10. Mercieca K, Dharmasena A, Hopley C. Corneal perforation during scleral indentation in a patient with pellucid marginal degeneration. *Indian J Ophthalmol*. 2016;64:233–234.
11. Grewal S, Laibson PR, Cohen EJ, Rapuano CJ. Acute hydrops in the corneal ectasias: associated factors and outcomes. *Trans Am Ophthalmol Soc*. 1999;97:187–198. ; discussion 198–203.
12. Orlin SE, Sulewski ME. Spontaneous corneal perforation in pellucid marginal degeneration. *CLAO J : official publication of the Contact Lens Association of Ophthalmologists, Inc*. 1998;24:186–187.
13. Aldave AJ, Mabon M, Hollander DA, McLeod SD, Spencer WH, Abbott RL. Spontaneous corneal hydrops and perforation in keratoconus and pellucid marginal degeneration. *Cornea*. 2003;22:169–174.
14. Symes RJ, Catt CJ, Sa-ngiampornpanit T, Males JJ. Corneal perforation associated with pellucid marginal degeneration and treatment with crescentic lamellar keratoplasty: two case reports. *Cornea*. 2007;26:625–628.
15. Forooghian F, Assaad D, Dixon WS. Successful conservative management of hydrops with perforation in pellucid marginal degeneration. *Canadian journal of ophthalmology Journal canadien d'ophtalmologie*. 2006;41:74–77.
16. Shikauchi M, Takamura E, Shinozaki K, Hori S. Pellucid marginal corneal degeneration with acute hydrops and spontaneous corneal perforation. *J Eye*. 2004;21:103–106.
17. Lucarelli MJ, Gendelman DS, Talamo JH. Hydrops and spontaneous perforation in pellucid marginal corneal degeneration. *Cornea*. 1997;16:232–234.
18. Akpek EK, Altan-Yaycioglu R, Gottsch JD, Stark WJ. Spontaneous corneal perforation in a patient with unusual unilateral pellucid marginal degeneration. *J Cataract Refract Surg*. 2001;27:1698–1700.
19. Lang PJ, Seitz B, Völcker HE. Long-term results after perforating corneo-scleroplasty in a case of acute unilateral superior pellucid marginal corneal degeneration. *Klin Monbl Augenheilkd*. 2003;220:262–267.
20. Palamar M, Dincer G, Teker ME, Kayahan B, Gonul AS. Bilateral keratoconus, acute hydrops and unilateral corneal perforation due to Tourette syndrome. *Saudi J Ophthalmol*. 2019;33:177–179.
21. Lam FC, Bhatt PR, Ramaesh K. Spontaneous perforation of the cornea in mild keratoconus. *Cornea*. 2011;30:103–104.
22. Hilely A, Kleinmann G. Case report: acute hydrops and spontaneous corneal perforation in a patient with keratoconus treated with colchicine for familial Mediterranean fever. *Int Ophthalmol*. 2019;39:1367–1369.
23. Tsalousis KT, Chalvatzis N, Symeonidis C, et al. Corneal perforation as a primary manifestation of keratoconus in a patient with underlying rheumatoid arthritis. *Journal of ophthalmic inflammation and infection*. 2012;2:57–60.
24. Yeh S, Smith JA. Management of acute hydrops with perforation in a patient with keratoconus and cone dystrophy: case report and literature review. *Cornea*. 2008;27:1062–1065.
25. Stoiber J, Muss W, Ruckhofer J, Grabner G. Acute keratoconus with perforation in a patient with Down's syndrome. *Br J Ophthalmol*. 2003;87:120.
26. Lahoud S, Brownstein S, Laflamme MY, Poleski SA. Keratoconus with spontaneous perforation of the cornea. *Canadian journal of ophthalmology Journal canadien d'ophtalmologie*. 1987;22:230–233.
27. Dantas PE, Nishiwaki-Dantas MC. Spontaneous bilateral corneal perforation of acute hydrops in keratoconus. *Eye Contact Lens*. 2004;30:40–41.
28. Ingraham HJ, Donnenfeld ED, Perry HD. Keratoconus with spontaneous perforation of the cornea. *Arch Ophthalmol*. 1991;109:1651–1652.
29. Mostafavi D, Chu DS. Two cases of keratoconus associated with spontaneous corneal perforation. *Cornea*. 2010;29:825–827.
30. Ch'ng SW, Pillai MB, Aazeem S, Tu KL. Acute corneal hydrops mimicking full thickness perforation. *BMJ Case Rep*. 2012, 2012.
31. Nicoli C, Wainsztein RD, Trotta LP. Corneal topography of spontaneous perforation of acute hydrops in keratoconus. *J Cataract Refract Surg*. 1999;25:871–872.
32. Petrelli M, Cohen J, Hashemi K, Grentzelos MA, Kymionis GD. A new surgical approach for the management of acute corneal hydrops complicated with corneal perforation. *Cornea*. 2020;39:1066–1068.
33. Rubsamén PE, McLeish WM. Keratoconus with acute hydrops and perforation. Brief case report. *Cornea*. 1991;10:83–84.
34. Sii F, Lee GA, Gole GA. Perforated corneal hydrops treated with sulfur hexafluoride (SF6) gas and tissue adhesive. *Cornea*. 2005;24:503–504.