

Laparoscopic Pylorus- and Spleen-Preserving Duodenopancreatectomy for a Multifocal Neuroendocrine Tumor

Erik Schlöricke^a Martin Hoffmann^b Peter Kujath^b Ganesh M. Shetty^c Fabian Scheer^c
Marc O. Liedke^a Markus Zimmermann^b

^aVisceral, Thoracic and Vascular Surgery, West Coast Hospital Heide, Heide, Germany,

^bDepartment of Surgery, University of Schleswig-Holstein, Campus Lübeck, Lübeck, Germany,

^cInstitute of Diagnostic and Interventional Radiology, West Coast Hospital Heide, Heide, Germany

Keywords

Pylorus- and spleen-preserving duodenopancreatectomy · Laparoscopic total duodenopancreatectomy, LDP · Neuroendocrine tumor, NET · Multiple endocrine neoplasia, MEN

Summary

Background: In contrast to laparoscopic left pancreatic resection, laparoscopic total duodenopancreatectomy is a procedure that has not been standardized until now. It is not only the complexity that limits such a procedure but also its rare indication. The following article demonstrates the technical aspects of laparoscopic pylorus- and spleen-preserving duodenopancreatectomy. **Case Report:** The indication for intervention in the underlying case was a patient diagnosed with a multiple endocrine neoplasia (MEN) I syndrome and a multifocal neuroendocrine tumor (NET) infiltrating the duodenum and the pancreas. The patient was post median laparotomy which was necessary after jejunal perforation due to a peptic ulcer. The resection was carried out entirely laparoscopically, and the reconstruction, which included a biliodigestive anastomosis and a gastroenterostomy, was carried out by means of a median upper abdomen laparotomy of 7 cm in length through which the resected specimen was also removed. The total operative time was 391 min. The blood loss accounted for 250 ml. The postoperative course was uneventful, and the patient was discharged on the eighth postoperative day. **Conclusion:** Laparoscopic pancreatectomy is a treatment option in carefully selected indications. The complexity of the operation demands a high level of expertise in the surgical team.

© 2015 S. Karger GmbH, Freiburg

Introduction

Over the last decade remarkable progress has been made in laparoscopic surgery. Nowadays, laparoscopic pancreatic surgery is a standard procedure in diagnosis and treatment [1]. However, a special feature of this procedure continues to be laparoscopic total duodenopancreatectomy (LDP) [2], being a combination of the already established laparoscopic left-sided pancreatectomy and the still challenging laparoscopic resection of the pancreatic head [3, 4]. A limitation to the establishment of this method is the rare indication for this procedure [5]. Depending on the indication, LDP can also be performed as a pylorus- and spleen-preserving procedure [6]. As already described in laparoscopic left pancreatic resection, a spleen-preserving procedure is associated with a lower postoperative complication rate and is therefore favored in appropriate cases [7]. In the following article, we report a case of laparoscopic pylorus- and spleen-preserving duodenopancreatectomy (LDP) in a patient with multiple endocrine neoplasia (MEN) I syndrome and a multifocal neuroendocrine tumor (NET) of the duodenum and pancreas.

Case Report

The diagnosis and surgical treatment was done in the West Coast Hospital in Heide, Germany. A 30-year-old patient with a body mass index of 31 kg/m² was diagnosed with MEN I syndrome at the age of 28 years by gene analysis. The diagnosis was made following primary hyperparathyroidism due to solitary parathyroid adenoma. In addition, a prolactinoma was detected, which was managed conservatively. The patient then developed a jejunal perforation 20 cm distal to the ligament of Treitz due to a perforated ulcer. This was handled with segmental resection by means of a median laparotomy. A consecutive duodenoscopy showed multiple duodenal ulcerations. The corresponding laboratory parameters (gastrin 1,983 ng/l) and chromogranin A (3,510 µg/l) confirmed a gastrinoma. Further diagnostic imaging in the form of endosonography, magnetic resonance tomography, positron emission tomography, and so

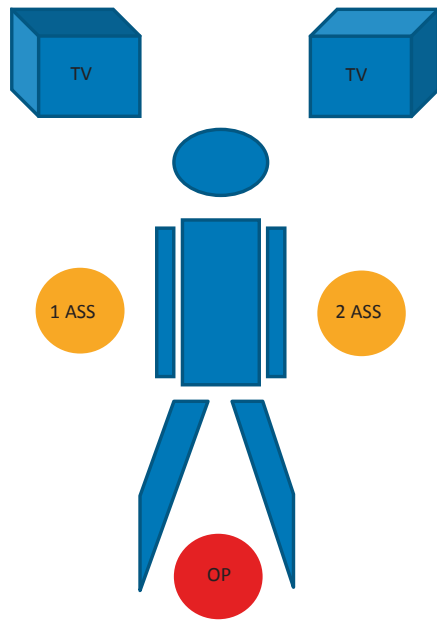


Fig. 1. Position of the patient, the surgeon, and the assistant.

matostatin receptor scintigraphy showed multiple NET throughout the pancreas, particularly in the pancreatic tail. It also showed two pathological lymph nodes in the area close to the pancreatic head. After an interdisciplinary discussion of the findings, an indication for LDP was made. The decision for such an indication was made when taking into account the young age of the patient and therefore the aim to avoid further secondary operations for recurrences.

Surgical Technique of LDP

Figure 1 shows the positioning of the patient as well as the position of the surgeon and the assistant. The monitors are positioned on either side of the head of the patient. The positions of the trocars, as shown in figure 2, allow the use of three 10-mm trocars (midline and paramedian on both sides) as well as of two 5-mm trocars (anterior axillary line) for optimal visualization in the preparatory phase. The described technique requires no extra instruments except for 5-mm Titan Clips (Ethicon Endoscopic Clip Applier 5 mm Titan Ligamax 5[®]; Johnson & Johnson Medical GmbH, Ethicon Deutschland, Norderstedt, Germany); thus, it has no impact on costs. As grasping forceps the atraumatic PO7R and the Dorsey bowel forceps P618R (both Aesculap[®], Tuttlingen, Germany) are utilized. The preparation is performed with the bipolar Maryland forceps PM431R and the Metzenbaum Scissors PM430R (both Aesculap[®], Tuttlingen, Germany). Alternatively, the Metzenbaum Scissors can be replaced by an ultrasonic dissector (Ultracision Harmonic Scalpel[®]; Johnson & Johnson Medical GmbH, Ethicon Deutschland, Norderstedt, Germany).

The preparation according to the presented technique is carried out by the following three steps:

- spleen-preserving mobilization and exposure of the tail of the pancreas;
- pylorus-preserving exposure and mobilization of the pancreatic head and the duodenum;
- removal of the resected segment and reconstruction by means of a small median laparotomy.

Spleen-Preserving Mobilization and Exposure of the Tail of the Pancreas

The preparatory stage begins after an exploratory laparoscopy and laparoscopic ultrasound of the liver and the hepatoduodenal ligament to rule out other unexpected pathologies. The visualization of the pancreas requires a mobilization of the entire transverse colon and of both colic flexures. The mobilization begins with the opening of the omental bursa. For this purpose, the division of the gastrocolic ligament can be successfully carried out even in extremely obese patients. The pancreas is exposed once the stomach is retracted

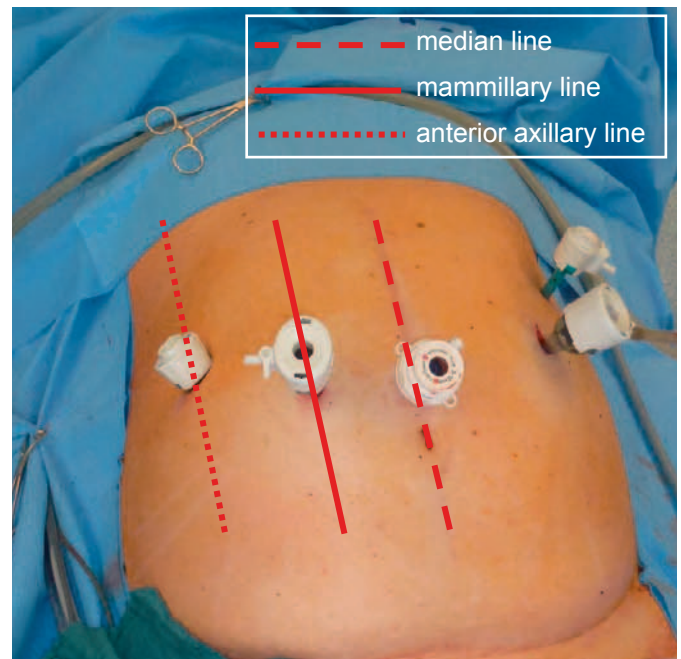


Fig. 2. Position of the trocars.

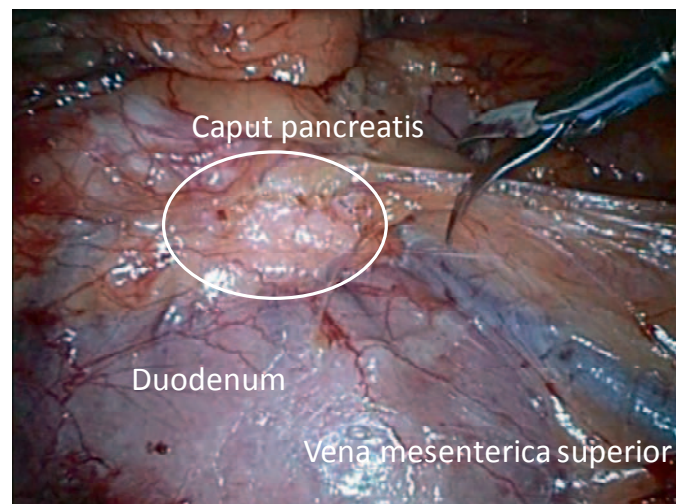


Fig. 3. Exposed superior mesenteric vein as a landmark to visualize the portal vein.

cranially and ventrally. This step also facilitates the subsequent mobilization of the two colic flexures, which is started from the left side. After the mobilization of the descending colon from its lateral adhesions, the preparation is carried out by beginning on Gerota's fascia and then moving upwards to the exposition of the spleen. Due to the preparation of the left colonic flexure an opening of the omental bursa from the left side and an exposition of the pancreas is possible. The preparation along the front edge of the pancreas can be carried out up to the middle colic artery and middle colic vein. Tension on the transverse colon in dorsocaudal direction can avoid an iatrogenic lesion of the inferior mesenteric vein (fig. 3). The mobilization of the right colonic flexure should also be carried out on Gerota's fascia. In order to avoid iatrogenic lesion of the duodenum, a further opening of the omental bursa to the right side to explore Gerota's fascia from the cranial direction is performed. During this step, a small branch leading from the pancreatic head to the middle colic vein can impede further preparation. A lesion of this only 2–3 cm long venous branch can lead

to severe bleeding and consecutive conversion to laparotomy. After exposition of this branch a ligation with an ultrasonic dissector can easily be done. All other mentioned steps are performed in avascular planes and can therefore be carried out with bipolar scissors. As shown in figure 3, the medial colic vein and the superior mesenteric vein are displayed after a complete mobilization of the transverse mesocolon. Both of them are used as a guide to reach the portal vein, which is then mobilized along the posterior surface of the pancreas up to the venous confluence. This can be done with scissors. Any electrocoagulation should be avoided due to thermic lesions of the venous wall which can also lead to emergency conversion. Finally, it is important to state that mobilization of the portal vein can only be done after preparation of the hepatoduodenal ligament.

The splenic vein is then mobilized laterally, starting from the venous confluence. Here, the difficulty in dissection arises from small vulnerable branches leading to the body and tail of the pancreas. As for the portal vein, electrocoagulation should be strictly avoided, too, and the same also applies to ultrasonic dissection. Isolation of single branches should only be performed by scissors and grasping forceps. These are consecutively ligated with titanic clips and dissected as shown in figure 4. The smallest uncontrolled lesion on these vessels would result in a significant loss of overview. Subsequently, the splenic artery is dissected, beginning on the upper margin of the pancreas. To avoid severe bleeding, preparation should be performed according to the previous paragraph. If adequate distance to venous structures is ensured, electrocoagulation may be used. The mobilization to the splenic hilum can be carried out from either the upper or the lower edge of the pancreas. The mobilization of the pancreatic tail beginning at the splenic hilum starts with its preparation from the retroperitoneum on the level of Gerota's fascia up to the ventrally exposed splenic vessels. The preparation of the pancreatic tail from the hilum is unproblematic because the splenic artery and splenic vein show no branches in this area. It is important to consider that the spleen can have multiple hila. This variant of peripheral segmentation of the splenic vessels has to be kept in mind during preparation. The fat body located between the pancreatic tail and the spleen contains lymph nodes and therefore has to remain with the histological specimen.

Pylorus-Preserving Exposure and Mobilization of the Pancreatic Head and the Duodenum

In the previous step, the portal vein was exposed from the middle colic vein and mobilized up to the venous confluence from the lower surface of the pancreas. The head of the pancreas is then mobilized using the Kocher maneuver. This is carried out by first exposing the aorta, dorsally undergoing the hepatoduodenal ligament, and then partially opening the peritoneum of the duodenojejunal flexure.

In our approach, the dissection includes the hepatoduodenal ligament. As shown in figure 5, this step exposes the portal vein, the common bile duct, and the gastroduodenal artery. After the exposition of these landmarks, a lymphadenectomy is done to the right and left side of the hepatic artery until the upper edge of the pancreatic head. Even in this step only bipolar scissors and grasping forceps are used. Only for the right gastric artery the application of the ultrasonic dissector is recommended. The assistant has to enable sufficient traction in the operating area by tearing at the gallbladder. After the dissection of the right gastric artery, a small orifice in the region of the lesser omentum opens up. This can be used as a landmark for further postpyloric mobilization. If this vessel is not to be exposed, further adhesions between the anterior pancreatic surface and the posterior wall of the stomach need to be dissected. After the separation of the gastroepiploic artery and gastroepiploic vein as well as its ligation with Lapro Clips 12 mm (Covidien®, Neustadt/Donau, Germany), a circular postpyloric mobilization of the duodenum is possible. The mobilization of the duodenum is carried out close to the upper margin of the pancreas. Small vessels in this area are ligated with the help of an ultrasonic dissector. A distance of 2–3 cm guarantees a pylorus-preserving re-anastomosis after a postpyloric division of the stomach with the help of a GIA (fig. 6). The dissection is performed with a bendable Endo GIA (Echelon Flex, Endopath Stapler®; Johnson & Johnson Medical GmbH, Ethicon Deutschland, Norderstedt, Germany) which facilitates the adaption to the given anatomy. The mobilized stomach is then retracted on to left upper abdomen.

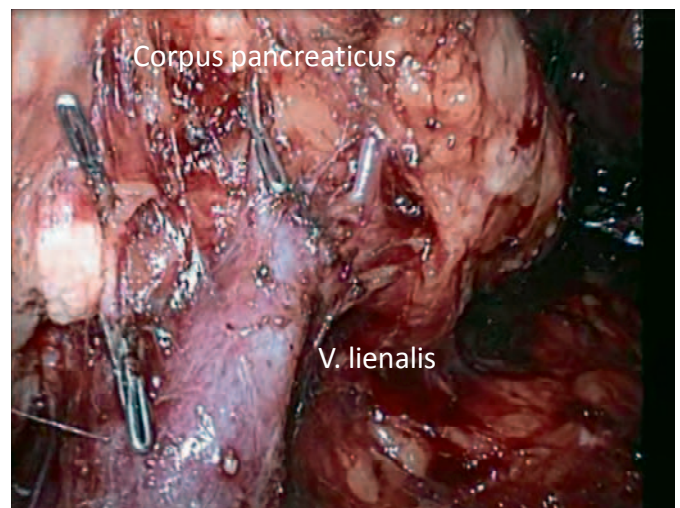


Fig. 4. Dissection of the small branches from the splenic vein to the body and tail of the pancreas.

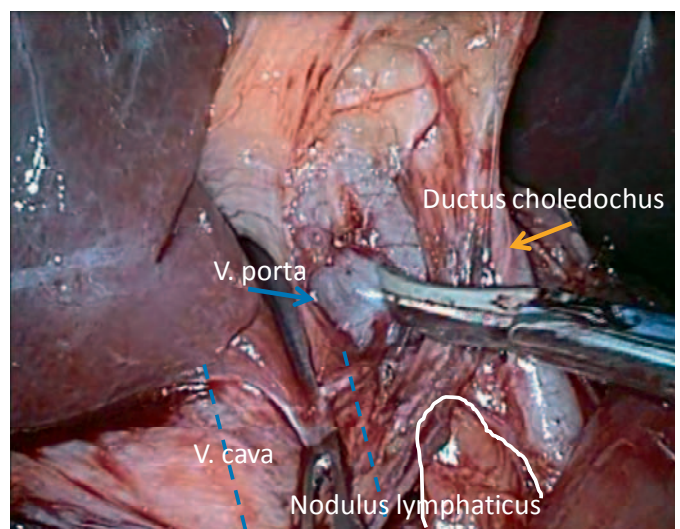


Fig. 5. Dissection of the hepatoduodenal ligament.

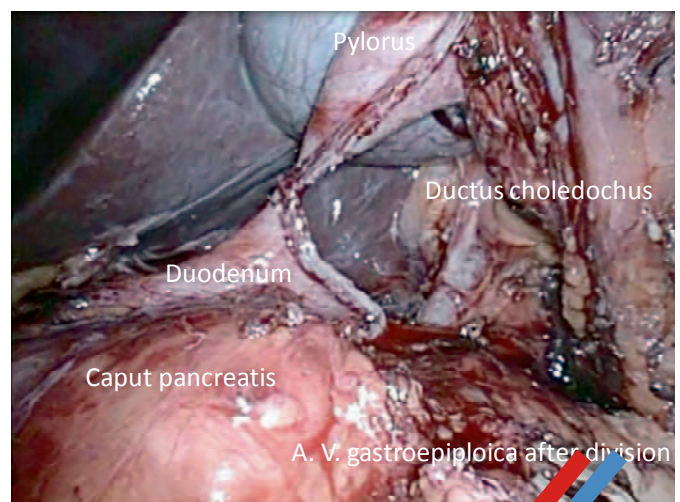


Fig. 6. Postpyloric division of the stomach.

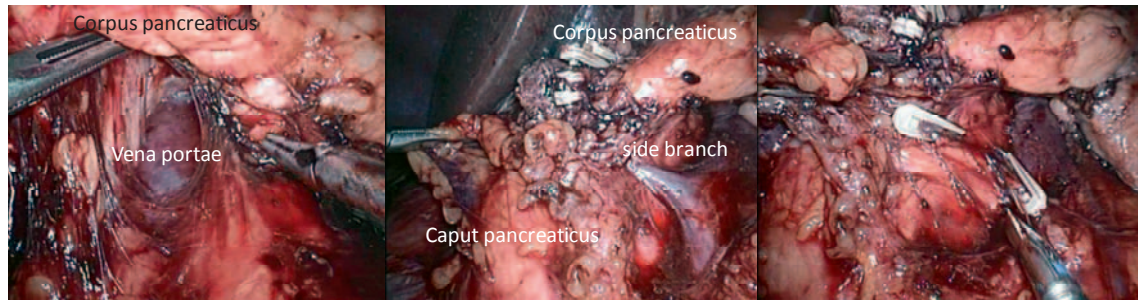


Fig. 7. Mobilization of the portal vein.

The mobilization of the first jejunal loop is carried out by first displacing the transverse colon superiorly. The already divided peritoneum of the duodenojejunal flexure during the Kocher maneuver is now completely incised. Typically, the first loop is divided 15–20 cm distal to the flexure using an Endo GIA. The mesentery of the proximal oral end is divided as close to the intestinal wall as possible, using an ultrasonic dissector to prevent a compromise in the blood supply of the aboral loop. An additional ligation of the gastric margin vessels with clips is not necessary. The oral loop is then shifted to the right by dividing the peritoneum. The retraction of the transverse colon to the lower abdomen completes the circular mobilization of the pancreatic head.

The actual dissection of the pancreatic head begins with the division of the gastroduodenal artery, which was already exposed during the preparation of the hepatoduodenal ligament. The artery is ligated with two 12 mm Lapro Clips proximally and one 12 mm Lapro Clip distally. The common bile duct, which is found in the caudal direction, is temporarily closed with a Lapro Clip 12 mm and dissected. Further on, the also already exposed portal vein is mobilized in a circular fashion. The previous mobilization of the pancreatic corpus and tail allows its displacement to a ventrolateral direction and therefore facilitates this step significantly. Starting from the lower margin of the pancreas, perforating branches are exposed by bipolar scissors and grasping forceps. These very flat and short venous branches require subtle preparation and permit no other instruments than mentioned above. Because of a tiny plane between the pancreas and the veins the preparation can be done by carefully spreading the scissors. Electrocoagulation should be avoided. All branches are ligated in central and peripheral direction with a Lapro Clip 12 mm and a Titan Clip 5 mm (fig. 7). The application of clips of different length provides additional safety in broad discharging veins.

The further preparation of the uncinate process is performed in a caudo-cranial direction. This requires a sufficient mobilization of the pancreatic head during the Kocher maneuver. Here, the ultrasonic dissector can be used. In order to avoid a lesion of the root of mesentery, preceding ultrasonic identification is recommended. Furthermore, a lesion or impairment of the autonomic plexus near the superior mesenteric artery can thus be avoided (fig. 8).

In our approach, the traction applied on the gallbladder and the retraction of the liver are maintained until the completion of this step. After a typical ante-grade mobilization of the gallbladder, the common bile duct is divided close to its junction with the cystic duct.

Removal of the Resected Segment and Reconstruction through Small Median Laparotomy

After the completion of the preparatory phase, the specimen is then removed through a small, 7-cm upper abdominal median laparotomy. This is followed by a reconstruction with the already prepared free loop. The choledocho- and gastrojejunostoma is then carried out in an end-to-side anastomosis. An Easy-Flow drainage is then placed in the former pancreatic bed.

Results

The total operative time was 391 min. Blood loss accounted for 250 ml. The postoperative course was uneventful. Histology revealed the following findings: three diffusely distributed glucagon- and polypeptide-producing NET (G1), 1.5 cm in size with infiltration of the surrounding peripancreatic fat and soft tissue,

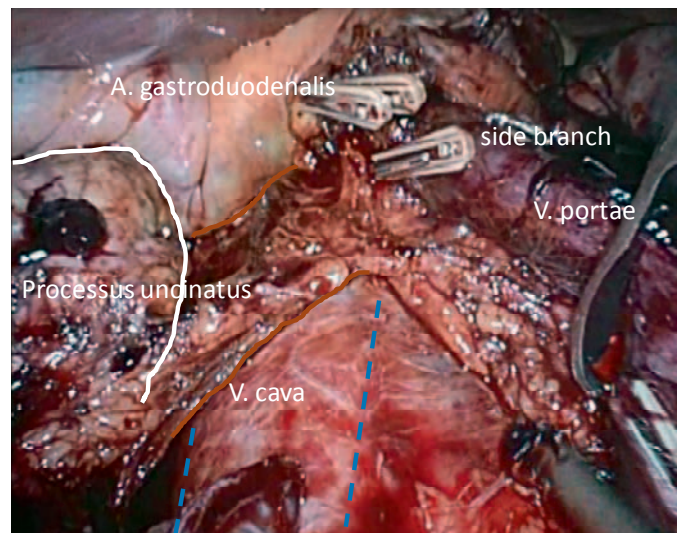


Fig. 8. Caudo-cranial dissection of the uncinate process.

in different areas of the pancreas, extending up to the edge of the pancreas with formation of a connective tissue pseudocapsule (fig. 9). A lymph node metastasis of a NET, G2, measuring 2–2.5 cm, gastrin-producing and without any evidence of an extranodal carcinoma, was recovered on the upper margin of the head of the pancreas.

A postoperative laboratory parameter control on the sixth postoperative day showed the following findings: chromogranin A 107 µg/l and gastrin 54 ng/l. The postoperative exo- and endocrine pancreatic insufficiency was treated with the administration of Pangrol 20,000 2-2-2 and Protaphane 6-0-6 IE as well as with a short-acting insulin depending on the requirement (target value 120 mg/dl). The postoperative diet advancement was rapid. The glycemic control was also uneventful. The patient was discharged on the eighth postoperative day.

Discussion

In contrast to other methods, such as the open low anterior resection of the rectum, there is a significant discrepancy between the size of the surgical wound and the surgical specimen that is removed during the operation [8, 9]. Hence, laparoscopic pancreatic surgery could lead to a reduced intraoperative dysregulation of catecholamines or a reduced compromise of the immune system. In addition, possible complications seen in open procedures, such as adhesions or incisional hernias in the long term, could be reduced [10]. The complexity of the anatomy and thus the necessary exper-

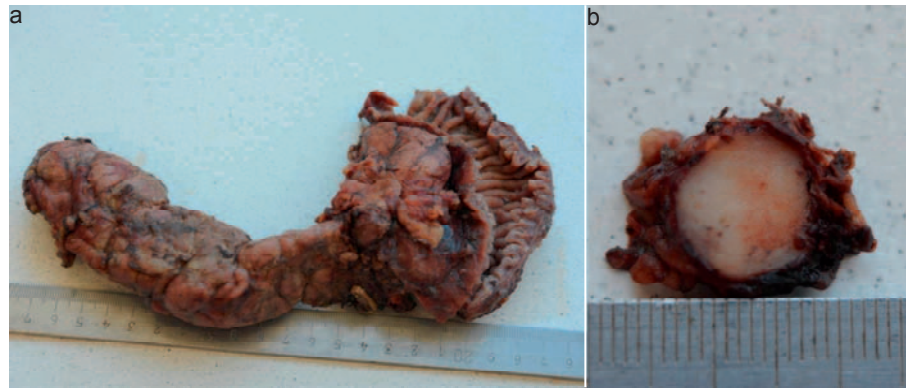


Fig. 9. **a** Operation specimen and **b** sagittal cut of an intrapancreatic NET fixed in formalin.

tise of the surgical team have resulted in a prolonged learning curve and a limited appeal of pancreatic laparoscopic surgery. However, the increasing number of publications on the subject shows the feasibility of laparoscopic resection of the pancreas [11]. The development of laparoscopic pancreatic surgery is a perfect example of the increasing complexity of laparoscopic procedures. As with other operations, the primary aim of laparoscopic surgery was to clarify the operability and the determination of tumor stage [12]. The improvement of the technical equipment and the increasing sophistication of the operators allow the progressive development of such extensive procedures.

The technical requirements include laparoscopic ultrasonography with duplex sonography, tissue dissection by using ultrasound or thermocauterization, and visualization in HD quality. Laparoscopic ultrasound allows the localization and planning of resection, thus displaying small structures such as the blood supply in the region of the tail of the pancreas, and thereby ensures a secure blood supply [13]. As with other major laparoscopic procedures, no special instruments or equipment are required to carry out the technique of LDP described above.

The increasing expertise of the operators is reflected in both the quantity and the quality of resective procedures in pancreatic surgery. Enucleations and left pancreatic resections are now part of the standard laparoscopic procedure [14], even though spleen-preserving left pancreatic resection through the venous branches of the splenic artery from the tail of the pancreas is a considerable challenge [15]. Since the beginning of the last decade, surgery of the pancreatic head is increasingly being performed laparoscopically. However, a standardized procedure has not yet been established [16, 17].

Total pancreaticoduodenectomy is a combination of resection of the head and body of the pancreas as well as of the tail of the pancreas. Gagner and Pomp [18] first published a laparoscopic pylorus-preserving pancreaticoduodenectomy in 1994. However, only sporadic reports on laparoscopic total pancreaticoduodenectomy were published by a few centers [18]. In a review by Gumbs et al. [19] from 2011, a total of 285 cases of laparoscopic pancreatectomy were reported. This shows that the laparoscopic technique is increasingly being favored for this procedure as well. The rare indications for total pancreatectomy may possibly be mentioned as

limiting factors. As in the presented case, the indications are mainly NETs or intraductal papillary mucinous neoplasms [20, 21]. The complete loss of endocrine and exocrine function of the pancreas means that the indication has to be carefully made. The preoperative localization of multilocular NETs in the pancreas, the required tumor safety margin of 2–3 cm, and the MEN 1 in the duodenum with multiple small gastrinomas were deciding factors for the indication for a total duodenopancreatectomy. Histological examination with evidence of multilocular NETs in the pancreas and duodenum as well as the corresponding lymph node metastasis confirmed this.

The rare indication for such a procedure results in a lack of a specific learning curve for a possible laparoscopic procedure. Thus, training in this procedure can only be indirectly achieved by means of experience in laparoscopic surgery and particularly experience in the resection of the head and tail of the pancreas.

In contrast to subtotal pancreatectomies, due to the rare indication, there are no randomized controlled trials comparing the advantages and disadvantages of the open and laparoscopic approach of LDP. Possible benefits of the laparoscopic procedure could only be indirectly deducted from studies concerning subtotal pancreatectomies. The meta-analysis by Venkat et al. [21] comparing laparoscopic versus open left pancreatectomy showed a shortened hospital stay and a reduced morbidity in case of laparoscopic total duodenopancreatectomy. Kim et al. [22] as well as Asbun and Stauffer [23] were able to confirm this. The blood loss at <250 ml was also minimal. In particular, the injury to the small branches of the splenic vein and the portal vein can lead to significant blood loss and require a conversion [24, 25]. The preservation of the metabolic and immunological function of the spleen appears to be favorable. Moreover, splenectomy is associated with a higher number of postoperative complications such as overwhelming post-splenectomy infection (OPSI) syndrome, abscess, or portal hypertension [26, 27]. We do not believe that the segmental resection of the vessels, as described by Warshaw [27], is a favored method. Complications such as bleeding and infarction of the spleen are the known complications of this approach [28]. The careful dissection of the vessels is associated with a further extension of the operation time. Dallemagne et al. [28] reported a mean operative time of 500 min. The extension of the operation time by this group can best be

explained by the laparoscopic reconstruction which was carried out. In the majority of the reported cases, the reconstructions were carried out in the hybrid method, which included an open choledocho- or pylorojejunostomy [29, 30].

The shortened hospital stay and the fewer long-term complications versus longer operative time and higher equipment costs when compared with the open procedure will remain a controversial aspect in future discussions.

Conclusion

In selected cases, laparoscopic pylorus- and spleen-preserving total duodenectomy is a minimally invasive therapeutic option.

The flat learning curve of the procedure, however, precludes a higher level of expertise for the surgery. The advantages associated with a laparoscopic procedure are in favor of this procedure. The rare indication for this procedure will probably be the reason for not being standardized in the near future.

Disclosure Statement

E. Schlörcke, M. Hoffmann, P. Kujath, G.M. Shetty, F. Scheer, M.O. Liedke, and M. Zimmermann hereby declare that they have no conflicts of interest to disclose.

References

- 1 Ito M, Horiguchi A, Asano Y, et al: Spleen-preserving distal pancreatectomy performed laparoscopically. *Hepatogastroenterology* 2010;57:162–164.
- 2 Buchs NC, Addeo P, Bianco FM, et al: Robotic versus open pancreaticoduodenectomy: a comparative study at a single institution. *World J Surg* 2011;35:2739–2746.
- 3 Schlörcke E, Nolde J, Hoffmann M, et al: Laparoscopic spleen-preserving distal pancreatectomy. *Langenbecks Arch Surg* 2011;396:1119–1123.
- 4 Zeh HJ, Zureikat AH, Secrest A, et al: Outcomes after robot-assisted pancreaticoduodenectomy for periampullary lesions. *Ann Surg Oncol* 2012;19:864–870.
- 5 Tanaka M, Chari S, Adsay V, et al: International consensus guidelines for management of intraductal papillary mucinous neoplasms and mucinous cystic neoplasms of the pancreas. *Pancreatology* 2006;6:17–32.
- 6 Kendrick ML, Cusati D: Total laparoscopic pancreaticoduodenectomy: feasibility and outcome in an early experience. *Arch Surg* 2010;145:19–23.
- 7 Casadei R, Marchegiani G, Laterza M, et al: Total pancreatectomy: doing it with a mini-invasive approach. *JOP* 2009;10:328–331.
- 8 Giulianotti PC, Addeo P, Buchs NC, et al: Early experience with robotic total pancreatectomy. *Pancreas* 2011;40:311–313.
- 9 Schlörcke E, Bader FG, Hoffmann M, et al: Offen chirurgische versus laparoskopische Versorgung der iatrogenen Kolonperforation – Ergebnisse nach 13 Jahren Erfahrungen. *Zentralbl Chir* 2013;138:257–261.
- 10 Mabrut J, Fernandez-Cruz L, Azagra JS, et al: Laparoscopic pancreatic resection: results of a multicenter European study of 127 patients. *Surgery* 2005;137:597–605.
- 11 Marangos IP, Buanes T, Røsok BI, et al: Laparoscopic resection of exocrine carcinoma in central and distal pancreas results in a high rate of radical resections and long postoperative survival. *Surgery* 2012;151:717–723.
- 12 Keck T, Küsters S, Wellner UF, et al: Total laparoscopic partial pancreatoduodenectomy and reconstruction via laparoscopic pancreatogastrostomy. *Langenbecks Arch Surg* 2012;397:1009–1012.
- 13 Palanivelu C, Jani K, Sendhilkumar K, et al: Laparoscopic restorative total proctocolectomy with ileal pouch anal anastomosis for familial adenomatous polyposis. *JLS* 2008;12:256–261.
- 14 Pryor A, Means JR, Pappas TN: Laparoscopic distal pancreatectomy with splenic preservation. *Surg Endosc* 2007;21:2326–2330.
- 15 Weber SM, Cho CS, Merchant N, et al: Laparoscopic left pancreatectomy: complication risk score correlates with morbidity and risk for pancreatic fistula. *Ann Surg Oncol* 2009;16:2825–2833.
- 16 Kooby DA, Gillespie T, Bentrem D, et al: Left-sided pancreatectomy: a multicenter comparison of laparoscopic and open approaches. *Ann Surg* 2008;248:438–446.
- 17 Keck T, Wellner U, Küsters S, et al: Laparoskopische Pankreaskopfresektion. Machbarkeit und perioperative Ergebnisse. *Chirurg* 2011;82:691–697.
- 18 Gagner M, Pomp A: Laparoscopic pylorus-preserving pancreaticoduodenectomy. *Surg Endosc* 1994;8:408–410.
- 19 Gumbs AA, Rodriguez Rivera, Angel M, et al: Laparoscopic pancreaticoduodenectomy: a review of 285 published cases. *Ann Surg Oncol* 2011;18:1335–1341.
- 20 Libutti SK, Choyke PL, Bartlett DL, et al: Pancreatic neuroendocrine tumors associated with von Hippel Lindau disease: diagnostic and management recommendations. *Surgery* 1998;124:1153–1159.
- 21 Venkat R, Edil BH, Schulick RD, et al: Laparoscopic distal pancreatectomy is associated with significantly less overall morbidity compared to the open technique: a systematic review and meta-analysis. *Ann Surg* 2012;255:1048–1059.
- 22 Kim SC, Song KB, Jung YS, et al: Short-term clinical outcomes for 100 consecutive cases of laparoscopic pylorus-preserving pancreaticoduodenectomy: improvement with surgical experience. *Surg Endosc* 2013;27:95–103.
- 23 Asbun HJ, Stauffer JA: Laparoscopic vs open pancreaticoduodenectomy: overall outcomes and severity of complications using the Accordion Severity Grading System. *J Am Coll Surg* 2012;215:810–819.
- 24 Vijan SS, Ahmed KA, Harmsen WS, et al: Laparoscopic vs open distal pancreatectomy: a single-institution comparative study. *Arch Surg* 2010;145:616–621.
- 25 Davidson RN, Wall RA: Prevention and management of infections in patients without a spleen. *Clin Microbiol Infect* 2001;7:657–660.
- 26 Miura F, Takada T, Asano T, et al: Hemodynamic changes of splenogastric circulation after spleen-preserving pancreatectomy with excision of splenic artery and vein. *Surgery* 2005;138:518–522.
- 27 Warshaw AL: Conservation of the spleen with distal pancreatectomy. *Arch Surg* 1988;123:550–553.
- 28 Dallemagne B, de Oliveira, Antonio Talvane Torres, et al: Full laparoscopic total pancreatectomy with and without spleen and pylorus preservation: a feasibility report. *J Hepatobiliary Pancreat Sci* 2013;20:647–653.
- 29 Choi SH, Hwang HK, Kang CM, et al: Pylorus- and spleen-preserving total pancreaticoduodenectomy with resection of both whole splenic vessels: feasibility and laparoscopic application to intraductal papillary mucin-producing tumors of the pancreas. *Surg Endosc* 2012;26:2072–2077.
- 30 Kim DH, Kang CM, Lee WJ: Laparoscopic-assisted spleen-preserving and pylorus-preserving total pancreatectomy for main duct type intraductal papillary mucinous tumors of the pancreas: a case report. *Surg Laparosc Endosc Percutan Tech* 2011;21:e179–182.