

# Keyhole approach in the neuroendoscopic treatment for hydrocephalus

Qiang Cai, MD, PhD\*, Xiangyang Zhang, Long Wang, Shulan Huang, Zhibiao Chen\*, Qianxue Chen\*

## Abstract

The aim of the study was to explore keyhole approach and dura suture in the neuroendoscopic treatment for hydrocephalus.

Twelve cases of hydrocephalus patients who were treated with neuroendoscope by this approach were analyzed retrospectively from April 2015 to April 2016 in our department. The basic steps of this procedure was using drill and milling cutter to form a small bone flap instead of burr hole, and then making a cruciate incision on the dura. After endoscopic third ventriculostomy or endoscopic third ventriculostomy + ventriculocystostomy finished, dura was sutured and the bone flap was reset.

All 12 patients could suture dura effectively, and no cerebrospinal fluid leak and subcutaneous cerebrospinal fluid collection happened; symptoms of hydrocephalus were also improved. Moreover, during the operation, we found this approach could suspend dura, and avoid the cerebral sulcus and cortical coarse vein effectively, which could reduce the risk of intracranial hemorrhage. In addition, we found this approach could increase the reachable range of the neuroendoscope significantly.

Keyhole approach can suture dura and avoid the cerebral sulcus and cortical coarse vein effectively, increase the indications, and reduce complications of neuroendoscope. So, this approach has clinical values and can be used in hydrocephalus.

**Abbreviations:** CSF = cerebrospinal fluid, ETV = endoscopic third ventriculostomy, MRI = magnetic resonance imaging, QCACs = quadrigeminal cistern arachnoid cysts, VC = ventriculocystostomy.

**Keywords:** hydrocephalus, keyhole approach, neuroendoscope

## 1. Introduction

Neuroendoscope was an important tool for the treatment of hydrocephalus, and endoscopic third ventriculostomy (ETV) was the primary method for obstructive hydrocephalus at present.<sup>[1,2]</sup> With the wide application of neuroendoscope, complications also gradually increased.<sup>[3,4]</sup> Cerebrospinal fluid (CSF) leak and subcutaneous CSF collection were one of the most common complications of ETV. Although these may not lead to intracranial infection directly, most of the researchers believe these were the risk

factors which led to intracranial infection.<sup>[4]</sup> Now, during the procedure of ETV, the dura was cut and coagulated to introduce the neuroendoscope into the lateral ventricle after burr hole was made on the skull. This made dura suture difficult, which may lead to CSF leak and subcutaneous CSF collection. To overcome CSF leak and subcutaneous CSF collection, we improved the surgical approach by keyhole approach instead of burr hole, which made dura suture possible. At the same time, we found that this approach had other advantages in the subsequent cases, which are reported as follows.

## 2. Materials and methods

### 2.1. Clinical-radiological features

Between April 2015 and April 2016, 12 patients (8 male, 4 female) affected by hydrocephalus were endoscopically treated by keyhole approach. Patient age ranged from 1 to 65 years. Preoperative magnetic resonance imaging (MRI) showed that the categories of hydrocephalus consisted of aqueduct stenosis in 4 cases, intraventricular cyst in 3 cases, quadrigeminal cistern arachnoid cyst in 2 cases, aqueduct cyst in 1 case, Chiari malformation in 1 case, shunt failure and intracranial infection after brain trauma in 1 case.

### 2.2. Surgical approaches and methods

We used keyhole approach for these patients and compared with the traditional burr hole approach. Also, all procedures were approved by ethics committee of Renmin Hospital of Wuhan University.

### 2.3. Burr hole approach

Patients were positioned supine and the head was minimally elevated. The burr hole around 1.5 cm was made just anterior to

Editor: Kenneth Casey.

Dr Xiangyang Zhang and Dr Long Wang are the co-first authors.

Funding: This work was supported by Nature Science Foundation of Hubei Province of China (2015CFB182), Hubei Province Health and Family Planning Scientific Research Project (WJ2015MB092), National Natural Science Foundation of China (81671306), Wuhan Science and Technology plan project (2016060101010067), and the Foundation of China Scholarship Council.

The authors report no conflicts of interest.

Department of Neurosurgery, Renmin Hospital of Wuhan University, Hubei Province, China.

\* Correspondence: Dr Qiang Cai, No. 238, Jiefang Road, Wuchang District, Wuhan City, Hubei Province 430060, China (e-mail: cqno@sina.com); Zhibiao Chen, No. 238, Jiefang Road, Wuchang District, Wuhan City, Hubei Province 430060, China (e-mail: zhibiaochen@sina.com); Qianxue Chen, No. 238, Jiefang Road, Wuchang District, Wuhan City, Hubei Province 430060, China (e-mail: qianxuechen@sina.com).

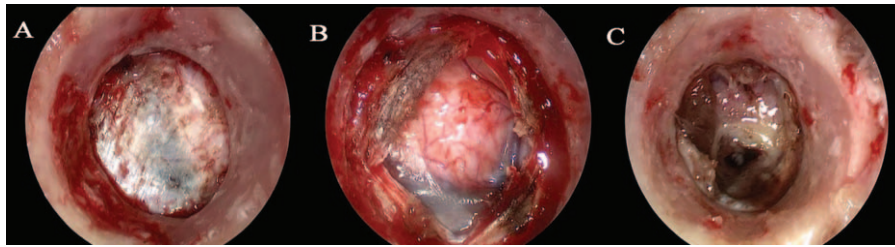
Copyright © 2017 the Author(s). Published by Wolters Kluwer Health, Inc. This is an open access article distributed under the Creative Commons Attribution-NoDerivatives License 4.0, which allows for redistribution, commercial and non-commercial, as long as it is passed along unchanged and in whole, with credit to the author.

Medicine (2017) 96:1(e5823)

Received: 19 October 2016 / Received in final form: 6 December 2016 /

Accepted: 10 December 2016

<http://dx.doi.org/10.1097/MD.0000000000005823>



**Figure 1.** The traditional operation approach need burr hole on skull, cut and coagulate dura. So, the dura cannot suture. A, After a burr hole was made, the dura matter emerged. B, The dura matter needed to cut and coagulate to make the neuroendoscope introduce into lateral ventricle. C, The dura matter cannot be sutured.

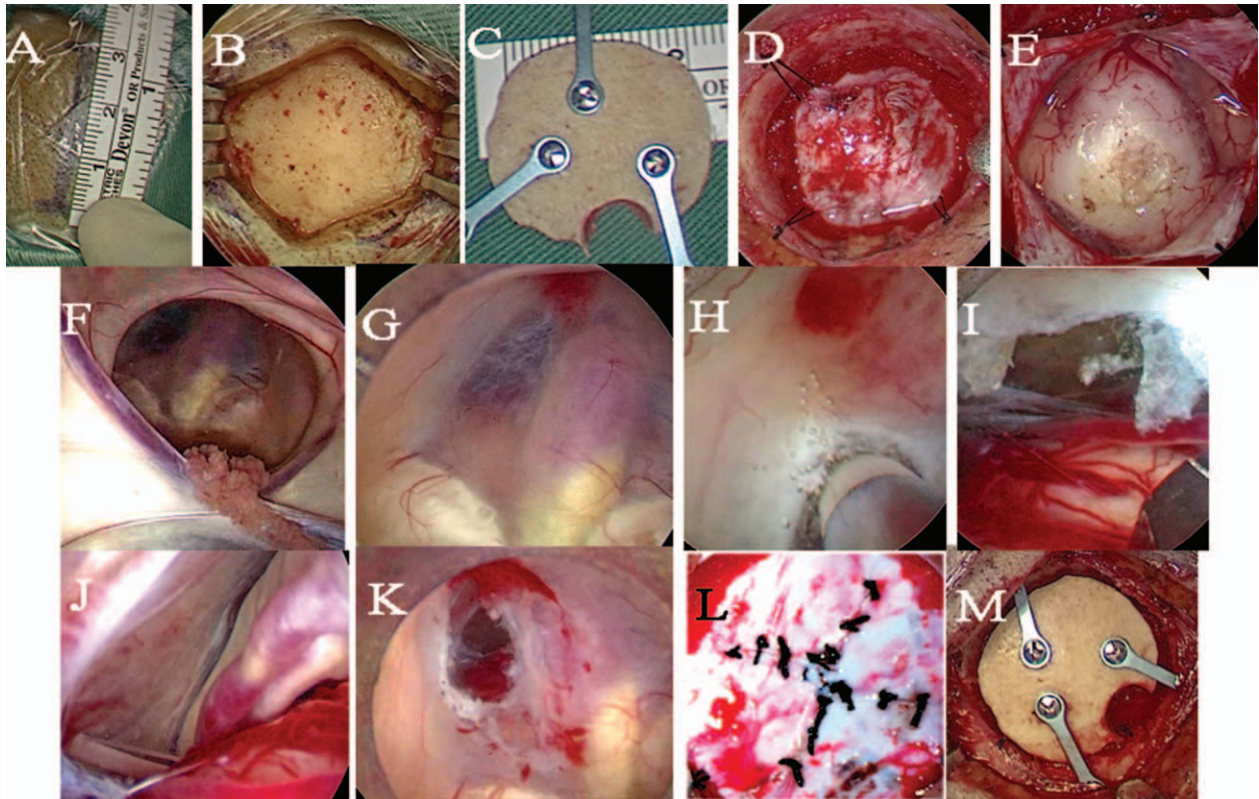
the coronal suture in the mid-pupillary line. Then dura was cut and coagulated to make the neuroendoscope introduce into lateral ventricle. After ETV was completed, the gel-form was inserted into the tract of neuroendoscope and then the scalp was closed (Fig. 1).

#### 2.4. Keyhole approach

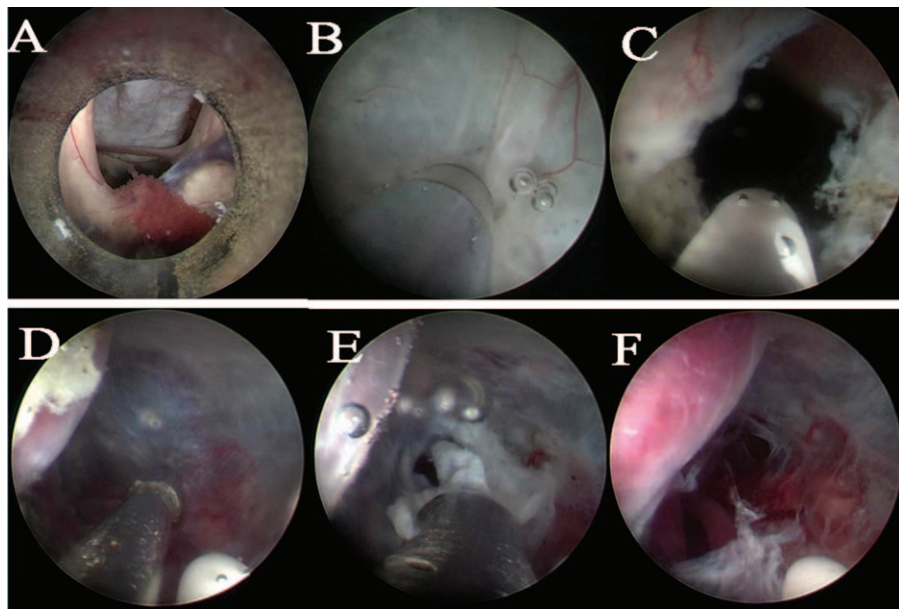
A straight or curvilinear scalp incision was made encompassing the burr-hole location. Then, a bone flap was created about 2 cm in diameter instead of burr hole. The dura was suspended and then a dural cruciate incision without the use of electrocautery was made to facilitate a watertight dural closure. Avoiding

sulcus, gyrus was coagulated and cut, and then the neuroendoscope was introduced into the lateral ventricles. After completion of the ETV, the dura was closed carefully by sutures. The bone flap was reset and fixed, and then the scalp was closed (Fig. 2).

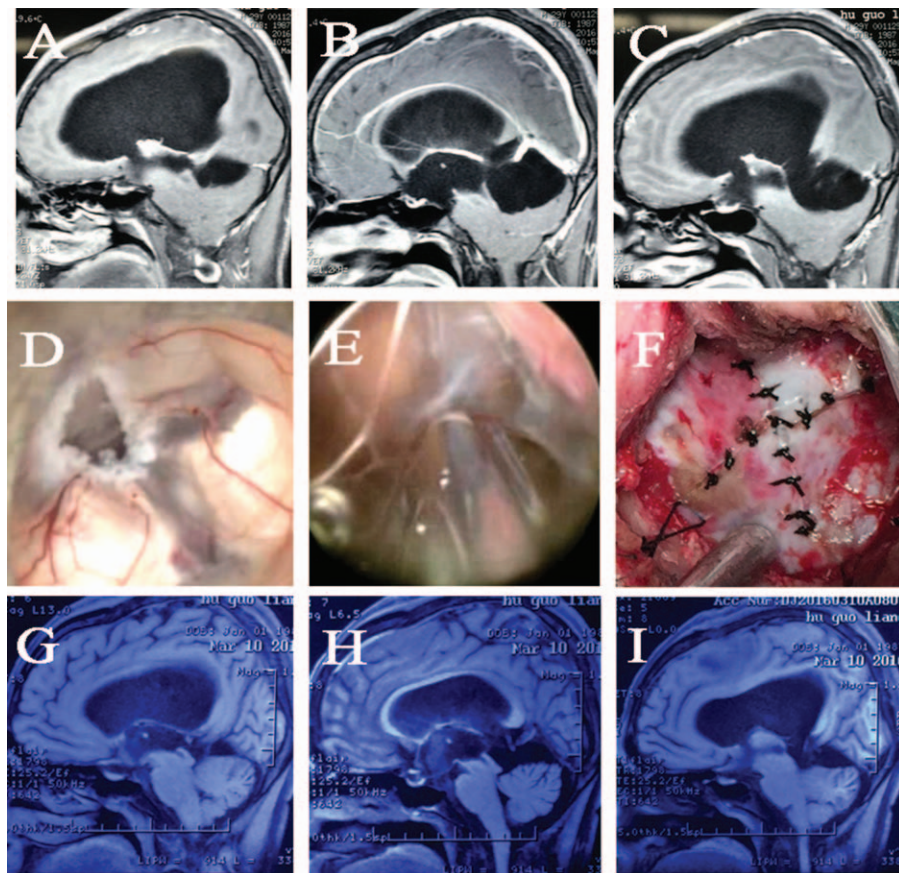
For hydrocephalus by aqueduct stenosis or intracranial infection, we performed ETV only; for third ventricle cyst, we performed ventriculocystostomy (VC) + ETV (Fig. 3); for quadrigeminal cistern arachnoid cyst, we performed ETV first, and then VC was done (Fig. 4). For adults, we choose mini titanium plate system to fix bone flap, whereas for children, absorbable cranial fixation system was used (Fig. 5).



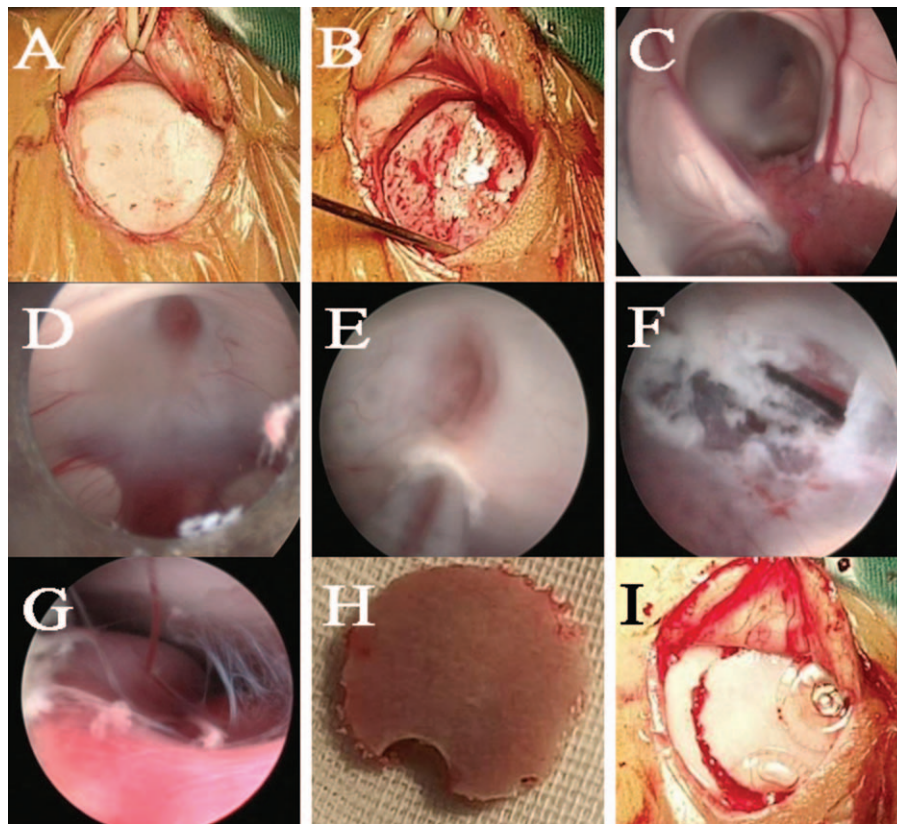
**Figure 2.** The basic steps of keyhole approaches in the neuroendoscopic treatment for hydrocephalus. (A) A 3 to 4 cm long straight longitudinal skin incision; (B) mastoid retractor distract scalp; (C) bone flap around 2 cm created; (D) suspend dura; (E) dural cruciate incision was made and gyrus coagulated; (F) the enlarged interventricular foramen as the landmark of anatomical structure in lateral ventricle; (G) the floor of third ventricle; (H) fenestration on the floor of third ventricle, avoid the basilar artery; (I) further open the Lilliequist membrane; (J) endoscope enter into prepontine cistern and basilar artery, superior cerebellar artery, brainstem, and abducent nerves were observed; (K) the observation of third ventricle floor after ETV; (L) dura closed by sutures after ETV; (M) the bone flap was reset and fixed. ETV=endoscopic third ventriculostomy.



**Figure 3.** Operation view of cyst in third ventricle. (A) Endoscopic view of enlarged interventricular foramen and the cyst was founded in the anterior part of third ventricle; (B) ventriculocystostomy performed at first; (C) endoscopic view after ventriculocystostomy; (D) observation of the structures of the third ventricle; (E) endoscopic third ventriculostomy; (F) Lilliequist membrane opened and prepontine cistern structures were observed.



**Figure 4.** Data of quadrigeminal cistern arachnoid cysts accompanied obstructive hydrocephalus around operation. (A) Preoperative sagittal MRI show hydrocephalus significantly by ventricular enlargement, sulcus disappeared, gyrus narrowed; (B) midline sagittal MRI shows cyst located in the quadrigeminal cistern area and aqueduct compressed obviously; (C) preoperative sagittal MRI show that cerebellum was compressed and stretched into foramen magnum, which hint high press in the posterior fossa; (D) endoscopic third ventriculostomy; (E) transventricular ventriculocystostomy; (F) dura closed by sutures; (G) postoperative sagittal MRI shows hydrocephalus improved significantly; (H) postoperative sagittal MRI shows cysts shrinked obviously; (I) postoperative sagittal MRI shows that the compression of cerebellum and the high press of posterior fossa improved obviously.



**Figure 5.** Keyhole approach treatment for hydrocephalus in children. (A) A curvilinear scalp incision was made instead of straight incision; (B) bone flap created; (C) intraoperative endoscopic view of lateral ventricles; (D) structures of the third ventricle floor; (E) endoscopic third ventriculostomy; (F) Lilliequist membrane; (G) endoscopic view and structures of prepontine cistern; (H) size and shape of bone flap; (I) absorbable cranial fixation system was used to fix bone flap.

### 3. Results

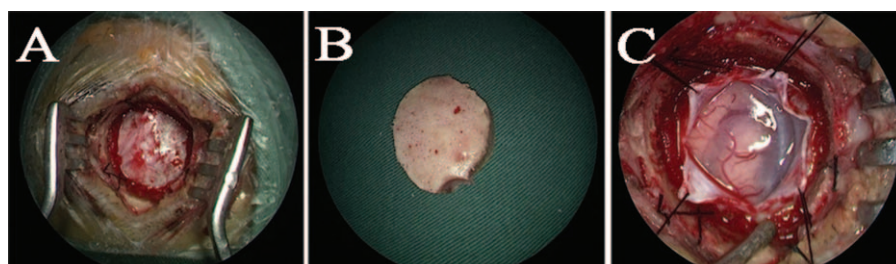
All the neuroendoscopic procedures were completed uneventfully, the dura closed effectively in all cases, and no CSF leak and subcutaneous CSF collection happened. At the same time, we found this surgical approach could suspend dura, and avoid the cerebral sulcus and cortical coarse vein effectively, which could reduce the risk of intracranial hemorrhage (Fig. 6). In addition, we found this approach could increase the reachable range of the neuroendoscope significantly. In the treatment of the quadrigeminal arachnoid cyst, we introduced the neuroendoscope to the third ventricle and finished the ETV first, then the neuroendoscope returned to the lateral ventricle, with adjustment of the neuroendoscope in the lateral ventricles, and then we completed VC. We use the softness and elasticity of the brain in this

procedure, and no more large hole is created in the brain. So, this approach could help in completing ETV and VC at one time, and no other incision or burr hole is needed (Fig. 4).

The symptoms in all patients were improved, and the ventricular system and cyst shrunk significantly, and the exudation around ventricular system also reduced obviously in postoperation MRI (Fig. 4).

### 4. Discussion

With the advent of improved optics and endoscope technology, neuroendoscopes have become the cornerstone of minimally invasive neurosurgery, employed in a number of various procedures such as hydrocephalus. Considering the advantage of excellent visualization and illumination, neuroendoscopes



**Figure 6.** Keyhole approach could reduce the risk of intracranial hemorrhage. (A) Dura suspended; (B) bone flap; (C) avoid the cerebral sulcus and cortical coarse vein to reduce the risk of intracranial hemorrhage.

allow neurosurgeons to navigate around structures, especially in CSF-filled ventricular system, which made ETV gradually the primary treatment for obstructive hydrocephalus.<sup>[1,2]</sup> Meanwhile, as experience grows, various studies suggested that complications of ETV increasingly reported and affected the prognosis of patients.<sup>[3,4]</sup> The complications of the ETV was about 2% to 15%,<sup>[5]</sup> which included CSF leakage, intracranial infection, intracranial hemorrhage, subdural effusion, postoperative fever, subcutaneous effusion, and so on. CSF leak was one of the most common complications with incidence of about 2.2%, and accounted for 27.5% of all the complications in ETV.<sup>[3]</sup>

The CSF leak could increase the risk of intracranial infection.<sup>[6,7]</sup> Cinalli et al<sup>[6]</sup> reported 9 cases which encountered CSF leak in a group of 231 patients, of which 4 (44%) cases developed intracranial infection. This was significant considering the fact that the overall infection rate was 4.7%.

For the traditional burr hole approach cannot suture dura, many alternative methods came into being to reduce the occurrence of CSF leak. Teo et al<sup>[8]</sup> suggested using the thinnest endoscope to fistula, plugging of the cortical tract by gel foam, and upright postoperative positioning to reduce leakage. Mohanty reported a method to reduce CSF leak in which the galea and pericranium flap reflected in a single layer after the scalp incision, and then were closed in a watertight fashion after the procedure.<sup>[9]</sup> Delayed suture removal, repeated lumbar puncture, or ventricular tap in some cases could help prevent a leak.<sup>[10]</sup> The most ideal way of preventing the CSF leak was dura watertight closure using continuous sutures, which was used by Cinalli et al,<sup>[11]</sup> but it usually required a significant bone removal and may be difficult in children with paper-thin dura. While, we used keyhole approach which could close the dura in watertight and replace the bone flap also at the same time.

Intracranial hematoma was another severe complication of ETV which may lead to procedure failure or even cause the death of patients. To avoid the occurrence of intracranial hematoma, fine operation was essential; in addition, we also needed to pay attention to some details. First, the endoscopic introduce point should try to avoid cerebral sulcus which the blood vessel inside in, and the choice from the gyrus was much safe. Second, we needed to far away some cortical coarse vein which maybe happened in some case. The neuroendoscopy tract was too close to this vein, which may also increase the hemorrhage rate. Third, to reduce the epidural hematoma, dura suspension was usually needed. However, in traditional burr hole approach, for the small operation field, it was very difficult to suspend dura and away from the coarse vein. We changed the burr hole into small bone flap, which enlarged the operation space and avoided sulcus and coarse vein effectively. Meanwhile, this approach made us suspend dura easily and reduce incidence of epidural hematoma (Fig. 6).

Arachnoid cysts account for about 1% of intracranial lesions, and quadrigeminal cistern arachnoid cysts (QCACs) were comprising 5% to 10% of all intracranial arachnoid.<sup>[12]</sup> QCACs were usually asymptomatic, but for their intimate relationship with the dorsal midbrain, they were almost invariably associated with hydrocephalus when symptomatic. At present, ventriculo-peritoneal or cystoperitoneal shunting, microscopic craniotomy for cyst excision, and endoscopic fenestration are 3 main types of surgical methods for QCACs.<sup>[13]</sup> For hydrocephalus patients, the ventricular system was large enough for surgeons to perform a

'transventricular ventriculocystostomy' and a third ventriculostomy or cystcisternostomy at the same time. So, cysts originating in the quadrigeminal plate cistern were usually suitable for endoscopic treatment. And highly encouraging results had been more and more frequently reported in the literature.<sup>[13,14]</sup> At the same time, some authors advice that VC should be performed together with ETV for the following 2 reasons: chronic midbrain compression by the QCACs may lead to secondary aqueductal occlusion; ETV was more safer and easier than fenestration of the deep cyst wall. Moreover, they also suggested that ETV should firstly be performed because it was more dangerous for VC than ETV in the third ventricle.<sup>[13]</sup>

The choice of endoscopic approaches and trajectories was made on the basis of the types of QCACs and preoperative MRI scans.<sup>[12-14]</sup> For the restriction of burr hole, the reachable scope of neuroendoscope was limited, and it was difficult to perform VC as ETV by the same approach in some cases.<sup>[14]</sup> While, for our keyhole approach, the restriction for neuroendoscope was removed and the activity of neuroendoscope was greatly improved, which made the VC and ETV performed in the same approach (Fig. 4).

In summary, keyhole approach has the advantage of suture dura, far away cortical coarse vein, and avoid sulcus effectively, which can reduce the occurrence of CSF leak and intracranial hematoma. Meanwhile, this approach made neuroendoscope move more freely, which increased the indication of operation. So, we believe this approach has the characteristics of safety and effectiveness, and has value for clinical application.

## References

- [1] Obaid S, Weil AG, Rahme R, et al. Endoscopic third ventriculostomy for obstructive hydrocephalus due to intraventricular hemorrhage. *J Neurol Surg A* 2015;76:99-111.
- [2] Choudhri O, Feroze AH, Nathan J, et al. Ventricular endoscopy in the pediatric population: review of indications. *Child Nervous Syst* 2014;30:1625-43.
- [3] Peretta P, Ragazzi P, Galarza M, et al. Complications and pitfalls of neuroendoscopic surgery in children. *J Neurosurg* 2006;105(3 suppl): 187-93.
- [4] Bouras T, Sgouros S. Complications of endoscopic third ventriculostomy. *J Neurosurg Pediatr* 2011;7:643-9.
- [5] Yadav YR, Parihar V, Pande S, et al. Endoscopic third ventriculostomy. *J Neurosci Rural Pract* 2012;3:163-73.
- [6] Cinalli G, Spennato P, Ruggiero C, et al. Complications following endoscopic intracranial procedures in children. *Child Nervous Syst* 2007;23:633-44.
- [7] Navarro R, Gil-Parra R, Reitman AJ, et al. Endoscopic third ventriculostomy in children: early and late complications and their avoidance. *Child Nervous Syst* 2006;22:506-13.
- [8] Teo C, Rahman S, Boop FA, et al. Complications of endoscopic neurosurgery. *Child Nervous Syst* 1996;12:248-53.
- [9] Mohanty A, Suman R. Role of galeal-pericranial flap in reducing postoperative CSF leak in patients with intracranial endoscopic procedures. *Child Nervous Syst* 2008;24:961-4.
- [10] Yadav YR, Parihar VS, Ratre S, et al. Avoiding complications in endoscopic third ventriculostomy. *J Neurol Surg A* 2015;76:483-94.
- [11] Cinalli G, Spennato P, Ruggiero C, et al. Aqueductal stenosis 9 years after mumps meningoencephalitis: treatment by endoscopic third ventriculostomy. *Child Nervous Syst* 2004;20:61-4.
- [12] Yu L, Qi S, Peng Y, et al. Endoscopic approach for quadrigeminal cistern arachnoid cyst. *Br J Neurosurg* 2016;30:429-37.
- [13] Gui S, Bai J, Wang X, et al. Assessment of endoscopic treatment for quadrigeminal cistern arachnoid cysts: a 7-year experience with 28 cases. *Child Nervous Syst* 2016;32:647-54.
- [14] Cappabianca P, Cinalli G, Gangemi M, et al. Application of neuroendoscopy to intraventricular lesions. *Neurosurgery* 2008;62(suppl 2): 575-97.