

Comparison of 2 open-sourced 3-dimensional modeling techniques for orthopaedic application

Yuan Chai, PhD^a, Robert Simic, BM^a, Paul N. Smith, MD, FRACS^b, Krisztina Valter, MD, PhD^c, Ajay Limaye, PhD^d, Rachel W. Li, MD, PhD^{e,*}

Abstract

Objectives: Although 3-dimensional (3D) printing is becoming more widely adopted for clinical applications, it is yet to be accepted as part of standard practice. One of the key applications of this technology is orthopaedic surgical planning for urgent trauma cases. Anatomically accurate replicas of patients' fracture models can be produced to guide intervention. These high-quality models facilitate the design and printing of patient-specific implants and surgical devices. Therefore, a fast and accurate workflow will help orthopaedic surgeons to generate high-quality 3D printable models of complex fractures. Currently, there is a lack of access to an uncomplicated and inexpensive workflow.

Methods: Using patient DICOM data sets ($n = 13$), we devised a novel, simple, open-source, and rapid modeling process using Drishti software and compared its efficacy and data storage with the 3D Slicer image computing platform. We imported the computed tomography image directory acquired from patients into the software to isolate the model of bone surface from surrounding soft tissue using the minimum functions. One pelvic fracture case was further integrated into the customized implant design practice to demonstrate the compatibility of the 3D models generated from Drishti.

Results: The data sizes of the generated 3D models and the processing files that represent the original DICOM of Drishti are on average 27% and 12% smaller than that of 3D Slicer, respectively (both $P < 0.05$). The time frame needed to reach the stage of viewing the 3D bone model and the exporting of the data of Drishti is 39% and 38% faster than that of 3D Slicer, respectively (both $P < 0.05$). We also constructed a virtual model using third-party software to trial the implant design.

Conclusions: Drishti is more suitable for urgent trauma cases that require fast and efficient 3D bone reconstruction with less hardware requirement. 3D Slicer performs better at quantitative preoperative planning and multilayer segmentation. Both software platforms are compatible with third-party programs used to produce customized implants that could be useful for surgical training.

Level of Evidence: Level V.

Keywords: CT modeling, preoperative planning, open-sourced, 3D reconstruction

1. Introduction

Current orthopaedic preoperative surgical planning for traumatic fractures involves using computed tomography (CT) scans in conjunction with x-rays to assess complex fractures.^[1,2] Although 3-dimensional (3D) modeling is becoming more prevalent, virtual models fail to provide insight into the biomechanics of the bone fragments when realigned, especially with complex fractures. The reconstructive surgical procedures take long hours because of difficulties encountered in fracture reduction. Extended tourniquet

times increase the risk of tissue perfusion injury, whereas lengthy surgical times increase the risk of infection.^[3–5] Rapidly produced 3D models would be significant surgical aids, which allow surgeons to accurately assess the fracture. By doing so, a more effective strategy to reconstruct the fracture can be developed. It is also useful to offer 3D printed physical models to surgeons/students/trainees/nurses/patients/their families for their education and training purposes.^[6]

Recent technological advances have seen the emergence of 3D printing being adapted for interventional clinical application and

^a Trauma and Orthopaedic Research Laboratory, Department of Surgery, The Medical School, The Australian National University, Canberra, ACT, Australia, ^b Trauma and Orthopaedic Research Unit, Clinical Orthopaedic Surgery, The Canberra Hospital, Garran, ACT, Australia, ^c The Medical School, and John Curtin School of Medical Research, The Australian National University, Canberra, ACT, Australia, ^d National Computational Infrastructure, The Australian National University, Canberra, ACT, Australia; and ^e The Medical School, and John Curtin School of Medical Research, The Australian National University, Acton, ACT, Australia.

*Corresponding author. Address: Rachel W. Li, MD, PhD, The Medical School, and John Curtin School of Medical Research, The Australian National University, Acton, ACT 2601, Australia. E-mail: rachel.li@anu.edu.au.

The Australian Research Council Linkage Scheme (ARC-LP150100343). No other conflict of interest to declare.

Presented at the 2019 Conference on Applied Modeling in Acute Care (2019AMAC), Canberra, ACT, Australia (Patient specific modeling, surgical planning and rapid production of injury specific 3D printed fixation implants—improving pelvic fracture management).

This manuscript involves deidentified patient CT data; thus, ethical approval letter of the study is attached as a separate file.

Copyright © 2022 The Authors. Published by Wolters Kluwer Health, Inc. on behalf of the Orthopaedic Trauma Association.

This is an open access article distributed under the terms of the Creative Commons Attribution-Non Commercial-No Derivatives License 4.0 (CCBY-NC-ND), where it is permissible to download and share the work provided it is properly cited. The work cannot be changed in any way or used commercially without permission from the journal.

OTAI (2022) e213

Received: 21 March 2021 / Accepted: 8 May 2022

Published online 21 September 2022

<http://dx.doi.org/10.1097/OI9.000000000000213>

medical education. 3D printing has low cost and high versatility and thus its application in preoperative planning for comminuted fractures becomes popular.^[7,8] Emerging case reports and reviews within the literature show promise in 3D printed bone models for surgical planning.^[9–12] Sterilized 3D printed models also provide tactile feedback, helping identify key landmarks during surgery and selecting patient-specific surgical guides.^[13,14] These real cases can be replicated by 3D printing to facilitate clinical training.

Although 3D printing is becoming more widely adopted, a reliable, inexpensive workflow to rapidly generate a 3D printed model in trauma cases is yet to be established. Current 3D printing workflows for reconstructing comminuted fractures require a trained technician or a subscription to expensive commercial software suites, limiting accessibility. Current image-processing techniques also produce artifacts, leading to anatomically inaccurate replication of the patients' bones.^[15] Consequently, surgical planning workflows require a multicenter approach consisting of a mixed team of engineers and surgeons, increasing operating costs and reducing efficiency.^[16,17]

3D printing has been adopted to print patient-specific surgical guides and implants, such as plates and screws and customized surgical instruments.^[18–22] Potential advantages of 3D printing technology include reduced blood loss, decreased surgical times, and risk of infection, thereby minimizing the incidence of acute complications.^[10,23] The technology has yet to become part of standard practice, with universal quality assurance under development.^[24,25]

This study aims to address key deficits of the current process. We propose a novel, simple, rapid, and open-source method to create virtual 3D models using the Drishti software (National Computational Infrastructure of Australia, Canberra, Australia) to allow orthopaedic surgeons to generate their own high-quality 3D printable models of complex fractures.^[26] Drishti is a free accessible tool (<https://github.com/nci/drishti>) for tomography visualization, aiming at an easy and fast 3D rendering of image stacks for nontechnical people. The proposed workflow is compared with the bone segmentation software 3D Slicer, the other open-sourced 3D image rendering platform widely used for medical purposes.^[27] Both software platforms are designed to generate 3D models using 2D image stacks rapidly. Although these open-sourced platforms are not FDA-approved for clinical use, they have been widely adopted to evaluate anatomies under institutional approval.

2. Materials and Methods

2.1. Study Design

Deidentified patient CT Digital Imaging and Communications in Medicine (DICOM) image directories were obtained from the Trauma and Orthopaedic Research Unit, The Canberra Hospital, Australia, after ethics approval from the ANU and the Australian Capital Territory Health Human Research Ethics Committee (ETHLR.17.160). Thirteen data sets were used for this study and are presented in Table 1. One fractured pelvis case was used for the customized implant design.

Data of each patient were processed using both 3D Slicer and Drishti on a laptop of CPU up to 1.8 GHz clock speed and 4.0 GHz turbo speed, with 16 GB memory and 512 GB SSD. To address the urgent application scenario, the processing time frame required first to view the 3D bone model and export the data were recorded, which are clinically most relevant stages. The optimal processes of minimum actions to view the 3D bone model and

export the model were performed for each case in both software platforms. Considering 3D anatomy usually contains large data sets, the original DICOM's data sizes, the processed data file, and the generated 3D model of Drishti and 3D Slicer are also documented and analyzed. The processing data file refers to the data set converted from DICOM to a format readable by each platform that can represent the DICOM. We also assessed the ease of segmentation and the ability to use the output for further design. We explored the potential of incorporating the 3D modeling process into the customized implant design.

2.2. Drishti Suite

The open-sourced Drishti software v2.7 (<https://github.com/nci/drishti>) was downloaded and installed. The Drishti suite consists of 3 programs: Drishti Import, Drishti, and Drishti Paint. This study mainly used Drishti Import and Drishti Paint to convert 2D image data to 3D models.

Drishti Import converted the CT image data set into a Drishti compatible data file for processing. The process was conducted as follows: We dragged the CT image directory folder into Drishtiimport.exe and defaulted all the dialog boxes' settings popup. The CT slices were imported and ready to view. We saved the data set and acquired a .pvl.nc data file.

Drishti Paint was then used to perform semiautomated image processing to isolate and extract the bone surfaces from the CT data. We loaded the .pvl.nc file in Drishtipaint.exe and defaulted all the settings to preview the CT images and the 3D model at the current segmentation level. The thresholding function under the Transfer Functions panel was adjusted to change the segmentation level to isolate the pixels at the selected brightness range. The real-time 3D rendering feature allows for displaying the segmented 3D structures. Further processing techniques such as tagging, region growing, and gating were used to highlight or exclude components from the 3D view. Then, we selected the "mesh-tagged region" to export a .ply file, which contained the segmented 3D structure we saw in the 3D view. The time was recorded when a clear 3D bone was visualized and when data meshed.

2.3. 3D Slicer

The software 3D Slicer is downloaded and installed from <https://www.slicer.org/>. Upon opening the software, the DICOM directory folder was dragged into the window under the "Load DICOM Data" module. We double clicked the loaded study to view the data

TABLE 1
Data Sets Overview.

No.	Description	Slice	Size (MB)	Contrast
1	Pelvis, ilium fracture	125	22	Low
2	Pelvis, iliac crest fracture	96	25	Low
3	Pelvis, iliac crest fracture	687	213	Low
4	Pelvis, iliac crest and acetabulum fracture	631	184	Low
5	Pelvis, iliac crest and pubic ring fracture	661	207	Low
6	Pelvis, pubic ring fracture	292	148	High
7	Pelvis, pubic ring fracture	1589	468	Low
8	Hemipelvis, femur fracture	65	33	High
9	Spine and pelvis, severe pelvic fracture	709	131	High
10	Spine and iliac crest, iliac crest fracture	108	25	Low
11	Shoulder	257	65	Low
12	Skull	463	62	High
13	Knee	313	72	Low

set in a Four-Up table view similar to Drishti Paint. Then, the “Segmentation” module was engaged to segment the area of interest. A series of functions such as threshold, paint, erase, islands, and smoothing were performed to mask the area of interest fully. Then, we turned on the “Show 3D” to visualize the segmented 3D model. After we fully segmented the bone, left click “Segmentations...” — “Save to files...” with the selection of saving the 3D model, landmarks, and compact CT data set, a .stl cloud point model is completed. The time was recorded when the 3D bone was exhibited, and the data were exported and saved.

2.4. Case Presentation of Further Customized Implant Design

In this study, fractured pelvis data were used and were successfully segmented using Drishti, followed by the design of customized fixation plates ready for final production. The process includes fracture segmentation, restoring the original conformation of the anatomy concerning the intact contralateral hemipelvis, and designing the fixation plate referring to the reconstructed model.^[28] This method also avails the planning of screw length and direction preoperatively. We used Geomagic (3D Systems (Rock Hill, SC)) to assist in manually reconstructing the fractures to a correct position. Each fracture was identified and separated into individual models. Fractures were moved back to their original position. Then, the model was exported and imported to SolidWorks (Waltham, MA), where a computer-aided design (CAD) surface reconstruction was performed on a fracture-restored 3D model. The implant design was completed based on the geometry of the bone model. A workflow was created to generate implants using a Drishti-converted pelvic model and designing a customized fixation plate (Fig. 1).

3. Results

3.1. Processing Time and Data Size

We selected the time points meaningful to surgeons and can be observed on both platforms to compare the 2 software outcomes. Thus, we recorded the processing time from the first click of the process to viewing the 3D bone model within the software and completing the data/model export. We also documented the size of the processing data generated by the software representing the original DICOM and the data size of the exported 3D bone model. The outcomes are listed in Table 2.

3.2. Software Comparison

To better compare the software performances using processing time and data size parameters, we further calculated the paired ratios of these parameters. The outcome is listed in Table 3.

We can see that the processing data size of both software platforms is slightly larger than the original DICOM. However, the processing data size of Drishti is averagely 12% smaller than that of 3D Slicer ($P = 0.046$). Owing to the better noise removal ability, the storage space of the 3D models using Drishti is on average 27% of the sizes of 3D Slicer ($P = 0.004$). The processing time of Drishti is also faster than that of 3D Slicer at both time points (39% faster for viewing 3D model $P = 0.003$ and 38% faster for exporting data $P = 0.001$).

3.3. Customized Implant Design

Starting from the CT data-converted 3D model using Drishti, we designed a workflow of further applying the method to design a

customized implant for a complex pelvic fracture. The workflow is presented in Figure 1. The 3D bone model generated by 3D Slicer is also compatible with this workflow.

4. Discussion

Although Drishti is not specifically designed for medical purposes, it has clinical advantages of easy use, low hardware requirement, small data storage, and fast response for emergent scenarios. These advantages are discussed below.

4.1. Ease of Segmentation

By thresholding, tagging, and gating in Drishti Paint, the bone was isolated from the soft tissue with reasonable accuracy, decreasing subsequent processing time because cleaning was no longer required. Region growing further improved the isolation of bone from the surrounding soft tissue but became overly time-consuming when the fracture contained many fine fragments of bone, as seen in comminuted fractures. In this situation, a decision needs to be made regarding the importance of a particular small fragment to the overall reconstruction. If the fragment is judged insignificant, it can be deleted to simplify the overall process. Compared with Drishti, 3D Slicer has powerful functions and a better user interface. It produces faster and better-quality 3D bones using high-contrast CT images. However, Drishti is more suitable for an urgent situation that produces 3D models faster with less computer space requirement and more efficient processing power. It also means less hardware requirement and a simpler learning curve. In addition, by the time of the study, Drishti was the first open-sourced segmentation software that embedded the local thresholding technique (“gradient thresholding” in software). It compares the color changes in local areas rather than applying a threshold to the whole image. This improvement has a great potential to make the segmentation much easier by applying fewer tools to remove noises and identifying connected bones more quickly and accurately. The performance evaluation of the local threshold will be investigated in later studies. On the other hand, a quantified comparison with commercial software such as Materialise Mimics (Materialise HQ, Leuven, Belgium) will need to be considered.^[29]

Compared with the “Show 3D” mode of 3D Slicer segmentation that constructs 3D models in real time, Drishti renders the segmentation much faster and displays the 3D model at a lower but reasonable resolution (see Fig. 2 for the same case). Although 3D Slicer demonstrates a higher 3D resolution, it requires better hardware support and a longer waiting time for any segmentation change. These data suggest that Drishti is more suitable to support clinicians in emergencies. In addition, Drishti’s more moderate hardware requirement allows its use in a financially restricted clinical environment for a smooth 3D view. On the other hand, 3D Slicer contains more in-build modules for multilayer segmentation and image quantification. It provides better feasibility on landmarking and measurement for preoperative planning. By contrast, Drishti’s user interface lacks a voxel-level quantification. Third-party CAD software is required for quantitative modeling using the Drishti workflow.

This project has highlighted some of the technical issues faced in producing 3D models and working in virtual space. Image processing is time-consuming, and further automated processes would enhance the accessibility of the technology.^[15] Hardware limitations also need to be considered, as with larger data sets conversion times may become significantly prolonged without adequate processing power. Although a finer slice thickness

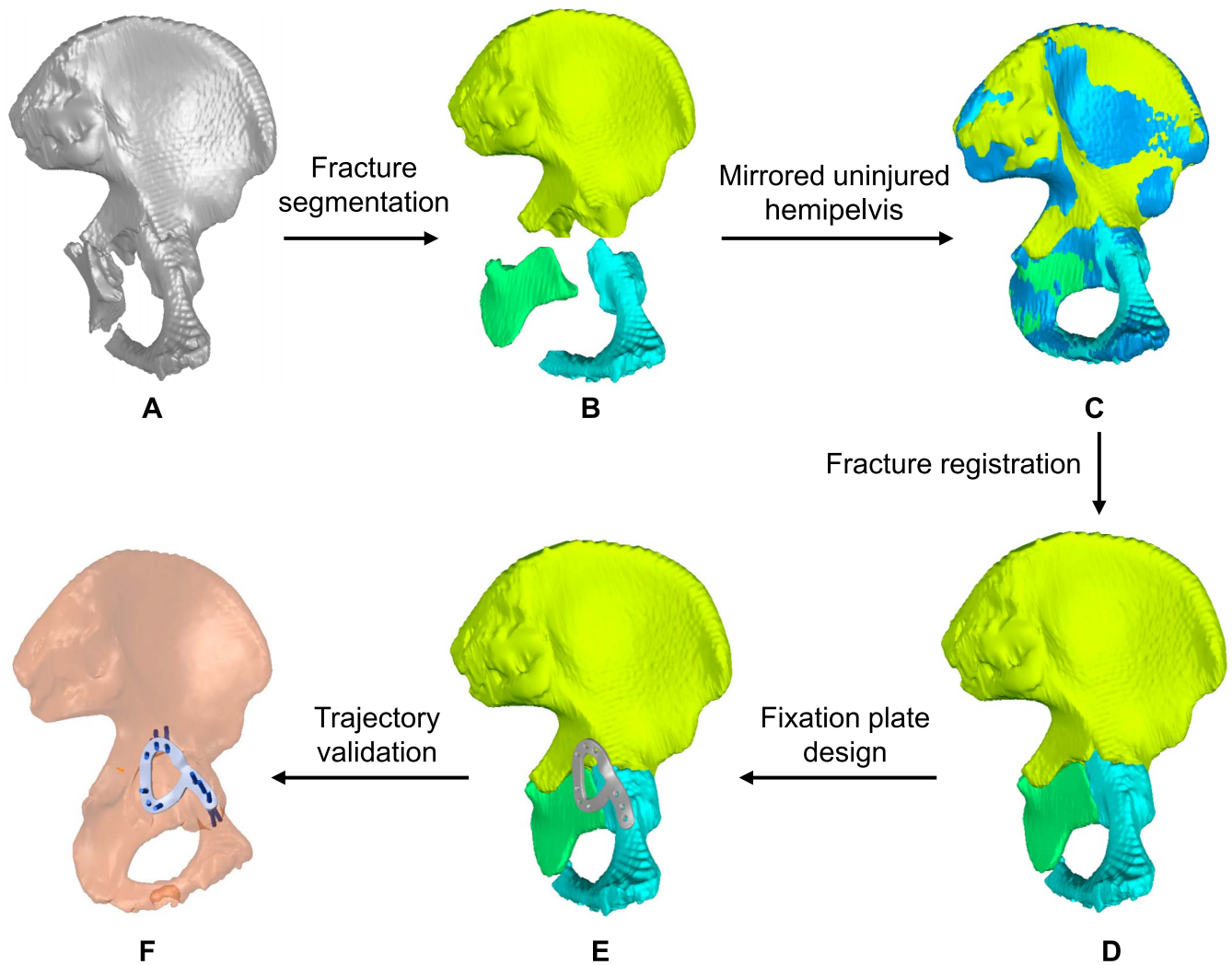


Figure 1. Fixation plates designed from a pelvic model converted using Drishti.

improved the quality of our virtual 3D models, soft tissue around the bone fragments also increased, complicating the conversion of the models. Thresholding was easier in areas with

relatively less surrounding soft tissue, such as the skull and knee, than in areas with large amounts of soft tissue, such as the thorax and pelvis.

TABLE 2
Performance Evaluation of Drishti and 3D Slicer.

No.	Drishti				3D Slicer			
	Processing Time (s)		Data Size (MB)		Processing Time (s)		Data Size (MB)	
	View 3D	Export Data	Processing Data	3D Model	View 3D	Export Data	Processing Data	3D Model
1	35	51	31	34	41	66	30	119
2	35	56	38	41	57	88	38	173
3	44	84	171	207	135	181	262	1260
4	48	79	157	150	97	139	227	764
5	59	95	165	261	128	175	255	1137
6	40	60	73	60	40	67	68	117
7	74	131	397	263	229	305	572	1556
8	33	47	16	8	28	48	16	20
9	50	79	177	132	125	179	182	380
10	33	46	28	45	68	96	32	149
11	36	56	64	86	85	117	78	760
12	38	61	115	102	66	102	105	249
13	49	74	78	43	62	91	92	319

TABLE 3
Performance Comparison of Drishti and 3D Slicer.

No.	Processing Data Size		3D Model Size		Time Consumption	
	Drishti vs. DICOM	3D Slicer vs. DICOM	Drishti vs. 3D Slicer	Drishti vs. 3D Slicer	View Model Drishti vs. 3D Slicer	Export Model Drishti vs. 3D Slicer
1	1.41	1.36	1.03	0.29	0.85	0.77
2	1.52	1.52	1.00	0.24	0.61	0.64
3	0.80	1.23	0.65	0.16	0.33	0.46
4	0.85	1.23	0.69	0.20	0.49	0.57
5	0.80	1.23	0.65	0.23	0.46	0.54
6	0.49	0.46	1.07	0.51	1.00	0.90
7	0.85	1.22	0.69	0.17	0.32	0.43
8	0.48	0.48	1.00	0.40	1.18	0.98
9	1.35	1.39	0.97	0.35	0.40	0.44
10	1.12	1.28	0.88	0.30	0.49	0.48
11	0.98	1.20	0.82	0.11	0.42	0.48
12	1.85	1.69	1.10	0.41	0.58	0.60
13	1.08	1.28	0.85	0.13	0.79	0.81
Average	1.20	1.05	0.88	0.27	0.61	0.62
SD	0.35	0.40	0.16	0.12	0.27	0.18

4.2. Data Storage

We need to note that the 3D models generated from 3D Slicer are in .stl format, and 3D models from Drishti are in .ply format. The main difference is that the .ply format usually contains color information, but .stl format does not. There is no discernible difference in the quality of the 2 formats. Thus, we compared the data size of the original generated 3D data.

The outcome in Table 1 demonstrates that the 3D bone model generated using Drishti is 73% smaller than those created by 3D Slicer ($P = 0.004$), proving its better ability for automated noise removal. Considering the generation of the 3D models was at an optimal process with minimum actions, the model sizes could be further compressed by adding a few simple steps. This is especially necessary for 3D Slicer because the threshold algorithm cannot exclude noise effectively, and the segmentation tools are more powerful with high flexibility. Other simple functions such as *Island* and *Smoothing* could easily reduce noise to decrease the model size substantially.

Meanwhile, operation factors such as threshold selection and fluency of software operation also influence the segmentation quality and time consumption. Because of the limitation of this

study, there was only one experienced engineer involved in processing the data at a computer of above-average specification. Multiple operators and testing computers will be necessary to draw a better conclusion as to the efficacy of the system.

Notably, both platforms generated processing data representing the original DICOM image directory. Although the processing data size of Drishti is smaller than that of 3D Slicer ($P = 0.046$), there was no statistical difference found in the processing data size when it is compared with the DICOM size ($P = 0.330$ and 0.076 for Drishti and 3D Slicer, respectively).

4.3. Further Integration of Implant Design

Within the software frame of Drishti and 3D Slicer, both platforms generated comparable satisfactory outcomes. Thus, both software platforms can be integrated into further workflow of fracture reconstruction and personalized implant design. Reconstructed templates could be used to design personalized surgical implants, including fixation/locking plates and screws. For example, using point-cloud processing software and CAD software to reconstruct a bone fracture is efficient when an individual bone is processed.

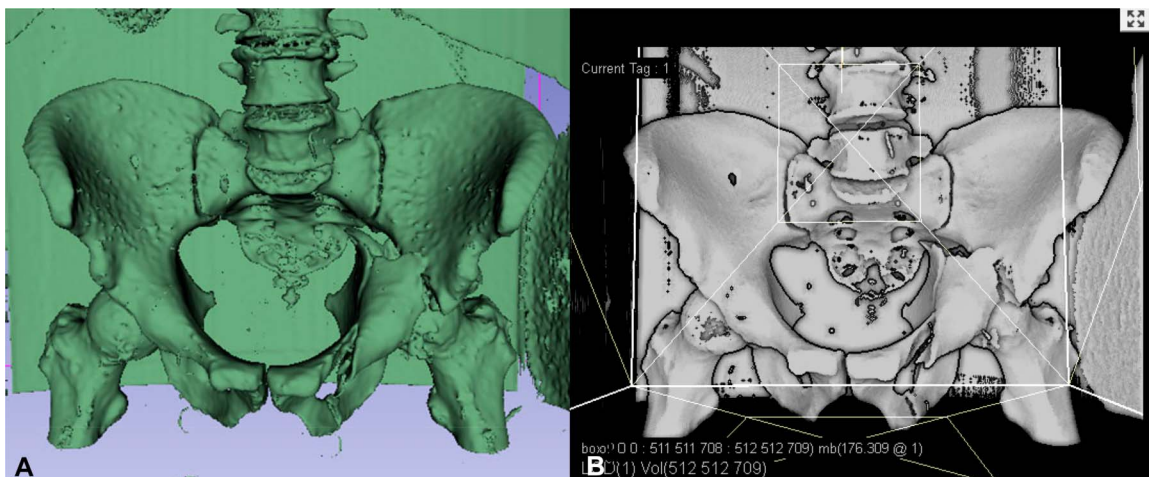


Figure 2. 3D view of a pelvic fracture case within the software: (A) Drishti and (B) 3D Slicer.

We demonstrated a case study in Figure 1, which used the 3D bone model generated from Drishti for further design. The fractured bone model was imported into Geomagic for cloud point processing and in SolidWorks for CAD design of the personalized implant. Some other software can replace the workflow we presented, such as MeshLab. MeshLab served as a potential open-source solution for rapid 3D bone processing. Although MeshLab allows for complicated manipulation, the software has a significant learning curve. This process would be too labor intensive for a novice user to serve as a viable option for rapid modeling in trauma surgery. Geomagic, a commercially licensed software, had a simpler user interface and allowed for real-time manipulation of bone fragments in 3D space with relative ease, making it suitable for rapid model generation.

5. Conclusions

This study focused on the image processing aspect of the workflow with which surgeons can create a 3D model, plan operation procedures, design patient-specific implants, and deliver a design file for 3D printing. Voxel-based data allow for rapid rendering of CT images through various algorithms; however, it may concern the loss of detail, requiring large data sets to maintain fidelity.^[30] After conversion to the .ply file format, soft tissue converted with bone initially required extra cleaning in third-party software such as MeshLab or Geomagic. However, 3D Slicer integrated part of the automated cleaning and voxel editing functions that benefit the complex surgical planning process. The image processing techniques mentioned have been previously well described in the literature with commercial and open-source software.^[8,16,17,31–33] Drishti's major advantage is fast real-time bone segmentation using histogram, which greatly aids imaging processing and reduces learning difficulty. We consistently found that after image processing in Drishti and subsequent export, file sizes are generally smaller than the similar platform 3D Slicer, which reduced the processing burden with subsequent third-party software and saved the storage space required for large data sets.

References

- Hak DJ, Rose J, Stahel PF. Preoperative planning in orthopedic trauma: benefits and contemporary uses. *Orthopedics*. 2010;33:581–584.
- Duncan JM, Nahas S, Akhtar K, et al. The use of a 3D printer in preoperative planning for a patient requiring acetabular reconstructive surgery. *J Orthop Case Rep*. 2015;5:23–25.
- Olivecrona C, Lapidus LJ, Benson L, et al. Tourniquet time affects postoperative complications after knee arthroplasty. *Int Orthop*. 2013;37:827–832.
- Peersman G, Laskin R, Davis J, et al. Prolonged operative time correlates with increased infection rate after total knee arthroplasty. *HSS J*. 2006;2:70–72.
- Cie C. Additive manufacturing technologies: 3D printing, rapid prototyping, and direct digital manufacturing. *J Print Media Technol Res*. 2015;4:70.
- Chai Y, Chen X-B, Zhang D, et al. Laser polished fused deposition poly-lactic acid objects for personalized orthopaedic application. *SN Appl Sci*. 2020;2:1–10.
- Bortolotto C, Eshja E, Peroni C, et al. 3D printing of CT dataset: validation of an open source and consumer-available workflow. *J Digit Imaging*. 2016;29:14–21.
- Auricchio F, Marconi S. 3D printing: clinical applications in orthopaedics and traumatology. *EFORT Open Rev*. 2016;1:121–127.
- Diment LE, Thompson MS, Bergmann JHM. Clinical efficacy and effectiveness of 3D printing: a systematic review. *BMJ Open*. 2017;7:e016891.
- Hughes AJ, DeBuitler C, Soden P, et al. 3D printing aids acetabular reconstruction in complex revision hip arthroplasty. *Adv Orthop*. 2017;2017:8925050.
- Yang L, Shang XW, Fan JN, et al. Application of 3D printing in the surgical planning of trimalleolar fracture and doctor-patient communication. *Biomed Res Int*. 2016;2016:2482086.
- Tack P, Victor J, Gemmel P, et al. 3D-printing techniques in a medical setting: a systematic literature review. *Biomed Eng Online*. 2016;15:115.
- Battiato C, Basigliani L, Giovannini F. Traumatological application of 3D model in complex acetabular fractures. *Trauma Cases Rev*. 2017;3:053.
- Mulford JS, Babazadeh S, Mackay N. Three-dimensional printing in orthopaedic surgery: review of current and future applications. *ANZ J Surg*. 2016;86:648–653.
- Hosny A, Keating SJ, Dilley JD, et al. From improved diagnostics to presurgical planning: high-resolution functionally graded multimaterial 3D printing of biomedical tomographic data sets. *3D Print Addit Manuf*. 2018;5:103–113.
- Wong KC. 3D-printed patient-specific applications in orthopedics. *Orthop Res Rev*. 2016;8:57–66.
- Mitsouras D, Liacouras P, Imanzadeh A, et al. Medical 3D printing for the radiologist. *Radiographics*. 2015;35:1965–1988.
- Phan K, Sgro A, Maharaj MM, et al. Application of a 3D custom printed patient specific spinal implant for C1/2 arthrodesis. *J Spine Surg*. 2016;2:314–318.
- Cherkasskiy L, Caffrey JP, Szewczyk AF, et al. Patient-specific 3D models aid planning for triplane proximal femoral osteotomy in slipped capital femoral epiphysis. *J Child Orthop*. 2017;11:147–153.
- Mok S-W, Nizak R, Fu S-C, et al. From the printer: potential of three-dimensional printing for orthopaedic applications. *J Orthop Transl*. 2016;6:42–49.
- Liu A, Xue GH, Sun M, et al. 3D printing surgical implants at the clinic: a experimental study on anterior cruciate ligament reconstruction. *Sci Rep*. 2016;6:21704.
- Mobbs RJ, Coughlan M, Thompson R, et al. The utility of 3D printing for surgical planning and patient-specific implant design for complex spinal pathologies: case report. *J Neurosurg Spine*. 2017;26:513–518.
- Chen X, Possel JK, Wacongne C, et al. 3D printing and modelling of customized implants and surgical guides for non-human primates. *J Neurosci Methods*. 2017;286:38–55.
- Leng S, McGee K, Morris J, et al. Anatomic modeling using 3D printing: quality assurance and optimization. *3D Print Med*. 2017;3:6.
- Christensen A, Rybicki FJ. Maintaining safety and efficacy for 3D printing in medicine. *3D Print Med*. 2017;3:6.
- Limaye A. Drishti: a volume exploration and presentation tool. In: *Developments in X-Ray Tomography VIII*, 2012. 8506.
- Fedorov A, Beichel R, Kalpathy-Cramer J, et al. 3D Slicer as an image computing platform for the Quantitative Imaging Network. *Magn Reson Imaging*. 2012;30:1323–1341.
- Chai Y, Chen X-B, Estoque JA, et al. A novel approach of customized pelvic implant design based on symmetrical analysis and 3D printing. *3D Print Addit Manuf*. 2021:1–8.
- Islam MN, Boswell B, Pramanik A. An investigation of dimensional accuracy of parts produced by three-dimensional printing. Proceedings of the World Congress on Engineering 2013 Vol I, WCE 2013, July 3-5, 2013, London, United Kingdom, pp 522–525.
- Mashari A, Montealegre-Gallegos M, Knio Z, et al. Making three-dimensional echocardiography more tangible: a workflow for three-dimensional printing with echocardiographic data. *Echo Res Pract*. 2016;3:RS7–R64.
- Chen X, Xu L, Wang W, et al. Computer-aided design and manufacturing of surgical templates and their clinical applications: a review. *Expert Rev Med Devices*. 2016;13:853–864.
- Pietrabissa A, Marconi S, Peri A, et al. From CT scanning to 3-D printing technology for the preoperative planning in laparoscopic splenectomy. *Surg Endosc*. 2016;30:366–371.
- Green N, Glatt V, Tetsworth K, et al. A practical guide to image processing in the creation of 3D models for orthopedics. *Tech Orthop*. 2016;31:153–163.