

Case Report

Phenytoin Induced Erythema Multiforme after Cranial Radiation Therapy

Atilla Kazanci, M.D.,¹ İsmail Hakkı Tekkök, M.D.²

Department of Neurosurgery,¹ Ankara Atatürk Education and Research Hospital, Ankara, Turkey

Department of Neurosurgery,² Ankara Bayındır Hospital, Ankara, Turkey

The prophylactic use of phenytoin during and after brain surgery and cranial irradiation is a common measure in brain tumor therapy. Phenytoin has been associated with variety of adverse skin reactions including urticaria, erythroderma, erythema multiforme (EM), Stevens-Johnson syndrome, and toxic epidermal necrolysis. EM associated with phenytoin and cranial radiation therapy (EMPACT) is a rare specific entity among patients with brain tumors receiving radiation therapy while on prophylactic anti-convulsive therapy. Herein we report a 41-year-old female patient with left temporal glial tumor who underwent surgery and then received whole brain radiation therapy and chemotherapy. After 24 days of continuous prophylactic phenytoin therapy the patient developed minor skin reactions and 2 days later the patient returned with generalized erythematous and itchy maculopapular rash involving neck, chest, face, trunk, extremities. There was significant periorbital and perioral edema. Painful mucosal lesions consisting of oral and palatal erosions also occurred and prevented oral intake significantly. Phenytoin was discontinued gradually. Systemic administration of corticosteroids combined with topical usage of steroids for oral lesions resulted in complete resolution of eruptions in 3 weeks. All cutaneous lesions in patients with phenytoin usage with the radiotherapy must be evaluated with suspicion for EM.

Key Words : Cranial Radiotherapy · Erythema Multiforme · Phenytoin.

INTRODUCTION

Treatment of intracranial malignancies includes prophylactic anti-convulsant and steroid medication in addition to a combination of surgery, radiation therapy and chemotherapy. Phenytoin as an anti-convulsant therapy has been known for variety of adverse skin reactions including urticaria, erythroderma, erythema multiforme (EM), Stevens-Johnson syndrome, and toxic epidermal necrolysis for a long time^{2,4,6,10,11,13}. Erythema multiforme (EM) is a skin reaction that ranges from self-limited cutaneous eruption to a progressive mucocutaneous disease^{1,4,5,8,9,13,15}. EM typically presents with self-limited targetoid lesions on the extensor surfaces of extremities and is often associated with underlying infection (commonly herpes simplex) or a hypersensitivity reaction to a variety of medications like sulfonamides, penicillines, quinolones and anti-convulsants^{1,2,4,6,11}.

Hypersensitivity reaction mechanism caused by anti-convulsant drugs is not clear however, it has been proposed that toxic metabolite of aromatic anti-convulsants could bind the cellular macromolecules causing a secondary immunological response³.

In patients receiving phenytoin as a prophylactic anti-convulsant who have also treated with radiotherapy, anti-epileptics must be administered with caution, and all cutaneous reactions developing subsequently within the radiation site must be promptly evaluated with a high index of suspicion for erythema multiforme.

Herein we report the case of a patient who developed EM after administration of cranial irradiation and phenytoin treatment.

CASE REPORT

A 41-year-old female patient with left temporal lobe WHO grade IV glioblastoma multiforme underwent surgery on the first day after admitting to our hospital (Fig. 1). The patient was given 300 mg/day of phenytoin and 16 mg/day dexamethasone before the surgery. Upon initial diagnosis of glioblastoma multiforme (GBM) after maximal surgical resection the patient underwent radiotherapy, and concomitant and adjuvant chemotherapy with temozolomide. She continued taking phenytoin and tapering dosage of dexamethasone. She subsequently un-

• Received : August 25, 2014 • Revised : January 11, 2015 • Accepted : January 14, 2015

• Address for reprints : Atilla Kazanci, M.D.

Department of Neurosurgery, Ankara Atatürk Education and Research Hospital, Ankara 06810, Turkey

Tel : +00905057793149, Fax : +90 312 291 27 26, E-mail : atillakazanci@gmail.com

• This is an Open Access article distributed under the terms of the Creative Commons Attribution Non-Commercial License (<http://creativecommons.org/licenses/by-nc/3.0>) which permits unrestricted non-commercial use, distribution, and reproduction in any medium, provided the original work is properly cited.

derwent whole brain radiation therapy and was given a total dose of 6000 cGy over 5 days per week in doses of 2.0 Gy fractions spaced over 6 weeks. The patient underwent chemotherapy with temozolomide 130 mg/day for 42 days. After 1 month without chemotherapy she was given 6 cycles of 300 mg/day temozolomide for 5 days.

After completing radiation therapy and tapering of dexamethasone on the 24th day of continuous prophylactic phenytoin therapy the patient developed minor skin reactions on the scalp within the radiation field especially on left temporal side. The maculopappular eruption generalized within a few days to involve the neck, face, trunk and extremities (Fig. 2). Edema on the lips, mucosal lesions consisting of oral erosions, conjunctival suffusion and periorbital edema also evolved. Laboratory serology included a normal blood cell differential with 12% monocytes, 1.9% eosinophils. Transaminase levels were mildly elevated-aspartate aminotransferase 49 U/L and alanine aminotransferase 57 U/L. Anti-nuclear antibody (ANA), anti-double stranded DNA (Anti-dsDNA), anti-extractable nuclear antigen (Anti-ENA), anti-neutrophil cytoplasmic antibody (ANCA) were negative and serum immunoglobulin levels were normal. There was no clinical and/or laboratory evidence of an infection or an autoimmune disease.

Dermatological consultation was sought and a diagnosis of

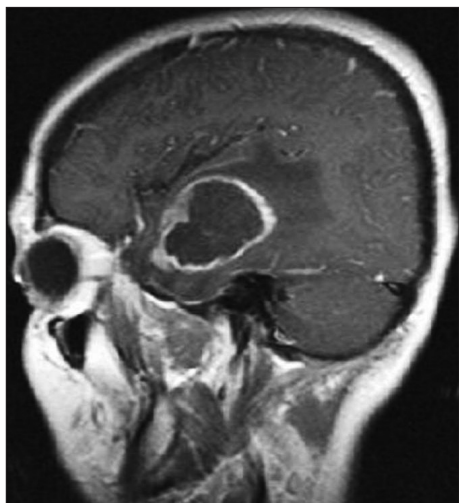


Fig. 1. Preoperative sagittal MRI scan showing left temporal lobe glioblastoma multiforme.

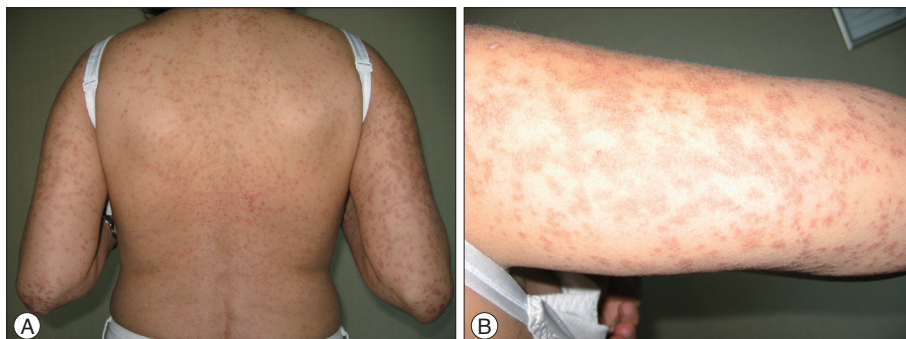


Fig. 2. A : The maculo-pappular eruptions (smooth skin rash or redness covered by elevated bumps) on the neck, face, trunk and extremities. B : The maculo-pappular rashes on the extremities.

phenytoin induced EM was considered. Phenytoin was discontinued and patient received intravenous corticosteroid that was tapered over 4 days. The patient was also given topical corticosteroid for oral ulcerations. On the 6th day of discontinuation of phenytoin patient had temporal lobe seizure and levetiracetam 2000 mg/day and carbamazepine 400 mg/day was initiated for seizure prophylaxis. Over the following 1 week resolution of the mucocutaneous lesions occurred and the patient completely recovered within 3 weeks after stopping phenytoin.

DISCUSSION

EM is a mucocutaneous reaction associated with several precipitating factors that include infections and various drugs such as sulfonamides, penicillin, anti-convulsants, allopurinol and anti-inflammatory drugs^{1,3,4,7,8,10}. EM typically presents with self-limited targetoid lesions on the extensor surfaces of extremities but skin lesions range from skin rashes to a progressive mucocutaneous disease^{1,4,5,8,9,13,15}.

Phenytoin is commonly prescribed as a prophylactic anti-convulsant in patients with intracranial malignancies. Phenytoin induced skin reactions ranging from urticaria to toxic epidermal necrolysis has been reported several times^{1-4,6,8,9,11-15}. Skin reactions associated with anti-convulsant therapy mainly occur during the first few days to 8 weeks of anti-convulsant drug administration^{8,10,11}. As in our case skin lesions occurred 24 days after continuous prophylactic phenytoin therapy.

A generalized hypersensitivity has also been described in approximately 10% of patients receiving phenytoin that consists of fever, arthralgias, peripheral eosinophilia, generalized lymphadenopathy and hepatosplenomegaly^{1,3,7,8}. This hypersensitivity reaction frequently associated with aromatic anti-convulsants such as phenytoin, phenobarbital and carbamazepine. Anti-convulsants are converted to reactive metabolites and induce cytochrome P450 3A and produce oxidative reactive intermediates that may be implicated in hypersensitivity reactions and then these metabolites excreted from kidney via another hepatic enzyme epoxide hydrolase^{2,3,5,8-11,13}. Imbalance between the formation of metabolites and enzymatic detoxification leads to accumulation of metabolites causes them to bind with cellular macromolecules resulting in a toxic role in type 4 hypersensitivity reactions^{1,3,5,8,10}. Baba et al.³ suggested that hypersensiti-

ty reactions developed after craniotomy and surgical trauma could have been involved in decreasing activity of hepatic enzymes due to exposure to anaesthetic agents³. Thus this is a clinical phenomenon that occurs with unusual frequency in patients with brain tumor who undergo radiation therapy while taking phenytoin or other anticonvulsants such as phenobarbital and carbamazepine⁸. Both carbamazepine and barbiturates have shown cross-sensitivity with phenytoin

Recently management of glioblastoma multiforme progressively changed to maximal surgical resection with postoperative radiotherapy and concurrent chemotherapy. In our case after maximal surgical resection the patient underwent radiotherapy, and concomitant and adjuvant chemotherapy with temozolomide. Several reports in literature suggest the existence of a phenomenon in which EM, Stevens-Johnson syndrome or toxic epidermal necrolysis may occur in patients with brain tumors treated with radiation therapy and anti-convulsant drugs and it was concluded that radiation therapy was responsible because reinstitution of the drugs did not result in recurrence of the reaction. As in our case the clinical picture differed from the classic form of EM in that the erythema began on the scalp and spread to the extremities, progressing to extensive bullous formation^{1,6,8,10}. As a well recognized phenomenon cutaneous reactions with radiation therapy is usually dose dependent and consists of erythema limited to the radiation field^{1,4,6,10}. Irradiation can enhance a primary antibody response and impairs T suppressor cells and radiation therapy might promote the development of a hypersensitivity reaction to phenytoin that may be more evident patients receive a tapering dosage of steroids⁸.

Ahmed et al.¹ recently used definition EMPACT (E : erythema M : multiforme associated with P : phenytoin and C : cranial radiation T : therapy) to best describe this disorder. Ahmed et al. reviewed 24 patients which had taken phenytoin for variable time periods (mean 40 days) the lesions developed within the port site during the radiation treatments or soon after its completion. In literature many cases, as in our case, the skin rashes and eruptions first occur in the irradiation area which may result in misdiagnosis as a normal radiation reaction and this may cause delaying the diagnosis of EM lesions and more severe syndromes^{2,4,6,8,10}. In literature as in our case not only skin eruptions but EM lesions on the irradiation area with phenytoin treatment was described as diagnostic criteria for EMPACT¹. It is also reported that the incidence of this syndrome is much more frequent in cases where phenytoin was administered less than 2 months prior to start of radiotherapy, compared to cases where treatment commenced more than 2 months before irradiation^{10,13}.

The optimal treatment for EM is not well defined. Phenytoin should be discontinued immediately and high dose intravenous steroid application resolves dermal lesions. For the oral mucosal lesions topical steroid is necessary^{8,10,11,13}. If the lesions are more severe like Stevens-Johnson syndrome or toxic epidermal necrolysis symptomatic treatment should be applied si-

milar to that used for burns. Metabolic and electrolyte imbalance should be corrected by replacement of intravenous fluids.

CONCLUSION

The prophylactic use of anti-convulsants after brain surgery or during cranial irradiation is very common. In patients receiving phenytoin as a prophylactic anti-convulsant who have also treated with radiotherapy EM is a relatively rare adverse situation. The physician must be aware of the anti-convulsant hypersensitivity syndrome when combined with radiotherapy and all cutaneous reactions developing subsequently within the radiation field must be evaluated with the suspicion of EM. In patients with disseminated rashes phenytoin administration should be discontinued immediately and intravenous steroid treatment should be given and if necessary symptomatic and supportive treatment should be started similar to that given to patients with burns.

References

- Ahmed I, Reichenberg J, Lucas A, Shehan JM : Erythema multiforme associated with phenytoin and cranial radiation therapy : a report of three patients and review of the literature. *Int J Dermatol* 43 : 67-73, 2004
- Arif H, Buchsbaum R, Weintraub D, Koyfman S, Salas-Humara C, Bazil CW, et al. : Comparison and predictors of rash associated with 15 anti-epileptic drugs. *Neurology* 68 : 1701-1709, 2007
- Baba M, Karakaş M, Aksungur VL, Homan S, Yücel A, Acar MA, et al. : The anticonvulsant hypersensitivity syndrome. *J Eur Acad Dermatol Venereol* 17 : 399-401, 2003
- Barbosa LA, Teixeira CR : Erythema multiforme associated with prophylactic use of phenytoin during cranial radiation therapy. *Am J Health Syst Pharm* 65 : 1048-1050, 2008
- Lin MS, Dai YS, Pwu RF, Chen YH, Chang NC : Risk estimates for drugs suspected of being associated with Stevens-Johnson syndrome and toxic epidermal necrolysis : a case-control study. *Intern Med J* 35 : 188-190, 2005
- Mamon HJ, Wen PY, Burns AC, Loeffler JS : Allergic skin reactions to anticonvulsant medications in patients receiving cranial radiation therapy. *Epilepsia* 40 : 341-344, 1999
- Man CB, Kwan P, Baum L, Yu E, Lau KM, Cheng AS, et al : Association between HLA-B*1502 allele and antiepileptic drug-induced cutaneous reactions in Han Chinese. *Epilepsia* 48 : 1015-1018, 2007
- Micali G, Linthicum K, Han N, West DP : Increased risk of erythema multiforme major with combination anticonvulsant and radiation therapies. *Pharmacotherapy* 19 : 223-227, 1999
- Mockenhaupt M, Messenheimer J, Tennis P, Schlingmann J : Risk of Stevens-Johnson syndrome and toxic epidermal necrolysis in new users of antiepileptics. *Neurology* 64 : 1134-1138, 2005
- Oner Dincbas F, Yörük S, Demirkesen C, Uzel O, Koca S : Toxic epidermal necrolysis after cranial radiotherapy and phenytoin treatment. *Onkologie* 27 : 389-392, 2004
- Pelekanos J, Camfield P, Camfield C, Gordon K : Allergic rash due to antiepileptic drugs : clinical features and management. *Epilepsia* 32 : 554-559, 1991
- Roujeau JC, Kelly JP, Naldi L, Rzany B, Stern RS, Anderson T, et al. : Medication use and the risk of Stevens-Johnson syndrome or toxic epidermal necrolysis. *N Engl J Med* 333 : 1600-1607, 1995

13. Rzany B, Correia O, Kelly JP, Naldi L, Auquier A, Stern R : Risk of Stevens-Johnson syndrome and toxic epidermal necrolysis during first weeks of antiepileptic therapy : a case-control study. Study Group of the International Case Control Study on Severe Cutaneous Adverse Reactions. *Lancet* 353 : 2190-2194, 1999
14. Welykyj S, Gradini R, Nakao J, Massa M : Carbamazepine-induced eruption histologically mimicking mycosis fungoides. *J Cutan Pathol* 17 : 111-116, 1990
15. Wöhrl S, Loewe R, Pickl WF, Stingl G, Wagner SN : EMPACT syndrome. *J Dtsch Dermatol Ges* 3 : 39-43, 2005