

Diagnosis and laparoscopic management of a 5-week ectopic pregnancy in a rudimentary uterine horn: A case report

Monacci F. *, Lanfredini N., Zandri S., Strigini F., Luchi C., Giannini A., Simoncini T.

Department of Clinical and Experimental Medicine, Division of Gynecology and Obstetrics, University of Pisa, Italy

ARTICLE INFO

Article history:

Received 3 October 2018

Received in revised form 2 November 2018

Accepted 13 November 2018

Keywords:

Rudimentary horn pregnancy

Ectopic pregnancy

Uterine malformation

ABSTRACT

Uterine anomalies result from the failure of complete fusion of the Müllerian ducts during embryogenesis. A unicornuate uterus with a rudimentary horn is the rarest anomaly and results from the failure of one of the Müllerian ducts to develop completely and an incomplete fusion with the contralateral side.

Diagnosis and surgical management of a 5-week ectopic pregnancy in a non-communicating rudimentary horn in an 18-year-old nulliparous woman in whom this congenital uterine anomaly was previously unknown are described.

© 2018 The Authors. Published by Elsevier B.V. This is an open access article under the CC BY-NC-ND license (<http://creativecommons.org/licenses/by-nc-nd/4.0/>).

1. Introduction

Uterine anomalies result from the failure of complete fusion of the Müllerian ducts during embryogenesis. A unicornuate uterus with a rudimentary horn is the rarest anomaly and results from the failure of one of the Müllerian ducts to develop completely and an incomplete fusion with the contralateral side. The prevalence of unicornuate uterus is estimated to be 1 in 4020 in the general population [1]. In 84% of those with the condition a rudimentary contralateral horn is present and in the majority of cases it is non-communicating [2–4]. The anomaly is commonly associated with adverse pregnancy outcomes and the main concern is rupture of the horn containing an ectopic pregnancy, leading to life-threatening haemoperitoneum [2–4].

For this reason, it is important to detect unicornuate uterus with a rudimentary horn either before pregnancy or during early obstetric ultrasound screening. Early surgical management of such an ectopic pregnancy is essential.

We present a case of 5-week ectopic pregnancy in a rudimentary horn in a patient in whom this congenital uterine anomaly was previously undiagnosed.

2. Case report

An 18-year-old nulliparous woman was referred at five weeks of pregnancy because of scant vaginal bleeding and lower abdominal

pain. No previous gynecological evaluation had been undertaken as there was no history of dysmenorrhea or abnormal menstrual bleeding.

Clinical examination showed that the uterus was deviated to the left side of the pelvis and a contiguous 30-mm mass was palpable on the right side of the pelvis.

Transabdominal ultrasound revealed a left-sided uterus of normal size and with an endometrial thickness of 13 mm: no gestational sac was present. In the right adnexal area, a 7-mm gestational sac, containing a yolk sac and a 2 mm embryo with no detectable fetal heart beat, surrounded by myometrium, were seen. The structure containing the gestational sac did not appear to communicate with the cervical canal and was connected to the uterus by a fibrotic band (Fig. 1). 2D ultrasound and subsequent 3D ultrasound supported the diagnosis of a left-sided unicornuate uterus with an ectopic pregnancy in a right-sided rudimentary horn. Differential diagnoses included abdominal or tubal pregnancy and bicornuate uterine pregnancy.

Abdominal ultrasound revealed normal kidneys. Beta human chorionic gonadotropin (beta HCG) (5056 UI/l) levels confirmed the presence of an ongoing pregnancy.

Laparoscopic surgery was undertaken after obtaining consent. At the beginning of the procedure, a left-side unicornuate uterus and normal left adnexa were found. The right rudimentary horn was distended by the presence of an ectopic pregnancy and it was connected to the uterus by a 1-cm fibrotic band. The right ovary and fallopian tube were normal (Fig. 2A). No active bleeding or free blood in the abdominal cavity was visible. The right ureter was identified and isolated after opening the broad ligament. The right mesosalpinx and utero-ovarian ligament were coagulated and excised. The fibrotic band was coagulated and the rudimentary horn was disconnected from the cervix. The whole rudimentary horn containing the ectopic pregnancy and right fallopian

* Corresponding author at: Department of Experimental and Clinical Medicine, Division of Obstetrics and Gynecology, University of Pisa, Italy, Via Roma, 67, 56126 Pisa, Italy.
E-mail address: andrea.giannini@unipi.it (F. Monacci).

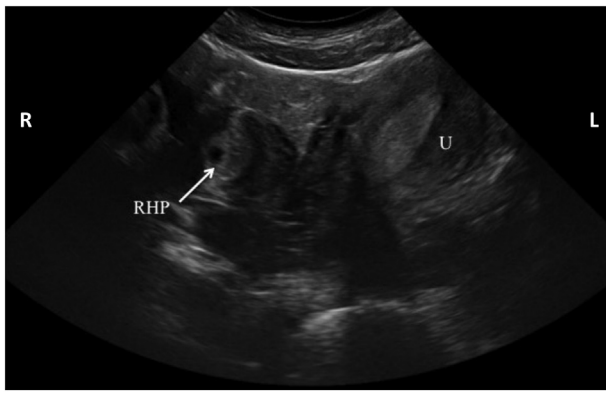


Fig. 1. The transabdominal sonogram shows the left-sided uterus and the rudimentary horn with the yolk sac on the right (arrow). U uterus, RHP rudimentary horn pregnancy.

tube were removed in an endobag through suprapubic laparoscopic access, after performing a 3 cm mini-laparotomy.

At discharge, two days later, the patient's serum beta-HCG had declined to 932 UI/l. Levels were monitored every three days until they had fallen to the non-pregnant range after three weeks.

The pathology report confirmed the presence of an ectopic pregnancy in the rudimentary horn. Five months after surgery the patient was diagnosed with a viable six-week uterine pregnancy.

3. Discussion

Congenital uterine abnormalities are defined as deviations from normal anatomy resulting from embryological anomaly of the Mullerian or paramesonephric ducts. They are benign conditions, with a prevalence of 4–7%. Depending on the type and the degree of anomaly, they may have a profound impact on reproductive outcomes, as they are associated with spontaneous abortion, life-threatening uterine rupture, pre-term delivery, fetal malpresentation, increased cesarean section rates and intra-uterine fetal growth restriction. Unicornuate uterus results from the partial or complete failure of development of one of the Müllerian ducts. Partial development of one duct leads to a rudimentary uterine horn, whereas complete absence of the duct leads to an isolated hemi-uterus [3].

The ESHRE/ESGE classification system allows a categorization of uterine anomalies according to increasing severity of the anatomical deviation [5]. Anomalies are classified into the following main classes, expressing uterine anatomical deviations deriving from the same embryological origin: U0, normal uterus; U1, dysmorphic uterus; U2, septate uterus; U3, bicorporeal uterus; U4, hemi-

uterus; U5, aplastic uterus; U6, for still unclassified cases. Class U4 includes hemi-uterus, defined as unilateral uterine development with the contralateral part incompletely formed or absent (Fig. 3). Class U4 is further divided into two sub-classes depending on the presence or not of a functional rudimentary cavity: class U4a or hemi-uterus with a rudimentary (functional) cavity is characterized by the presence of a communicating or non-communicating functional contralateral horn; class U4b or hemi-uterus without a rudimentary (functional) cavity is characterized either by the presence of a non-functional contralateral uterine horn or by aplasia of the contralateral part. Our case was class U4a, as she had a functional cavity, allowing pregnancy.

Hemi-uterus with a rudimentary horn is often associated with other congenital anomalies, such as urinary tract and musculoskeletal malformations; the most frequent is renal agenesis, which affects up to 30% of the patients with Mullerian duct anomalies [6]. Our patient had a normal renal tract.

The reported incidence of rudimentary horn pregnancies varies from 1 per 76,000 pregnancies to 1 per 150,000 [6]. Where an ectopic pregnancy occurs in a non-communicating horn, transperitoneal transmigration of sperm is believed to have occurred [7]. The variation in incidence figures is due to difficulties in diagnosis.

Sonographic criteria for a presumptive diagnosis of rudimentary horn pregnancy were proposed by Tsafirir et al. in 2005 [8]; (1) a pseudopattern of an asymmetrical bicornuate uterus, (2) absent visual continuity tissue surrounding the gestational sac and the uterine cervix, and (3) the presence of myometrial tissue surrounding the gestational sac. Additionally, hypervascularization typical of placenta accreta may support the diagnosis of rudimentary horn pregnancy. Mavrelou et al. [9] added some further diagnostic features: (1) a single interstitial portion of Fallopian tube in the main uterine body; (2) a gestational sac, mobile and separate from the uterus, surrounded by myometrium; and (3) a vascular pedicle joining the gestational sac to the unicornuate uterus. These criteria help differentiate rudimentary horn pregnancy from tubal pregnancy, where a ring of myometrium surrounding the gestational sac is absent.

In addition, 3D ultrasound (as used in this case) has been shown to be accurate in the diagnosis of uterine malformations, with a good level of agreement with MRI in the classification of the different types based on the ESHRE-ESGE consensus [10].

Complete laparoscopic removal of a rudimentary horn is always recommended even if the horn communicates with the cervix, whether the woman is pregnant or not [5]. This is to prevent menstrual and pregnancy problems. When a diagnosis of pregnancy in a rudimentary horn is made, immediate surgery is the most commonly recommended intervention because of concerns regarding life-threatening uterine rupture.

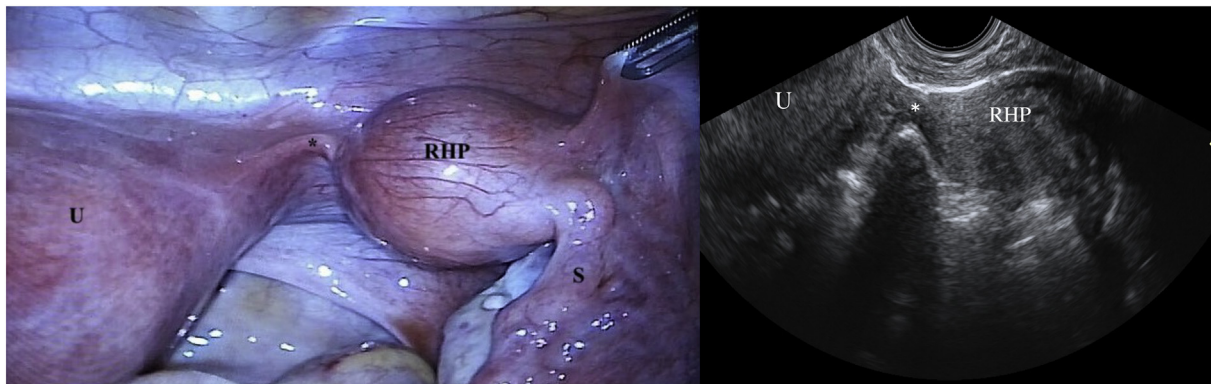


Fig. 2. Laparoscopic (a) and ultrasonographic (b) view of right rudimentary horn containing pregnancy. Asterisk (*) indicates the fibrotic band connecting uterus to the rudimentary horn. U uterus, RHP rudimentary horn pregnancy, S salpinx.

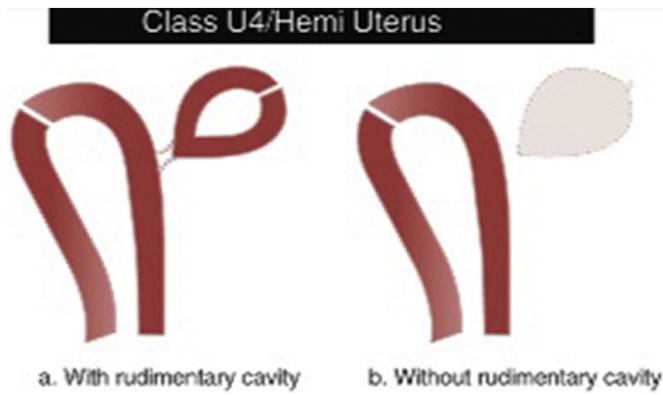


Fig. 3. Class U4 or hemi-uterus is defined as the unilateral uterine development; the contralateral part could be either incompletely formed or absent. From “*The ESHRE/ESGE consensus on the classification of female genital tract congenital anomalies*” [5].

To conclude, diagnosis and successful management of a case of 5-week ectopic pregnancy in a rudimentary horn are described.

Contributors

All authors made a substantive contribution to the information or material submitted for publication.

Conflict of Interest

The authors declare that they have no conflict of interest regarding the publication of this case report.

Funding

This research did not receive any specific grant from funding agencies in the public, commercial, or not-for-profit sectors.

Patient Consent

Written informed consent was obtained from the patient for the publication of this case report and the accompanying images.

Provenance and Peer Review

This case report was peer reviewed.

References

- [1] D. Reichman, M.R. Laufer, B.K. Robinson, Pregnancy outcomes in unicornuate uteri: a review, *Fertil. Steril.* 91 (2009) 1886–1894.
- [2] P. Heinonen, Unicornuate uterus and rudimentary horn, *Fertil. Steril.* 68 (1997) 224–230.
- [3] P. Acien, M.I. Acien, The history of female genital tract malformation classifications and proposal of an updated system, *Hum. Reprod. Update* 17 (2011) 693–705.
- [4] P. Acien, Incidence of mullerian defects in fertile and infertile women, *Hum. Reprod.* 12 (1997) 1372–1376.
- [5] G.F. Grimbizis, S. Gordts, A. Di Spiezio Sardo, S. Brucker, C. De Angelis, M. Gergolet, T.C. Li, V. Tanos, H. Brölmann, L. Gianaroli, R. Campo, The ESHRE/ESGE consensus on the classification of female genital tract congenital anomalies, *Hum. Reprod.* 28 (2013) 2032–2044.
- [6] C. Blancafort, B. Graupera, M.A. Pascual, L. Hereter, J.L. Browne, M.T. Cusido, Diagnosis and laparoscopic management of a rudimentary horn pregnancy: role of three-dimensional ultrasound, *J. Clin. Ultrasound* 45 (2017) 112.
- [7] G.G. Nahum, H. Stanislaw, C. McMahon, Preventing ectopic pregnancies: how often does transperitoneal transmigration of sperm occur in effecting human pregnancy? *BJOG* 111 (2004) 706–714.
- [8] A. Tsafirir, N. Rojansky, H.Y. Sela, J.M. Gomori, M. Nadjari, Rudimentary horn pregnancy: first-trimester prerupture sonographic diagnosis and confirmation by magnetic resonance imaging, *J. Ultrasound Med.* 24 (2005) 219–223.
- [9] D. Mavrellos, E. Sawyer, S. Helmy, T.K. Holland, J. Ben-Nagi, D. Jurkovic, Ultrasound diagnosis of ectopic pregnancy in the non-communicating horn of a unicornuate uterus (cornual pregnancy), *Ultrasound Obstet. Gynecol.* 30 (2007) 765–770.
- [10] G.F. Grimbizis, A. Di Spiezio Sardo, S.H. Saravelos, S. Gordts, C. Exacoustos, D. Van Schoubroeck, C. Bermejo, N.N. Amso, G. Nargund, D. Timmermann, A. Athanasiadis, S. Brucker, C. De Angelis, M. Gergolet, T.C. Li, V. Tanos, B. Tarlatzis, R. Farquharson, L. Gianaroli, R. Campo, The Thessaloniki ESHRE/ESGE consensus on diagnosis of female genital anomalies, *Gynecol. Surg.* 13 (2016) 1–16.