

# Clinical Relevance of Bronchial Anthracofibrosis in Patients with Chronic Obstructive Pulmonary Disease Exacerbation

Hyera Kim, M.D.<sup>1</sup>, Seung-Ick Cha, M.D.<sup>1</sup>, Kyung-Min Shin, M.D.<sup>2</sup>, Jae-Kwang Lim, M.D.<sup>2</sup>, Serim Oh, M.D.<sup>1</sup>, Min Jung Kim, M.D.<sup>1</sup>, Yong Dae Lee, M.D.<sup>1</sup>, Miyoung Kim, M.D.<sup>1</sup>, Jaehee Lee, M.D.<sup>1</sup> and Chang-Ho Kim, M.D.<sup>1</sup>

Departments of <sup>1</sup>Internal Medicine and <sup>2</sup>Radiology, Kyungpook National University School of Medicine, Daegu, Korea

**Background:** Bronchial anthracofibrosis (BAF), which is associated with exposure to biomass smoke in inefficiently ventilated indoor areas, can take the form of obstructive lung disease. Patients with BAF can mimic or present with an exacerbation of chronic obstructive pulmonary disease (COPD). The purpose of the current study was to investigate the prevalence of BAF in Korean patients with COPD exacerbation as well as to examine the clinical features of these patients in order to determine its clinical relevance.

**Methods:** A total of 206 patients with COPD exacerbation were divided into BAF and non-BAF groups, according to computed tomography findings. We compared both clinical and radiologic variables between the two groups.

**Results:** Patients with BAF (51 [25%]) were older, with a preponderance of nonsmoking women; moreover, they showed a more frequent association with exposure to wood smoke compared to those without BAF. However, no differences in the severity of illness and clinical course between the two groups were observed. Patients in the BAF group had less severe airflow obstruction, but more common and severe pulmonary hypertension signs than those in the non-BAF group.

**Conclusion:** Compared with non-BAF COPD, BAF may be associated with milder airflow limitation and more frequent signs of pulmonary hypertension with a more severe grade in patients presenting with COPD exacerbation.

**Keywords:** Anthracosis; Biomass; Pulmonary Disease, Chronic Obstructive; Tomography, Spiral Computed; Hypertension, Pulmonary

## Address for correspondence: Seung-Ick Cha, M.D.

Department of Internal Medicine, Kyungpook National University Hospital, 130 Dongdeok-ro, Jung-gu, Daegu 700-721, Korea

Phone: 82-53-200-6412, Fax: 82-53-426-2046

E-mail: sicha@knu.ac.kr

Received: Apr. 27, 2014

Revised: Jul. 1, 2014

Accepted: Jul. 3, 2014

©It is identical to the Creative Commons Attribution Non-Commercial License (<http://creativecommons.org/licenses/by-nc/3.0/>).

Copyright © 2014

The Korean Academy of Tuberculosis and Respiratory Diseases.

All rights reserved.

## Introduction

Bronchial anthracofibrosis (BAF) is characterized by definite narrowing or obliteration of large airways with anthracotic pigmentation in the bronchial mucosa<sup>1</sup>. Although anthracotic pigmentation is caused primarily by the inhalation and deposition of carbon particles along with iron, lead, cadmium and other organic or inorganic materials<sup>2</sup>, BAF is generally not associated with pneumoconiosis or smoking<sup>1</sup>. According to a few recent studies, it has shown a close association with exposure to wood smoke, as a result of burning fuels for cooking and heating, particularly in poorly ventilated spaces<sup>1,3</sup>. Consequently, BAF develops mostly in elderly women<sup>1,3,4</sup>. The original diagnosis of BAF is made when multiple

dark pigmentations are observed on the bronchial mucosa on bronchoscopy<sup>2,3</sup>. On computed tomography (CT) scan, BAF is characterized by multiple lobar or segmental bronchial wall thickening and narrowing combined with surrounding lymph node enlargement with or without atelectasis<sup>1,3-5</sup>.

BAF is frequently associated with tuberculosis, pneumonia, lung cancer, and chronic obstructive pulmonary disease (COPD)<sup>2,3</sup>. In pulmonary function testing (PFT), patients with BAF commonly exhibit obstructive ventilatory impairment<sup>2,3</sup>. Data from recent meta-analyses consistently demonstrated that biomass smoke, including wood smoke exposure, is a risk factor for COPD<sup>6-8</sup>. Therefore, there is a possibility that patients with BAF could be diagnosed as COPD alone, if not undergoing further evaluation for BAF. In South Korea, BAF is frequently recognized in clinical practice, and several studies regarding BAF in Korean patients have been published<sup>1,3-5</sup>. We hypothesized that a proportion of patients with COPD exacerbation might have BAF, not just COPD in Korea. The aim of the present study was to investigate the prevalence of BAF in patients with COPD exacerbation and to examine the clinical features of these patients.

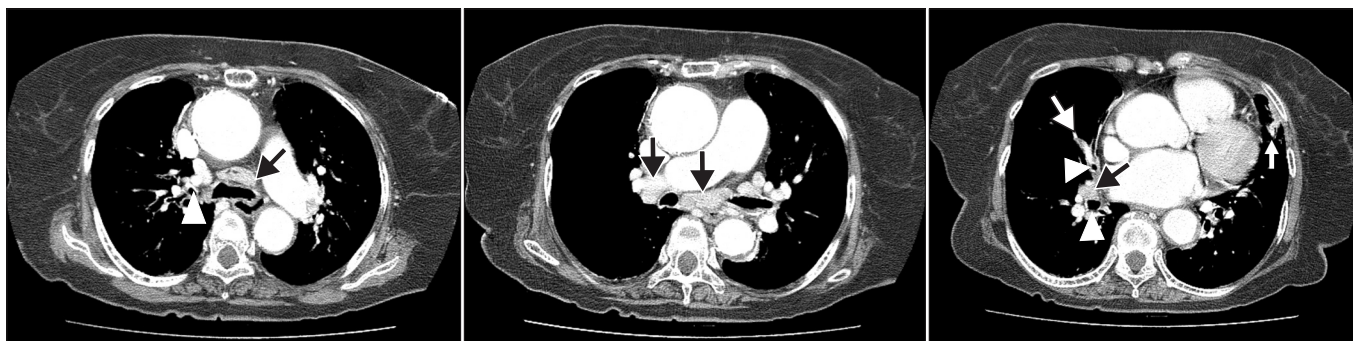## Materials and Methods

### 1. Patients

Between August 2008 and April, 2012, a cohort of COPD exacerbation hospitalized to the Kyungpook National University Hospital (KNUH), a tertiary referral center (Daegu, Korea) were analyzed retrospectively. This study was approved by the Institutional Review Board of the KNUH, which waived the requirement for written informed consent because of the retrospective nature of the study. According to the criteria of the Global Initiative for Chronic Obstructive Lung Diseases<sup>9</sup>, COPD was diagnosed on the basis of the available spirometric data. COPD exacerbation was defined as acute deterioration from a stable state requiring hospitalization<sup>10</sup>. On arrival at the

hospital, evaluation of patients was performed by emergency or internal medicine department physicians through history taking, physical examination, chest radiographs, and routine laboratory tests. Patients with any specific causes identified on these examinations, including pneumonia, pneumothorax, and congestive heart failure, were excluded. After exclusion, all patients underwent chest CT scan with or without contrast enhancement within 24 hours of admission to the hospital. Based on CT findings, cases with other causes which could result in lymph node enlargement, such as lung cancer and interstitial lung diseases, were also excluded. The etiology of COPD exacerbations was determined as follows: 1) pneumonia was diagnosed when consolidation or focal ground-glass opacity (GGO) was observed on CT scan; 2) tracheobronchitis if symptoms suggestive of respiratory infection, including increased sputum, purulent sputum, fever, or symptoms of upper respiratory infection (sore throat or rhinorrhea with myalgia) were identified without consolidation or focal GGO on CT scan or if centrilobular nodule or a tree-in-bud pattern suggestive of bronchiolitis was observed on CT imaging without consolidation or GGO; 3) congestive heart failure, when CT findings suggestive of pulmonary edema and echocardiographic left ventricular dysfunction coexisted<sup>11</sup>; 4) similar to an earlier study<sup>12</sup>, pulmonary embolism on CT scan as a sharply delineated pulmonary arterial filling defect present in at least two consecutive image sections and located centrally within the vessel or with acute angles at its interface with the vessel wall; and 5) undetermined, when the etiology could not be determined.

The diagnosis of BAF was based on the CT findings that fulfilled the following criteria: 1) bronchostenosis that caused smooth narrowing of multiple lobar or segmental bronchi; 2) calcified or non-calcified lymph node enlargement adjacent to narrowed bronchi; and 3) these two criteria which could not be attributed to other causes (Figure 1)<sup>4,5</sup>. All patients were classified into patients with BAF (BAF group) and without BAF (non-BAF group) according to the presence or absence of CT findings consistent with BAF. A variety of clinical variables



**Figure 1.** On the computed tomography scan, bronchial anthracofibrosis is characterized by smooth narrowing and thickening of multiple lobar or segmental bronchi (white arrowheads) and calcified lymph node enlargement adjacent to the narrowed bronchi (black arrows) with or without lobar or segmental atelectasis (white arrow).

and CT findings were compared between the two groups.

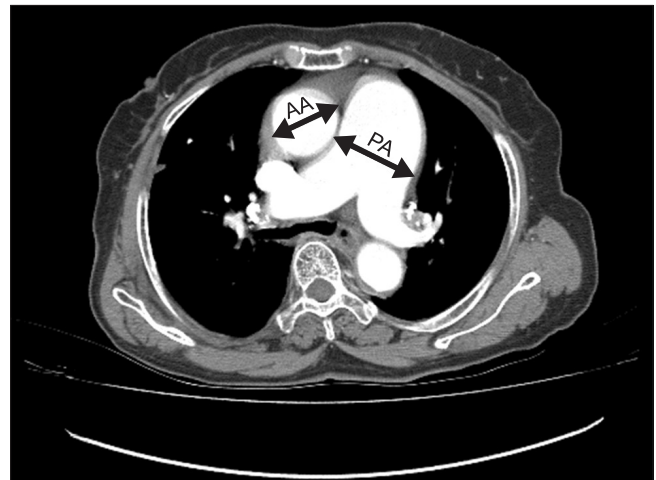
## 2. Clinical data

Demographic and clinical variables of the patients were checked, including gender, age, smoking history, body mass index, and comorbid conditions. History of exposure to wood smoke and its duration was retrospectively taken by an interviewer over the phone. For severity of illness, BAP-65 classes were assessed<sup>13</sup>. BAP-65 score was defined as follows: class I, patients  $\leq 65$  years of age without any three risk factors (blood urea nitrogen level  $\geq 25$  mg/dL, altered mental status, or pulse  $\geq 109$  beats/min); class II, patients  $> 65$  years of age with no risk factors; and class III, IV, and V, patients with one, two, and three risk factors, respectively. With respect to clinical course, hospital stay and treatment outcome (improvement, transfer, or death) were recorded.

PFT data were obtained according to the standards of the American Thoracic Society and European Respiratory Society Guideline<sup>14</sup>. Spirometric data within six months before and after index admission date for comparison of airflow obstruction between the BAF and non-BAF groups were used in statistical analysis. Laboratory data included white blood cell (WBC) count, erythrocyte sedimentation rate (ESR), C-reactive protein (CRP), procalcitonin, N-terminal-pro-B-type natriuretic peptide (NT-proBNP), troponin I, D-dimer, and arterial blood gas analysis data.

## 3. Radiologic data

CT scans were reviewed by two radiologists and a consensus diagnosis was reached. In addition to the presence of BAF, we checked for the presence of consolidation, GGO, bronchiolitis, emphysema, bronchiectasis, bronchial wall thickening, pleural effusion, and inactive pulmonary tuberculosis. These CT findings were defined as follows: consolidation as airspace opacification with obscuration of the underlying vasculature<sup>15</sup>; GGO as less densely increased attenuation without obscuration of the underlying vasculature<sup>15</sup>; bronchiolitis as centrilobular nodules with either V- or Y-shaped branching linear opacities<sup>16</sup>; emphysema characterized by the presence of areas of abnormally low attenuation near the center of the secondary pulmonary lobule or diffuse areas of low attenuation with little intervening normal lung<sup>17</sup>; bronchiectasis when the internal diameter of the bronchus was greater than that of the adjacent pulmonary artery (PA); and inactive pulmonary tuberculosis when irregular lines and calcified nodules along with distortion of bronchovascular bundles were located in upper lobes and superior segments of lower lobes<sup>18</sup>. The presence of bronchial wall thickening was considered when radiologists initially suspected the presence of bronchiectasis at 5th or 6th generation bronchi but then, on comparing the caliber of the bronchus to the adjacent artery, determined that there was no bronchial



**Figure 2.** The diameter of the main pulmonary artery (PA) and the diameter of the ascending aorta (AA) are measured at the level of the PA bifurcation.

dilatation<sup>19</sup>. Thus, the bronchus looked more prominent than normal without features of bronchiectasis.

To determine the prevalence of pulmonary hypertension, we measured main PA size and PA-to-ascending aorta (AA) ratio. Similar to previous studies<sup>20,21</sup>, we measured the diameters of PA and AA at the level of the PA bifurcation in order to obtain PA size and PA-to-AA ratio (Figure 2). The widest short axis diameter of the PA and the diameter of AA in its longest diameter were measured using computer calipers. As in previous studies, PA size  $> 33$  mm<sup>21</sup> and PA-to-AA ratio  $> 1$ <sup>22</sup> were selected as the cutoff values for pulmonary hypertension.

## 4. Echocardiography

Transthoracic echocardiographic findings, including right ventricular (RV) dysfunction and RV systolic pressure (RVSP), were also reviewed. RV dysfunction was defined as RV free wall hypokinesia, and RVSPs were calculated using tricuspid regurgitation flow velocity as determined by Doppler echocardiography<sup>23</sup>. RVSP  $> 40$  mm Hg was selected as the cutoff value for pulmonary hypertension.

## 5. Statistical analysis

SPSS ver. 12.0 (SPSS Inc., Chicago, IL, USA) was used in performance of statistical analyses. The data are expressed as the mean  $\pm$  standard deviation or median with interquartile range (IQR), if the data were skewed for continuous variables and number with percentage for categorical variables. Kappa statistic was used for measurement of the agreement between bronchoscopy and CT in determining the presence of BAF. Between the two groups, continuous variables were compared using the Student's t-test or the Mann-Whitney U test,

whereas categorical variables were compared using either chi-squared test or Fisher's exact test.

## Results

### 1. Demographic and clinical characteristics

Blinded to bronchoscopic finding, radiologists determined

the presence or absence of BAF based on CT findings in 30 patients for whom both bronchoscopic results and CT images were available. Kappa statistic for diagnosing was 0.933 between bronchoscopy and CT. Initially, 209 patients were included in this study but three were excluded due to stage III or IV lung cancer (n=2) or pneumoconiosis (n=1). Consequently, a total of 206 patients were included in the final analysis and 51 (25%) were diagnosed as having BAF based on CT scan.

Patients with BAF were significantly older (78±7.6 years vs.

**Table 1.** Clinical characteristics of patients (n=206)

	BAF (n=51)	Non-BAF (n=155)	p-value
Age, yr	78±7.6	71±9.8	<0.001
Female	31 (61)	35 (23)	<0.001
Never-smoker	26/50 (52)	28/155 (18)	<0.001
Pack-years	40 (30–50)	45 (30–60)	0.358
Wood smoke exposure	20/34 (59)	27/99 (27)	0.001
Duration, yr	30 (25–40)	20 (7–30)	0.018
Body mass index, kg/m <sup>2</sup>	23 (20–26)	21 (19–24)	0.069
Comorbidities			
Diabetes	12 (24)	20 (13)	0.069
Hypertension	21 (41)	54 (35)	0.415
Ischemic heart disease	3 (6)	15 (10)	0.571
Congestive heart failure	3 (6)	8 (5)	1.000
Atrial flutter or fibrillation	4 (8)	5 (3)	0.229
Stroke	1 (2)	5 (3)	1.000
Chronic liver disease	0 (0)	4 (2.6)	0.574
Chronic kidney disease	0 (0)	1 (0.6)	1.000
Hyperlipidemia	0 (0)	1 (0.6)	1.000
Past history of tuberculosis	10 (20)	29 (19)	0.887
Symptoms of respiratory infection	37 (73)	140 (90)	0.002
BAP-65 score	2 (2–3)	2 (2–3)	0.842
Causes of COPD exacerbation			
Tracheobronchitis	30 (59)	94 (61)	
Pneumonia	9 (18)	46 (30)	
Pulmonary embolism	2 (4)	3 (2)	
Left heart failure	1 (2)	2 (1)	
Unknown causes	9 (18)	10 (7)	
Treatment outcome			
Improvement	46 (90)	143 (92)	0.313
Death	2 (4)	9 (6)	
Transfer	3 (6)	3 (2)	

Values are presented as mean±standard deviation, median (interquartile range), number (%) or number/number (%).

BAP-65, severity of illness score based on the presence of blood urea nitrogen≥24 mg/dL, altered mental status, pulse≥109 beats/min, or age>65 years.

BAF: bronchial anthracofibrosis; COPD: chronic obstructive pulmonary disease.

**Table 2. Laboratory and spirometric data**

	No.	BAF	No.	Non-BAF	p-value
White blood cell count, / $\mu$ L	51	10,976 $\pm$ 4,528	155	11,943 $\pm$ 5,215	0.238
CRP, mg/dL	51	1.37 (0.37–9.46)	154	3.56 (0.75–11.49)	0.096
ESR, mm/hr	47	25 (16–38)	150	31 (17–55)	0.164
Procalcitonin, ng/mL	45	0.05 (0.05–0.11)	116	0.06 (0.05–0.26)	0.052
NT-proBNP, pg/mL	50	425 (133–1,666)	148	207 (93–755)	0.018
Troponin-I, ng/mL	48	0.04 (0.04–0.12)	147	0.04 (0.04–0.07)	0.321
D-dimer, $\mu$ g/L	43	239 (100–518)	135	224 (122–369)	0.817
Serum sodium, mEq/L	51	140 $\pm$ 4.1	155	138 $\pm$ 5.5	0.051
Serum albumin, g/dL	51	3.8 (3.4–4.1)	155	3.8 (3.4–4.1)	0.953
PaO <sub>2</sub> , mm Hg	50	77 (65–94)	153	76 (65–93)	0.751
PaO <sub>2</sub> /FiO <sub>2</sub>	50	345 (271–401)	153	323 (264–376)	0.267
Postbronchodilator FEV <sub>1</sub> /FVC, %	26	54 $\pm$ 13.6	113	43 $\pm$ 13.7	0.001
Postbronchodilator FEV <sub>1</sub> , % pred.	26	78 $\pm$ 28.3	113	59 $\pm$ 24.3	<0.001

Values are presented as mean $\pm$ standard deviation or median (interquartile range).

BAF: bronchial anthracofibrosis; CRP: C-reactive protein; ESR: erythrocyte sedimentation rate; NT-proBNP: N-terminal-pro-B-type natriuretic peptide; FEV<sub>1</sub>: forced expiratory volume in 1 second; FVC: forced vital capacity.

71 $\pm$ 9.8 years,  $p$ <0.001) with female preponderance (61% vs. 23%,  $p$ <0.001) (Table 1). The BAF group included more never-smokers than the non-BAF group (52% vs. 18%,  $p$ <0.001). As expected, history of exposure to wood smoke was significantly more common in the BAF group, compared to the non-BAF group (59% vs. 27%,  $p$ =0.001). Symptoms suggestive of respiratory infection were observed less frequently in the BAF group than the non-BAF group (73% vs. 90%,  $p$ =0.001). No difference in BAP-65 class was observed between the two groups. In addition, no significant differences in length of hospital stay and treatment outcome were observed between the two groups.

Respiratory tract infection, including tracheobronchitis and pneumonia, was the most common cause of COPD exacerbation in both groups, however, its frequency was significantly lower in the BAF group, compared with the non-BAF group (77% vs. 90%,  $p$ =0.011) (Table 1). Conversely, patients with unknown cause were more common in the BAF group, compared with the non-BAF group (18% vs. 7%,  $p$ =0.017).

## 2. Laboratory and spirometric data

Peripheral blood WBC count and blood levels of ESR, CRP, procalcitonin, troponin-I, and D-dimer did not differ significantly between the two groups (Table 2). However, significantly higher serum level of NT-proBNP was observed, compared with the non-BAF group (425 pg/mL [IQR, 133–1,666 pg/mL] vs. 207 pg/mL [IQR, 93–755 pg/mL],  $p$ =0.018). Postbronchodilator values of percent predicted forced expiratory volume in 1 second (FEV<sub>1</sub>) and FEV<sub>1</sub>/forced vital capacity were significantly higher in the BAF group, compared with the non-

BAF group (78 $\pm$ 28.3% vs. 59 $\pm$ 24.3%,  $p$ <0.001; and 54 $\pm$ 13.6% vs. 43 $\pm$ 13.7%,  $p$ =0.001, respectively), suggesting that patients with BAF had less severe airflow obstruction than those without BAF.

## 3. Computed tomographic and echocardiographic findings

Of various CT findings, frequencies of emphysema and bronchial wall thickening were significantly greater in the non-BAF group, compared with the BAF group (80% vs. 33%,  $p$ <0.001; and 92% vs. 73%,  $p$ <0.001, respectively) (Table 3). The frequencies of the remaining CT findings did not differ between the two groups. Both PA size and PA-to-AA ratio were significantly greater in the BAF group, compared with the non-BAF group (35 $\pm$ 5.5 vs. 31 $\pm$ 5.0,  $p$ <0.001; and 0.95 $\pm$ 0.15 vs. 0.85 $\pm$ 0.13,  $p$ <0.001, respectively). The frequencies of patients with PA size>33 mm and PA-to-AA ratio >1 were significantly higher in the BAF group, compared with the non-BAF group (59% vs. 28%,  $p$ <0.001; and 43% vs. 11%,  $p$ <0.001).

Echocardiographic pulmonary hypertension was frequently observed in the BAF group, as compared with the non-BAF group (50% [6/12] vs. 18% [6/33],  $p$ =0.033), although echocardiographic data were available in the minority of the patients.

## Discussion

In the current study, approximately 25% of Korean patients with COPD exacerbation had CT findings consistent with BAF. The current data demonstrated that in Korea, BAF is common

**Table 3.** Computed tomographic and echocardiographic findings

	BAF (n=51)	Non-BAF (n=155)	p-value
CT findings			
Emphysema	17 (33)	124 (80)	<0.001
Bronchiectasis	4 (8)	15 (10)	1.000
Bronchial wall thickening	37 (73)	143 (92)	<0.001
Bronchiolitis	9 (18)	18 (12)	0.268
Ground glass opacity	2 (4)	9 (6)	1.000
Consolidation	11 (22)	46 (30)	0.262
Pleural effusion	9 (18)	13 (8)	0.063
Inactive pulmonary tuberculosis	12 (24)	43 (28)	0.555
Pulmonary embolism	3 (6)	4 (3)	0.368
Diameter of main pulmonary artery, mm	35±5.5	31±5.0	<0.001
Diameter of main pulmonary artery>33 mm	30 (59)	44 (28)	<0.001
PA-to-AA ratio	0.95±0.15	0.85±0.13	<0.001
PA-to-AA ratio>1	22 (43)	17 (11)	<0.001
Echocardiography			
RVSP	38 (23–48)	30 (24–34)	0.441
RVSP>40 mm Hg	6/12 (50)	6/33 (18)	0.033
RV dysfunction	1/13 (8)	2/34 (6)	1.000

Values are presented as mean±standard deviation, median (interquartile range) or number (%).

BAF: bronchial anthracofibrosis; CT: computed tomography; PA-to-AA ratio: ratio of diameter of main pulmonary artery and diameter of ascending aorta; RVSP: right ventricular systolic pressure; RV: right ventricular.

in nonsmoking elderly women and that among patients presenting with COPD exacerbation, the severity of illness and clinical course are similar regardless of BAF. Of note, patients with BAF had milder airflow limitation, compared to those without BAF. However, signs of pulmonary hypertension were more common with a more severe grade in the BAF group, compared with the non-BAF group.

In developing countries, such as Mexico and Columbia, where biomass fuel has been used for heating and cooking in poorly ventilated spaces, a considerable number of patients with obstructive airway disease, particularly in nonsmoking elderly females, are caused by exposure to wood smoke<sup>3,24,25</sup>. Nowadays, biomass smoke is considered an independent risk factor for COPD<sup>6,7</sup>. In the current study, BAF was suspected in a quarter of patients presenting with COPD exacerbation. Patients with BAF who do not undergo bronchoscopy or chest CT scan can be diagnosed as having only COPD. Symptoms suggestive of respiratory infection were noted less frequently in the BAF group, compared with the non-BAF group. Thus, patients with unknown causes of COPD exacerbation were more common in the BAF group. One explanation is that BAF was found in older patients, who were less likely to recognize their respiratory symptoms. However, the possibility of other undetected causes of COPD exacerbation could not be ex-

cluded.

Patients with BAF had less severe airflow limitation, compared to those without BAF. This finding corresponds to the previous report<sup>24</sup>. This could not be exactly explained. On CT scan, BAF is characterized by stenosis of larger airways and less frequent peripheral bronchial wall thickening, compared to non-BAF COPD. In contrast, emphysema was observed less frequently in the BAF group. This finding concurred with that of a previous study showing that pathologically, emphysema was more severe in the cigarette smoke-induced COPD group, compared to the biomass smoke group<sup>26</sup>. In addition, patients with BAF can exhibit a mixed restrictive-obstructive pattern in addition to obstructive defect<sup>3</sup>. These findings suggest that the disease entity of BAF may be different from that of non-BAF COPD.

It is noteworthy that the BAF group more frequently had signs of pulmonary hypertension and more severe degree of pulmonary hypertension than the non-BAF group. This is in an agreement with a necropsy finding where intimal thickening was more severe in the biomass smoke-induced COPD group, compared with the cigarette smoke-induced COPD group<sup>26</sup>. As more fibrosis is microscopically observed in the lung parenchyma as well as in the walls of the airways of COPD patients exposed to biomass smoke<sup>26</sup>, fibrosis of the

lung parenchyma can promote the occurrence of pulmonary hypertension. However, evidence of lung parenchymal fibrosis was not observed on CT of the BAF group in the present study. We speculate that extrinsic compression of pulmonary arteries by adjacent peribronchial fibrosis of larger airways may contribute to more common and severe pulmonary hypertension in patients with BAF like fibrosing mediastinitis<sup>27</sup>. However, this finding was not noted on CT of the BAF group.

Whether BAF is a phenotype of COPD or a distinct entity remains to be clarified. Biomass smoke, such as wood smoke, is considered a risk factor for COPD. However, BAF is thought to be one end of the spectrum of wood smoke-induced lung diseases<sup>28</sup>. BAF is characterized by radiologically bronchial narrowing and thickening of larger airways, physiologically less severe airflow limitation, and hemodynamically more severe and common pulmonary hypertension, suggesting that the pathogenesis of BAF may differ from that of tobacco smoke-related COPD which results from a mixture of small airway disease and parenchymal destruction.

Several limitations of the current study should be considered. First, although bronchoscopy is needed to confirm BAF, the diagnosis was based on CT findings in this study. However, the CT findings of BAF are well-established, and agreement rate between bronchoscopy and CT scan in diagnosis of BAF was high for 30 patients whose bronchoscopic data were available. Second, as this study was retrospective, some clinical data were not available. Thus, selection bias could not be avoided. Third, history of exposure to wood smoke and its duration was taken by an interviewer over the phone. Recall bias should be considered. Finally, as our criteria for tracheo-bronchitis and pneumonia were broad, there is a possibility that the frequencies were overestimated.

In conclusion, BAF should be considered in Korean patients with presenting with COPD exacerbation, particularly in non-smoking elderly females with a history of exposure to wood smoke. Compared with non-BAF COPD, BAF is characterized by less frequent emphysema and bronchial wall thickening on CT scan, less severe airflow limitation, and more common pulmonary hypertension with a greater degree of severity. From these results, BAF is a distinct phenotype of obstructive lung disease.

## Acknowledgements

This research was supported by Kyungpook National University Research Fund, 2012.

## Conflict of Interest

No potential conflict of interest relevant to this article was reported.

## References

1. Chung MP, Lee KS, Han J, Kim H, Rhee CH, Han YC, et al. Bronchial stenosis due to anthracofibrosis. *Chest* 1998;113:344-50.
2. Gupta A, Shah A. Bronchial anthracofibrosis: an emerging pulmonary disease due to biomass fuel exposure. *Int J Tuberc Lung Dis* 2011;15:602-12.
3. Kim YJ, Jung CY, Shin HW, Lee BK. Biomass smoke induced bronchial anthracofibrosis: presenting features and clinical course. *Respir Med* 2009;103:757-65.
4. Kim HY, Im JG, Goo JM, Kim JY, Han SK, Lee JK, et al. Bronchial anthracofibrosis (inflammatory bronchial stenosis with anthracotic pigmentation): CT findings. *AJR Am J Roentgenol* 2000;174:523-7.
5. Park HJ, Park SH, Im SA, Kim YK, Lee KY. CT differentiation of anthracofibrosis from endobronchial tuberculosis. *AJR Am J Roentgenol* 2008;191:247-51.
6. Hu G, Zhou Y, Tian J, Yao W, Li J, Li B, et al. Risk of COPD from exposure to biomass smoke: a metaanalysis. *Chest* 2010;138:20-31.
7. Kurmi OP, Semple S, Simkhada P, Smith WC, Ayres JG. COPD and chronic bronchitis risk of indoor air pollution from solid fuel: a systematic review and meta-analysis. *Thorax* 2010;65:221-8.
8. Po JY, FitzGerald JM, Carlsten C. Respiratory disease associated with solid biomass fuel exposure in rural women and children: systematic review and meta-analysis. *Thorax* 2011;66:232-9.
9. Rabe KF, Hurd S, Anzueto A, Barnes PJ, Buist SA, Calverley P, et al. Global strategy for the diagnosis, management, and prevention of chronic obstructive pulmonary disease: GOLD executive summary. *Am J Respir Crit Care Med* 2007;176:532-55.
10. Tillie-Leblond I, Marquette CH, Perez T, Scherpereel A, Zanetti C, Tonnel AB, et al. Pulmonary embolism in patients with unexplained exacerbation of chronic obstructive pulmonary disease: prevalence and risk factors. *Ann Intern Med* 2006;144:390-6.
11. Abroug F, Ouanes-Besbes L, Nciri N, Sellami N, Addad E, Hamda KB, et al. Association of left-heart dysfunction with severe exacerbation of chronic obstructive pulmonary disease: diagnostic performance of cardiac biomarkers. *Am J Respir Crit Care Med* 2006;174:990-6.
12. Lee JW, Cha SI, Jung CY, Choi WI, Jeon KN, Yoo SS, et al. Clinical course of pulmonary embolism in lung cancer patients. *Respiration* 2009;78:42-8.
13. Shorr AF, Sun X, Johannes RS, Yaitanes A, Tabak YP. Validation of a novel risk score for severity of illness in acute exacerbations of COPD. *Chest* 2011;140:1177-83.
14. Miller MR, Hankinson J, Brusasco V, Burgos F, Casaburi R, Coates A, et al. Standardisation of spirometry. *Eur Respir J* 2005;26:319-38.

15. Nambu A, Saito A, Araki T, Ozawa K, Hiejima Y, Akao M, et al. *Chlamydia pneumoniae*: comparison with findings of *Mycoplasma pneumoniae* and *Streptococcus pneumoniae* at thin-section CT. *Radiology* 2006;238:330-8.
16. Pipavath SJ, Lynch DA, Cool C, Brown KK, Newell JD. Radiologic and pathologic features of bronchiolitis. *AJR Am J Roentgenol* 2005;185:354-63.
17. Thurlbeck WM, Muller NL. Emphysema: definition, imaging, and quantification. *AJR Am J Roentgenol* 1994;163:1017-25.
18. Lee KS, Im JG. CT in adults with tuberculosis of the chest: characteristic findings and role in management. *AJR Am J Roentgenol* 1995;164:1361-7.
19. Miller WT Jr, Barbosa E Jr, Mickus TJ, Mullin C, Van Deerlin VM, Shiley KT. Chest computed tomographic imaging characteristics of viral acute lower respiratory tract illnesses: a case-control study. *J Comput Assist Tomogr* 2011;35:524-30.
20. Wells JM, Washko GR, Han MK, Abbas N, Nath H, Mamary AJ, et al. Pulmonary arterial enlargement and acute exacerbations of COPD. *N Engl J Med* 2012;367:913-21.
21. Devaraj A, Wells AU, Meister MG, Corte TJ, Wort SJ, Hansell DM. Detection of pulmonary hypertension with multidetector CT and echocardiography alone and in combination. *Radiology* 2010;254:609-16.
22. Edwards PD, Bull RK, Coulden R. CT measurement of main pulmonary artery diameter. *Br J Radiol* 1998;71:1018-20.
23. McQuillan BM, Picard MH, Leavitt M, Weyman AE. Clinical correlates and reference intervals for pulmonary artery systolic pressure among echocardiographically normal subjects. *Circulation* 2001;104:2797-802.
24. Ramirez-Venegas A, Sansores RH, Perez-Padilla R, Regalado J, Velazquez A, Sanchez C, et al. Survival of patients with chronic obstructive pulmonary disease due to biomass smoke and tobacco. *Am J Respir Crit Care Med* 2006;173:393-7.
25. Dennis RJ, Maldonado D, Norman S, Baena E, Martinez G. Woodsmoke exposure and risk for obstructive airways disease among women. *Chest* 1996;109:115-9.
26. Rivera RM, Cosio MG, Ghezzi H, Salazar M, Perez-Padilla R. Comparison of lung morphology in COPD secondary to cigarette and biomass smoke. *Int J Tuberc Lung Dis* 2008;12:972-7.
27. McCann C, Gopalan D, Sheares K, Screatton N. Imaging in pulmonary hypertension, part 2: Large vessel diseases. *Postgrad Med J* 2012;88:317-25.
28. Sandoval J, Salas J, Martinez-Guerra ML, Gomez A, Martinez C, Portales A, et al. Pulmonary arterial hypertension and cor pulmonale associated with chronic domestic woodsmoke inhalation. *Chest* 1993;103:12-20.