



# Oral histiocytic sarcoma in a cat with mandibular invasion and regional lymph node metastasis

Stephani L Ruppert<sup>1</sup>, Sylvia H Ferguson<sup>1</sup> ,  
 Jason D Struthers<sup>1</sup>  and Teela L Jones<sup>2</sup> 

*Journal of Feline Medicine and Surgery Open Reports*  
 1–6

© The Author(s) 2021

Article reuse guidelines:

sagepub.com/journals-permissions

DOI: 10.1177/20551169211058044

journals.sagepub.com/home/jfmsopenreports

This paper was handled and processed by the American Editorial Office (AAFP) for publication in *JFMS Open Reports*



## Abstract

**Case summary** An 11-year-old female spayed domestic medium-hair cat presented for dental prophylaxis, at which time no oral mass was appreciated. Fifteen days after a dental cleaning, a mass expanding the oral mucosa of the rostral mandible was identified. An incisional biopsy revealed that the oral mucosa was infiltrated by neoplastic round-to-spindloid mesenchymal cells arranged in streams and small, dense aggregates consistent with an undifferentiated sarcoma. The patient was managed medically for approximately 6 months following the diagnosis, but, owing to declining health, euthanasia was elected and a post-mortem examination was performed. On post-mortem examination, the previously described neoplastic cells were infiltrating the rostral mandible and had metastasized to the right submandibular lymph node. Immunohistochemistry performed during the postmortem examination found that neoplastic cells were positive for Iba-1, CD18 and CD204, and negative for MUM-1, S100, Melan-A and E-cadherin, favoring a diagnosis of oral histiocytic sarcoma. Although recently recognized in cats, feline oral histiocytic sarcoma is rare, the tumor's immunohistochemical profile is unstandardized, and the tumor's behavior and prognosis are unclear. The diagnosis is challenging if small incisional biopsies are submitted and the neoplasm is poorly differentiated. This case report discusses the clinical, macroscopic, microscopic and immunohistochemical features of oral histiocytic sarcoma in a cat with mandibular invasion and submandibular lymph node metastasis.

**Relevance and novel information** Feline primary oral histiocytic sarcoma is rare and tumor behavior and prognosis are unclear. This report broadens the immunohistochemical features of the tumor and recognizes mandibular invasion and submandibular lymph node metastasis.

**Keywords:** Histiocytic sarcoma; immunohistochemistry; metastasis; oral neoplasia; undifferentiated sarcoma

**Accepted:** 19 October 2021

## Case description

An 11-year-old female spayed domestic medium-hair cat was presented for dental prophylaxis and extractions owing to grade 4 dental disease. It had a mildly elevated respiratory effort associated with a previously diagnosed congenital peritoneopericardial diaphragmatic hernia. On physical examination, there was an intermittent systolic murmur. A cardiology consultation noted no structural or functional cardiac abnormalities. Preoperative blood work was normal except for a mild lymphopenia  $1.3 \times 10^9$  (reference interval  $1.5\text{--}7.00 \times 10^9$ ), which was considered insignificant. Owing to the patient's fractious temperament,

gabapentin (50 mg PO) was administered 1 h before appointments. During the dental procedure, 15 teeth

<sup>1</sup>Department of Pathology and Population Medicine, Midwestern University, Glendale, AZ, USA

<sup>2</sup>Department of Specialty Medicine, Midwestern University, Glendale, AZ, USA

### Corresponding author:

Sylvia H Ferguson DVM, PhD, DACVP, Department of Pathology and Population Medicine, Midwestern University College of Veterinary Medicine, 5725 West Utopia Drive, Glendale, AZ 83508, USA

Email: sfergu@midwestern.edu



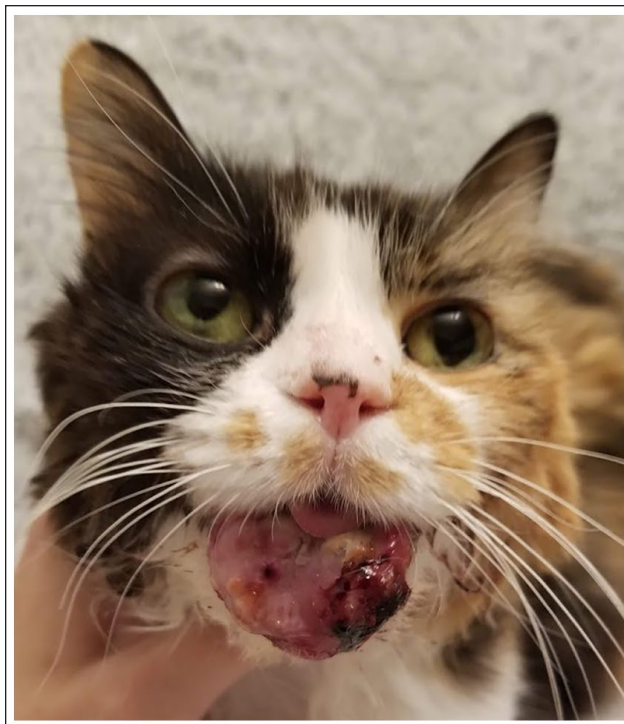Creative Commons Non Commercial CC BY-NC: This article is distributed under the terms of the Creative Commons

Attribution-NonCommercial 4.0 License (<https://creativecommons.org/licenses/by-nc/4.0/>) which permits non-commercial use, reproduction and distribution of the work without further permission provided the original work is attributed as specified on the SAGE and Open Access pages (<https://us.sagepub.com/en-us/nam/open-access-at-sage>).

were extracted or had crown amputations, leaving four upper incisors and two upper molars remaining. No masses or other abnormalities were noted on dental radiographs. Robenacoxib (Onsior; Elanco) and buprenorphine (Simbadol; Zoetis) were prescribed for 3 days for analgesia. Fifteen days post-procedure, the owner noticed a small, red swelling extending from the gingiva to the mucocutaneous junction on the rostral portion of the mandible. At the recheck appointment 21 days post-procedure, the cat was sedated for a more thorough examination of the swelling. Dental radiographs were performed, and a fine-needle aspirate and an incisional biopsy were obtained. Dental radiographs showed a soft tissue swelling of the rostral mandible.

Cytology of the aspirate identified large numbers of spindloid-to-rounded mesenchymal cells with moderate anisocytosis and anisokaryosis. A few of the mesenchymal cells were described as having a plasmacytoid appearance. The incisional biopsy of the rostral mandibular soft tissue swelling was  $0.5 \times 0.2 \times 0.1$  cm, homogeneously tan in color and firm. Microscopically, abutting intact lamina epithelialis mucosa, the lamina propria was infiltrated by neoplastic round-to-spindloid mesenchymal cells arranged in streams and small, dense aggregates that were unencapsulated and supported by pre-existing collagen. Cells had variably distinct cell borders, an oval-to-indentated, occasionally eccentrically located, nucleus with vesicular chromatin and 1–2 variably distinct nucleoli, and small-to-moderate amounts of eosinophilic, vacuolated cytoplasm. Additionally, some cells had subtle paranuclear clearing. The neoplastic cells exhibited mild nuclear pleomorphism, moderate anisocytosis and anisokaryosis, and the mitotic count was 10 mitoses per 10 high power ( $\times 400$ ) fields. Immunohistochemistry for cytokeratin (AE1/AE3) was negative, ruling out an epithelial origin of the neoplastic cells. The final diagnosis was sarcoma, and plasmacytoma and lymphoma were listed as possible differential diagnoses. In lieu of additional immunohistochemistry, a second opinion by a board-certified pathologist specializing in oral pathology was requested. The second opinion, final diagnosis was round cell neoplasm (favored plasmacytoma). Further immunohistochemistry was declined.

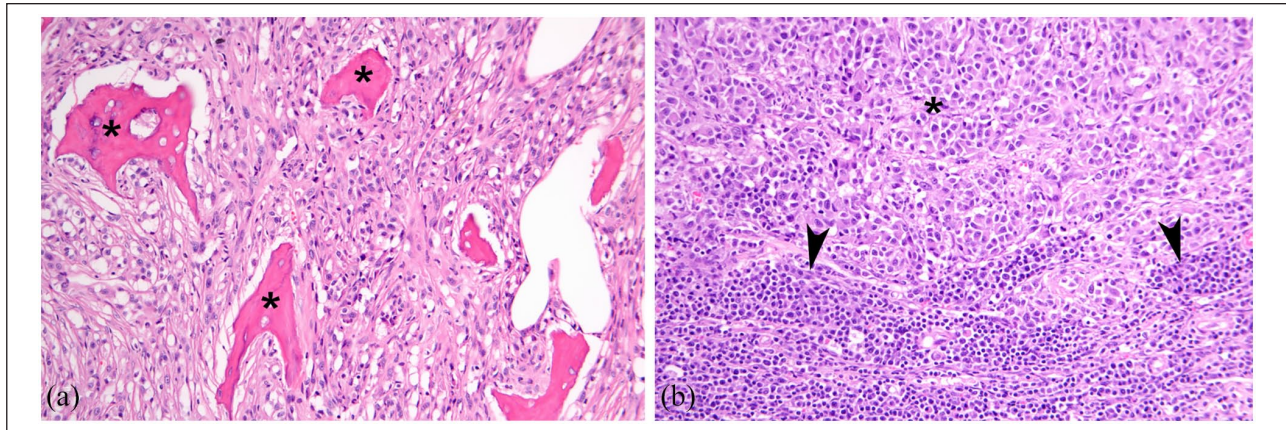
Owing to the poor prognosis for long-term survival and potential complications of mandibulectomy in cats, the owner elected for palliative care. Prednisolone (2mg/kg per day PO [Compounded; Roadrunner Pharmacy]) was prescribed and the patient was given buprenorphine (Simbadol; Zoetis) as needed for pain management. The mass grew rapidly over 6 months, with moderate amounts of hemorrhage. Euthanasia was elected when the cat was dysphagic and appeared uncomfortable 195 days after the initial dental procedure (180 days after the owner's initial observation of the mass).



**Figure 1** Oral histiocytic sarcoma in a cat. Infiltrative mass arising from the oral mucosa of the rostral mandible and extending to the right ventral tongue. The mass is irregular, tan, firm and ulcerated, with areas of previous hemorrhage

On gross examination of the oral cavity, there was an irregular  $3.0 \times 2.5 \times 1.5$  cm, firm, ulcerated, tan-to-dark red (previous hemorrhage) infiltrative mass arising from the right rostral mandibular gingiva, invading and expanding the rostral portion of the right mandible, and extending to the right ventral aspect of the tongue (Figure 1). All teeth were absent except the right and left maxillary molars and incisors. The right submandibular lymph node was firm and on cut section there was a focal 0.3cm diameter tan nodule obliterating the parenchyma. Aside from the oral mass, additional postmortem findings included peritoneopericardial hernia and unilateral renal lymphoplasmacytic interstitial nephritis and fibrosis. All other organ systems were grossly unremarkable. Samples of the oral mass, right mandible, tongue, mucocutaneous junction of the mass, right submandibular lymph node, liver, lungs, adrenal glands, stomach, small and large intestines, kidneys, brain, urinary bladder, heart, spleen and pancreas were placed in 10% neutral buffered formalin, processed routinely, paraffin embedded, sectioned at  $4\mu\text{m}$  and stained with hematoxylin and eosin.

Microscopically, the oral neoplasm was invasive and consisted of poorly differentiated, spindloid-to-round cells arranged in streams, bundles and occasionally sheets. Within the sections of the mandible and right



**Figure 2** Oral histiocytic sarcoma in a cat. (a) Neoplastic cells invade, separate and replace the bony trabeculae (asterisks) of the mandible (hematoxylin and eosin). (b) Neoplastic cells (asterisk) invade the right submandibular lymph node and obliterate the normal architecture (arrowheads); hematoxylin and eosin

submandibular lymph node, the previously described neoplastic cells were invading and replacing the bone (Figure 2a) and were effacing and replacing the normal architecture of the right submandibular lymph node (Figure 2b). Neoplastic cells were not identified in any of the other examined tissues.

## Discussion

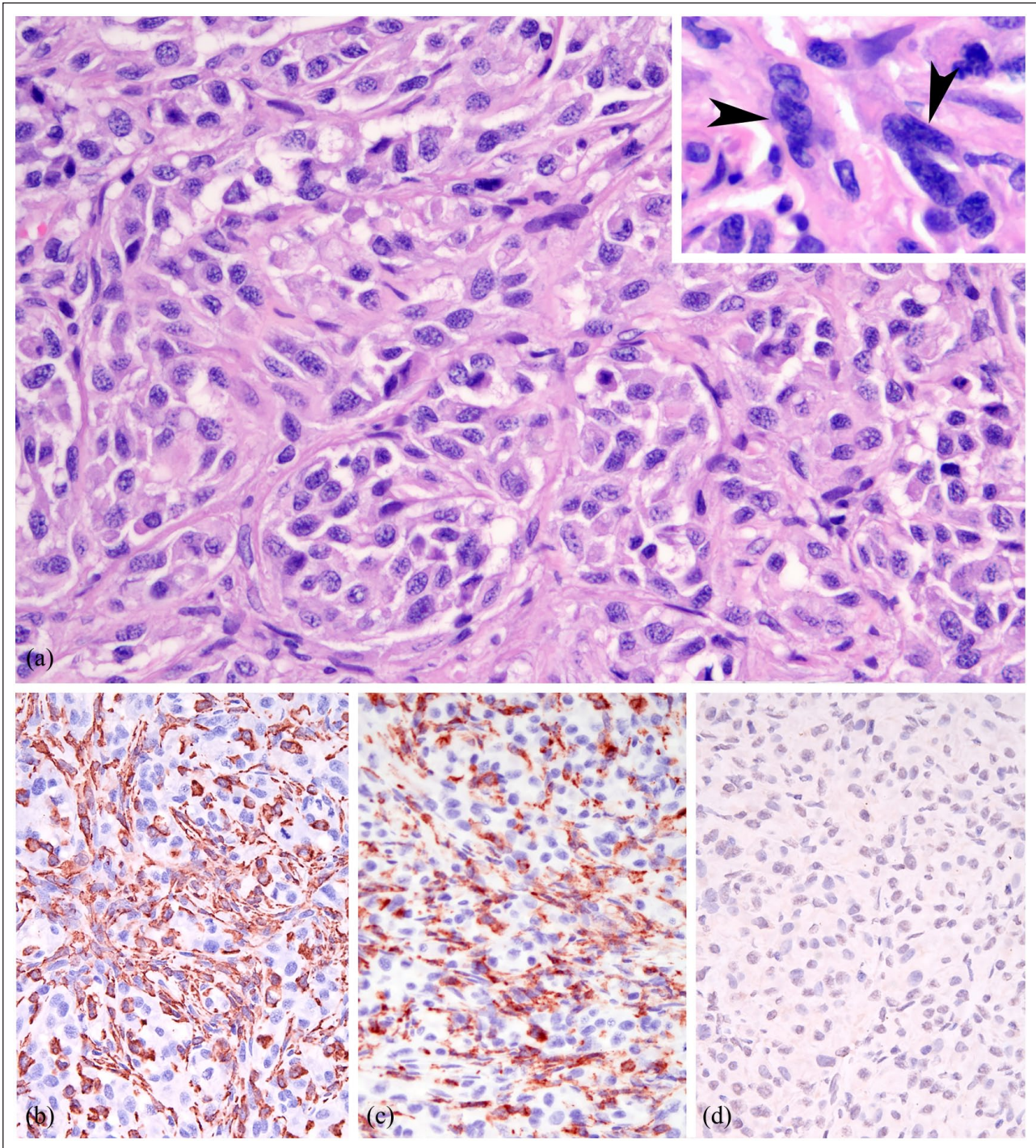
Histiocytic sarcomas in cats are considered uncommon and have been sporadically reported in a wide variety of anatomic locations, including the tarsus, mediastinum, disseminated, eye, nasopharynx and brain.<sup>1-13</sup> Oral histiocytic sarcomas, in particular, are considered rare in any species.<sup>14-16</sup> To date, there has only been one published report in a cat.<sup>17</sup> The most common differential diagnosis for an oral neoplasm in a cat is squamous cell carcinoma followed by fibrosarcoma.<sup>14,18</sup> Our case report describes the second known case of oral histiocytic sarcoma in a cat. The novel features of this case include the presence of extensive mandibular invasion and regional (right submandibular) lymph node metastasis. Additionally, this report is the first to use CD204 as one of the diagnostic steps in differentiating histiocytic sarcoma from the other, more common, poorly differentiated feline oral tumors, and is the first to use immunohistochemistry to determine the histiocytic lineage of oral histiocytic sarcoma in cats.

The tumor's neoplastic cells had large, indented-to-reniform nuclei and abundant eosinophilic cytoplasm; multinucleation was also occasionally observed (Figure 3a). Based on the microscopic features, the differential diagnoses included fibrosarcoma, amelanotic melanoma, plasmacytoma and histiocytic sarcoma. Accordingly, immunohistochemistry for Melan-A, S-100, MUM-1, Iba-1 and CD18 was performed. The diagnosis of histiocytic sarcoma was then made based on the presence of strong membranous staining for ionized calcium-binding adaptor molecule 1 (Iba1) (Figure 3b) and CD18. Both Iba-1 and

CD18 occur in all subpopulations of the macrophage/monocyte lineage (including Langerhans and interstitial dendritic cells [DCs]), in inflammatory and neoplastic histiocytes, as well as in normal histiocytes.<sup>19</sup> The neoplastic cells were also frequently positive for CD204 (Figure 3c); this is a scavenger receptor that is expressed by macrophages, and is a reliable marker for histiocytic sarcomas in dogs.<sup>20,21</sup> Neoplastic cells were diffusely negative for Melan-A, S100 and MUM-1 (Figure 3d), ruling out melanoma and plasma cell tumor. Spleen was used as a positive control for all histiocytic markers (CD18, Iba-1 and CD204) and MUM-1.

In dogs, immunostaining of most histiocytic sarcomas suggests that they are derived from interstitial DCs (CD1a+, MHC class II+ and CD11c/CD18+).<sup>1,22</sup> Interstitial DCs are resident DCs typically found within most organs except the brain.<sup>23</sup> Further classification of the histiocytic lineage of this neoplasm was attempted by performing immunohistochemistry for E-cadherin. E-cadherin staining, if present, suggests that neoplastic cells are likely of Langerhans DC origin. The neoplastic cells, in this case, were diffusely negative for E-cadherin; while this is suggestive of interstitial DC origin, it is important to note that a lack of E-cadherin staining does not completely rule out Langerhans DC origin because, after activation, Langerhans DCs can downregulate their expression of E-cadherin as they migrate to the dermis.<sup>1,24,25</sup> To definitively determine that histiocytes are of Langerhans DC origin, electron microscopy is needed to identify cytoplasmic Birbeck granules. Birbeck granules are induced when Langerhans DCs are exposed to transforming growth factor beta.<sup>1,24-26</sup> Further classification of the histiocytes with immunohistochemistry indicates that these neoplastic cells are most likely of interstitial DC origin. As previously mentioned, this finding is consistent with the current literature, as histiocytic sarcomas are predominantly of interstitial DC origin.<sup>1,22</sup>





**Figure 3** Oral histiocytic sarcoma in a cat; microscopic and immunohistochemical features. (a) Neoplastic cells are pleomorphic, ranging from round to spindloid and occasionally are multinucleated (inset, arrowheads); hematoxylin and eosin  $\times 400$ . Immunohistochemistry for (b) ionized calcium-binding adaptor molecule 1 (Iba-1), (c) CD204 and (d) multiple myeloma 1 (MUM-1); hematoxylin and eosin  $\times 400$

While histiocytic sarcomas of interstitial DC origin are most common, there are rare reports of neoplasms of macrophage–myeloid origin. For example, a nasal histiocytic sarcoma of macrophage–myeloid type was reported in a cat.<sup>13</sup> There was infiltration of the bone

marrow but no nodal metastasis and neoplastic cells were predominantly round and demonstrated phagocytic activity. The cells were immunohistochemically positive for lysozyme, CD18 and MHC class II, and cytochemically positive for alpha naphthyl acetate esterase.<sup>13</sup>



## Conclusions

In cats, histiocytic sarcoma is a rare differential diagnosis for primary oral neoplasia; however, this entity should be considered if, microscopically, the neoplasm is consistent with a poorly differentiated, pleomorphic sarcoma. Immunohistochemistry to confirm histiocytic origin and to exclude more common diagnoses is strongly recommended and may include CD18, Iba-1 and CD204. In this case, within 6 months, this aggressive tumor had invaded the mandible and metastasized to a regional lymph node. To our knowledge, while this is the second report of oral histiocytic sarcoma in a cat, it is the first to elucidate the tumor's behavior, predict patient prognosis and reaffirm what the literature purports; that is, histiocytic sarcomas typically originate from interstitial DCs.

**Acknowledgements** We would like to thank Dr Roberto Cediél for his attentive and thorough patient care while managing this rare condition.


**Conflict of interest** The authors declared no potential conflicts of interest with respect to the research, authorship, and/or publication of this article.

**Funding** The authors received no financial support for the research, authorship, and/or publication of this article.

**Ethical approval** This work involved the use of non-experimental animals only (including owned or unowned animals and data from prospective or retrospective studies). Established internationally recognized high standards ('best practice') of individual veterinary clinical patient care were followed. Ethical approval from a committee was therefore not specifically required for publication in *JFMS Open Reports*.

**Informed consent** Informed consent (either verbal or written) was obtained from the owner or legal custodian of all animal(s) described in this work (either experimental or non-experimental animals) for the procedure(s) undertaken (either prospective or retrospective studies). No animals or humans are identifiable within this publication, and therefore additional informed consent for publication was not required.

**ORCID iD** Sylvia H Ferguson  <https://orcid.org/0000-0002-3438-5223>

Jason D Struthers  <https://orcid.org/0000-0003-2456-636X>

Teela L Jones  <https://orcid.org/0000-0001-6786-619X>

## References

- Moore PF. **A review of histiocytic diseases of dogs and cats.** *Vet Pathol* 2014; 51: 167–184.
- Pinard J, Wagg CR, Girard C, et al. **Histiocytic sarcoma in the tarsus of a cat.** *Vet Pathol* 2006; 43: 1014–1017.
- Teshima T, Hata T, Nezu Y, et al. **Amputation for histiocytic sarcoma in a cat.** *J Feline Med Surg* 2012; 14: 147–150.
- Bisson J, Van den Steen N, Hawkins I, et al. **Mediastinal histiocytic sarcoma with abdominal metastasis in a Somali cat.** *Vet Rec Case Rep* 2017; 5: e000405.
- Smoliga J, Schatzberg S, Peters J, et al. **Myelopathy caused by a histiocytic sarcoma in a cat.** *J Small Anim Pract* 2005; 46: 34–38.
- Ide K, Setoguchi-Mukai A, Nakagawa T, et al. **Disseminated histiocytic sarcoma with excessive hemophagocytosis in a cat.** *J Vet Med Sci* 2009; 71: 817–820.
- Ide T, Uchida K, Tamura S, et al. **Histiocytic sarcoma in the brain of a cat.** *J Vet Med Sci* 2010; 72: 99–102.
- Bell R, Philbey AW, Martineau H, et al. **Dynamic tracheal collapse associated with disseminated histiocytic sarcoma in a cat.** *J Small Anim Pract* 2006; 47: 461–464.
- Friedrichs KR and Young KM. **Histiocytic sarcoma of macrophage origin in a cat: case report with a literature review of feline histiocytic malignancies and comparison with canine hemophagocytic histiocytic sarcoma.** *Vet Clin Pathol* 2008; 37: 121–128.
- Huber B and Leleonnec M. **Diagnosis and treatment of hemophagocytic histiocytic sarcoma in a cat.** *JFMS Open Rep* 2020; 6: 2055116920957196.
- Scurrrell E, Trott A, Rozmanec M, et al. **Ocular histiocytic sarcoma in a cat.** *Vet Ophthalmol* 2013; 16 Suppl 1: 173–176.
- Santifort KM, Jurgens B, Grinwis GC, et al. **Invasive nasal histiocytic sarcoma as a cause of temporal lobe epilepsy in a cat.** *JFMS Open Rep* 2018; 4: 2055116918811179.
- Wong VM, Snyman HN, Ackerley C, et al. **Primary nasal histiocytic sarcoma of macrophage-myeloid cell type in a cat.** *J Comp Pathol* 2012; 147: 209–213.
- Mikiewicz M, Pazdzior-Czapula K, Gesek M, et al. **Canine and feline oral cavity tumours and tumour-like lesions: a retrospective study of 486 cases (2015–2017).** *J Comp Pathol* 2019; 172: 80–87.
- Wingo K. **Histopathologic diagnoses from biopsies of the oral cavity in 403 dogs and 73 cats.** *J Vet Dent* 2018; 35: 7–17.
- Takahashi M, Tomiyasu H, Hotta E, et al. **Clinical characteristics and prognostic factors in dogs with histiocytic sarcomas in Japan.** *J Vet Med Sci* 2014; 76: 661–666.
- Necova S, North S, Cahalan S, et al. **Oral histiocytic sarcoma in a cat.** *JFMS Open Rep* 2020; 6: 2055116920971248.
- Stebbins KE, Morse CC and Goldschmidt MH. **Feline oral neoplasia: a ten-year survey.** *Vet Pathol* 1989; 26: 121–128.
- Pierezan F, Mansell J, Ambrus A, et al. **Immunohistochemical expression of ionized calcium binding adapter molecule 1 in cutaneous histiocytic proliferative, neoplastic and inflammatory disorders of dogs and cats.** *J Comp Pathol* 2014; 151: 347–351.
- Ide T, Uchida K, Kagawa Y, et al. **Pathological and immunohistochemical features of subdural histiocytic sarcomas in 15 dogs.** *J Vet Diagn Invest* 2011; 23: 127–132.
- Kato Y, Murakami M, Hoshino Y, et al. **The class A macrophage scavenger receptor CD204 is a useful immunohistochemical marker of canine histiocytic sarcoma.** *J Comp Pathol* 2013; 148: 188–196.

- 22 Affolter VK and Moore PF. **Localized and disseminated histiocytic sarcoma of dendritic cell origin in dogs.** *Vet Pathol* 2002; 39: 74–83.
- 23 D'Agostino PM, Gottfried-Blackmore A, Anandasabapathy N, et al. **Brain dendritic cells: biology and pathology.** *Acta Neuropathol* 2012; 124: 599–614.
- 24 Borkowski TA, Van Dyke BJ, Schwarzenberger K, et al. **Expression of E-cadherin by murine dendritic cells: E-cadherin as a dendritic cell differentiation antigen characteristic of epidermal Langerhans cells and related cells.** *Eur J Immunol* 1994; 24: 2767–2774.
- 25 Tang A, Amagai M, Granger LG, et al. **Adhesion of epidermal Langerhans cells to keratinocytes mediated by E-cadherin.** *Nature* 1993; 361: 82–85.
- 26 Argenta FF, de Britto FC, Pereira PR, et al. **Pulmonary Langerhans cell histiocytosis in cats and a literature review of feline histiocytic diseases.** *J Feline Med Surg* 2020; 22: 305–312.